

**SREE CHITRA TIRUNAL INSTITUTE FOR  
MEDICAL SCIENCES &  
TECHNOLOGY  
THIRUVANANTHAPURAM-695011**



**DIPLOMA IN CARDIAC LABORATORY TECHNOLOGY**

**January 2014 - December 2015**

*Work Book submitted in partial fulfillment of the requirements for the  
award of the  
Diploma in Cardiac Laboratory Technology*

**WORK BOOK  
by**

**ARCHA KRISHNA**  
DCLT Student  
Dept. of Cardiology  
SCTIMST  
Thiruvananthapuram

**SREE CHITRA TIRUNAL INSTITUTE FOR MEDICAL  
SCIENCES AND TECHNOLOGY**

*(An Institute of National Importance under Govt. of India)*

Thiruvananthapuram-695 011, Kerala, India



## *CERTIFICATE*

This is to certify that this is the bonafide work book of the laboratory work undertaken by **Mrs. Archa Krishna** in partial fulfillment of the requirements for the award of Diploma in Cardiac Laboratory Technology.

Place: Thiruvananthapuram    Prof:Dr. Jagan Mohan A Tharakan,  
Date : 15 November 2015        Head of the Department  
Department of Cardiology  
SCTIMST



## **PREFACE**

This work book, I have done as a part of my training in the Dept of Cardiology for Diploma in Cardiac Laboratory Technology (DCLT) course includes brief details of the equipment used in the Dept. and working involved with the equipments, the routine protocols and the procedures followed in our different labs, number of cases which I have individually done in ECG, ECHO, TMT, HOLTER labs and the cases which I have assisted in Cardiac Cath Lab.

DCLT is a two years full time residential programme conducted in the Department of Cardiology for Students from Bachelor of Physics community to excel and learn the newer techniques in the field of cardiology. Selection is done by a national level entrance examination. At present Institute offers 3 seats.

The students are posted in the Department of Cardiology equipped with all modern medical facilities. During the two year programme, first year posting is in noninvasive cardiology and the second year is in invasive cardiology. The course schedule contains theory classes, practical training, seminar presentations and projects. Diploma is awarded after successful completion of 2 year term based on a written examination with viva-voce and internal assessment.



## **ABOUT OUR INSTITUTION**

The Sree Chitra Tirunal Institute for Medical Sciences & Technology (SCTIMST), Thiruvananthapuram is an Institute of National Importance established by an Act of the Indian Parliament. It is an autonomous Institute under the administrative control of the Department of Sciences and Technology, Govt.of India.

The Institute signifies the convergence of medical sciences and technology and its mission is to enable the indigenous growth of biomedical technology, besides demonstrating high standards of patient care in medical specialities and evolving postgraduate training programs in advanced medical specialities, biomedical engineering and technology, as well as in public health.

The hospital has 253-beds and serves as hospital tertiary care of cardiovascular and neurological diseases, a biomedical technology wing with facilities for developing medical devices from a conceptual stage to commercialization, and a center of excellence for training and research in public health.

The Institute has the status of a University and offers post doctoral, doctoral and postgraduate courses in medical specialities, public health, nursing, basic sciences and health care technology. It is a member of the Association of Indian Universities and the Association of Commonwealth Universities.



## **DECLARATION**

I declare that I have actually performed all the procedures listed in this work book during my course and this work book has not been submitted in any form, whole or part for awarding another degree or diploma at any other university or institution of higher education.

Place : Thiruvananthapuram

Archa Krishna

Date : 15 November 2015



## **ACKNOWLEDGEMENT**

First and foremost I would like to thank to Head of the Department of Cardiology **Dr. Jagan Mohan A Tharakan** and all other faculty members of the department who guided through the different cases of studies and encouraged and helped me in all aspect of my training.

I thank the director of this Institute, **Dr. Asha Kishore**, Dean **Dr. Suresh Nair** and Registrar **Dr. A.V George** for their valuable advice,help and attention towards me. I express my gratitude to **Mr. Koruthu P varghese**, the Head of the Department of Biomedical Engineering for his precious advice that helped me for the successful completion of the course.

I extend my heartfelt thanks to all Technical staff and technical head **Mrs. Suji K**, for their timely guidance and ideas that helped to learn more. Iam also grateful to all PG Students of the Deptartment of Cardiology. Iam also thankful to all my friends who helped during the study in the Institute and the patients who were the core medium of study.

At last I would like to acknowledge my sincere thanks to all colleagues for their co-operation in the work places and in the studies. I also thank to all other colleagues, Technical and Service personal and well wishers who helped me in all the way during the last two year of my study.

Archa Krishna



# **CONTENTS**

## **I. CARDIAC ANATOMY**

Cardiac surface anatomy.....	3
Cardiac chambers.....	4
Cardiac valves.....	8
The conduction system.....	10
Coronary arteries.....	15
Coronary veins.....	19
The arterial circulation.....	20
The venous circulation.....	23

## **II. CARDIOVASCULAR PHYSIOLOGY**

The cardiac cycle.....	28
Heart sounds and murmurs.....	34
Cellular physiology terminology.....	35
Pressure waves in the heart.....	38
Shunt detection and quantification.....	45

## **III. CARDIAC PATHOLOGY**

Coronary artery disease.....	49
Heart failure.....	52
Congenital heart disease.....	54
Hypertensive heart disease.....	68
Disorders of lungs and pulmonary circulation.....	69
Rheumatic fever and rheumatic heart disease.....	70
Disorders of the cardiac valves.....	71

Pericardial disease..... 74

Tumours of the heart..... 75

#### IV. ELECTROCARDIOGRAPHY

The cardiac electrophysiology..... 77

Waves of normal electrocardiogram..... 78

The cardiac axis..... 83

Normal ECG..... 85

Sinus rhythm disturbance..... 86

Atrial arrhythmias..... 87

Junctional rhythms..... 89

Atrioventricular heart blocks..... 90

Pre Excitation syndrome..... 91

Interventricular conduction disturbance..... 92

Ventricular arrhythmias..... 93

Atrial enlargement..... 95

Myocardial ischemia..... 97

#### V. ECHOCARDIOGRAPHY

Principles and techniques of ECHO..... 102

Transducers..... 106

Imaging window..... 107

Contrast ECHO..... 112

Stress ECHO..... 113

3D..... 114

Transesophageal ECHO..... 115

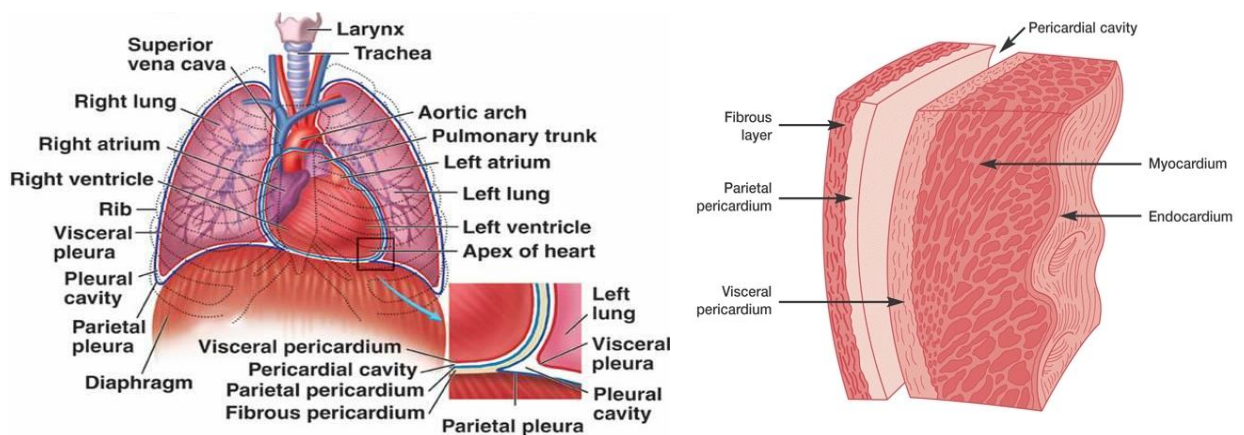
VI.	AMBULATORY ELECTROCARDIOGRAPHY	
	HOLTER monitoring.....	118
	Components.....	120
	Analyzing software.....	122
VII.	STRESS ELECTROCARDIOGRAPHY	
	Basic principles.....	125
	Equipments necessary in exercise laboratory.....	126
	Electrocardiographic response.....	129
VIII.	HARDWARES	
	Tools for catheterization.....	133
	Catheters .....	137
	Guide catheters.....	144
	Coronary guide wires.....	148
	Coronary balloon.....	153
	Coronary stents.....	157
	Closure devices.....	163
	Valvuloplasty balloon.....	165
	Coils and Biopptome.....	168
	C7 Dragonfly catheters.....	170
	Foreign body retrieval catheters.....	171
	Cuvettes and ACT.....	171
	Cleaning and sterilization	172
IX.	CARDIAC CATHETERIZATION DIAGNOSTIC STUDIES AND PROCEDURE	
	Indications and contraindications.....	177
	Percutaneous vascular access.....	179

	Right heart catheterization.....	182
	Left heart catheterization.....	183
	Radio contrast media.....	189
	Coronary angiography.....	191
	Fractional flow reserve.....	197
	Percutaneous coronary interventions.....	205
	Coronary atherectomy.....	206
	Intravascular ultra sound.....	211
	Optical coherence tomography.....	214
	Transluminal alcohol septal ablation.....	219
	Percutaneous transluminal mitral valvulopalsty.....	221
	Congenital procedures.....	227
	Endomyocardial biopsy.....	241
	Cardiac tamponade.....	242
X.	<b>CARDIAC ELECTROPHYSIOLOGY AND DEVICE IMPLANTATION</b>	
	Cardiac electrophysiology.....	249
	Advanced mapping and navigation modalities.....	264
	Pacemakers.....	266
	Implantable cardiovascular defibrillation.....	274
	Cardiac resynchronization therapy.....	278
XI.	<b>INTRA-AORTIC BALLOON COUNTERPULSATION.....</b>	<b>285</b>
XII.	<b>CARDIAC EMERGENCY DRUGS.....</b>	<b>299</b>
XIII.	<b>COMPLICATIONS IN INTERVENTIONAL PROCEDURES.....</b>	<b>304</b>
XIV.	<b>DEPARTMENTAL EQUIPMENTS.....</b>	<b>312</b>
XV.	<b>CATEGORIES OF BIOMEDICAL WASTE.....</b>	<b>334</b>
XVI.	<b>LOG BOOK</b>	

# **CARDIAC ANATOMY**

## THE HEART

Andreas Vesalius (1514-1564) is considered the “father” of modern anatomy. The heart is a roughly cone shaped hollow muscular organ. It is about 10cm long and is about the size of the owner’s fist. It weighs about 225g in women’s and is heavier in men about 310g. It is placed in the middle of chest or thoracic cavity (middle mediastinum), posterior to the body of sternum and the second to sixth costal cartilages and anterior to the fifth to the eighth thoracic vertebrae. The heart rests on the superior surface of the diaphragm. The heart has a base, which is formed by the atria and great arteries, and an apex, which is formed by the junction of ventricles and ventricular septum.



The heart lies in a double walled fibroserous sac called **pericardial sac**, which is divided into (a) fibrous pericardium and (b) serous pericardium. The fibrous pericardium envelops the heart and attaches onto the great vessels. The serous pericardium is a closed sac consisting of two layers – a visceral layer or epicardium forming the outer lining of the great vessels and the heart, and a parietal layer forming an inner lining of the serous pericardium contain the pericardial fluid, which prevents friction between the heart and the pericardium.

The wall of heart is composed of three layers: (a) epicardium: (b) myocardium: and (c) endocardium.

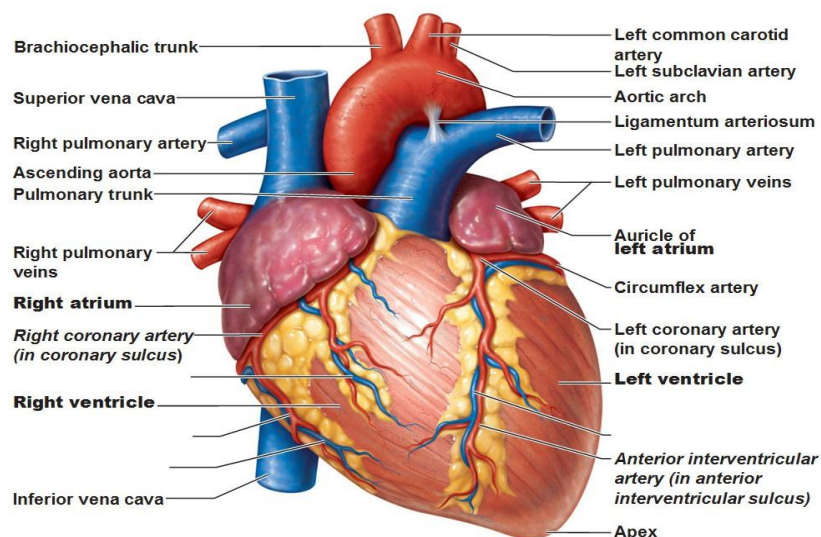
The **epicardium** is the outer lining of the cardiac chambers and is formed by the visceral layer of the serous pericardium. The **myocardium** is the intermediate layer of the heart and is composed of three discernable layers of muscle that are seen predominantly in the left ventricle and inter-ventricular septum alone and includes a subepicardial layer. The rest of the heart is composed mainly of the subepicardial and subendocardial layers. The myocardium also contains important structures such

as excitable nodal tissue and conducting system. The **endocardium** the innermost layer of the heart is formed by endothelium and subendothelial connective tissue.

## CARDIAC MUSCLE TISSUE

Cardiac muscle cells make up the myocardium portion of the heart wall. They are relatively short, branched fibers that measure approximately 10-20 micrometers in diameter and 50-100 micrometers in length. Typically each cardiac myocyte contains a single nucleus, which is centrally positioned. The cell is a short cylinder, with striations and a single central nucleus surrounded by a light perinuclear space. These cells branch, and at rectangular intervals, the cytoplasm reveals a transverse dark line called the 'intercalated disc'. It has partial properties both of the skeletal and the smooth muscle of fibres.

## CARDIAC SURFACE ANATOMY



Because of its shape, the heart has three surfaces: anterior, inferior and posterior. Often the surfaces are referred to as: sternocostal (anterior), diaphragmatic (inferior) and base (posterior). The apex of the heart is directed downward, forward and to the left.

**Anterior (Sternocostal) surface:** It is formed mainly by the right atrium and right ventricle. They are separated from each other by the vertical atrioventricular groove. The right border of the anterior surface is formed by the right atrium while the left border is formed by left atrium and part of left auricle.

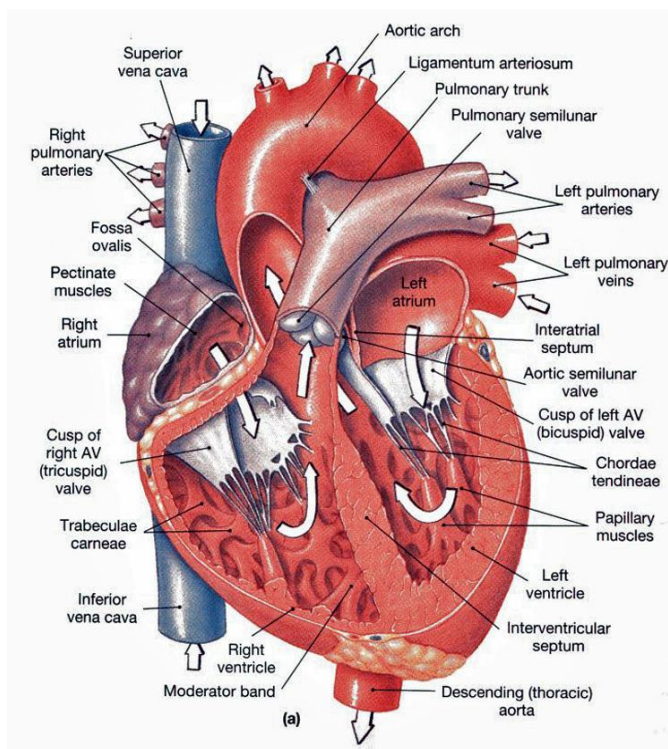
**Inferior (Diaphragmatic) surface:** It is formed mainly by the right and left ventricles separated by the posterior interventricular groove. The inferior surface of the right atrium into which the inferior vena cava opens, also forms part of this surface.

**The base of the heart (posterior surface):** It is formed mainly by the left atrium, into which the four pulmonary veins drain. It lies opposite to the apex. Often, the beginners think of the diaphragmatic surface of the heart as its base because of the fact that the heart rests on it, however, it should be kept in mind that the heart does not rest on its base. It rests on the diaphragmatic surface which is not the base. The posterior surface is called the base because it lies opposite to the apex of the pyramidal shaped heart.

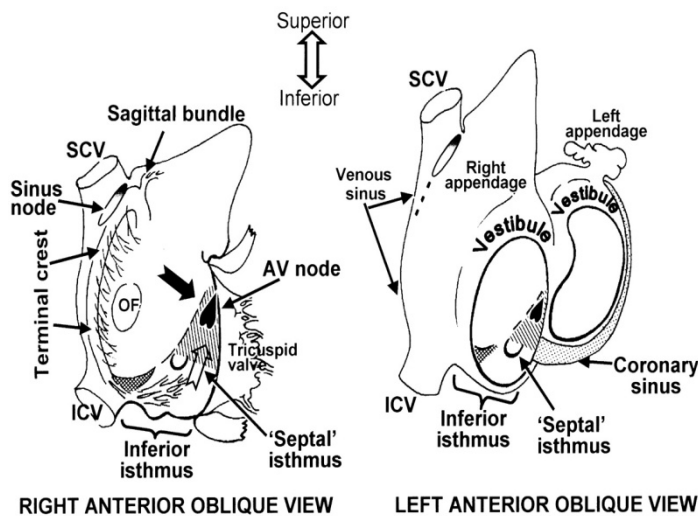
Each atrium has an appendage (auricle), a small muscular pouch on the surface of each atrium, resembling an ear lobe.

The annulus fibrosus, considered as the heart's skeleton, is a plane of connective tissue composed four fibrous rings. Two of these rings form the interface between the atria and the ventricles and constitute an attachment for the muscular fibres and the atrioventricular valves. The two other fibrous rings surround arterial orifices and serve for attachment of the great blood vessels and the semilunar valves.

## CARDIAC CHAMBERS



## RIGHT ATRIUM



Venous blood returns to the heart via superior and inferior venae cavae into the right atrium, where it is stored during right ventricular systole. During ventricular diastole, blood flows from the right atrium into the right ventricle.

The right atrium is larger than the left, but its wall is somewhat thinner, about 2 mm thick. The capacity of the right atrial cavity is about 57 millilitres. The right atrium consists of two regions: Anteromedially, the right **atrial appendage** produces from the right atrium and overlaps the aortic root. On the posterior external surface of the right atrium a ridge, the **sulcus terminalis** (or terminal groove), extends vertically from the superior to the inferior vena cava. This corresponds to an internal muscular bundle, the **crista terminalis**. The sinus node is usually located at the lateral margin of the junction of the superior vena cava with the right atrium and the right atrial appendage. The inner surface of the posterior and medial walls of the right atrium is smooth, while the surface of the lateral wall and of the right atrial appendage are composed of parallel muscle bundles, the **pectinate muscles**.

There are four openings in the right atrium that are:

**The superior vena cava (svc)**, which returns blood from the upper half of the body, the opening of SVC has no valve. **The inferior vena cava (IVC)**, that returns blood from the lower half of the body. A rudimentary valve, **the Eustachian valve**, formed by a crescentic fold. **The coronary sinus**, which returns blood from the coronary circulation. **The Thebesian valve**, sometimes guards the opening of coronary sinus. The valve is formed by a fold of the lining membrane of the atrium.

**Right atrioventricular orifice**, it lies anterior to the opening for inferior vena cava and is guarded by the tricuspid valve.

The posterior cusp and right coronary cusp of the aortic root lean against the medial right atrium, forming a normal slight bulge known as the **torus aorticus**. The insertion of crista terminalis through the interatrial groove is the origin of an important muscular bundle that runs from the right to left atrium, **Bachmann's bundle**. The **Atrioventricular node** is located in the lower atrial septum, just above the septal leaflet of the tricuspid valve. **The Koch's triangle** is the landmark for the AV node bundle: at the angle formed by the tendon of Todaro and the annulus of the septal leaflet of the tricuspid valve.

The **fossa ovalis (oval fossa)** is an oval depression in the atrial septum that separates the right and left atrial cavities. It lies at the lower part of the septum, above and to the left of the orifice of the inferior vena cava.

### **RIGHT VENTRICLE**

Right ventricle receives venous blood from the right atrium during ventricular diastole and propels blood into the pulmonary circulation during ventricular systole. The right ventricle is normally the most anterior cardiac chamber, lying directly beneath the sternum. The right ventricle, which normally contracts against very low resistance, has a crescent-shaped chamber and a thin outer wall, measuring 4 to 5 mm thickness. The anterior right ventricular wall curves over the ventricular septum, which normally bulges into the right ventricular cavity. The walls of right ventricle are much thicker as compared to those of right atrium. They show several internal projecting ridges, which are formed of muscle bundles. These ridges are known as **trabeculae carneae** and they give the walls a spongy appearance. They are of three types:

Type 1: First type of trabeculae consists of papillary muscles, which project inward. They are attached by their bases to the ventricular wall and their apices are attached by fibrous chords, known as **chordae tendinae**, to the cusps of the tricuspid valve.

Type 2: Second type consists of muscle fibers attached to the ventricular walls in the same way as the first type but they are free in the middle. One of them, known as the **moderator band**, crosses the entire ventricular cavity from septal to anterior wall.

Type 3: It is simply composed of prominent ridges.

The right ventricle can be partitioned into an inflow tract, an outflow tract, and an apical trabecular component. The trabecular muscles in the apex of the right ventricle are much coarser than those in the left ventricle. There are two openings in the right ventricle: the right atrioventricular orifice (guarded by tricuspid valve) and the opening for the pulmonary trunk (guarded by the pulmonary valve). The smooth walled outflow tract, also referred to as the **infundibulum**, forms the superior part of the right ventricle. It is separated from the inflow tract by a thick muscle, the crista supraventricularis. The area of the ventricular wall below the pulmonary valve is called **right ventricular outflow tract (RVOT)**.

### **LEFT ATRIUM**

The left atrium receives blood from the pulmonary veins and serves as the reservoir during the left ventricular systole and as conduit during left ventricular filling. The left atrium is located superiorly, in the midline and posterior to the other cardiac chambers. The wall of the left atrium is 3mm thick, slightly thicker than that of the right atrium.

The left atrial appendage lies to the left and anterior to the main pulmonary artery. The four pulmonary veins, two right and two left, superior and inferior veins, connect with left atrium posteriorly, conveying oxygenated blood from the lungs. The openings of the pulmonary veins are not guarded by any valve, however, the left atrioventricular orifice is guarded by bicuspid valve.

The endocardium of the left atrium is smooth and slightly opaque. Pectinate muscles are present only in the left atrial appendage. The atrial septum is smooth but may contain a central shallow area, corresponding to the fossa ovalis.

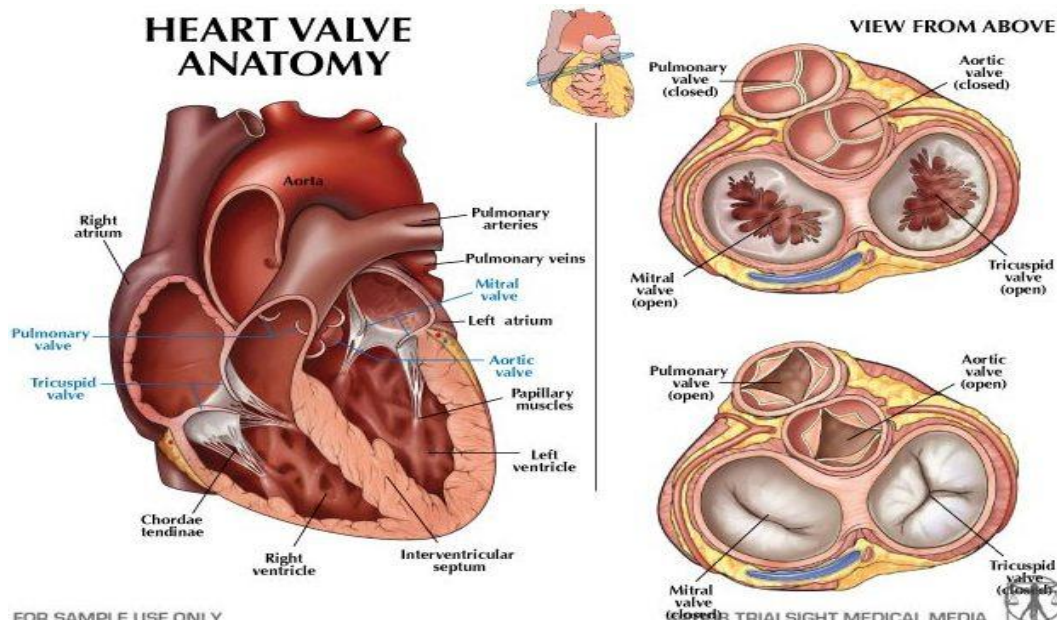
### **LEFT VENTRICLE**

The left ventricle receives blood from the left atrium during ventricular diastole and ejects blood into the systemic arterial circulation during ventricular systole. The left ventricle is roughly bullet shaped, with the blunt tip directed anteriorly, inferiorly, and to the left, where it contributes, with the lower ventricular septum, to the apex of the heart.

It is the strongest chamber of the heart. Its walls measuring 8 to 15 mm, or three times thicker than those of the right ventricle. The reason for extra thick walls is that the left ventricle has to deal with high pressures. The pressure inside the left ventricle is about six times higher than that inside the right ventricle. In cross section, the right ventricle is circular and consequently the right ventricle is crescentic. It is because of the bulging of the interventricular septum into the right ventricle. There

are two openings in the left ventricle: the left atrioventricular orifice (guarded by mitral valve, also known as bicuspid valve) and the aortic opening (guarded by aortic valve). The apical portion of the left ventricle is characterized by fine trabeculations.

## CARDIAC VALVES



The heart contains four cardiac valves: two semilunar valves and atrioventricular valves. The two semilunar valves, aortic and pulmonic, the outlet orifice of their respective left and right ventricles. The two AV valves, mitral and tricuspid, guard the inlet orifice of their respective left and right ventricles. The four cardiac valves are surrounded by the fibrous tissue forming partial or complete “rings” (valve annulus).

## SEMILUNAR VALVES

**The aortic valve** separates the left ventricular outflow tract from the ascending aorta. The aortic valve has also been called the left semilunar valve and the left arterial valve and has three leaflets, or cusps: the left coronary cusp, the right coronary cusp, and the non-coronary cusp. The inlets to the coronary artery system can be found within the sinus of Valsalva, superior to the the leaflet attachments and inferior to the sinotubular junction. The left coronary ostium is found midway between the commissures of the left coronary cusp, and almost immediately branches into the anterior interventricular branch and the circumflex branch. The right coronary ostium is found above the right coronary cusp and gives rise to the

right coronary artery. The final cusp is named the non-coronary cusp and is positioned posteriorly relative to the other two cusps.

**The pulmonary valve** separates the right ventricular outflow tract of the right ventricle from the pulmonary trunk. The pulmonary valve can also be referred to as the pulmonic valve, the right semilunar valve, and the right arterial valve. Its three leaflets, or cusps, are difficult to name because of the oblique angle of the valve. Its nomenclature is therefore derived based on the nomenclature of the aortic valve, which lies in proximity to it. The two leaflets attached to the septum are named the left and right leaflets, and correspond to the right and left leaflets of the aortic valve, which they face. The third leaflet is called the anterior leaflet or the non-coronary leaflet (to maintain the nomenclature of the aortic valve).

### **ATRIOVENTRICULAR VALVES**

**The mitral valve** is also called the bicuspid valve and the left atrioventricular valve. As the name bicuspid valve may suggest, the mitral valve is considered to have two primary leaflets: the anterior and posterior leaflets. The anterior leaflet has also been called the septal, medial, or aortic leaflet, while the posterior leaflet is also referred to as the lateral, marginal, or mural leaflet. Each leaflet is then further broken down into scallops divided by commissures, or zones of apposition. Due to the high variability of leaflet and scallop anatomy, and an alphanumeric nomenclature has been proposed by Carpentier that breaks the leaflets into regions. Three regions are found on the anterior leaflet (A1-A3) with opposing regions on the posterior leaflet (P1-P3). The subvalvular apparatus of the mitral valve consists of chordae tendinae attaching to the anterior and posterior papillary muscles of the left ventricle.

**The tricuspid valve**, also called the right atrioventricular valve, gets its name because it is generally considered to have three leaflets: the anterior, posterior and septal leaflets. Of these, the anterior, also called the infundibular or anterosuperior, leaflet is typically the largest. The posterior leaflet is also referred to as the inferior or marginal leaflet and the septal leaflet is also referred to as the medial leaflet. Terminating on the ventricular side of the tricuspid valve leaflets, the chordae tendinae are connected to three papillary muscles in the right ventricle. In humans, the three papillary muscles of the right ventricle have highly variable anatomy. The anterior papillary muscle is usually the most prominent, with the moderator band terminating at its head. The moderator band typically originates from the septal papillary muscle. The septal papillary muscle is normally the least prominent, and is missing 21.4% of the time.

## **SUPERIOR VENA CAVA, INFERIOR VENA CAVA, PULMONARY TRUNK, AORTA AND PULMONARY VEINS:**

### **SUPERIOR VENA CAVA**

The superior vena cava (SVC) is a large valveless venous channel formed by the union of the brachiocephalic veins. It receives blood from the upper half of the body (except the heart) and returns it to the right atrium.

The SVC begins behind the lower border of the first right costal cartilage and descends vertically behind the second and third intercostal spaces to drain into the right atrium at the level of the third costal cartilage. Its lower half is covered by the fibrous pericardium, which it pierces at the level of the second costal cartilage.

### **INFERIOR VENA CAVA**

The inferior vena cava (IVC) drains venous blood from the lower trunk, abdomen, pelvis and lower limbs to the right atrium of the heart.

The IVC is formed by the confluence of the two common iliac veins at the L5 vertebral level. The IVC has a retroperitoneal course within the abdominal cavity. It runs along the right side of the vertebral column with the aorta lying laterally on the left. Various other veins drain into the IVC along its course before it passes through the diaphragm at the caval hiatus at the T8 level. It has a short intra-thoracic course before draining into the right atrium.

### **PULMONARY TRUNK**

The pulmonary artery, which is one of the great arteries and is sometimes referred to as the main pulmonary artery or pulmonary trunk, is a major blood vessel in the heart through which blood is transported to our lungs from the right ventricle. While most arteries transport oxygenated blood to different parts of the body, the pulmonary artery delivers de-oxygenated blood to the right and left lungs

In an average person, it has a length of approximately five centimetres (two inches) and a width of about three centimetres (one-point-two inches). The main pulmonary artery (MPA) is intrapericardial and courses posteriorly and superiorly from the pulmonic valve. It divides into the left pulmonary artery (LPA) and right pulmonary artery (RPA) at the level of the fifth thoracic vertebra. The RPA is longer than the LPA and crosses the mediastinum, sloping slightly inferiorly to the right lung hilus. The LPA represents the continuation of the MPA.

## **PULMONARY VEINS**

The pulmonary veins along with the bronchial veins are part of the venous drainage system of the lungs. The pulmonary veins drain oxygenated blood to the left atrium.

There are typically four pulmonary veins:

Right superior - drains right upper and middle lobes

Right inferior - drains right lower lobe

Left superior - drains left upper lobe

Left inferior - drains left lower lobe

The pulmonary veins course in the intersegmental septa and as such do not run with the bronchi like the pulmonary arteries do. The superior pulmonary vein takes an oblique inferomedial course whereas the inferior pulmonary veins run horizontally peripherally before taking a more vertical course. They pass through the lung hilum, antero-inferiorly to the pulmonary arteries, forming a short intrapericardial segment, to drain into the left atrium. The ostia of the inferior pulmonary veins are more posteromedial and the left pulmonary veins being more superior.

There is extensive communication with deep bronchial veins within the lung and with the superficial bronchial veins at the hilum. The pulmonary veins are covered by a short (~9mm) myocardial layer, which is often the focus of atrial fibrillation with the left superior pulmonary vein being the foci for almost half of cases.

## **AORTA**

The aorta is the largest vessel in the body. It transports oxygenated blood from the left ventricle of the heart to every organ. The aorta starts in the heart with the aortic valve; immediately adjacent is the aortic root, followed by the ascending aorta, the transverse aorta (the aortic arch), the descending aorta, and the thoracoabdominal aorta. The aorta ends in the abdomen after bifurcation (to divide or fork into two branches) of the abdominal aorta in the two common iliac arteries.

The size of the aorta is directly proportionate to the patient's height and weight. Its diameter may range from 3cm (more than an inch) to 1.2cm (half an inch). It is typically the largest in the aortic root and smallest in the abdominal aorta.

The aorta is divided as here in seven sections:

**Aortic valve:**

The aorta starts with the aortic valve just below the first branches of the aorta, the coronary arteries.

**Aortic Root:**

The aortic root is the segment above the aortic valve and below the sinotubular junction. The left and right coronary arteries - supplying the heart with oxygenated blood – arise here from the sinuses of Valsalva.

**Ascending aorta:**

The ascending aorta arises from the upper end of the left ventricle. It is about 5 cm long and enclosed in the pericardium. The ascending aorta is the segment between the sinotubular junction and the largest aortic branch vessel; the innominate (brachiocephalic) artery. This is the only portion of the aorta that does not give any branch vessels. The ascending aorta is the most anterior (toward the front of the body) portion of the aorta.

**Aortic arch:**

Arch of the aorta is the continuation of the ascending aorta. It is situated in the superior mediastinum behind the lower half of the manubrium sterni. It begins at the level of the upper border of the second sternocostal articulation of the right side, and runs at first upward, backward, and to the left in front of the trachea; then travels backward on the left side of the trachea and finally passes downward on the left side of the body of the fourth thoracic vertebra. At this point the aortic arch continues as the descending aorta.

The aortic arch has three branches. The first, and largest, branch of the arch of the aorta is the brachiocephalic trunk, which is to the right and slightly anterior to the other two branches and originates behind the manubrium of the sternum. Next, the left common carotid artery originates from the aortic arch to the left of the brachiocephalic trunk and then ascends along the left side of the trachea and through the superior mediastinum. Finally, the left subclavian artery comes off of the aortic arch to the left of the left common carotid artery and ascends, with the left common carotid, through the superior mediastinum and along the left side of the trachea. The arch of the aorta forms two curvatures: one with its convexity upward, the other with its convexity forward and to the left. Its upper border is usually about

2.5 cm. below the superior border to the manubrium sterni. Blood flows from the upper curvature to the upper regions of the body, located above the heart - namely the arms, neck, and head.

### **Descending thoracic aorta:**

The descending aorta (thoracic aorta) is between the arch of the aorta and the diaphragm muscle below the ribs. It lies in the posterior mediastinum. At the origination point, it is on the left side of the vertebrae. As it descends, it winds around the vertebrae and ends in front. The diameter of the artery is 2.32 centimeters. It has six paired branches: bronchial arteries, mediastinal arteries, esophageal arteries, pericardial arteries, superior phrenic artery, and intercostal arteries. There are nine pairs of the intercostal arteries. The right branches are longer than the left, because the descending aorta (thoracic aorta) is on the left side of the vertebrae. Through its various branches, it supplies blood to the esophagus, lungs, and the chest area, including the ribs and mammary glands.

### **Abdominal aorta:**

The abdominal aorta branches to the intestine and the kidneys and divides into left and right common iliac arteries. The branch vessels of the abdominal aorta include the celiac artery, the superior mesenteric artery, the left and right renal arteries, and the inferior mesenteric artery.

### **Thoracoabdominal aorta:**

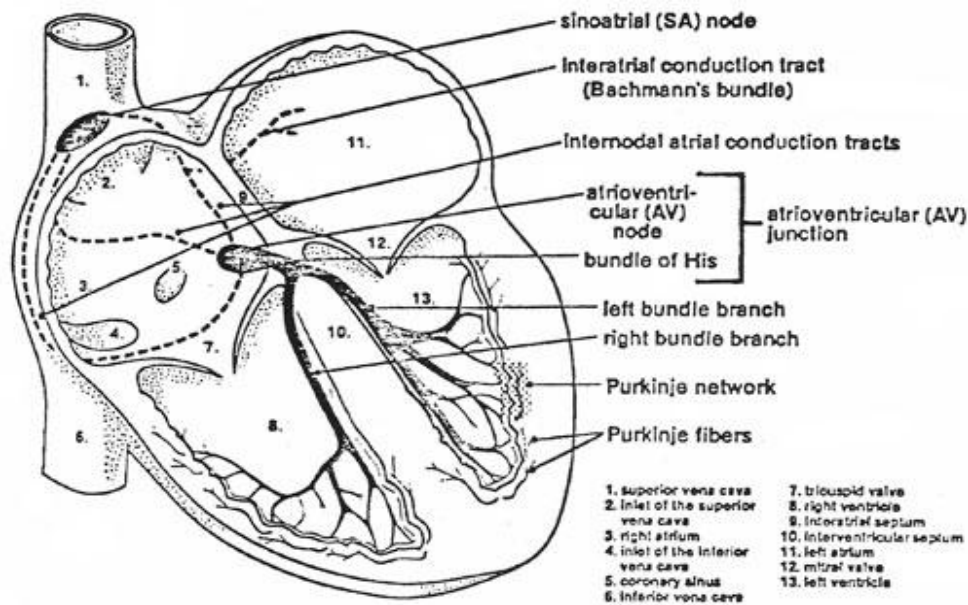
The thoracoabdominal aorta is the segment starting past the last branch of the aortic arch and ends with the abdominal aortic bifurcation into left and right common iliac artery.

### **Microscopic anatomy of the aorta:**

The aortic wall is made up of three layers:

- Inner layer of the intima (far left).
- Middle layer of the media (center).
- Outer layer of the adventitia that includes vessels (vasovasorum) supplying the aortic wall with oxygenated blood.

## THE CONDUCTION SYSTEM OF HEART



The electrical conduction system of the heart is composed of sinoatrial (SA) node, internodal atrial conduction tracts, interatrial conduction tract, atrioventricular (AV) node, bundle of HIS, right and left bundle branches, and Purkinje network. The AV node and the bundle of HIS form the AV junction. The bundle of HIS, the right and left bundle branches, and the Purkinje network are also known as the HIS-Purkinje system of the ventricles. As its sole function, the electrical conduction system of the heart transmits minute electrical impulses from the SA node (where they are normally generated) to the atria and ventricles, causing them to contract.

The SA node lies in the wall of the right atrium near the inlet of the superior vena cava and consists of pacemaker cells that generate electrical impulses automatically and regularly. The AV node lies partly in the right side of the interatrial septum in front of the opening of the coronary sinus tricuspid valve.

**Function of conducting system of heart:** The conducting system of heart is responsible not only for generating rhythmical cardiac impulses but also for conducting these impulses rapidly throughout the myocardium of the heart. Thus it aids in coordinated and efficient contraction of different chambers of the heart.

The activities of the conducting system of heart can be influenced by the autonomic nerve supply of heart. The parasympathetic nerves slow the rhythm and

diminish the speed of conduction, while the sympathetic nerves have the opposite effect.

**Internodal pathways:** Impulses from the sinuatrial node have been shown to travel to the atrioventricular node more rapidly than they can pass through the muscle of the heart. This can be explained by presence of specialized pathways in the atrial wall, which have a structure in between that of the Purkinje fibers and ordinary muscle cells. These specialized pathways are called internodal pathways and there are three of them in the atrial wall.

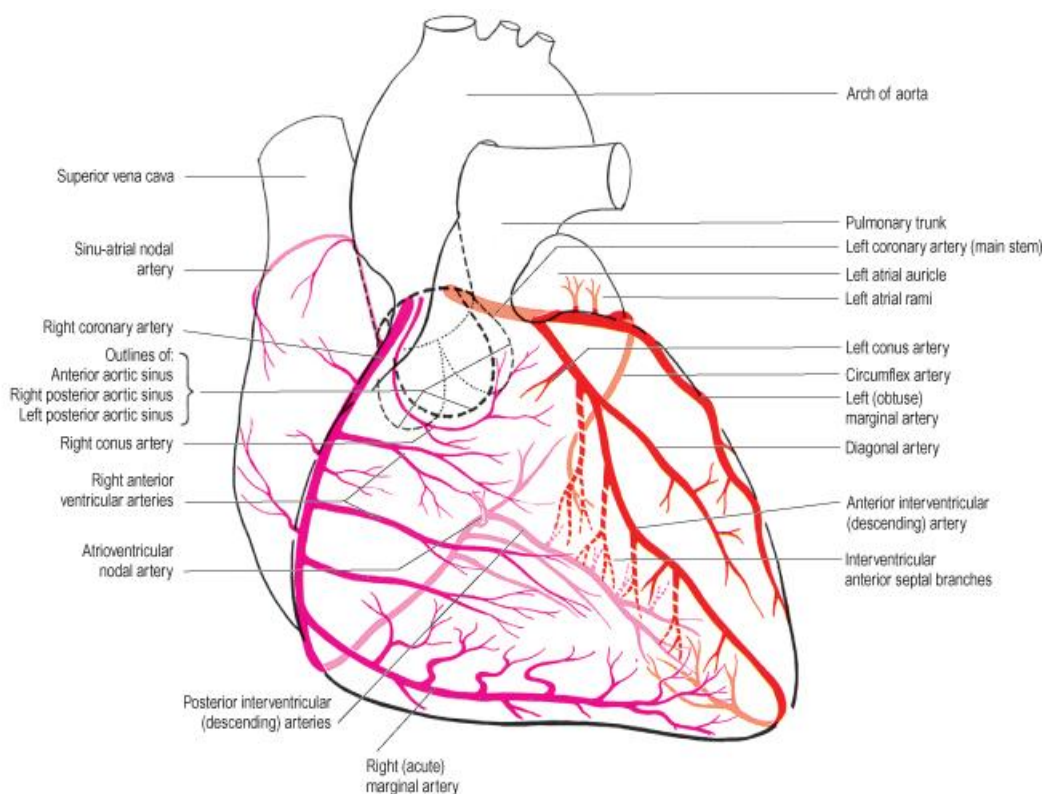
**Anterior internodal pathway:** It leaves the anterior end of the SA node and passes anterior to the superior vena cava to end in the AV node.

**Middle internodal pathway:** It leaves the posterior end of the SA node and passes posterior to the superior vena cava to end in the AV node.

**Posterior internodal pathway:** It leaves the posterior part of the SA node and descends through the crista terminalis to end in the AV node.

## **CORONARY ARTERIES**

The heart muscle, like every other organ or tissue in your body, needs oxygen-rich blood to survive. Blood is supplied to the heart by its own vascular system, called coronary circulation.



## **CORONARY OSTIA**

### **Location:**

The coronary arteries originate as the right and left main coronary arteries, which exit the ascending aorta just above the aortic valve (coronary ostia). There are three cusps of the aortic valve: the non-coronary cusp, which contains no ostia, the right coronary cusp, which contains the ostia of the right coronary artery, and the left coronary cusp, which contains the ostia of the left (main) coronary artery. The ostia of the left and right coronary arteries are located just above the aortic valve, as are the left and right sinuses of Valsalva.

### **Function:**

Oxygenated blood is pumped into the aorta from the left ventricle; it then flows into the coronary artery ostia. Blood flow into the coronary arteries is greatest during ventricular diastole.

## **RIGHT CORONARY ARTERY**

### **Location:**

The right coronary artery emerges from the aorta into the AV groove. It descends through the groove, then curves posteriorly, and makes a bend at the crux of the heart and continues downward in the posterior interventricular sulcus. Within millimeters after emerging from the aorta, the right coronary artery gives off two branches: 1) the conus (arteriosus) artery which runs to the right ventricular outflow tract, and 2) the atrial branch which gives off the SA nodal artery (in ~ 50-73% of hearts), which runs along the anterior right atrium to the superior vena cava, encircling it before reaching the SA node. The right coronary artery continues in the AV groove and gives off a variable number of branches to the right atrium and right ventricle. The most prominent of these is the right marginal branch which runs down the right margin of the heart supplying this part of the right ventricle. As the right coronary curves posteriorly and descends downward on the posterior surface of the heart, it gives off two to three branches. The AV nodal artery which branches from the right coronary artery at the crux of the heart and passes anteriorly along the base of the atrial septum to supply the AV node (in 50-60 % of hearts), proximal parts of the bundles (branches) of His, and the parts of the posterior interventricular septum that surround the bundle branches.

### **Function:**

The coronary arteries supply blood to the myocardium (heart tissue) itself; that is, coronary capillaries deliver oxygenated blood (nutrients) to all of the heart's cells.

Numerous clinically relevant arterial branches arise from the right coronary artery, including those that supply the conduction system.

### **LEFT MAIN CORONARY ARTERY**

#### **Location:**

The left coronary artery (left main coronary artery) emerges from the aorta through the ostia of the left aortic cusp, within the sinus of Valsalva. The plane of the semilunar valve is tilted so that the ostium of the left coronary artery is superior and posterior to the right coronary ostium. The left coronary artery travels from the aorta, and passes between the pulmonary trunk and the left atrial appendage. Under the appendage, the artery divides (and is thus a very short vessel) into the anterior interventricular (left anterior descending artery) and the left circumflex artery. This bifurcation can often be seen when looking into the left coronary artery ostia with a videoscope. Note that the left coronary artery may be completely absent, i.e., the anterior interventricular and circumflex arteries arise independently from the left aortic sinus.

#### **Function:**

The coronary arteries supply blood to the myocardium (heart tissue) itself; that is, coronary capillaries deliver oxygenated blood (nutrients) to all of the heart's cells. The left coronary artery and its branches supply the majority of oxygenated blood to ventricular myocardium, and additionally to the left atrium, left atrial appendage, pulmonary artery, and aortic root.

### **LEFT ANTERIOR DESCENDING**

#### **Location:**

The left anterior descending (LAD, interventricular) artery appears to be a direct continuation of the left coronary artery which descends into the anterior interventricular groove. Branches of this artery, anterior septal perforating arteries, enter the septal myocardium to supply the anterior two-thirds of the interventricular septum (in ~90% of hearts).

#### **Function:**

In general, the LAD artery and its branches supply most of the interventricular septum; the anterior, lateral, and apical wall of the left ventricle, most of the right and left bundle branches, and the anterior papillary muscle of the bicuspid valve (left ventricle). It also provides collateral circulation to the anterior right ventricle, the posterior part of the interventricular septum, and the posterior descending artery.

## **LEFT CIRCUMFLEX ARTERY**

### **Location:**

The circumflex artery branches off of the left coronary artery and supplies most of the left atrium: the posterior and lateral free walls of the left ventricle, and part of the anterior papillary muscle. The circumflex artery may give off a variable number of left marginal branches to supply the left ventricle. The terminal branch is usually the largest of these branches. More likely, the circumflex artery may continue through the AV sulcus to supply the posterior wall of the left ventricle and (with the right coronary artery) the posterior papillary muscle of the bicuspid valve. The left circumflex branches decrease in diameter along their lengths.

### **Function:**

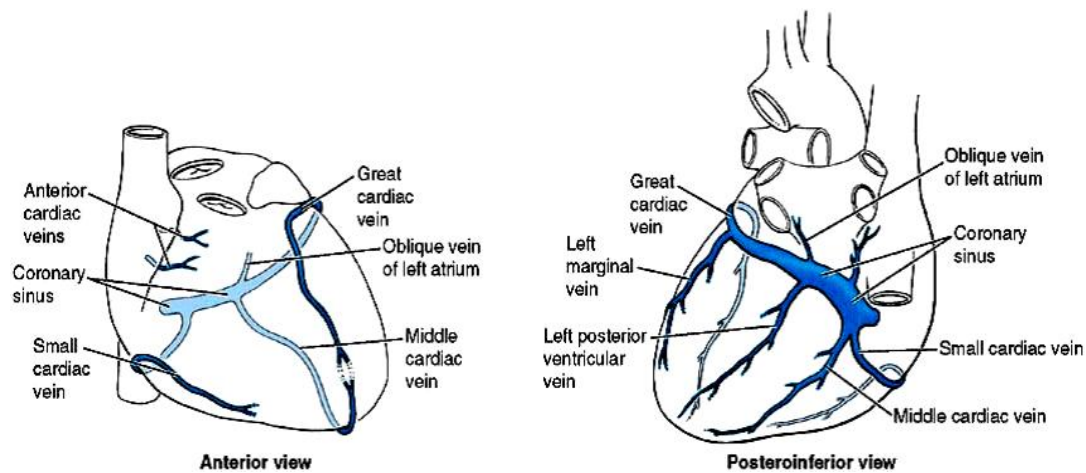
In 40-50% of hearts the circumflex artery supplies the artery to the SA node.

## **CARDIAC DOMINANCE**

In about 10% of hearts, the right coronary artery is rather small and is not able to give the posterior interventricular branch. In these cases the circumflex artery, the continuation of left coronary provides the posterior interventricular branch as well as to the AV node. Such cases are called as left dominant.

Mostly right coronary gives posterior interventricular artery. Such hearts are right dominant. Thus the artery giving the posterior interventricular branch is the dominant artery.

## THE CORONARY VEINS



After flowing through myocardium, most (80%) of the oxygen-depleted blood is returned to the right atrium by several prominent veins that run along the surface of the heart.

**Coronary sinus:** Is the largest vein draining the heart and lies in the coronary sulcus, which separates the atria from the ventricles. Opens into the right atrium between the opening of the IVC and the AV opening. Has a one-cusp valve at the right margin of its aperture.

Receives the great, middle, and small cardiac veins; the oblique vein of the left atrium; and the posterior vein of the left ventricle.

**Great cardiac vein:** Begins at the apex of the heart and ascends along with the IV branch of the left coronary artery. Turns to the left to lie in the coronary sulcus and continues as the coronary sinus.

**Middle cardiac vein:** Begins at the apex of the heart and ascends in the posterior IV groove, accompanying the posterior IV branch of the right coronary artery. Drains into the right end of the coronary sinus.

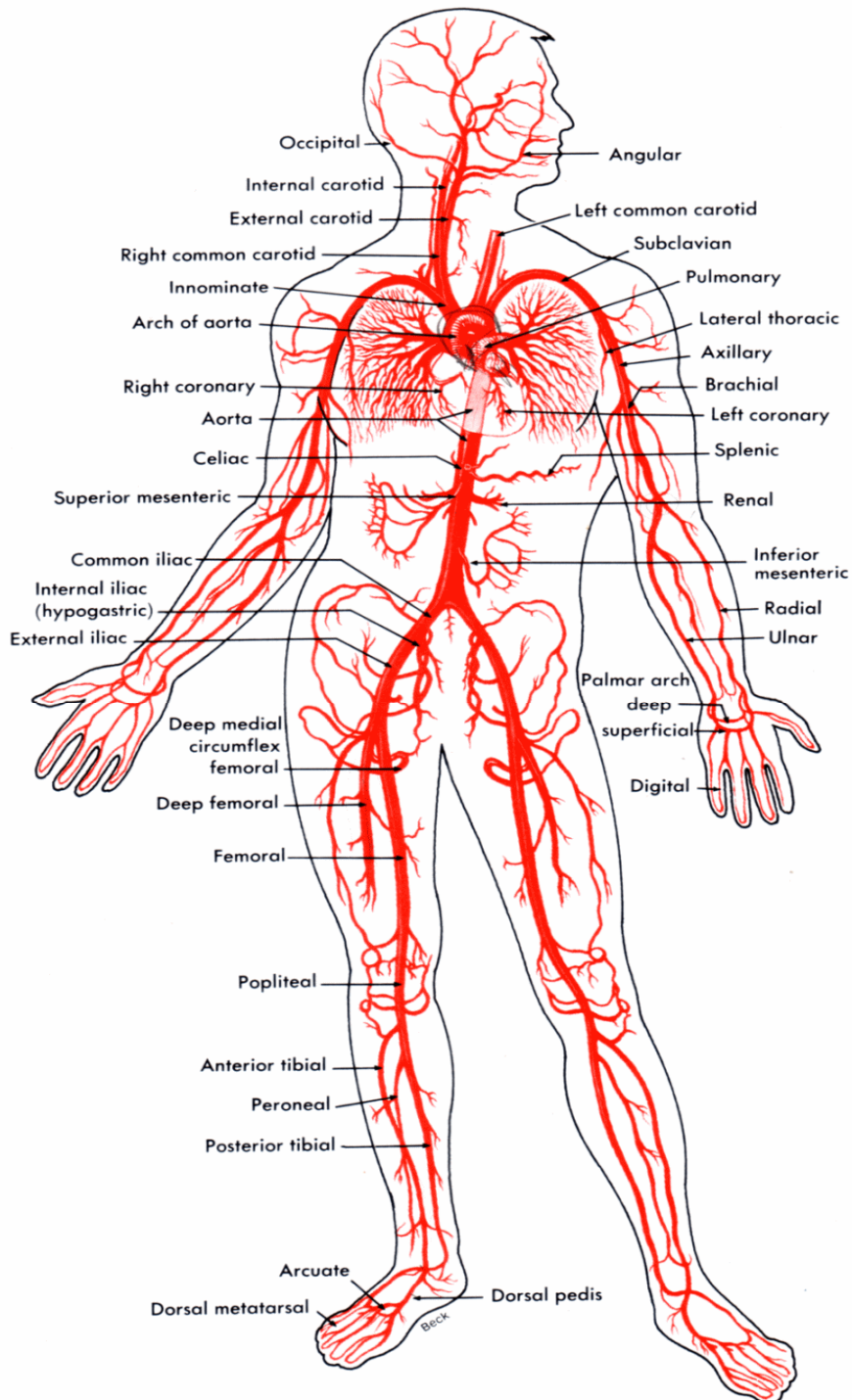
**Small cardiac vein:** Runs along the right margin of the heart in company with the marginal artery and then posteriorly in the coronary sulcus to end in the right end of the coronary sinus.

**Oblique vein of the left atrium:** Descends to empty into the coronary sinus, near its left end.

**Anterior cardiac vein:** Drains the anterior right ventricle, crosses the coronary groove, and ends directly in the right atrium.

**Smallest cardiac veins (venae cordis minimae):** Begin in the wall of the heart and empty directly into its chambers.

## THE ARTERIAL CIRCULATION



The aorta curves upward from the **left ventricle** of the heart as the **ascending aorta**, arches to the left as the **aortic arch**, then drops downward following the spine as the **thoracic aorta** to finally pass through the diaphragm to become the **abdominal aorta**.

The branches of the parts of the aorta are listed below in their sequence from the heart and the organs served.

#### **Branches of the Ascending Aorta:**

- **Right coronary artery** - heart
- **Left coronary artery** - heart

#### **Branches of the Aortic Arch:**

- **Brachiocephalic artery**
  - **Right common carotid artery** - head & neck
  - **Right subclavian artery** - vessel carrying blood beneath the right clavicle.
  - **Posterior auricular:** vessel carrying blood to the ear.
  - **Occipital:** vessel carrying blood to the head.
- **Left common carotid artery**
  - **Left internal carotid** - brain
  - **Left external carotid** - head & neck
- **Left subclavian artery**
  - **vertebral artery** - brain

The subclavian artery becomes the **axillary artery**, then continues into the arm as the **brachial artery** which supplies the arm. At the elbow, the brachial artery splits

- **Radial artery** - forearm
- **Ulnar artery** - forearm

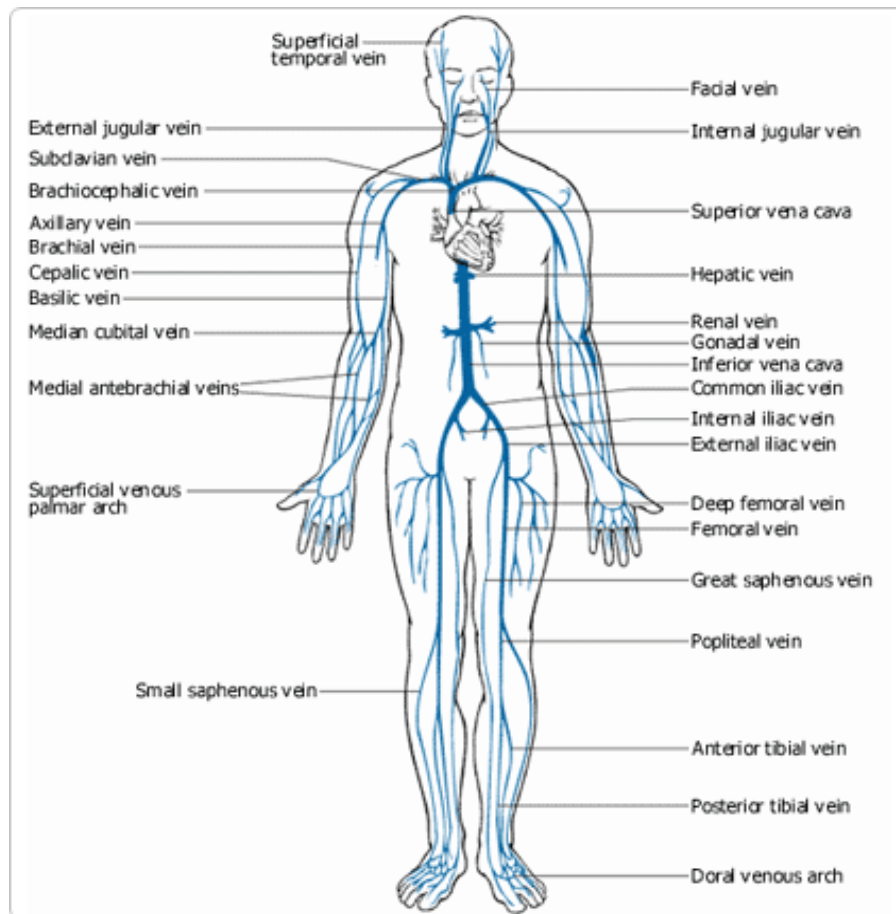
#### **Branches of the Thoracic Aorta:**

- **Intercostal arteries** - 10 pairs supply the muscles of the thorax wall
- **Bronchial arteries** - lungs
- **Esophageal arteries** - esophagus
- **Phrenic arteries** - diaphragm

## Branches of the Abdominal Aorta:

- **Celiac Trunk**
  - **Left gastric artery** - stomach
  - **Splenic artery** - spleen
  - **Common hepatic artery** - liver
- **Superior mesenteric artery** - small intestine
- **Right and Left Renal arteries** - kidneys
- **Right and Left Gonadal arteries** - called **ovarian arteries** in females (serving the ovaries) and **testicular arteries** in males (serving the testes).
- **Lumbar arteries** - several pairs serving the heavy muscles of the abdomen and trunk walls.
- **Inferior mesenteric artery** - lower large intestine
- **Right and Left Common iliac arteries** - the final branches of the abdominal aorta. Each divides into:
  - **Internal iliac artery** - pelvic organs
  - **External iliac artery** - enters the thigh where it becomes the **femoral artery**. The femoral artery and its branch, the **deep femoral artery**, serve the thigh. At the knee, the femoral artery becomes the **popliteal artery**, which then splits into:
    - **Anterior and posterior tibial arteries**, which supply the leg and foot. The anterior tibial artery terminates in the **dorsalis pedis artery**, which supplies the dorsum of the foot.

## THE VENOUS CIRCULATION



Although arteries are generally located in deep, well-protected body areas, many veins are more superficial and some are easily seen and palpated on the body surface. Most deep veins follow the course of the major arteries, and with a few exceptions, the naming of these veins is identical to that of their companion arteries. While major systemic arteries branch off the aorta, the veins converge on the **vena cava**.

Blood returns to the **right atrium** of the heart through the vena cava. Veins draining the head and arms empty into the **superior vena cava** and those draining the lower body empty into the **inferior vena cava**.

The veins listed below begin distally and move proximally to the heart.

### Veins Draining into the Superior Vena Cava:

- **Radial** and **ulnar veins** are deep veins draining the forearm. They unite to form the **brachial vein**, which drains the arm and empties into the **axillary vein**.
- **Cephalic vein** provides superficial drainage of the lateral aspect of the arm and empties into the axillary vein.
- **Basilic vein** provides superficial drainage of the medial aspect of the arm into the brachial vein. The basilic and cephalic veins are joined at the anterior aspect of the elbow by the **median cubital vein**. (This vein is often the site for blood removal for the purpose of blood testing.)
- **Subclavian vein** receives blood from the arm through the axillary vein and from the skin and muscles of the head through the **external jugular vein**.
- **Vertebral vein** drains the posterior part of the head.
- **Internal jugular vein** drains the dural sinuses of the brain.
- **Left & Right Brachiocephalic veins** drain the subclavian, vertebral, and internal jugular veins on their respective sides. The brachiocephalic veins join to form the **superior vena cava**, which enters the heart.
- **Azygos vein** a single vein that drains the thorax and enters the superior vena cava just before it joins the heart.

### Veins Draining into the Inferior Vena Cava:

The inferior vena cava, which is much longer than the superior vena cava, returns blood to the heart from all body regions below the diaphragm.

- **Anterior** and **posterior tibial veins** and the **peroneal vein** drain the calf and foot. The posterior tibial vein becomes the **popliteal vein** at the knee and then the **femoral vein** in the thigh. The femoral vein becomes the **external iliac vein** as it enters the pelvis.
- **Great saphenous veins** are the longest veins in the body. They receive the superficial drainage of the leg. They begin at the **dorsal venous arch** in the foot and travel up the medial aspect of the leg to empty into the femoral vein in the thigh.
- Each **Left & Right common iliac vein** is formed by the union of the **external iliac vein** and the **internal iliac vein** (which drains the pelvis) on its own side. The common iliac veins join to form the **inferior vena cava**, which then ascends superiorly in the abdominal cavity.

- **Right gonadal vein** drains the right male or female sex gland. (The **Left gonadal vein** empties into the left renal vein superiorly.)
- **Left & Right renal veins** drain the kidneys.
- **Left & Right hepatic veins** drain the liver.

## **THE PORTAL CIRCULATION**

1. Blood flow from the abdominal organs that passes through the portal vein, the sinusoids of the liver and into the hepatic vein before returning to the heart from the inferior vena cava. This pathway permits the liver to process and to detoxify substances entering the body from the gastrointestinal tract.

2. A portal system between the hypothalamus and the anterior pituitary gland. The hypothalamus secretes releasing or inhibiting hormones into the blood; they are carried directly to the anterior pituitary and stimulate or inhibit secretion of specific hormones.

## **THE FETAL CIRCULATION**

Oxygenated blood from the placenta enters the fetus through umbilical vein. Most of the newly oxygenated blood bypasses the liver via the ductus venosus and combines with oxygenated blood in the inferior vena cava. Blood then joins deoxygenated blood from the superior vena cava and empties into the right atrium. Since pressure in the right atrium is larger than pressure in the left atrium, most blood will be shunted through the foramen ovale. Some blood does travel from the right atrium to the right ventricle through the pulmonary trunk but most blood bypasses the pulmonary arteries and moves directly to the aorta via the ductus arteriosus. Deoxygenated blood returns to the umbilical arteries originating from the internal iliacs near the bladder.

## **LYMPHATICS OF THE HEART**

The lymphatics of the heart consist of small lymph vessels in the connective tissues of the tunica intima and media, which drain into an extensive epicardial lymphatic plexus. Efferent vessels from the epicardial plexus converge in the cardiac sulci to form right and left cardiac collecting lymph trunks, which run along with branches of the coronary arteries towards the root of the ascending aorta and pulmonary trunk.

## **NERVE SUPPLY OF THE HEART**

The heart is innervated by sympathetic and parasympathetic fibers through the cardiac plexus situated below the arch of aorta. The sympathetic supply arises from the cervical and upper thoracic portions of the sympathetic trunk. The parasympathetic supply comes from the vagus nerve.

Sympathetic fibers, which are postganglionic, terminate on the sinuatrial node, atrioventricular node, cardiac muscle fibers, and coronary arteries. Activation of these nerves causes cardiac acceleration, increased force of contraction and dilation of coronary arteries, all of which are meant to increase blood supply to the body.

The parasympathetic fibers, which are also postganglionic, terminate on sinuatrial node, atrioventricular node and coronary arteries. Cardiac muscle fibers do not receive the parasympathetic nerve fibers. Activation of these nerves cause reduction in rate of heart beats, and constriction of the coronary arteries. The force of contraction is not affected much by the parasympathetic activation.

Afferent fibers from the heart run with the parasympathetic nerves and the vagus nerve. Sensory impulses from the heart are carried in these afferent fibers.

# **CARDIOVASCULAR PHYSIOLOGY**

## **THE CARDIAC CYCLE**

The function of the heart is to maintain a constant circulation of blood throughout the body. The heart acts as a pump and its action consists of a series of events known as the cardiac cycle. During each heartbeat, or cardiac cycle, the heart contracts and then relaxes. The period of contraction is called systole and that of relaxation, diastole. The blood returns from the systemic circulation to the right atrium and flows via the tricuspid valve to the right ventricle. It is ejected from the right ventricle through pulmonary valve to the lungs. Oxygenated blood returns from the lungs to the left atrium, and flows via the mitral valve to the left ventricle. Finally blood is pumped through the aortic valve to the aorta and the systemic circulation.

When the ventricles contract, the atrioventricular valves closes, this will prevent the back flow of blood from the ventricles to the atria. The papillary muscles are shortened and so that they pull chordae tendinae and this prevent the inversion of the valves into the atria. As a result, there is increase in the blood pressure in the ventricles. As soon as the pressure inside the ventricles exceeds that in the pulmonary artery and aorta, the valves guarding the arterial orifices open and blood is driven from the ventricles into the arteries.

After this contraction phase the ventricles relax. The semilunar valves prevent the regurgitation of blood from the arteries to the ventricles. With each contraction the cardiac muscle squeezes blood from the heart into pulmonary or systemic circulation. The blood flows from an area of high pressure to low pressure area. The changing of blood pressure inside each chamber acts to open and close the heart valves as blood moves through the heart's chambers and into the circulation.

### **Stages of the cardiac cycle**

The normal number of cardiac cycles per minute ranges from 60 to 80. Taking 74 as an example each cycle lasts about 0.8 of a second and consists of:

- atrial systole — contraction
- ventricular systole — contraction of the ventricles
- complete cardiac diastole — relaxation of the atria and ventricles.

Systole:

Phase 1: Atrial contraction

Phase 2: Isovolumetric contraction

Interval between ventricular systole and semilunar valve opening  
 Phases 3 and 4: Rapid and Reduced ejection.

Diastole :

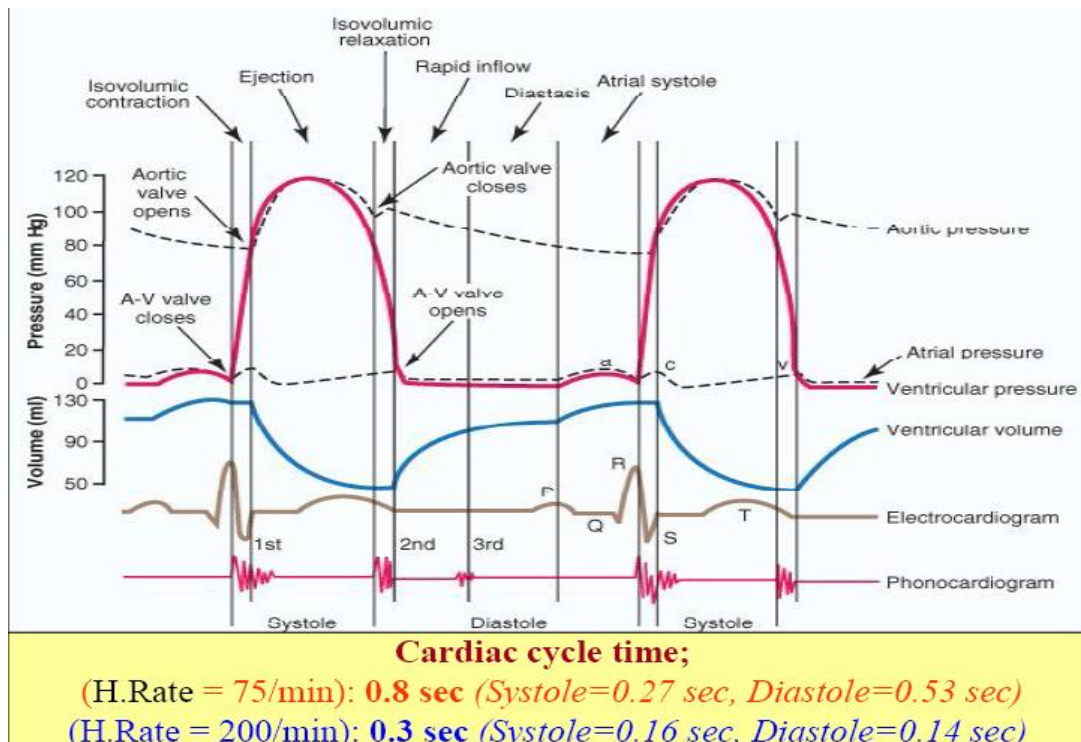
Phase 5: Isovolumetric relaxation

    Begins with closure of the semilunar valves

Phase 6: Rapid filling

    Opening of the AV valves

Phase 7: Reduced filling



## ATRIAL SYSTOLE (Phase 1)

Atrial systole occurs at the same time as ventricular diastole. It is initiated by the p wave of the electrocardiogram, which represents electrical depolarisation of the atria. Atrial depolarisation initiates contraction of the atrial musculature. It begins when atrium contracts. Just before the atrial contraction, the atrium is full of blood and the ventricle is partially full. The blood pressure inside each chamber is relatively low, but the atrial pressure is somewhat higher than ventricular pressure, ensuring that AV valve remains open. As the atrium contracts, the atrial pressure rise; then lowers as blood flow from atrium the ventricle. Ventricular pressure rises somewhat when it fills with blood, but not enough to exceed the pressure outside in the aorta. Therefore, during atrial systole, the aortic valve remains closed.

## **VENTRICULAR SYSTOLE**

Ventricular systole occurs in three phases: Isovolumetric contraction, rapid ejection and reduced ejection.

### **ISOVLUMETRIC CONTRACTION (Phase 2)**

This phase of the cardiac cycle begins with the appearance of the QRS complex of the ECG, which represents ventricular depolarisation. The ventricle begins to contract and ventricular blood pressure rises rapidly. When ventricular pressure exceeds atrial pressure, AV valve closes. As the ventricle continues to contract, ventricular pressure rises, but it is not yet greater than the pressure outside the aortic valve, so the aortic valve remains closed. During this phase the ventricle is, for a moment, a closed chamber that contains an unchanging volume of blood. Duration of isovolumetric contraction is 0.05 second.

### **RAPID EJECTION (Phase 3)**

When the ventricular pressure exceeds the blood pressure outside the aortic valve, the aortic valve opens. Blood is quickly and forcefully ejected into the aorta. This greatly decreases the volume of the ventricle and increases the blood flow and pressure in the aorta. The pressure in the aorta and ventricle quickly equalize and reach a peak. The duration of this period is 0.09 second.

### **REDUCED EJECTION (Phase 4)**

Near the end of the ventricular systole, muscle fibres contract less forcefully because they are no longer stretched by a large volume. The ventricle continues to empty, but at a slow rate. When the ventricle begins to relax, ventricular pressure declines quickly. Blood pumped into the aorta remains under pressure, the aortic valve closes. The closing of the aortic valve marks the end of the ventricular systole and the onset of the ventricular diastole. Duration is 0.13s.

## **VENTRICULAR DIASTOLE**

Ventricular diastole is the period during which the ventricle relaxes and fills with blood. It occurs in three phases: isovolumetric relaxation, rapid filling and reduce filling.

## **ISOVOLUMETRIC RELAXATION (Phase 5)**

After the aortic valve closes, ventricular pressure decreases rapidly as the walls of the ventricle relax. The blood pressure has not yet dropped far enough to open the AV valve, so for the ventricle is a closed chamber with an unchanged volume of blood. The duration of isovolumetric relaxation period is 0.12s.

## **RAPID FILLING (Phase 6)**

When ventricular pressure drops below atrial pressure, the AV valve opens and blood flows quickly from the atrium to the ventricle. Because blood is flowing passively, atrial pressure drops. Though the inflow of blood causes a slight increase in ventricular pressure, ventricular pressure continues to drop as the ventricles continue to relax. When the atrial and ventricular pressure begins to equalize, blood flow decreases. Duration is 0.11s.

## **REDUCED FILLING (Phase 7)**

Most of the blood that had accumulated in the atrium flow into the ventricle during the rapid filling. Blood continues to flow during the reduced filling phase, although relatively little enters the ventricle. The pressure inside both chambers remains constant. At the end of the reduced filling, both the atrium and ventricles are relatively full and the AV valve remains open. Duration of this phase is 0.19s.

## **CARDIAC OUTPUT**

Cardiac output (CO) is the volume of blood pumped out by the heart in one minute. It is measured in litres per minute. On an average, a woman's heart pumps 4l/min and a man's heart pumps 5l/min. In an average lifetime, a human heart pumps 150 to 200 million litres of blood. Cardiac output is the product of two relatively independent factors, heart rate and stroke volume.

$$\text{Cardiac output} = \text{Stroke volume} \times \text{Heart rate}$$

The cardiac output is primarily measured using Fick principle. In 1870, Aldoph Fick described the first method to estimate cardiac output in humans. He postulated the oxygen uptake in the lungs is entirely transferred to the blood and therefore that cardiac output can be calculated knowing oxygen consumption of the

body and the difference in oxygen content between in atrial and mixed venous blood.

**Cardiac output = O<sub>2</sub>consumption (ml/min) /**

**AVO<sub>2</sub> difference (ml O<sub>2</sub>/100ml blood) \* 10**

Another method is indicator dilution technique (thermodilution using a PA catheter). This technique is based on the principle that a single injection of a known amount of an indicator injected into the central circulation mixes completely with blood and changes concentration as it flows to a more distal location. The change in the indicator concentration is plotted over time, the area under the curve is used to calculate CO.

## **HEART RATE**

Heart rate (HR) is the number of time the heart beats per minute. The average heart rate for an adult at rest is 70 per minute (bpm). A healthy individuals heart rate can increase as much as three times normal rate, when the body requires greater cardiac output.

## **STROKE VOLUME (SV)**

Stroke volume is the amount of blood pumped by one ventricle per contraction. The average stroke volume is 75ml per contraction. Stroke volume also increases in response to metabolic demand.

Heart rate and stroke volume are the dynamic factors in the changing relationships between the blood supply and metabolic demand.

The volume of blood contained in the ventricles before the contraction is called end-diastolic volume (EDV). The volume of blood contained in the ventricles after the contraction is end-systolic volume. The stroke volume is expressed by,

Stroke volume = End-diastolic volume- End-systolic volume

Normal values range from 75 to 133ml for EDV and from 20 to 50ml for ESV

The factors that determine stroke volume are:

- Preload
- Afterload
- Contractility

## **PRELOAD**

Preload is another way of expressing EDV. Therefore, the greater the EDV, the greater the preload. A main factor is ventricular filling time. The faster the contractions are, the shorter the filling time and both the EDV and preload are lower.

The relationship between ventricular stretch and contraction has been stated in the Frank-Starling mechanism which says that the force of contraction is directly proportional to the initial length of muscle fibre. So that the greater the stretch of the ventricle the greater the contraction. Any sympathetic stimulation to the venous system will increase venous return to the heart and ventricular filling.

## **AFTERLOAD**

The ventricles must develop a certain tension to pump blood against a resistance of the vascular system. This tension is called afterload. The thick walled arteries keep blood flowing under fairly high pressure. A ventricular contraction must therefore be strong enough to overcome arterial pressure and force the aortic valve open. The higher the arterial pressure, the stronger a ventricular contraction must be to open the aortic valve.

## **CONTRACTILITY**

The ability of the myocardium to contract, (its contractility), controls the stroke volume which determines the end systolic volume. The greater contraction the greater the stroke volume and the smaller the end systolic volume. Higher the cardiac output, a longer filling time between contraction and less resistance to filling during diastole. Oxygen availability to the myocardium affects contractility therefore the heart strength decreases if there is not enough oxygen to meet the metabolic needs to the myocardial tissue.

## **HEART SOUNDS AND MURMERS**

One of the simplest methods of assessing the heart's condition is to listen to it using a stethoscope. In a healthy heart, there are only two audible heart sounds, called S1 and S2. The first heart sound S1, is the sound created by the closing of the atrioventricular valves during ventricular contraction and is normally described as "lub". The second heart sound, S2, is the sound of the semilunar valves closing during ventricular diastole and is described as "dub". Each sound consists of two components, reflecting the slight difference in time as the two valves close. S2 may split into two distinct sounds, either as a result of inspiration or different valvular or

cardiac problems. Additional heart sounds may also be present and these give rise to gallop rhythms. A third heart sound, S3 usually indicates an increase in ventricular blood volume. A fourth heart sound S4 is referred to as an atrial gallop and is produced by the sound of blood being forced into a stiff ventricle. The combined presence of S3 and S4 give a quadruple gallop.

Heart murmurs are generated by turbulent flow of blood, which may occur inside or outside the heart. Murmurs may be physiological (benign) or pathological (abnormal). Abnormal murmurs can be caused by stenosis restricting the opening of a heart valve, resulting in turbulence as blood flows through it. Abnormal murmurs may also occur with valvular insufficiency (regurgitation), which allows backflow of blood when the incompetent valve closes with only partial effectiveness. Different murmurs are audible in different parts of the cardiac cycle, depending on the cause of the murmur.

## **THE CONDUCTION SYSTEM OF THE HEART**

The cardiac cycle is regulated by specialized areas in the heart wall that forms the conduction system of the heart. Two of these areas are tissue mass called nodes; the third is a group of fibers called the atrioventricular bundle. The sinoatrial node, which is located in the upper wall of the right atrium and initiates the heart beat, is called the pacemaker. The second node, located in the interatrial septum at the bottom of the right atrium, is called the atrioventricular node. The atrioventricular bundle, also known as the bundle of His, is located at the top of the interventricular septum; it has branches that extend to all parts of the ventricle walls. Fibers travel first down both sides of the interventricular septum in groups called the right and left bundle branches. Smaller Purkinje fibers then travel in a branching network throughout the myocardium of the ventricles.

The order in which the impulses travel is as follows:

- The sinoatrial node generates the electric impulse that begins the heart beat.
- The excitation wave travels throughout the muscle of each atrium, causing it to contract.
- The atrioventricular node is stimulated. The relatively slower conduction through this node allows time for the atria to contract and completes the filling of the ventricles.
- The excitation wave travels rapidly through the Bundle of His and then throughout the ventricular walls by means of the bundle branches and Purkinje fibers.

## CELLULAR PHYSIOLOGY TERMINOLOGY

**Vector** - Symbolic representation of physical force.

**Electric Tension** - Latent energy resulting from the collection of (+) and (-) ions.

**Resting Membrane Potential** – (polarized state) in a polarized cell there are an equal number of (=) and (-) chargers. Normal resting membrane potential is -85mv to -95mv.

**Depolarization** - is when the polarized state has been interrupted by a stimulus, the result is that Na<sup>+</sup> ions rush inside the cell and some K<sup>+</sup> leaves the cell, and the cell's polarity changes.

**Repolarization** - is the state where the cell returns to its polarized state and the polarity reverses.

**Action potential** - the rapid sequence of depolarization and repolarization.

**Selective Permeability** - with all living cells, the membrane passes some substance but blocks others.

**Sodium pump** - a metabolic pump that pumps Na<sup>+</sup> out of a cell, and pumps K<sup>+</sup> to cell's interior, this occurs only in diastole.

### Cellular Activity

#### **Resting Cell**

Has equal number of (+) and (-) charges.

Repolarized.

Example:

		+	+	+		
		-	-	-		
+	-				-	+
			K <sup>+</sup>			
+	-				-	+
		-	-	-		
		+	+	+		

## Depolarized Cell

Exchange of Na<sup>+</sup> and K<sup>+</sup> and polarity reverses



Uniqueness of Pacemaker Cell vs. Non-Pacemaker Cell

SA Node

Pacemaker cells have one phase of action potential. The reason is because of a time-dependent decay in K<sup>+</sup> conductance. This, plus passive diffusion of Na<sup>+</sup> back into the cell, causes a threshold to be reached. (Constant Na<sup>+</sup> leakage, and constant K<sup>+</sup> moving) All action is self-initiated.

Phases of Action Potential:

Phase 0

This is the portion from the threshold to peak action potential (i.e. the exchange of Na<sup>+</sup> and K<sup>+</sup> in the cells).

Phase 1

Initiate stage of repolarization, it has a brief origin (initial phase due to influx of Cl<sup>-</sup> ion).

Phase 2

During the next 0.1 second, the repolarization process slows. This period does not exist in skeletal muscle. This allows cardiac muscle to have a more sustained contraction (isometric contraction; plateau phase).

Phase 3

Sudden acceleration of the rate of repolarization as K<sup>+</sup> leaves the cell in response to the influx of Na<sup>+</sup>.

Phase 4

This represents the resting potential.

## **PRESSURE WAVES IN THE HEART**

Hemodynamics is the study of the dynamic behavior of blood. As blood flows from chamber to chamber, as valves open and close, and as the myocardium contracts and relaxes, pressures are generated in various parts of the heart. These cardiovascular pressures can be measured and monitored through catheters whose tips are placed in the atria, pulmonary artery or systemic arteries

## **PRESSURE MEASURING DEVICES**

### **SENSITIVITY**

The sensitivity of a measurement system is defined as the ratio of the amplitude of the recorded signal to the amplitude of the input signal. The more rapid the sensing membrane, the lower the sensitivity; conversely, the more flaccid the membrane. This general principle applies to manometers currently in use.

### **FREQUENCY RESPONSE**

A second crucial property of any pressure measurement is its frequency response. The frequency response of a pressure measurement is defined as the ratio of output amplitude to input amplitude over a range of frequencies of the input pressure wave. Frequency response of a catheter system is dependent on catheter's natural frequency and amount of damping. The higher the natural frequency of the system, the more accurate the pressure measurement at lower physiologic frequencies.

### **NATURAL FREQUENCY AND DAMPING**

A third important concept is the natural frequency of a sensing membrane. Natural frequency is the frequency at which fluid oscillates in a catheter when it is tapped. Frequency of an input pressure wave at which the ratio of output/input amplitude of an undamaged system is maximal.

Damping is the dissipation of the energy of oscillation of a pressure measurement system, due to friction.

## **STRAIN-GAUGE TRANSDUCER**

Pressure measurement system today generally use electrical strain gauges based on the principle of the Wheatstone bridge. The strain gauge is a variable resistance transducer whose operation depends on the fact that when an electrical wire is stretched, its resistance to the flow of current increases. As long as the strain remains well below the elastic limit of the wire, there is a wide range within which the resistance is accurately proportional to the increase in length.

Strain-gauge pressure transducer increased pressure on diaphragm stretches, and increases resistance of G1 & G3 wires, while relaxing G2 & G4 wires. Voltage is applied across the wires and unbalanced resistance leads to current flow across Wheatstone bridge. The Wheatstone bridge uses this principle in converting a pressure signal to an electrical signal.

## **TRANSDUCER/MONITOR ZERO AND CALIBRATION**

Set-up of the transducer and monitor should be performed 15 to 20 minutes in advance to allow a sufficient warm-up period for stabilization. All transducers are affected by temperature changes, resulting in some drift to the zero baselines. Zero drift may occur within the monitor itself. For these reasons, rezeroing should be performed before infrequent or critical measurement readings, if there is a discrepancy between readings, whenever there is a change in transducer level or a large environmental temperature shift, or at least every 4 hours. This is true for both disposable and reusable transducers.

- Position the air-reference stopcock at the patient's midchest level or at the phlebostatic axis. The transducer may be placed on an IV pole, on an arm board next to the patient or directly on the patient's chest or arm.
- Remove the dead-ender cap and open the side arm of the air-reference stopcock.
- Select the appropriate scale on the monitor to correspond to the anticipated pressure range.
- Turn or press zero control knob on the monitor to obtain zero reading
- Adjust the tracing on the oscilloscope to the correct zero position.
- Press and hold the calibration knob on the monitor to read the precalibrated value.
- While depressing the calibration knob, adjust the tracing on the oscilloscope to the appropriate scale position.
- Close the air reference stopcock on the transducer dome and replace the dead-ender cap.

## **TRANSDUCER CALIBRATION**

To be assured of obtaining accurate pressure measurements calibration of the transducer is important. Attach a disposable dome to the transducer then press zero control knobs on the monitor. Attach a mercury manometer to one of the luer-lock fittings of the transducer dome, using short plastic tubing. Attach a hand bulb to the second luer-lock fitting on the transducer dome. Squeeze the hand bulb to 200mmHg and hold it. The digital readout should display 200mmHg and release the hand bulb and check for a return of the digital readout to zero. Repeat this at low pressures levels also. Remove the calibrating equipment and dome and attach the patient's dome to the transducer.

Blood pressure is the force or pressure which the blood exerts on the walls of the blood vessels. The systemic arterial blood pressure, usually called simply arterial blood pressure, is the result of the discharge of blood from the left ventricle into the already full aorta. When the left ventricle contracts and pushes blood into the aorta the pressure produced within the arterial system is called the systolic blood pressure. In adults it is about 120 mmHg (millimetres of mercury) or 16 kPa (kilopascals). When complete cardiac diastole occurs and the heart is resting following the ejection of blood, the pressure within the arteries is called diastolic blood pressure. In an adult this is about 80 mmHg or 11 kPa. The difference between systolic and diastolic blood pressures is the pulse pressure. Arterial blood pressure is measured with a sphygmomanometer and is usually expressed in the following manner:

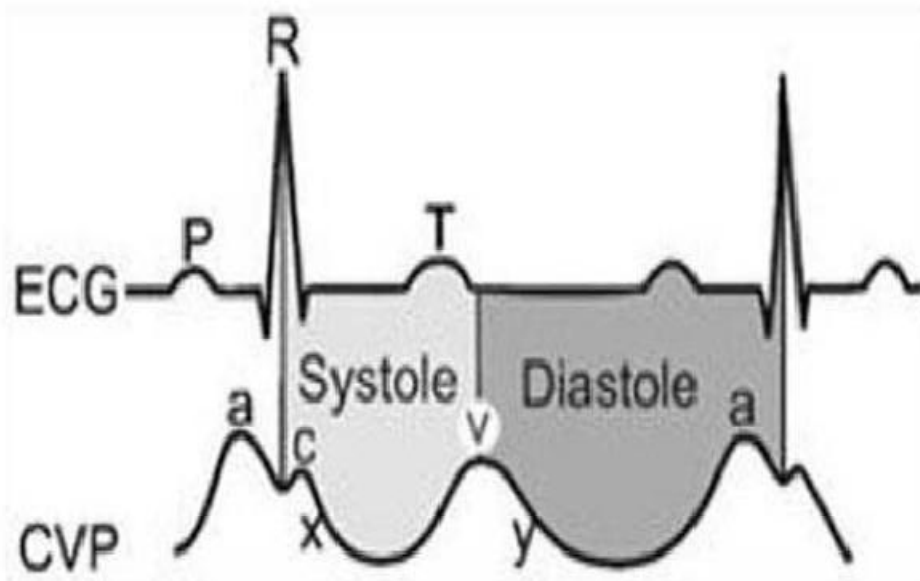
$$\text{BP} = 122 \text{ mmHg or BP}$$

The blood pressure is maintained within normal limits by fine adjustments. Blood pressure is determined by cardiac output and peripheral resistance.

$$\text{Blood pressure} = \text{cardiac output} * \text{peripheral resistance}$$

**Central venous pressure (CVP)**, also known as **mean venous pressure (MVP)** is the pressure of blood in the thoracic vena cava, near the right atrium of the heart. CVP reflects the amount of blood returning to the heart and the ability of the heart to pump the blood into the arterial system. CVP is often a good approximation of right atrial pressure (RAP), however the two terms are not identical, as right atrial pressure is the pressure in the right atrium. CVP and RAP can differ when arterial tone is altered. This can be graphically depicted as changes in the slope of the venous

return plotted against right atrial pressure (where central venous pressure increases, but right atrial pressure stays the same;  $VR = CVP - RAP$ ).



Direct measurement of arterial blood pressure is obtained via a peripheral artery catheter that is connected to a transducer and is a continuous display/recording device or monitor. Intra-arterial or direct blood pressure provides a continuous display of the arterial waveform along with measurements of mean arterial pressure, systolic and diastolic pressure.

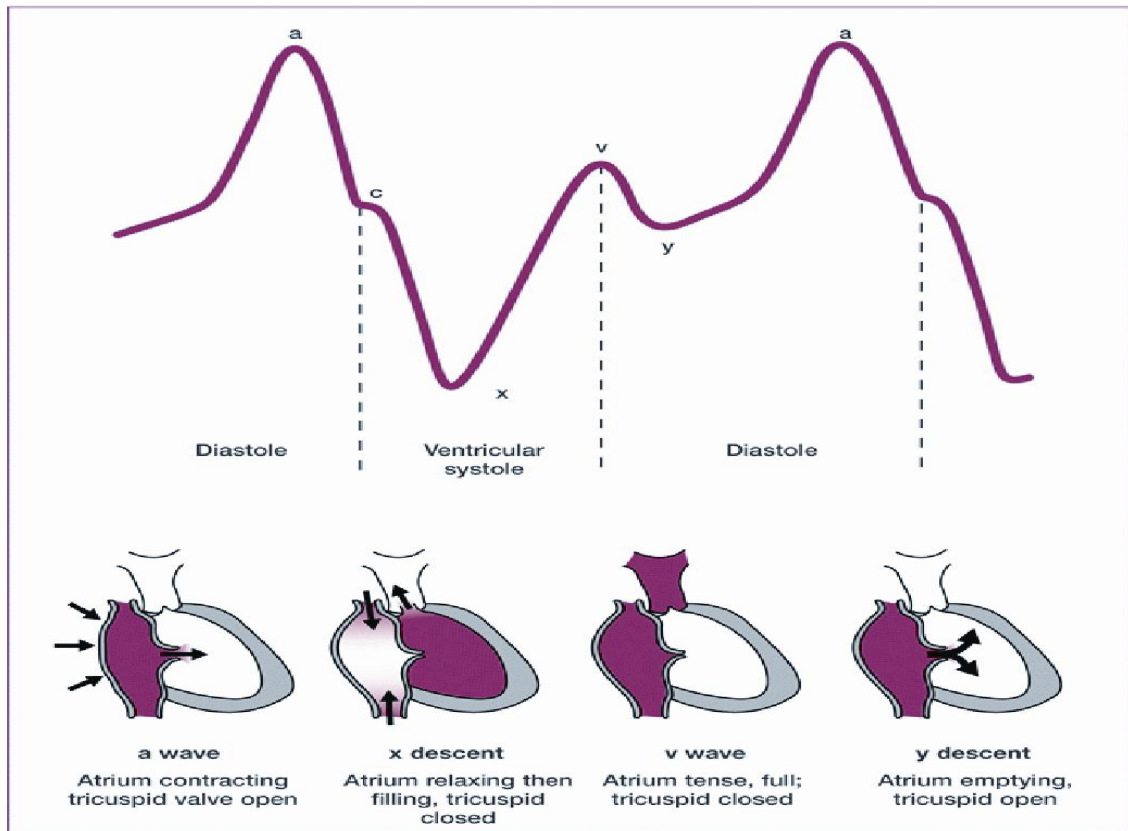
Indications for the use of direct arterial blood pressure monitoring include shock, critical illness, peripheral vasoconstriction, and intra-operative and post-operative monitoring of high-risk patients. In addition, arterial catheters allow for frequent monitoring of blood gas measurements.

## **RIGHT ATRIAL PRESSURE**

The right atrial pressure waveform normally has three positive waves, an “a” wave a “c” wave and a “v” wave, followed by the x, x’ and y descent. Normal RA pressure is 2 t 6 mmHg.

- a wave - Atrial systole
- c wave - Protusion of TV into RA
- x descent - Relaxation of RA
- - Downward pulling of tricuspid annulus by RV contraction
- v wave - RV contraction
- - Height related to atrial compliance and amount of blood return

- Smaller than a wave
- Y descent - TV opening and RA emptying into RV



## RIGHT VENTRICULAR PRESSURE

The RV waveform consists of systolic and diastolic phases. In the absence of outflow obstruction, the peak systolic pressure is normally the same as the PA systolic pressure, whereas the diastolic pressure falls to zero (+\_5mm hg)

- Systole – Isovolumetric contraction  
From TV closure to PV opening
- Ejection  
From PV opening to PV closure
- Diastole – Isovolumetric relaxation  
From PV closure to TV opening
- Filling  
From TV opening to TV closure  
Early rapid phase  
Slow phase  
Atrial contraction (a wave)

### Normal RV pressure

Systolic pressure : 20 to 30 mm Hg

Diastolic pressure : 0 to 5 mm Hg

End-diastolic pressure : 2 to 6 mm Hg

### PULMONARY ARTERY PRESSURE

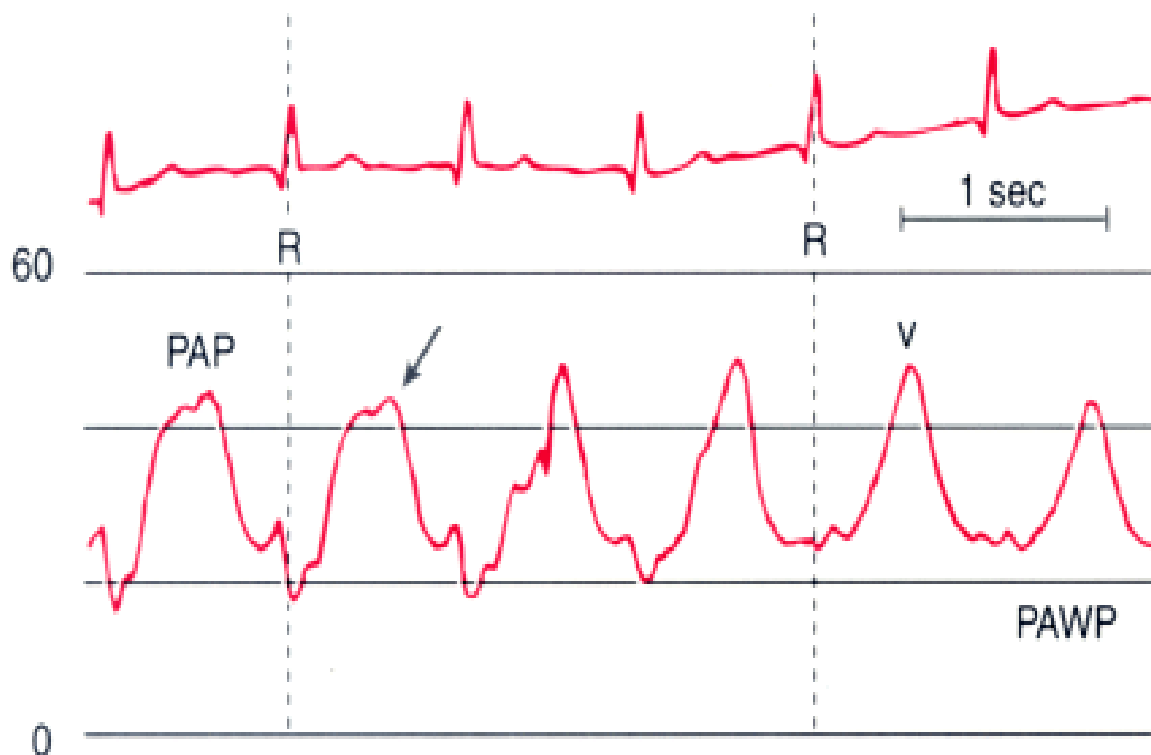
The PA waveform is the right sided circulation arterial pressure waveform and is comparable to the arterial waveform, consisting of systole, the dicrotic notch and diastole. Pressure readings obtained are usually the peak systolic, end-diastolic, and mean pressures.

### Normal PA pressure

Systolic pressure : 20 to 30 mm Hg

Diastolic pressure : 8 to 12 mm Hg

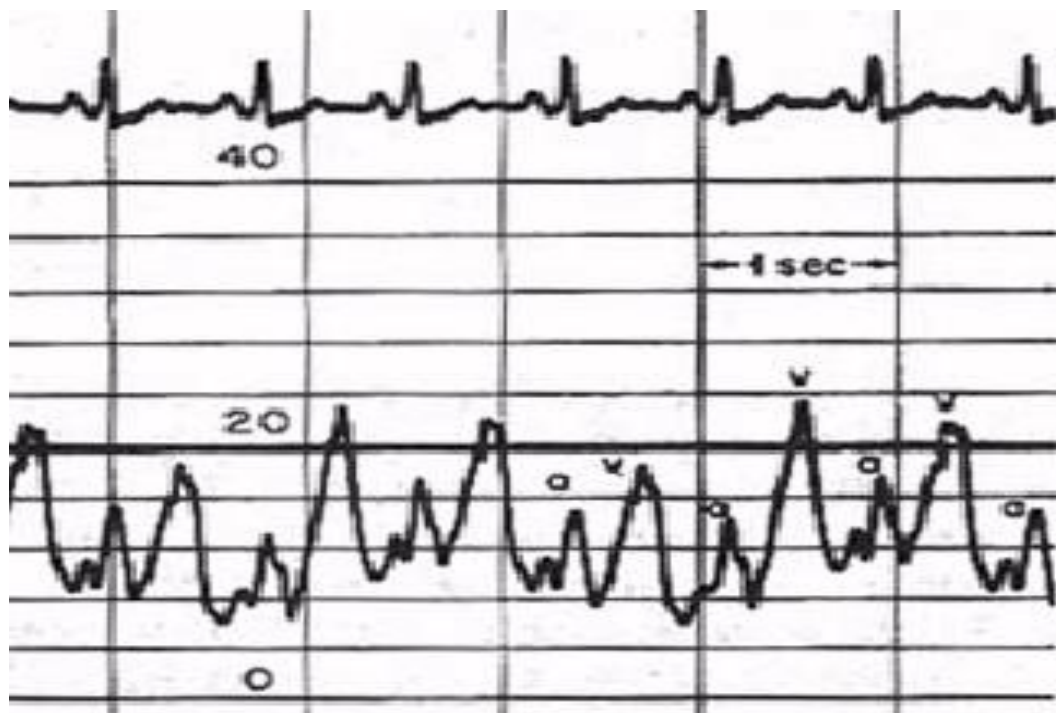
End-diastolic pressure : 10 to 20 mm Hg



## PULMONARY ARTERIAL WEDGE PRESSURE

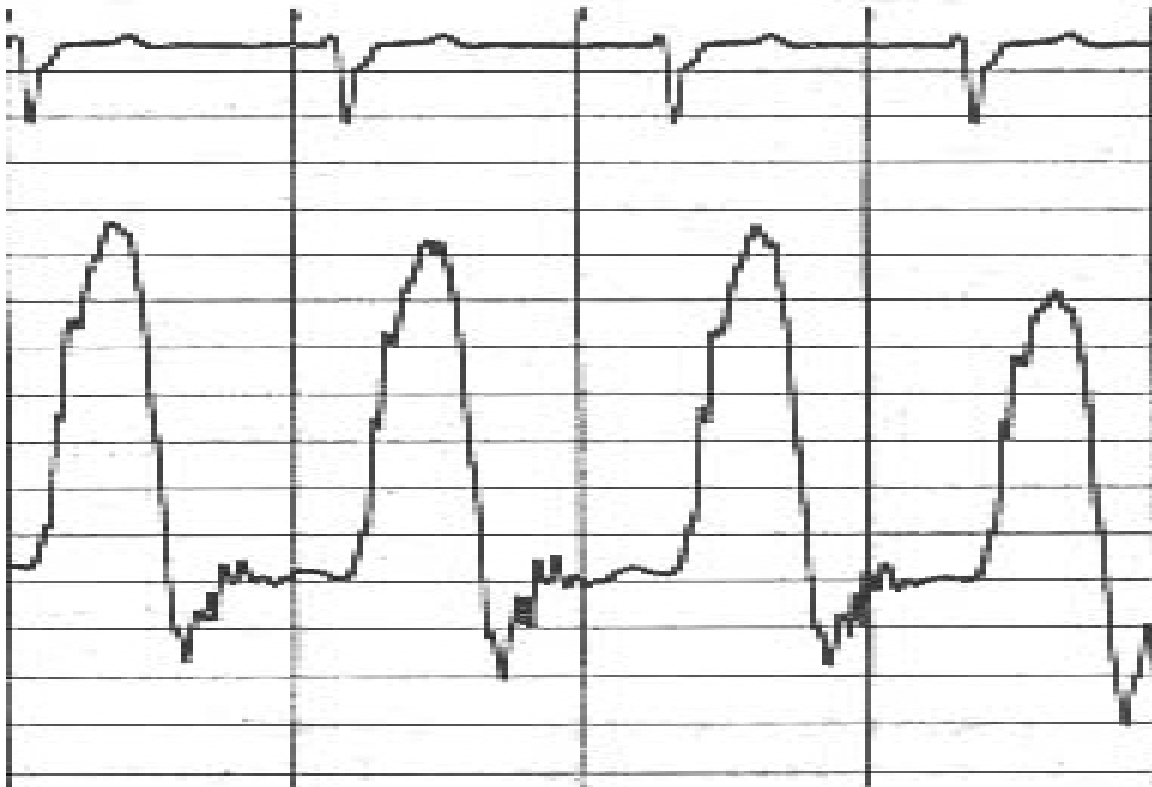
The PAWP is obtained during balloon inflation, which occludes PA branch and interrupts forward blood flow. Thus the tip of the catheter only measures that pressure distal to it, generated retrograde by the left atrium (LA). Therefore the PAWP reflects LA pressure and morphologically identical to the RA pressure waveform, consisting of an "a" wave, a "v" wave and occasionally a "c" wave. The "a" wave is absent in patients with atrial fibrillation

- "a" wave
  - Atrial systole
- "c" wave
  - Protrusion of MV into LA
- "x" descent
  - Relaxation of LA
  - Downward pulling of mitral annulus by LV contraction
- "v" wave
  - LV contraction
  - Height related to atrial compliance & amount of blood return
  - Higher than a wave
- "y" descent
  - MV opening and LA emptying into LV



## LEFT VENTRICULAR PRESSURE

- Systole
  - Isovolumetric contraction
    - From MV closure to AoV opening
  - Ejection
    - From AoV opening to AoV closure
- Diastole
  - Isovolumetric relaxation
    - From AoV closure to MV opening
  - Filling
    - From MV opening to MV closure
    - Early Rapid Phase
    - Slow Phase
    - Atrial Contraction (“a” wave”)



## SHUNT DETECTION AND QUANTIFICATION

Detection, localization and quantification of intracardiac shunts are an integral part of the hemodynamic evaluation of patients with congenital heart diseases.

$Q_p$  = Pulmonary blood flow

$Q_s$  = Systemic blood flow

$Q_{EP}$  = Effective pulmonary blood flow

$Q_{ES}$  = Effective systemic blood flow

PVR = Pulmonary vascular resistance

SVR = Systemic vascular resistance

PVRI = Pulmonary vascular resistance index

SVRI = Systemic vascular resistance

Cardiac output

$$= VO_2 \div [13.6 \times Hb \times (O_2 \text{ CONTENT OF AO} - O_2 \text{ CONTENT OF PA (IN DECIMAL))}]$$

13.6 – O<sub>2</sub> carrying capacity of a gram of Hb

VO<sub>2</sub> – Oxygen consumption

Hb – g/lit

$$BSA = \sqrt{[WEIGHT(KG) \times HEIGHT(CM)]} \div 3600$$

$$QP = [VO_2] \div [13.6 \times Hb \times (PV - PA)]$$

$$QS = [VO_2] \div [13.6 \times Hb \times (AO - MV)]$$

$$QEP = [VO_2] \div [13.6 \times Hb \times (PV - MV)]$$

$$QEP = QP - (\text{L-R SHUNT})$$

$$\text{L-R SHUNT} = QP - QEP$$

$$QEP=QES$$

$$PVR=[PA (P)-PCW(P)]\div[QP]$$

$$SVR=[AO(P)-RA(P)]\div[QS]$$

$$PVRI=PVR\times BSA$$

$$SVRI=SVR\times BSA$$

$$\text{O2 CONTENT OF AO}=[\text{Hb}\times 13.6\times \text{O2 SATURATION OF AO}]+[0.03\times \text{PO2}]$$

$$\text{O2 CONTENT OF PA}=[\text{Hb}\times 13.6\times \text{O2 SATURATION OF PA}]+[0.03\times \text{PO2}]$$

$$\text{O2 CONTENT OF PV}=[\text{Hb}\times 13.6\times \text{O2 SATURATION OF PV}]+[0.03\times \text{PO2}]$$

$$\text{O2 CONTENT OF SVC}=[\text{Hb}\times 13.6\times \text{O2 SATURATION OF SVC}]+[0.03\times \text{PO2}]$$

$$\text{O2 CONTENT OF IVC}=[\text{Hb}\times 13.6\times \text{O2 SATURATION OF IVC}]+[0.03\times \text{PO2}]$$

$$QP=[\text{VO2}]\div[\text{PV O2 CONTENT}-\text{PA O2 CONTENT}]$$

$$QS=[\text{VO2}]\div[\text{AO O2 CONTENT}-\text{MV O2 CONTENT}]$$

# **CARDIAC PATHOLOGY**

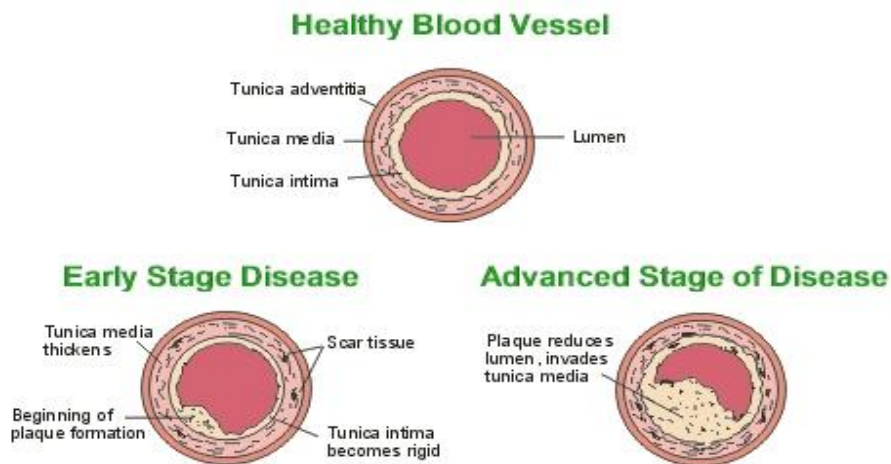
## **PATTERNS AND CLASSIFICATION OF HEART DISEASES**

For the purpose of pathologic discussion of heart disease, they are categorised on the basis of anatomic region involved and the functional impairment. Accordingly, topics on heart diseases are discussed here under the following headings:

### **CORONARY ARTERY DISEASE**

Coronary artery disease is a type of blood vessel disorder that is included in the general category of atherosclerosis. The term atherosclerosis is derived from two Greek words: ather meaning “fatty mush,” and skelros, meaning “hard.” This combination indicates that atherosclerosis begins as soft deposits of fat that harden with age. Atherosclerosis is often referred to as “hardening of the arteries.” Although this condition can occur in any artery in the body, the atheromas (fatty deposits) have a preference for the coronary arteries. Arteriosclerotic heart disease, cardiovascular heart disease, ischemic heart disease, coronary heart disease, and CAD are all terms used to describe this disease process.

#### **Pathophysiology of coronary artery disease:**



Coronary artery disease is usually caused by a build up cholesterol rich deposits or plaques on the lining inside the artery. These plaques are also called atheromatous plaques or simply atheromas and they cause a thickening of the arterial wall and a narrowing of the arterial space through which blood flows to reach the heart. The amount of blood reaching and supplying the heart muscles (myocardium) with oxygen and nutrients can therefore be reduced in the presence of atheromas.

An atheroma usually starts to develop as a result of damage or injury to the inner lining of the artery called the endothelium. Once the endothelium is damaged, cholesterol, fats, lipoproteins and other debris start to accumulate at the site of injury in the wall or intima of the artery.

High concentrations of low density lipoprotein (LDL) penetrate the damaged endothelium and undergo a chemical process called oxidation. This altered LDL acts as a beacon that attracts white blood cells or leukocytes to migrate towards the vessel wall. As macrophages appear, they engulf the lipoproteins and become foam cells. These foam cells give rise to the earliest visible form of an atheromatous lesion called the fatty streak.

Once the fatty streak is formed, it then attracts the smooth muscle cells to the site, where they multiply and start to produce extracellular matrix comprising of collagen and proteoglycan. It is this extracellular matrix that forms a large portion of the atherosclerotic plaque. This turns the fatty streak into a fibrous plaque. The lesion then starts to bulge into the inner wall of the blood vessel causing a significant narrowing of the luminal space.

Next, the fibrous plaque starts to support itself. It develops its own small vessels to provide it with a supply of blood in a process called angiogenesis. Thereafter, the plaques begin to calcify as calcium starts to deposit. The final plaque is made up of a cap of fibrous tissue covering a core that is rich in lipids as well as necrotic or dead cells. The edge of this cap is a key in acute coronary disease. This region is prone to rupture, which exposes the underlying core of lipids and necrotic material to thrombogenic factors in the blood. This can cause the aggregation of platelets that form a clot across the plaque and further narrow the artery.

Arteries that have become narrowed due to the presence of plaques may lead to angina or chest pain as the muscles of the heart are deprived of oxygen. As the deposits on the plaques grow in size and dimension, the blood vessels become further narrowed and there may be obstruction leading to a heart attack or a myocardial infarction.

#### **MYOCARDIAL INFRACTION:**

In myocardial infarction, deep fissuring of an atherosclerotic plaque leads to the formation of an occlusive thrombus. Unlike unstable angina, in myocardial infarction the thrombus does not resolve quickly and irreversible myocardial damage occurs as blood flow is completely stopped. Myocardial infarctions are clinically classified by the presence or absence of Q waves. In patients with non-Q-wave

myocardial infarctions, thrombotic occlusion is persistent and lasts for more than several hours and sometimes permanent unless treated aggressively.

### **ANGINA PECTORIS:**

Angina pectoris is a clinical syndrome of CAD resulting from transient myocardial ischemia. There are three overlapping clinical patterns of angina pectoris with some differences in their pathogenesis:

**Stable or Typical Angina:** Angina pectoris is said to be stable when its pattern of frequency, intensity, ease of provocation or duration does not change over a period of several weeks. Identification of activities that provoke angina and the amount of sublingual nitroglycerin required to relieve symptoms are helpful indicators of stability versus progression. A decrease in exercise tolerance or an increase in the need for nitroglycerin suggests that the angina is progressing in severity or transitioning to an accelerating pattern.

**Prinzmetal's variant or Accelerating Angina:** Angina pectoris is said to be accelerating when there is a change in the pattern of stable angina. This may include a greater ease of provocation, more prolonged episodes, and episodes of greater severity, requiring a longer recovery period or more frequent use of sublingual nitroglycerin. This suggests a transition and most likely reflects a change in coronary artery blood flow and perfusion of the myocardium. This frequently portends unstable angina or an acute coronary syndrome such as an acute MI. Should a patient transition from a stable to accelerating pattern of angina, acute medical attention is warranted.

**Unstable or Crescendo Angina:** Unstable angina pectoris occurs when the pattern of chest discomfort changes abruptly. Signs of unstable angina are: symptoms at rest, a marked increase in the frequency of attacks, discomfort that occurs with minimal activity, and new-onset angina of incapacitating severity. Unstable angina usually is related to the rupture of an atherosclerotic plaque and the abrupt narrowing or occlusion of a coronary artery, representing a medical emergency with an incipient acute coronary syndrome and an MI to follow. Immediate medical attention is mandatory.

### **Risk factors for ischaemic heart disease:**

- Hyperlipidemia
- Hypertension
- Diabetes mellitus

- Genetic predisposition
- Cigarette smoking
- Obesity
- Sedentary life-style
- Heavy alcohol consumption
- High risk for males than premenopausal women
- Mental stress.

## **HEART FAILURE**

- Failure of the heart to maintain adequate cardiac output to meet the body's demands. It's a clinical syndrome rather than a specific diagnosis.
- Heart failure does not often have a single cause. A number of problems usually "gang up" on the heart, causing it to fail. There are a number of health conditions that increase your chances of developing heart failure, including:
  - High blood pressure (hypertension) – this can put extra strain on the heart, which over time can lead to heart failure
  - Coronary heart disease (CHD) – where the arteries that supply blood to the heart become clogged up by fatty substances(atherosclerosis), and may cause angina or a heart attack
  - Heart muscle weakness (cardiomyopathy) – this can cause heart failure; the reasons for this are often unclear, but it may be genetic in origin, or caused by an infection (usually viral), alcohol misuse, or medication used to treat cancer
  - Heart rhythm disturbance (atrial fibrillation)
  - Heart valve disease, damage or problems with the heart's valves

### **Pathophysiology:**

- Cardiac output is a function of preload and afterload.
- Preload: Volume and pressure of blood in the heart at the end of diastole.
- Afterload: Volume and pressure of blood in the heart at the beginning of systole.
- Starling's Law: Under normal circumstances, the more the myocardium stretches (for instance from increasing blood volume or pressure), the harder it contracts hence maintaining cardiac output. However there is a limit to how much the myocardium will comply with this rule i.e. overstretching the heart will cause it to lose the ability to pump harder and therefore fail.

Once the heart fails, the body will try and increase the afterload and preload through counter-regulatory neurohormonal mechanisms (renin-angiotensin-aldosterone system mainly) which under normal circumstances will support cardiac function by maintaining cardiac output. It does this in 3 ways:

- Retain sodium and water to increase intravascular volume and preload
- Vasoconstriction of arteries to increase blood pressure and afterload
- Increased sympathetic activation leading to increased cardiac contractility

But in patients with impaired ventricular function and weak cardiac muscles, this increase in preload and afterload is harmful and will set off a vicious cycle which will further deteriorate cardiac function. The diagram on the right illustrates this.

### **Types of heart failure:**

There are many ways to classify heart failure depending on the parameters involved, but the two most common ones used are left/right heart failure and systolic/diastolic heart failure:

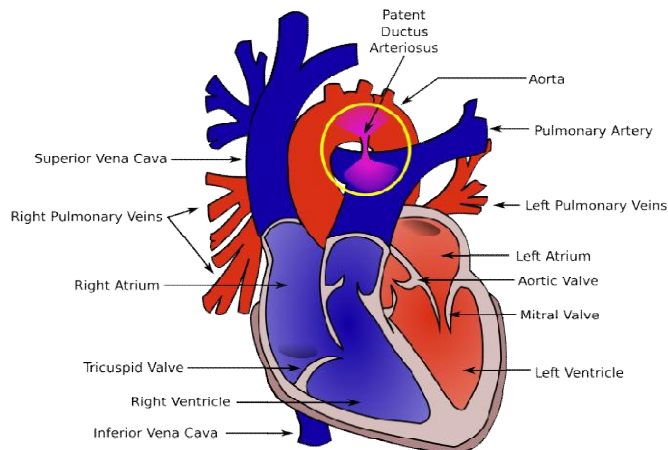
- Left heart failure – common causes are ischaemic heart disease, valvular heart disease, and hypertension. Affects the blood flow systemically to the brain and the rest of the body.  
Signs and symptoms: Tachypnoea, orthopnoea (shortness of breath on lying flat), paroxysmal nocturnal dyspnoea i.e. PND (attacks of severe sudden shortness of breath that usually wakes the patient up at night), bibasal crepitations, laterally displaced apex beat, gallop rhythm, murmurs, cyanosis.
- Right ventricular heart failure – common causes are chronic left heart failure resulting in back pressure to the right side of the heart, pulmonary hypertension, chronic lung disease, infarction to the right side of the heart and adult congenital heart disease. Affects blood flow to the lungs.  
Signs and symptoms: Peripheral pitting oedema, hepatomegaly, increased JVP, parasternal heave, ascites.
- Systolic heart failure – Insufficient contraction of the heart i.e. reduced ejection fraction.
- Diastolic heart failure – Insufficient relaxation of the heart muscles during diastole and hence decreased cardiac output. Patient has signs and symptoms of heart failure but ejection fraction is normal i.e. >45-50%. Common in elderly hypertensive patients.

It is important to remember that commonly patients have overlapping symptoms as chronic left heart failure for instance, will eventually lead to right heart failure.

## CONGENITAL HEART DISEASE

CYANOTIC	Increased pulmonary blood flow	<ol style="list-style-type: none"> <li>1. Transposition of the great arteries (TGA)</li> <li>2. Truncus Arteriosus</li> <li>3. Partial or Total anomalous pulmonary venous return (PAPVR/TAPVR)</li> <li>4. Single ventricle</li> <li>5. Hypoplastic left heart syndrome</li> <li>6. Interrupted aortic arch</li> </ol>
	Decreased pulmonary blood flow	<ol style="list-style-type: none"> <li>1. Tetralogy of fallot</li> <li>2. Tricuspid atresia</li> <li>3. Ebstein's anomaly</li> <li>4. Pulmonary atresia</li> <li>5. Pulmonary vascular obstructive disease (Eisenmenger's syndrome)</li> <li>6. Double outlet right ventricle</li> </ol>
ACYANOTIC	Increased pulmonary blood flow	<ol style="list-style-type: none"> <li>1. Patent ductus arteriosus (PDA)</li> <li>2. Atrial septal defect (ASD)</li> <li>3. Ventricular septal defect (VSD)</li> <li>4. Aorto - pulmonary window</li> <li>5. Endocardial cushion defect (AV canal defect)</li> </ol>
	Decreased systemic blood flow	<ol style="list-style-type: none"> <li>1. Coarctation of aorta</li> <li>2. Aortic stenosis</li> </ol>

## PATENT DUCTUS ARTERIOSUS (PDA)

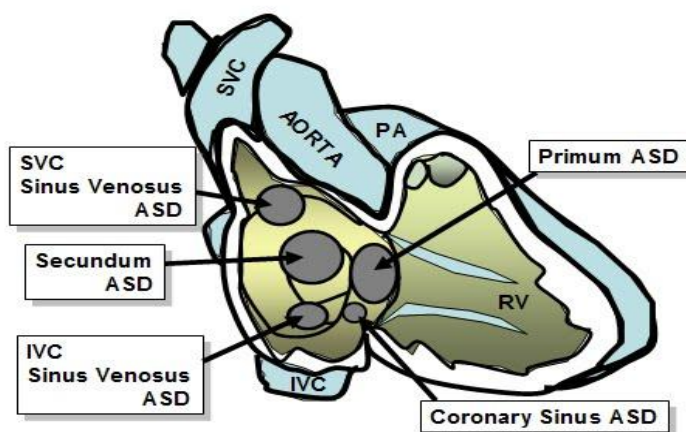


The ductus arteriosus is a communication between the pulmonary artery and the aortic arch distal to the left subclavian artery. PDA is the failure of the fetal ductus arteriosus to close after birth.

Left to right shunting of blood through the patent ductus results in an increase in pulmonary blood flow. The amount of blood that flows through the ductus, and the degree of symptoms exhibited, is determined by the differences in systemic and pulmonary vascular resistance, and in the circumference and the length of the PDA.

## ATRIAL SEPTAL DEFECT (ASD)

An atrial septal defect (ASD) is a communication or opening between the atria that result in shunting of blood between the two chambers. There are four anatomic types:



- Ostium primum - low in atrial septum, may involve a cleft mitral valve.
- Ostium secundum - center of the atrial septum. Most common type of ASD.
- Sinus venosus - high in the atrial septum. Associated with P-TAPVR.
- Coronary sinus - large opening between the coronary sinus and left atrium.

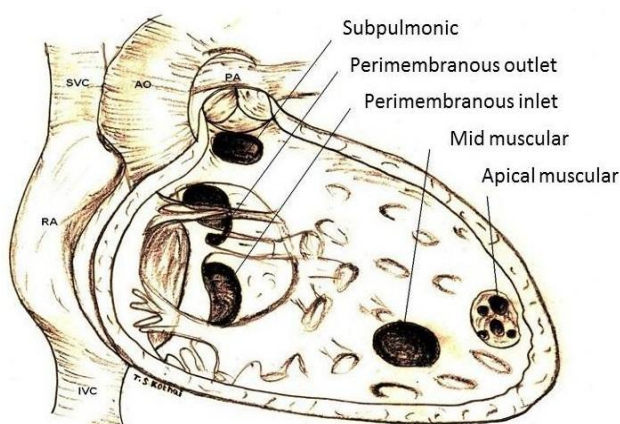
Because of higher pressure in the left atrium, blood is usually shunted from the left atrium across the ASD and into the right atrium. ASD's are restrictive when they are small enough to provide resistance to flow across the septum. ASD's are non-restrictive when the opening is large enough that equal pressures occur in both atria.

If the child has a cyanotic congenital heart defect, an ASD can provide an important shunt that allows mixing of oxygenated and venous blood within the atria. This may be necessary to sustain life.

### **VENTRICULAR SEPTAL DEFECT (VSD)**

A ventricular septal defect (VSD) is a communication (or multiple communications) between the right and left ventricles. VSD's are classified by their location in the ventricular septum. There are four anatomic types:

- Perimembranous - upper portion of septum (most common).
- Subpulmonary - below pulmonary valve.
- Muscular - muscle portion of ventricular septum. Usually low in the ventricular septum. Multiple muscular defects may be referred to as 'swiss cheese' defects.
- Atrioventricular canal - located beneath the tricuspid valve. Also called an inlet VSD.



Because of higher pressure in the left ventricle, blood is usually shunted from the left ventricle, across the VSD into the right ventricle, and into the pulmonary circulation. The risk of pulmonary hypertension depends on the size and location of the defect and the amount of pulmonary vascular resistance. Small VSD's restrict the amount of blood shunting from left to right. Large VSD's are non-restrictive, therefore a much higher degree of shunting occurs, and blood flow to the lungs is increased.

### **AORTO-PULMONARY WINDOW**

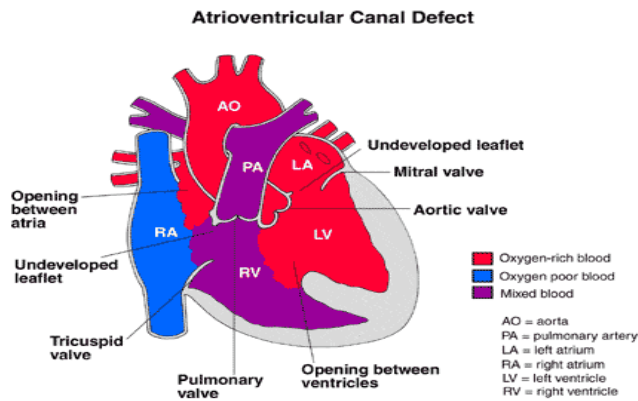
Aorto-pulmonary window is an opening between the ascending aorta and the main pulmonary artery. There must be two distinct and separate semilunar valves before this diagnosis can be made. The opening is of variable size and there are three anatomic types.

- Type I – Proximal defect, is located midway between the semilunar valves and the pulmonary bifurcation.
- Type II – Distal defect, involves both the main pulmonary artery and the origin of the right pulmonary artery.
- Type III – Total defect, incorporates defects present in types I and II. This is a rare cardiac malformation and 50% of patients have lesions.

There is left to right shunt, as with a VSD or a persistent PDA. As the pulmonary resistance decreases in the days and weeks after birth, there is an increase in left to right shunting of blood leading to CHF. Without repair, and depending on the size of the defect, varying degrees of irreversible pulmonary vascular disease develop.

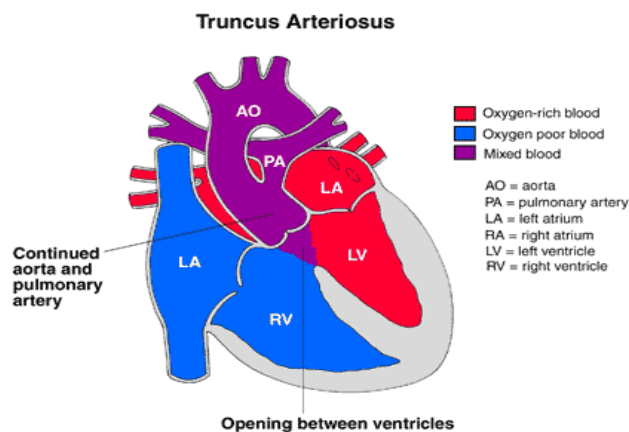
### **ENDOCARDIAL CUSHION DEFECT (ATRIO-VENTRICULAR CANAL DEFECT)**

Atrioventricular canal (AVC) may be complete or partial. Complete AVC is a communication between both the atria and the ventricles, as well as failure of the tricuspid and mitral valve rings to develop separately. There are often clefts in the septal valve leaflets. The term "canal" is used because the common AV valve orifice and the deficient atrial and/or ventricular septal tissue create a large opening in the center of the heart between the atria and ventricles. There are varying degrees of abnormality in the atrial and ventricular septum and the AV valves, resulting in many variations of severity and symptoms. In the partial form of AVC, only an ASD is present along with a cleft in the mitral valve.



Shunting occurs at the atrial and ventricular levels in a left-to-right direction. The right atrium also receives blood from the left ventricle via the insufficient mitral valve and ASD. Blood can also enter the right atrium via the incompetent tricuspid valve. The excessive volume load on the right side of the heart and subsequent increased blood flow to the lungs, creates a high risk for development of pulmonary vascular disease and pulmonary hypertension.

## TRUNCUS ARTERIOSUS



Truncus arteriosus is a rare congenital heart in which a single great vessel arises from the heart, giving rise to the coronary, systemic and pulmonary arteries. This single vessel contains only one valve (truncal valve). The truncus arteriosus overlies a VSD that is almost always seen in conjunction with this defect. There are four major types:

Type I – The most common; a single great vessel arises from the ventricles, and divides into an aorta and a main pulmonary artery (PA).

Type II – There is no PA main segment. The right and left PA's originate from the back of the truncus at the same level.

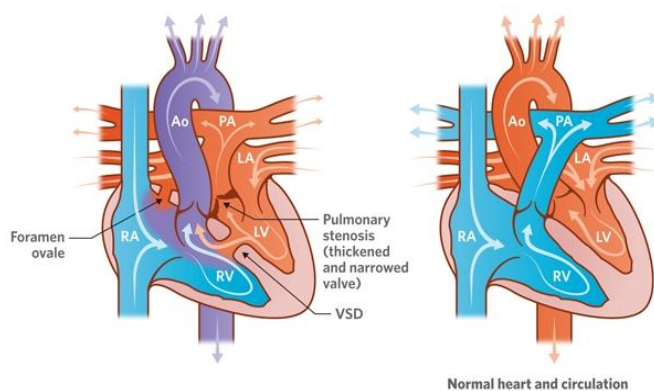
Type III – The right and left PA arise separately from the lateral aspect of the truncus. There is no main PA segment.

Type IV – No main PA. Pulmonary artery circulation is supplied from the systemic arterial circulation through collateral vessels of the bronchial arteries. This type is currently considered a form of Tetralogy of Fallot with pulmonary arteries.

In virtually every case of truncus arteriosus there is a VSD and a single large semilunar valve. Oxygenated and de-oxygenated blood from both the right and left ventricles is ejected into the common great vessel. Both systemic and pulmonary circulations receive mixed venous blood from both ventricles. Pressures in both ventricles are identical. Pulmonary blood flow is increased, therefore pulmonary vascular disease and PHTN will develop over time. The amount of blood flow to the lungs varies, depending on the nature of the pulmonary arteries.

#### **D- TRANSPOSITION OF GREAT ARTERIES**

Transposition of the great arteries with VSD and pulmonary stenosis



In D-Transposition of the Great Arteries (D-TGA) the aorta arises from the anatomic right ventricle and the pulmonary artery arises from the anatomic left ventricle. The most common form of transposition occurs when the ventricles are normally positioned and the aorta is malposed anteriorly and rightward above the right ventricle. A VSD is present in 40% of patients with D-TGA. Abnormal coronary artery patterns present in 33% of cases.

Blood flows from the RA to the RV and out through the aorta, carrying deoxygenated blood to the body. Blood flows from the LA to the LV and out through the PA, carrying oxygenated blood to the lungs. This results in two separate, parallel

circulations that require mixing at the atrial, ventricular or ductus arteriosus level. The degree of desaturation present will depend primarily on the amount of mixing between systemic and pulmonary venous blood. The extent of inter-circulatory mixing in D-TGA depends on the number, size and position of the anatomic communications.

### **L-TRANSPOSITION OF THE GREAT ARTERIES**

L-TGA, also known as congenitally corrected transposition. This malformation of the heart causes a reversal in the normal blood flow pattern because the right and left lower chambers of the heart are reversed. The L - transposition, however, is less dangerous than a d-transposition because the great arteries are also reversed. This "double reversal" allows the body to still receive oxygen-rich blood and the lungs to still receive the oxygen-poor blood. Most patients with L-TGA have associated cardiac defects (~80%), they include ventricular septal defect and valvar or subvalvar pulmonary stenosis. Patients are asymptomatic when L-TGA is not associated with other defects.

### **PARTIAL OR TOTAL ANOMALOUS PULMONARY VENOUS RETURN**

Total Anomalous Pulmonary Venous Return (T-APVR) results from the failure of the pulmonary veins to join normally to the left atrium during fetal cardiopulmonary development. The pulmonary veins empty abnormally into the right atria via drainage into one of the systemic veins. The infant must have an ASD or a PFO to survive. There are four anatomic variations; defined according to the site of the anomalous connection of the pulmonary vein to the venous circulation and to the right atrium.

- **Supracardiac:** The pulmonary veins join a common pulmonary vein behind the left atrium. This common vein ultimately enters the superior vena cava and right atrium.
- **Cardiac:** The pulmonary venous blood drains into a common pulmonary vein that drains into the right atrium or coronary sinus.
- **Infradiaphragmatic:** Pulmonary veins join to form a common pulmonary vein that descends below the diaphragm, through the portal system, then drains via the ductus venosus into the inferior vena cava and into the right atrium.
- **Mixed:** Pulmonary veins join the systemic circulation at two different sites, or use any combination of systemic venous drainage.

Partial Anomalous Pulmonary Venous Return (P-APVR) results when one or more (but not all) pulmonary veins drain into the right atrium or its venous tributaries.

There are two basic pathophysiologic states seen in T-APVR: unobstructed and obstructed. With unobstructed T-APVR, the entire pulmonary venous blood flow is returned to the systemic venous circulation, where there is mixing of the two venous returns in the right atrium. Mixing is virtually complete, each chamber of the heart receiving blood of almost identical oxygen concentration. Right atrial and ventricular dilation are present. The right to left shunting of blood across the PFO/ASD is essential for life. The amount of pulmonary blood flow is regulated by the pulmonary arteriolar resistance and by obstructions of the pulmonary veins. With obstructive T-APVR, the amount of pulmonary blood flow is reduced, causing cyanosis. This decreased flow, along with the systemic venous return, results in low arterial oxygen saturation and right heart failure.

### **INTERRUPTED AORTIC ARCH**

Interrupted Aortic Arch (IAA) refers to the congenital absence of a portion of the aortic arch. There are three types of IAA, and they are labelled according to the site of the interruption. IAA is always associated with a PDA and almost always with a VSD. Other cardiac defects may also be present.

- Type A: The ascending aortic arch is intact. The interruption occurs just distal to the left subclavian artery (the isthmus of aortic arch).
- Type B: The aorta is interrupted between the left carotid and the left subclavian artery, as a result the left subclavian artery arises from the descending aortic segment. This type is the most common.
- Type C: The aorta is divided between the innominate and the left carotid arteries. This type is extremely rare.

The ascending aorta receives blood from the left ventricle. The right ventricle perfuses the descending aorta through the ductus arteriosus. The infant will become acidotic and anuric when the ductus arteriosus closes. Ischemia to the liver, bowel and kidneys will occur. Profound ongoing acidosis will result in multi-system failure.

### **HYPOPLASTIC LEFT HEART SYNDROME**

Hypoplastic Left Heart Syndrome (HLHS) is identified as a small, underdeveloped left ventricle usually with aortic and/or mitral valve atresia or stenosis and hypoplasia of the ascending aorta. A large ductus arteriosus

is present. The right ventricle is dilated and hypertrophied, and an atrial septal defect is present. The entire systemic output is dependent on flow through the ductus arteriosus. This is a devastating diagnosis.

Because of its small size, the left ventricle is incapable of supporting the systemic circulation. Since outflow from the LV is either severely limited or absent, the systemic circulation must depend on mixed blood flow the pulmonary artery through the PDA. The foramen ovale stays open and left to right shunting occurs. The neonates right ventricle supports both pulmonary and systemic circulations. The PDA supplies the descending aorta with antegrade flow and the aortic arch with retrograde flow to the coronary circulation. Survival beyond birth is dependent on persistent patency of the ductus arteriosus to maintain systemic circulation.

### **SINGLE VENTRICLE**

Both AV valves are connected to a main, single ventricular chamber (i.e., double-inlet ventricle), and the main chamber is in turn connected to a rudimentary chamber through the bulboventricular foramen. One great artery arises from the main chamber, and the other arises from the rudimentary chamber. In about 80% of cases, the main ventricular chamber has anatomic characteristics of the LV (i.e., double-inlet LV). Occasionally, the main chamber has anatomic characteristics of the RV (i.e., double-inlet RV). Rarely does the ventricle have an intermediate trabecular pattern without a rudimentary chamber (i.e., common ventricle). Also, both atria rarely empty through a common AV valve into the main ventricular chamber with either LV or RV morphology (i.e., common-inlet ventricle). Either D-TGA or L-TGA is present in 85% of cases. The most common form of single ventricle is double-inlet LV with L-TGA with the aorta arising from the rudimentary chamber.

### **PULMONARY STENOSIS**

Pulmonary stenosis (PS) is a narrowing that obstructs blood flow from the right ventricle. It may be subvalvular, valvular, supra-valvular or in the pulmonary arteries. When this presents in neonates, it is referred to as 'critical pulmonary stenosis'.

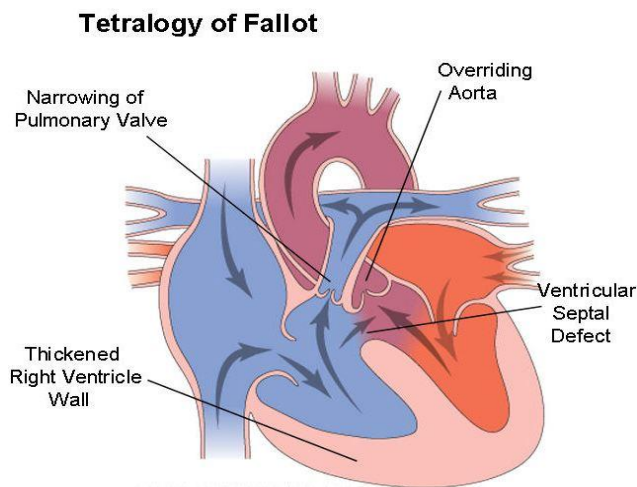
Pulmonary stenosis increases resistance to flow from the right ventricle. To maintain blood flow to the lungs, the right ventricle must generate higher pressures. The greater the pulmonary stenosis, the greater must be pressure generated by the right ventricle. Because the pressure on the right side is higher, right ventricular hypertrophy is also present. Pulmonary stenosis may be mild,

moderate or severe. When severe, the right ventricular hypertrophy may result in a right to left shunting through the foramen ovale.

### **PULMONARY ATRESIA**

There is no communication between the right ventricle and lungs so that the blood bypasses the right ventricle through an inter atrial septal defect. It then enters the lungs via patent ductus arteriosus.

### **TETROLOGY OF FALLOT**



Tetralogy of Fallot (TOF) is a congenital heart defect characterized by the association of four cardiac abnormalities; malaligned VSD, subpulmonary stenosis, overriding aorta and right ventricular hypertrophy. There is a wide spectrum of right ventricular outflow tract obstruction (RVOTO) in TOF. It may be subvalvular, valvular and/or supra-valvular. Typically, there is hypoplasia of the right ventricular outflow tract, stenosis of the pulmonary valve and hypoplasia of the pulmonary annulus and trunk. The right and left pulmonary arteries are usually normal in size. Some infants with TOF may be referred to as a 'pink' TET, if no cyanosis is present.

The hemodynamic changes and the degree of cyanosis that occur as a result of Tetralogy of Fallot are directly proportional to the degree of subpulmonary stenosis (right ventricular outflow tract obstruction), and the resulting limitation to pulmonary blood flow. If RVOTO is mild, there is minimal shunting of blood from left to right across the VSD which may result in over circulation and signs of CHF. If severe RVOTO is present, a large amount of blood shunts from right to left, producing systemic arterial oxygen desaturation which can lead to severe hypoxemia and acidosis. As long as the ductus remains open, pulmonary blood flow is adequate.

## **TETROLOGY OF FALLOT WITH PULMONARY ATRESIA**

This is an extreme variation of Tetralogy of Fallot and includes the 4 characteristic cardiac anomalies; malalignment type VSD, pulmonary stenosis, overriding aorta and right ventricular hypertrophy. But the coexistence of pulmonary atresia poses additional therapeutic challenges. There is no anatomic connection between the right ventricle and the pulmonary artery, and complete obliteration of the distal portion of the right ventricular - pulmonary outflow tract. The complexity of this lesion is dependent on the anatomy of the pulmonary circulation. There are four anatomic pulmonary subgroups.

- **Group I** - The main, right and left pulmonary arteries are well developed, and the blood flow is supplied by a large PDA.
- **Group II** - The main PA is absent. The right and left pulmonary arteries are well developed, and blood flow is supplied by a large PDA.
- **Group III** - The ductus is either absent or very small. Both left and right pulmonary arteries are diminutive or hypoplastic. The major source of pulmonary blood flow is supplied by aorto pulmonary collaterals (APCAS).
- **Group IV** - There are no true pulmonary arteries. Pulmonary blood flow is supplied entirely by APCAS.

## **TRICUSPID ATRESIA**

Tricuspid atresia is the failure of development of the tricuspid valve, resulting in a lack of direct communication between the right atrium and right ventricle. The floor of the right atrium is completely muscular. This defect is generally associated with a hypoplastic right ventricle and there is usually a ASD/PFO, VSD and/or PDA. Tricuspid atresia is often associated with some degrees of right ventricular outflow tract obstruction.

Because there is no direct communication between the right atrium and the right ventricle, blood flow is across the atrial septum from right to left via a PFO or an ASD. This results in complete mixing of desaturated systemic venous blood and fully saturated pulmonary venous blood at the atrial level, which is then ejected by the left ventricle. The workload of the left heart is increased due to the volume overload. The oxygen saturation levels are equal in the aorta and the PA.

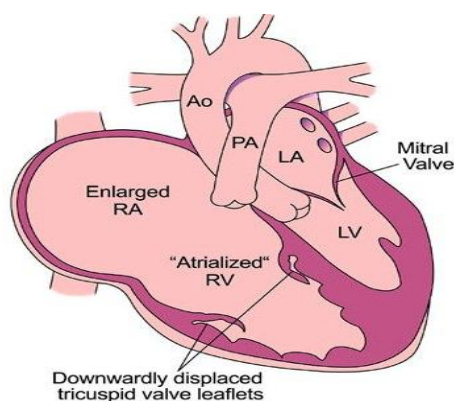
## **TRICUSPID STENOSIS**

In tricuspid stenosis, the tricuspid ring is small and the valve cusps are malformed. In this condition, there is an interatrial defect through which right- to-left shunt of blood takes place.

## **DOUBLE OUTLET RIGHT VENTRICLE (DORV)**

Double Outlet Right Ventricle (DORV) spans a wide spectrum of physiology from Tetralogy of Fallot to Transposition of the Great Arteries. DORV is a complex cardiac defect where both great vessels (aorta and pulmonary artery), either completely or nearly completely arise from the right ventricle. Most commonly they lie side by side in the same plane, and the aortic and pulmonary valves lie at the same level. A VSD is always present with DORV. The VSD may be subaortic, subpulmonary, or a combination of both. The classification of DORV is dependent on the location and type of VSD. The great vessels may be normally related or transposed. Some types of DORV have two adequately sized ventricles to allow a biventricular surgical repair. Other forms of DORV are associated with a severely underdeveloped left ventricle leading itself to a single ventricle pathway.

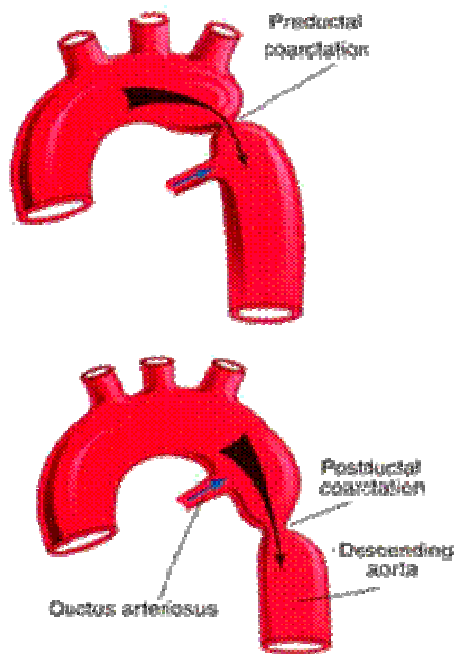
## **EBSTEIN'S ANOMALY**



Ebstein's anomaly is a rare congenital defect of the tricuspid valve. The tricuspid valve leaflets do not attach normally to the tricuspid valve annulus. The leaflets are dysplastic and the septal and posterior leaflets are downwardly displaced, adhering to the right ventricular septum. The tricuspid valve may be incompetent or, less commonly, stenotic. The portion of the right ventricle above the valve leaflets becomes "atrialized", and as a result, right ventricular size is compromised and the right atrium is enlarged. There is always a patent foramen

ovale or atrial septal defect. Ebstein's Anomaly presents one of the widest anatomic, physiologic, and symptomatic spectra of all congenital heart anomalies.

### **COARCTATION OF THE AORTA**



Coarctation of the aorta is a narrowing in the aortic arch. The coarctation may occur as a single lesion, as a result of improper development of the involved area of the aorta, or as a result of constriction of that portion of the aorta when the ductus arteriosus constricts. The coarctation is most often located near the ductus arteriosus; if narrowing is proximal to the ductus it is 'pre-ductal', if it is distal to the ductus it is 'postductal'.

Aortic narrowing increases resistance to flow from the proximal to the distal aorta. As a result, pressure in the aorta proximal to the narrowing is increased and pressure in the aorta distal to the narrowing is decreased. Collateral circulation can develop in older children and adults to maintain adequate flow into the distal descending aorta.

### **AORTIC STENOSIS**

Aortic Stenosis (AS) is a narrowing that obstructs blood flow from the left ventricle, leading to left ventricular hypertrophy and/or aortic insufficiency. AS may be mild, moderate, or severe. When this condition presents in neonates, it is referred

to as 'critical aortic stenosis'. There are three types of AS, classified according to the location of the stenotic area:

- **Valvular:** Failure of the cusps to separate, creating fusion of the valve, or presence of a bicuspid valve instead of tricuspid. Accounts for 80% of AS.
- **Subaortic:** Caused by the formation of a fibrous ring with a narrowed central orifice below the aortic valve. It may be discrete or diffuse and in infants is seen as a component of a more complex lesion.
- **Supravalvular:** Caused by a fibromembranous narrowing of the aorta above the aortic valve and coronary arteries. Associated with Williams Syndrome.

Whenever there is obstruction to the left ventricular outflow tract, the left ventricle will generate greater pressure to maintain flow beyond the area of resistance. As a result, left ventricular hypertension that is proportional to the degree of aortic obstruction develops, and systemic cardiac output may be compromised. Left ventricular hypertrophy, aortic insufficiency, and failure can develop.

### **CARDIAC MALPOSITION**

The term cardiac malposition indicates that the heart is abnormally located within the chest.

- Levocardia - The heart is located in the left chest (normal).
- Dextrocardia - The heart is located in the right chest.
- Mesocardia - The heart is located in the middle of the chest.

The hemodynamics associated with cardiac malposition range from normal to those incompatible with life, and are a direct consequence of the intra cardiac defect. The diagnosis of cardiac malposition is made by chest x-ray.

### **MAJOR AORTOPULMONARY COLLATERAL ARTERIES (MAPCA'S)**

Major aortopulmonary collateral arteries (MAPCA's) are persistent tortuous fetal arteries that arise from the descending aorta and supply blood to pulmonary arteries in the lungs usually at the posterior aspect of hilum. Embryologically, the intersegmental arteries regress with the normal development of pulmonary arteries.

They may persist to supply the pulmonary arteries when there is no flow or very little flow into the pulmonary arteries from the right ventricle. If there is an alternate

supply to the pulmonary arteries (e.g. patent ductus arteriosus), then the fetal arteries regress and such patient does not have MAPCAs

### **ANOMALOUS LEFT CORONARY ARTERY ARISING FROM THE PULMONARY ARTERY (ALCAPA)**

An anomalous left coronary artery from the pulmonary artery is a problem that occurs when the baby's heart is developing early in the pregnancy. The developing blood vessels in the heart do not connect correctly. In children with ALCAPA, the left coronary artery starts at the pulmonary artery. The pulmonary artery is the major blood vessel that takes oxygen-poor blood from the heart to the lungs. When this defect occurs, blood that is lacking in oxygen is carried to the left side of the heart. Therefore, the heart does not get enough oxygen. When the heart muscle is deprived of oxygen, the tissue begins to die. This condition leads to a heart attack in the baby.

A condition known as "coronary steal" further damages the heart in babies with ALCAPA. The low blood pressure in the pulmonary artery causes blood from the abnormal left coronary artery to flow toward the pulmonary artery instead of toward the heart. This results in less blood and oxygen to the heart. This problem will also lead to a heart attack in a baby. Coronary steal develops over time in babies with ALCAPA if the condition is not treated early.

### **HYPERTENSIVE HEART DISEASE**

Hypertensive heart disease refers to heart problems that occur because of high blood pressure. These problems include:

**Narrowing of the Arteries:** The coronary arteries transport blood to your heart muscle. When high blood pressure causes the blood vessels to become narrow, blood flow to the heart can slow or stop. This condition is known as coronary heart disease (CHD), also called coronary artery disease. CHD makes it difficult for your heart to function and supply the rest of your organs with blood. It can put you at risk for heart attack from a blood clot that gets stuck in one of the narrowed arteries and cuts off blood flow to your heart.

**Thickening and Enlargement of the Heart:** High blood pressure makes it difficult for your heart to pump blood. Just like other muscles in your body, regular hard work causes your heart muscles to thicken and grow. This alters the way the heart functions. These changes usually happen in the main pumping chamber of the heart

known as the left ventricle. The condition is known as left ventricular hypertrophy (LVH).

## **DISORDERS OF THE LUNG AND PULMONARY CIRCULATION**

Pulmonary vascular disease is defined as, any condition that affects the blood vessels along the route between the heart and lungs.

Basic information about the major types of pulmonary vascular disease follows:

### **PULMONARY HYPERTENSION**

The pulmonary circulation is a low pressure system. Pulmonary hypertension exists when the systolic pressure exceeds 30 mmHg. Pulmonary hypertension is a rare lung disorder in which the arteries that carry blood from the heart to the lungs become narrowed, making it difficult for blood to flow through the vessels. As a result, the blood pressure in these arteries -- called pulmonary arteries - rises far above normal levels. This abnormally high pressure strains the right ventricle of the heart, causing it to expand in size. Overworked and enlarged, the right ventricle gradually becomes weaker and loses its ability to pump enough blood to the lungs. This could lead to the development of right heart failure.

### **PULMONARY VENOUS HYPERTENSION**

It's increased blood pressure in the pulmonary veins (carrying blood away from the lungs, to the heart). Pulmonary venous hypertension is most often caused by congestive heart failure. A damaged mitral valve in the heart (mitral stenosis or mitral regurgitation) may contribute to pulmonary venous hypertension.

### **PULMONARY EMBOLISM**

Pulmonary embolism, pulmonary thrombosis and pulmonary infraction are related conditions:

- Pulmonary embolism results from the obstruction of pulmonary arterial vessels by thrombus or by material, such as fat or air, originating in some other site.
- Pulmonary thrombosis implies the formation of clot in situ. This is uncommon and implies the presence of pre-existing disease in the pulmonary arteries.
- Pulmonary infarction is the necrosis of a wedge of lung tissue resulting from pulmonary arterial occlusion.

## **CHRONIC THROMBOEMBOLIC DISEASE**

In rare cases, a blood clot to the lungs (pulmonary embolism) is never reabsorbed by the body. Instead, a reaction occurs in which multiple small blood vessels in the lungs also become diseased. The process occurs slowly, and gradually affects a large part of the pulmonary arterial system

## **COR PULMONALE**

The term "cor pulmonale" literally means heart disease related to the lungs or pulmonary circulation; it should logically include all disturbances of the pulmonary circulation. However, in current medical terminology the term "chronic cor pulmonale" is used exclusively to indicate the cardiac effect of chronic diseases of the lungs. The essential feature of chronic cor pulmonale is pulmonary hypertension caused most frequently by hypoxemia. "Acute cor pulmonale" has already been mentioned as referring to large pulmonary embolism, but there are some who question any use of the term "cor pulmonale" not connected with diseases of the lungs.

## **PULMONARY EDEMA**

Pulmonary edema occurs when fluid builds up in the air sacs (alveoli) of the lungs. It is usually caused by heart failure, with a rise in the vein's blood pressure going through the lungs. As the pressure in the blood vessels increases, fluid is pushed into the lungs and causes a shortness of breath.

Pulmonary edema may be caused by exercise at very high altitudes (high altitude pulmonary edema), direct damage to the lung (by poisonous gas or severe infection), as a side effect of medications, or from major trauma. Pulmonary edema may also be a complication of any heart disease that causes the heart muscle to weaken or become stiff.

## **RHEUMATIC FEVER AND RHEUMATIC HEART DISEASE**

Rheumatic fever (RF) is a systemic, post- streptococcal, non- suppurative inflammatory disease, principally affecting the heart, joints, central nervous system, skin and subcutaneous tissues. The chronic stage of RF involves all the layers of the heart (pancarditis) causing major cardiac sequelae referred to as rheumatic heart disease (RHD). The etiologic role of preceding throat infection with  $\beta$ -haemolytic streptococci of group A in RF is now well accepted. However, the mechanism of lesions in the heart, joints and other tissues is not by direct infection there are two

types of evidences in the etiology and pathogenesis of RF and RHD: the epidemiologic evidence and the immunologic evidence.

## **DISORDERS OF THE CARDIAC VALVES**

Valvular diseases are various forms of congenital and acquired disease which cause valvular deformities. Many of them result in cardiac failure. Rheumatic heart disease is the most common form of acquired valvular disease. The valvular deformities may be two types: stenosis and insufficiency:

Stenosis: is the term used for failure of a valve to open completely during diastole resulting in obstruction to the forward flow of the blood.

Insufficiency or incompetence or regurgitation: is the failure of a valve to close completely during systole resulting in back flow or regurgitation of the blood.

### **MITRAL VALVE DISEASE**

#### **MITRAL VALVE STENOSIS:**

Mitral stenosis is generally rheumatic in origin. Less common causes include bacterial endocarditis, Libman-Sacks endocarditis, endocardial fibroelastosis and congenital parachute mitral valve. The latent period between the rheumatic carditis and development of symptomatic mitral stenosis is about two decades. The appearance of the mitral valve in stenosis varies according to the extent of involvement. Generally, the valve leaflets are diffusely thickened by fibrous tissue and/or calcific deposits, especially towards the closing margin. There are fibrous adhesions of mitral commissures and fusion and shortening of chordae tendineae. In less extensive involvement, the bases of the leaflets of mitral valve are mobile while the free margins have puckered and thickened tissue with narrowed orifice; this is called as 'purse-string puckering'. The more advanced cases have rigid, fixed and immobile diaphragm-like valve leaflets with narrow, slit-like or oval mitral opening, commonly referred to as 'button-hole' or 'fish-mouth' mitral orifice.

#### **MITRAL REGURGITATION**

All the causes of mitral stenosis may produce mitral insufficiency, RHD being the most common cause. In addition, mitral insufficiency may result from non-inflammatory calcification of mitral valve annulus (in the elderly), myxomatous transformation of mitral valve (floppy valve syndrome), rupture of a leaflet or of the chordate tendineae or of a papillary muscle. A few other conditions cause mitral

insufficiency by dilatation of the mitral ring such as in myocardial infarction, myocarditis and left ventricular failure in hypertension.

In myxomatous degeneration of the mitral valve leaflets (floppy valve syndrome), there is prolapse of one or both leaflets into the left atrium during systole. In non-inflammatory calcification of mitral annulus seen in the aged, there is irregular, stony-hard, bead-like thickening in the region of mitral annulus without any associated inflammatory changes. It is thought to reflect degenerative changes of aging.

## **AORTIC VALVE DISEASE**

### **AORTIC STENOSIS**

It is of two main types: non-calcific and calcific type,

1. Non-calcific aortic stenosis: The most common cause of non-calcific aortic stenosis is chronic RHD. Other causes are congenital valvular and subaortic stenosis and congenitally bicuspid aortic valve.
2. Calcific aortic stenosis: Calcific aortic stenosis is more common type. Various causes have been ascribed to it. These include healing by scarring followed by calcification of aortic valve such as in RHD, bacterial endocarditis, Brucella endocarditis, Monckeberg's calcific aortic stenosis, healed congenital malformation and familial hypercholesterolaemic xanthomatosis.

The aortic cusps show characteristic fibrous thickening and calcific nodularity of the closing edges. Calcified nodules are often found in the sinuses of Valsalva. In rheumatic aortic stenosis, the commissures are fused and calcified, while in nonrheumatic aortic stenosis there is no commissural fusion.

### **AORTIC REGURGITATION**

In about 75% of patients, the cause is chronic RHD. However, isolated aortic insufficiency is less often due to rheumatic etiology. Other causes include syphilitic valvulitis, infective endocarditis, congenital subaortic stenosis (congenitally bicuspid aortic valve), myxomatous degeneration of aortic valve (floppy valve syndrome), traumatic rupture of the valve cusps, dissecting aneurysm, Marfan's syndrome and ankylosing spondylitis. The aortic valve cusps are thickened, deformed and shortened and fail to close. There is generally distension and distortion of the ring.

## **TRICUSPID VALVE DISEASE**

### **TRICUSPID STENOSIS**

Tricuspid stenosis is a narrowing or blockage of the tricuspid valve. Tricuspid stenosis causes the right atrium to become enlarged, while the right ventricle does not get enough blood. Tricuspid stenosis is usually associated with rheumatic fever. Often, people with tricuspid stenosis also have mitral stenosis.

### **TRICUSPID REGURGITATION**

It means there is a backflow of blood from the lower-right chamber (the right ventricle) to the upper-right chamber (the right atrium), either because of a damaged tricuspid valve or an enlarged right ventricle. Blood is pushed back into the major veins instead of moving forward into the lungs, where it can pick up oxygen. The main cause of tricuspid regurgitation is an enlarged right ventricle. This may be caused by any disorder that causes right ventricular failure, such as increased pressure in the pulmonary artery. Damage to the tricuspid valve may be caused by rheumatic fever.

## **PULMONARY VALVE DISEASE**

Pulmonary valve disease is relatively uncommon. Pulmonary stenosis is usually of congenital origin. Other causes of pulmonary stenosis include rheumatic heart disease and malignant carcinoid. Obstruction of the outflow tract of the right ventricle may occur in hypertrophic cardiomyopathy and mediastinal tumours.

Pulmonary regurgitation is usually secondary to pulmonary hypertension, but occasionally occurs as a consequence of infective endocarditis, as a complication of the surgical relief of pulmonary stenosis, as a congenital anomaly.

## **MYOCARDIAL DISEASE**

Involvement of the myocardium occurs in three major forms of diseases already discussed—*ischaemic heart disease*, *hypertensive heart disease* and *rheumatic heart disease*. In addition, there are two other broad groups of isolated myocardial diseases:

### **MYOCARDITIS:**

Inflammation of the heart muscle is called *myocarditis*. It's usually forms part of a generalized infection (particularly viral) but can also be due to physical and

chemical agents. Myocarditis is divided into four main etiologic types: Infective myocarditis, Idiopathic (Fiedler's) myocarditis, Myocarditis in connective tissue disease and Miscellaneous types of myocarditis.

### **CARDIOMYOPATHY**

The term cardiomyopathy refers to disease process involving heart muscle. The WHO definition of cardiomyopathy also excludes heart muscle diseases of known etiologies. However, the term cardiomyopathy has been loosely used by various workers for myocardial diseases of known etiology as well e.g. alcoholic cardiomyopathy, amyloid cardiomyopathy, ischaemic cardiomyopathy etc. This controversy is resolved by classifying all cardiomyopathies into two broad groups:

- Primary cardiomyopathy: Disease confined to heart muscle and not arising from any other identifiable disease process.
- Secondary cardiomyopathy: heart muscle diseases arising as part of a more generalized disorder, which closely resemble the clinical characteristics of a primary cardiomyopathy.

Three types of functional impairment are observed in patients with cardiomyopathy:

- Dilated: The ventricles are dilated with impaired function.
- Hypertrophic: The left ventricle is inappropriately thickened, but contractile function is preserved.
- Restrictive: Diastolic filling is impaired.

### **PERICARDIAL DISEASE**

Diseases of the pericardium are usually secondary to, or associated with, other cardiac and systemic diseases. They are broadly of 2 types: Pericardial fluid accumulations and Pericarditis.

#### **PERICARDIAL FLUID ACCUMULATIONS**

Accumulation of fluid in the pericardial sac may be watery or pure blood. Accordingly, it is of two types: hydropericardium (pericardialeffusion) and haemopericardium.

- Hydropericardium (pericardial effusion): Accumulation of fluid in pericardial cavity due to non inflammatory cause.
- Haemopericardium: Accumulation of pure blood in the pericardial sac.

## **PERICARDITIS**

Pericarditis is the inflammation of the pericardial layers and is generally secondary to diseases in the heart or caused by systemic diseases. Primary or idiopathic pericarditis is quite rare. Based on the morphologic appearance, pericarditis is classified into acute and chronic types, each of which may have several etiologies.

## **TUMOURS OF THE HEART**

Cardiac tumours are rare. The commonest is the myxoma which occurs most frequently in the left atrium, but occasionally in the other chambers. It varies from 1 to 8 cm in diameter, and is usually attached by a pedicle to the atrial septum. Because its position may vary with posture, transient or complete obstruction of the mitral valve may result. The tumour may prolapsed into the left ventricle and cause mitral regurgitation.

# **ELECTROCARDIOGRAPHY**

## **ELECTROCARDIOGRAPHY**

It is the technique by which the electrical activities of the heart are studied. The spread of excitation through myocardium produces local electrical potential. The causes flow of small currents through the body fluids particularly extracellular fluid. These small currents can be picked up from the surface of the body by using suitable electrodes and recorded in the form of electrocardiogram. This technique was discovered by Dutch physiologist, **Einthoven Willem** who is called the father of ECG.

Electrocardiogram is a written record of the heart, while electrocardiograph is an instrument with which it is recorded. The same is true for telegram. The graph of voltage versus time produced by this noninvasive medical procedure referred to as an electrocardiogram.

## **THE CARDIAC ELECTRO PHYSIOLOGY**

The most important muscle type in a vertebrate is cardiac muscle, which causes the heart beat. The cells that make up are called cardiac muscle cell or cardiomyocytes. Pacemaker cells, electrical conducting cells, myocardial cells these are the three types of cardiac cells. There are four basic properties of cardiac cells,

### **1. Excitability**

It is the knack of cardiac cells to respond to a suitable amount of stimuli and produce an electrical potential, also called electrical impulse. This electrical impulse spreads across the heart, causing it to beat. It is due to the cellular action potential.

### **2. Conductivity**

It is the ability of cardiac cells to transfer the action potential generated at the sino-atrial node from cell to cell.

### **3. Contractility**

It is a cardiac muscle cell's ability to transform an electrical signal originating at sino-atrial node into mechanical action.

### **4. Rhythmicity**

Rhythmicity is a property of cardiac muscle cells which describes their ability to contract regularly without the involvement of any nerves. Cardiac

muscle cells do not need any neural stimulation to perform their functions. The action potentials originate in the sino-atrial node and do not involve any nervous activity. The action potential then moves through the entire heart again without any neural input. This property of cardiac cell is also called automaticity.

### Action potential

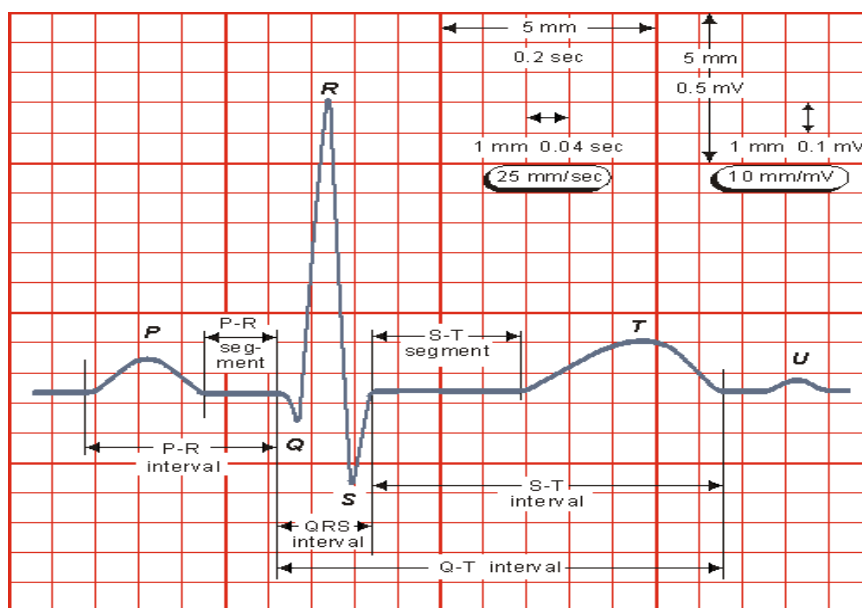
Electrical stimulation created by a sequence of ion fluxes through specialized channels in the membrane of cardiomyocytes that lead to cardiac contraction. The action potential in typical cardiomyocytes is composed of 5 phase (0-4).

### Conduction pathway

Depolarization occurs in the sinoatrial (SA) node; current travels through internodal tracts of the atria to the atrioventricular (AV) node; then through Bundle of His, which divides into right and left bundle branches; left bundle branch divides into left anterior and posterior fascicles.

## WAVES OF NORMAL ELECTROCARDIOGRAM

The waves of ECG recorded by Limb Lead II are considered as the typical waves. Normal electrocardiogram has the following waves namely P,Q,R,S and T. Einthoven had named the waves of ECG starting from the middle of the alphabets (P) instead of starting from the beginning (A).



P wave is the atrial complex

QRST complex is the ventricular complex

QRS complex is the initial ventricular complex

T wave is the final ventricular complex.

### **'P' WAVE**

It is a positive wave and the first wave in ECG. It is also called atrial complex. It is produced due to the depolarization of atrial musculature.

Duration: 0.1 second. And Amplitude: 0.1 to 0.12mV.

### **'QRS' COMPLEX**

It is also called the initial ventricular complex. Q wave is a small negative wave. It is continued as the tall R wave, which is a positive wave. R wave is followed by a small negative wave, the S wave. QRS complex is obtained because of the depolarization of ventricular musculature. Q wave is due to the depolarization of basal portion of interventricular septum. R wave is due to the depolarization of apical portion of interventricular septum and apical portion of ventricular muscle near the atrioventricular ring.

Duration : 0.08 to 0.10 second

Amplitude: Q wave: 0.1 to 0.2mV; R wave: 1mV; S wave: 0.4mV.

### **'T' WAVE**

It is the final ventricular complex and is a positive wave. T wave is due to the repolarization of the ventricular musculature.

Duration: 0.2 second. And Amplitude: 0.3mV.

Atrial repolarization is not recorded as a separate wave in ECG because, it is merged with QRS complex.

### **'U' WAVE**

It is a rare and insignificant wave of ECG. It is supposed to be due to repolarization of papillary muscle.

## **INTERVALS AND SEGMENTS OF ECG**

### **'P – R' INTERVAL**

It is the interval between the onset of P wave and the onset of Q wave. P-R interval signifies the atrial depolarization and conduction of the impulses through AV node.

Duration: The normal duration is 0.18 second and varies between 0.12 and 0.2 second.

### **'Q – T' INTERVAL**

It is the interval between the onset of Q wave and the end of T wave. Q-T interval indicates the ventricular repolarization.

Duration: 0.4 to 0.42 second.

### **'S-T' SEGMENTS**

It is the time interval between the end of S wave and the onset of T wave. It is isoelectric. Elevation of S-T segment occurs in acute myocardial infarction.

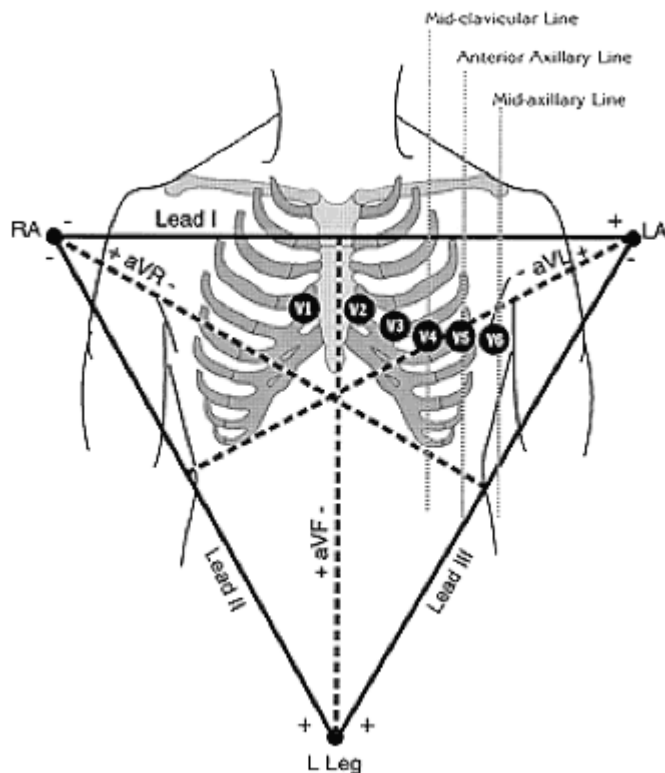
Duration: 0.08 second.

### **'R-R' INTERVAL**

It is the time interval between two consecutive R waves. It is the duration of one cardiac cycle.

Duration: The normal duration of R-R interval is 0.8 second.

## ECG LEADS



Two arrangements, bipolar and unipolar leads.

**Bipolar Lead:** One in which the electrical activity at one electrode is compared with that of another. By convention, a positive electrode is one in which the ECG records a positive (upward) deflection when the electrical impulse flows toward it and a negative (downward) deflection when it flows away from it.

**Unipolar Lead:** One in which the electrical potential at an exploring electrode is compared to a reference point that averages electrical activity, rather than to that of another electrode. This single electrode, termed the exploring electrode, is the positive electrode.

**Limb Leads:** I, II, III, aVR, aVL, aVF explore the electrical activity in the heart in a frontal plane; i.e., the orientation of the heart seen when looking directly at the anterior chest.

**Standard Limb Leads:** I, II, III; bipolar, form a set of axes 60° apart

**Lead I:** Composed of negative electrode on the right arm and positive electrode on the left arm.

**Lead II:** Composed of negative electrode on the right arm and positive electrode on the left leg.

**Lead III:** Composed of negative electrode on the left arm and positive electrode on the left leg.

**Augmented Voltage Leads:** aVR, aVL, aVF; unipolar; form a set of axes 60° apart but are rotated 30° from the axes of the standard limb leads.

**aVR:** Exploring electrode located at the right shoulder.

**aVL:** Exploring electrode located at the left shoulder.

**aVF:** Exploring electrode located at the left foot.

**Reference Point for Augmented Leads:** The opposing standard limb lead; i.e., that standard limb lead whose axis is perpendicular to the particular augmented lead.

### **CHEST LEADS (PRECORDIAL LEADS)**

V1, V2, V3, V4, V5, V6, explore the electrical activity of the heart in the horizontal plane; i.e., as if looking down on a cross section of the body at the level of the heart. These are exploring leads.

**Reference Point for Chest Leads:** The point obtained by connecting the left arm, right arm, and left leg electrodes together.

**Sternal angle (Angle of Louis):** It is the anterior angle formed by the junction of the manubrium and body of the sternum. The sternal angle is a palpable clinical landmark. Which attaches to the 2<sup>nd</sup> rib. It refers to the precordial leads position.

**V1:** Positioned in the 4th intercostal space just to the right of the sternum.

**V2:** Positioned in the 4th intercostal space just to the left of the sternum.

**V3:** Positioned halfway between V2 and V4.

**V4:** Positioned at the 5th intercostal space in the mid-clavicular line.

**V5:** Positioned in the anterior axillary line at the same level as V4.

**V6:** Positioned in the mid axillary line at the same level as V4 and V5.

**V1 and V2:** Monitor electrical activity of the heart from the anterior aspect, septum, and right ventricle.



The average direction of spread of the depolarisation wave through the ventricles as seen from the front is called the 'cardiac axis'. It is useful to decide whether the axis is in a normal direction or not. The direction of the axis can be derived most easily from the QRS axis complex in leads I, II and III.

A normal 11 o' clock-5 o'clock axis means that the depolarizing wave is spreading towards leads I, II and III, and is therefore associated with a predominantly upward deflection in all these leads; the deflection will be greater in lead II than in I and III. Normal axis is a mean vector between +90 degree and 0 degree.

**Right axis Deviation:** It is usually caused by right ventricular hypertrophy. In right axis deviation the direction of depolarisation is distorted to the right (1 – 7 o'clock). Right axis deviation is a mean vector of > +90 degree.

**Left axis Deviation:** It is the general direction of depolarisation becomes distorted to the left. This causes the deflection in lead III become –Ve. Left axis deviation is a mean vector more negative than -30 degrees.

**Iso-Electric:** When the deflection is perpendicular on the lead, this is called iso-electric. This QRS is neither +Ve or –Ve.

#### **Determining the axis of the mean vector:**

Check lead aVF.

if aVF is positive, check lead I

if lead I is positive, axis is normal.

if aVF is negative, check lead II.

if lead II is positive, it is in the gray zone.

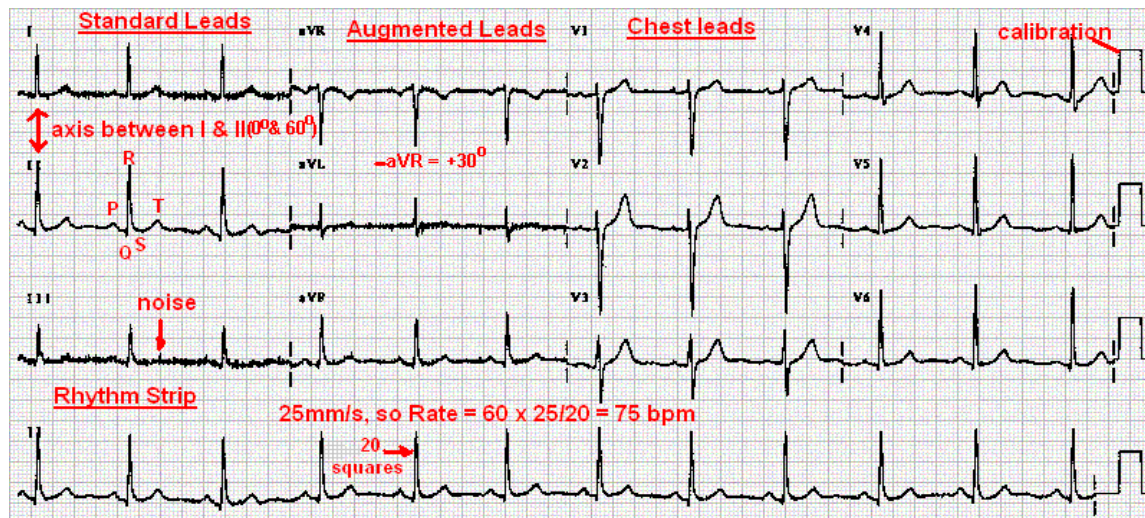
if lead II is negative, there is left axis deviation.

## **HEART RATE**

The rate of ventricular depolarization can be calculated by measuring the distance between each QRS complex. The approximate heart rate can be calculated using the formula:

$$300/\text{number of large boxes between QRS complexes} = \text{heart rate.}$$

## Normal ECG



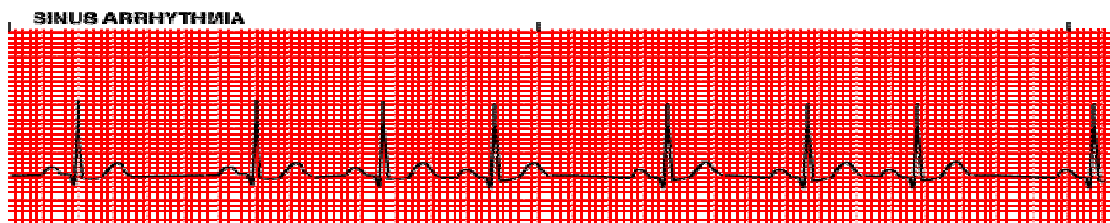
- Pulse rate lies between 60 and 100 beats/minute
- Rhythm is regular except for minor variations with respiration.
- P-R interval is the time required for completion of atrial depolarization; conduction through the AV node, bundle of His, and bundle branches; and arrival at the ventricular myocardial cells. The normal P-R interval is 0.12 to 0.20 seconds.
- The QRS interval represents the time required for ventricular cells to depolarize. The normal duration is 0.06 to 0.10 seconds.
- The Q-T interval is the time required for depolarization and repolarization of the ventricles.

The time required is proportional to the heart rate. The faster the heart rate, the faster the repolarization, and therefore the shorter the Q-T interval. With slow heart rates, the Q-T interval is longer. The Q-T interval represents about 40% of the total time between the QRS complexes (the R-R interval). In most cases, the Q-T interval lasts between 0.34 and 0.42 seconds.

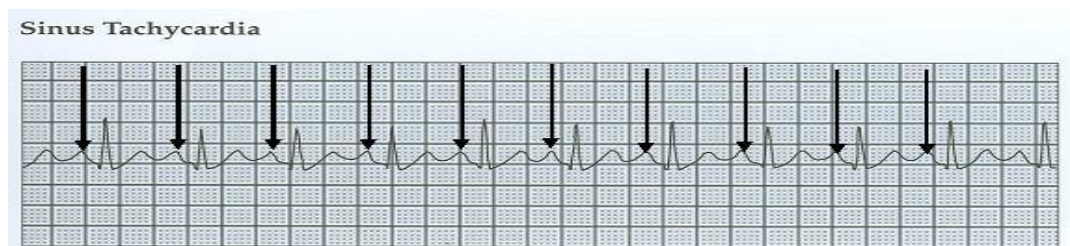
## SINUS RHYTHM DISTURBANCE

Sinus rhythms originate in the sinoatrial node. Diagnosis of sinus rhythms requires examining leads II and aVR for the correct polarity of the P waves. The P wave is always positive in lead II and negative in lead aVR. A P wave will precede each QRS complex, and the P-R interval should be constant.

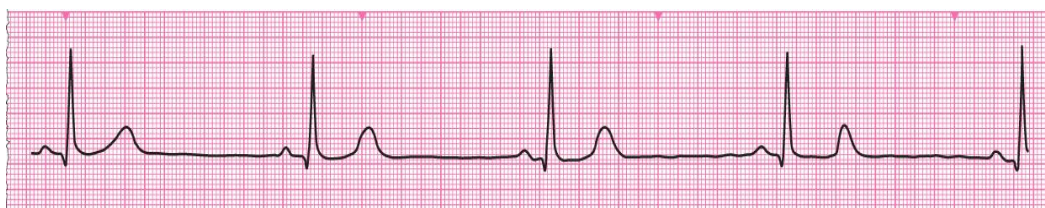
**Sinus Arrhythmia:** Under normal physiological conditions in a normal healthy person, the heart rate varies according to the phases of respiratory cycle. Heart rate increases during inspiration and decreases during expiration. This type of rhythmical increase and decrease in heart rate in relation to respiration is called sinus arrhythmia or respiratory sinus arrhythmia (RSA).



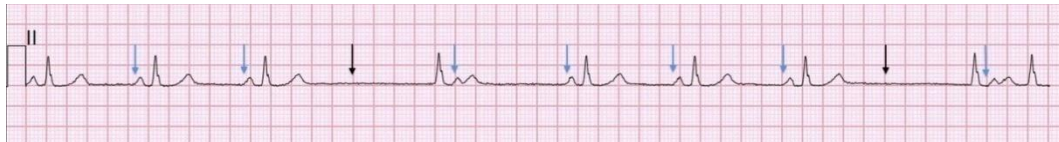**Sinus Tachycardia:** Sinus rhythm with a rate  $>100$  beats per minute. With fast rates, P waves may merge with preceding T waves and be indistinct. Can originate from the sinoatrial node, atrial muscle, or atrioventricular junction. Often referred to as supraventricular tachycardia without specifying site of origin.



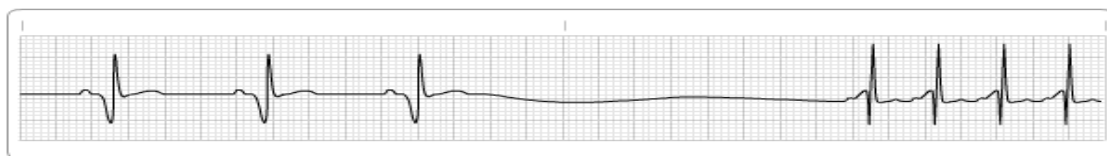
**Sinus Bradycardia:** Sinus rhythm with a rate  $<60$  beats per minute.



**Sinoatrial Block:** Refers to failure of the sinus node to function for one or more beats. In this condition, there are simply one or more missing beats; i. e., there are no P waves or QRS complexes seen. Fortunately, when the sinus fails to function for a significant period of time (sinus arrest), another part of the conduction system usually assumes the role of pacemaker. These pacing beats are referred to as escape beats and may come from the atria, the atrioventricular junction, or the ventricles.



**Sick Sinus Syndrome:** In elderly people, the sinus node may undergo degenerative changes and fail to function effectively. Periods of sinus arrest, sinus tachycardia, or sinus bradycardia may occur. It may be caused by age or coronary artery disease.

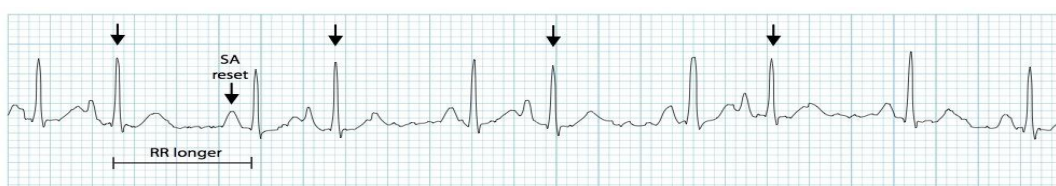

**Sick Sinus Syndrome**

## **ATRIAL ARRHYTHMIAS**

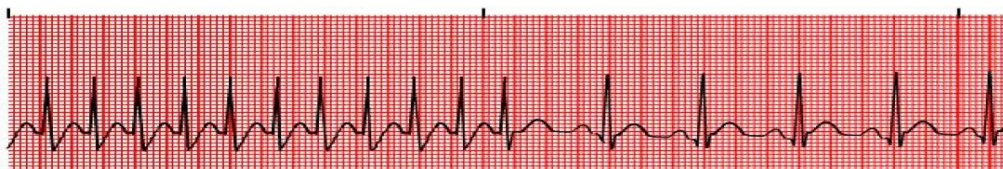
Include premature atrial beats, paroxysmal atrial tachycardia, multi-focal atrial tachycardia, atrial flutter, and atrial fibrillation. Because the stimuli arise above the level of the ventricles, the QRS pattern usually is normal.

**Premature Atrial Contraction (PAC):** An ectopic beat arising somewhere in either atrium but not in the sinoatrial node. Occurs before the next normal beat is due, and a slight pause usually follows. The P wave may have a configuration different from the normal P wave and may even be of opposite polarity.

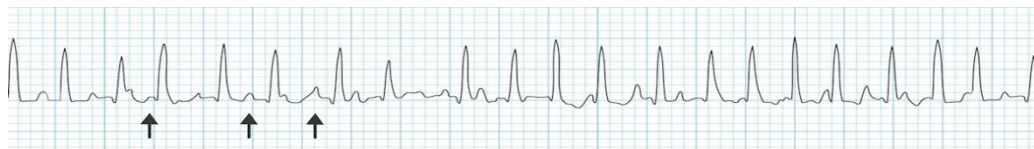

Occasionally, the P wave will not be seen because it is lost in the preceding T wave. The P-R interval may be shorter than the normal. If the premature atrial depolarization wave reaches the AV node before the node has had a chance to repolarize, it may not be conducted, and what may be seen is an abnormal P wave without a subsequent QRS complex. These premature atrial depolarization waves may be conducted to ventricular tissue before complete repolarization has occurred, and in such cases, the subsequent ventricular depolarization may take place by an abnormal pathway, generating a wide, bizarre QRS complex.

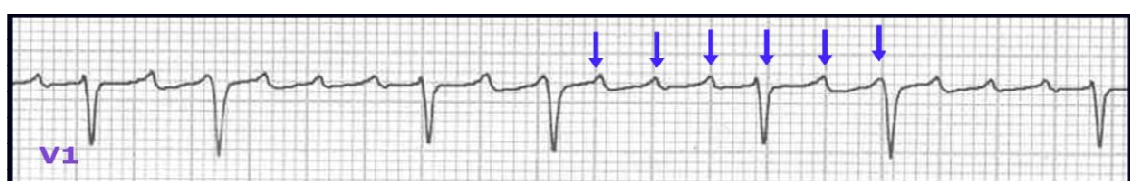**Paroxysmal Atrial Tachycardia (PAT):** Defined as three or more consecutive PACs. PAT usually occurs at a regular rate, most commonly between 150 and 250 beats per minute. P waves may or may not be seen and may be difficult to differentiate from sinus tachycardia.



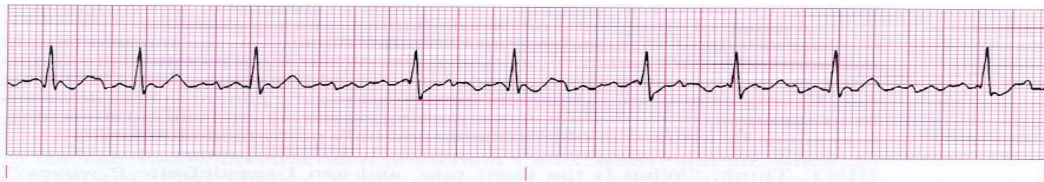**Multi-Focal Atrial Tachycardia (MFAT):** Results from the presence of multiple, different atrial pacemaker foci. This rhythm disturbance is characterized by a tachycardia with beat-to-beat variation of the P wave morphology.



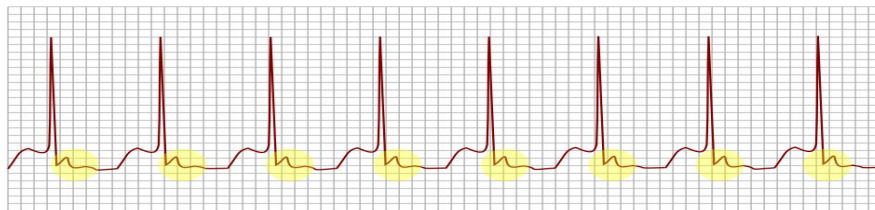
**Atrial Flutter:** An ectopic atrial rhythm. Instead of P waves, characteristic sawtooth waves are seen. The atrial rate in atrial flutter is usually about 300 beats per minute. However, the AV junction is unable to contract at this rapid rate, so the ventricular rate is less-usually 150, 100, 75, and so on, beats per minute. Atrial flutter with a ventricular rate of 150 beats per minute is called a two-for-one flutter because of the ratio of the atrial rate (300) to the ventricular rate (150).



**Atrial Fibrillation:** Here the atria are depolarized at an extremely rapid rate, greater than 400 beats per minute. This produces a characteristic wavy baseline pattern instead of normal P waves. Because the AV junction is refractory to most of the impulses reaching it, it only allows a fraction of them to reach the ventricles. The ventricular rate, therefore, is only 110-180 beats per minute. Also characteristic of atrial fibrillation is a haphazardly irregular ventricular rhythm.



**Atrioventricular Nodal Reentrant Tachycardia:** It is a common type of supraventricular tachycardia. It accounts for the many of the fast heart rate that start in the upper part of the heart. AVNRT can cause symptoms of any age. It typically is not a result of other forms of heart disease. It is caused by an abnormal or extra electrical pathway in the heart a kind of “short circuit”.



## **JUNCTIONAL RHYTHMS**

The three types of junctional rhythms are premature junctional contractions, junctional tachycardia, and junctional escape rhythms. Junctional rhythms arise in the AV junction. P waves, when seen, are opposite their normal polarity. They are called retrograde P waves. These P waves may precede, be buried in, or follow the QRS complex. Since the stimulus arises above the level of the ventricles, the QRS complex is usually of normal configuration.

**Premature Junctional Contractions:** Can occur since the AV junction may also serve as an ectopic pacemaker. These are similar to PACs, in that they occur before the next beat is due and a slight pause follows the premature beat.

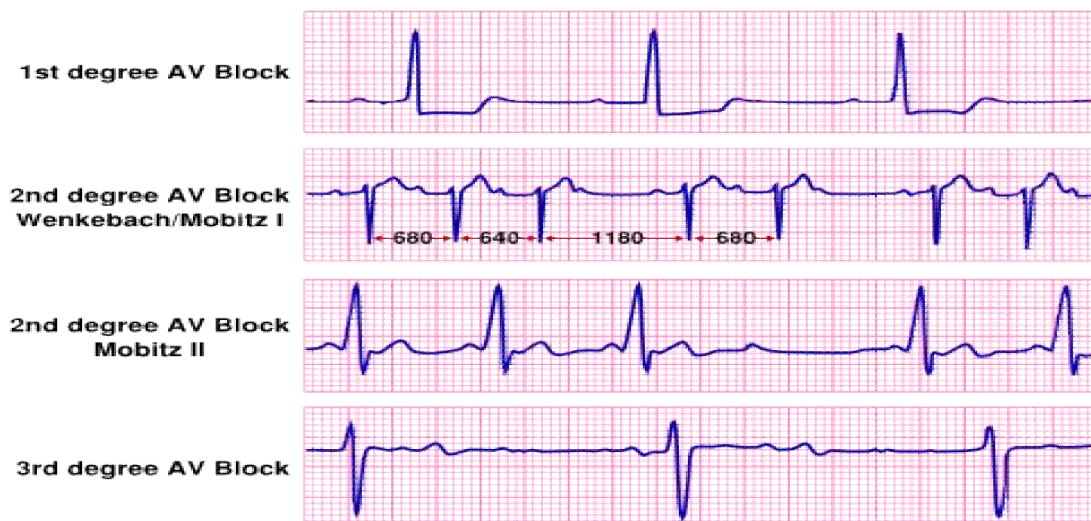**Atrioventricular Junctional Tachycardia:** A run of 3 or more premature junctional beats. Has about the same rate as PAT and often cannot be distinguished from it. The difference is not clinically significant.

**Atrioventricular Junctional Escape Beat:** An escape beat that occurs after a pause in the normal sinus rhythm. Atrial pacing usually resumes after the junctional beat. A junctional escape rhythm, defined as a consecutive run of atrioventricular junctional beats, may develop if the SA node does not resume the pacemaker role. Junctional escape rhythm has a rate between 40 and 60 beats per minute.

## **ATRIOVENTRICULAR HEART BLOCKS**

Heart block occurs in 3 forms: first degree, second degree, and third degree. Second degree heart block is divided into two types: Mobitz type 1 and Mobitz type 2.

**First Degree Heart Block:** The ECG abnormality is simply a prolonged P-R interval to greater than 0.2 seconds.



**Second Degree Heart Block, Mobitz Type 1:** The characteristic ECG is progressive lengthening of the P-R interval until finally a beat is dropped. The dropped beat is seen as a P wave that is not followed by a QRS complex.

**Second Degree Heart Block, Mobitz Type 2:** A more severe form of second degree block, since it often progresses to complete heart block. The characteristic ECG picture is that of a series of non-conducted P waves; e.g., 2:1, 3:1, 4:1, block.

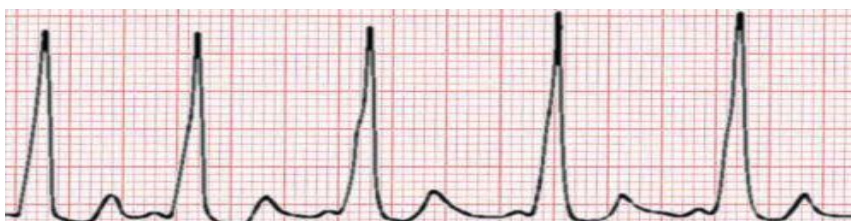**Third Degree Heart Block:** Also known as: Complete Heart Block. The atrioventricular junction does not conduct any stimuli from the atria to the ventricles. Instead, the atria and the ventricles are paced independently. The characteristic ECG picture is: (1) P waves are present and occur at a rate faster than the ventricular rate; (2) QRS complexes are present and occur at a regular rate, usually <60 beats per minute; and (3) the P waves bear no relationship to the QRS complexes. Thus, the P-R intervals are completely variable. The QRS complex may be of normal or abnormal width, depending on the location of the blockage in the AV junction.

## **PRE-EXCITATION SYNDROME**

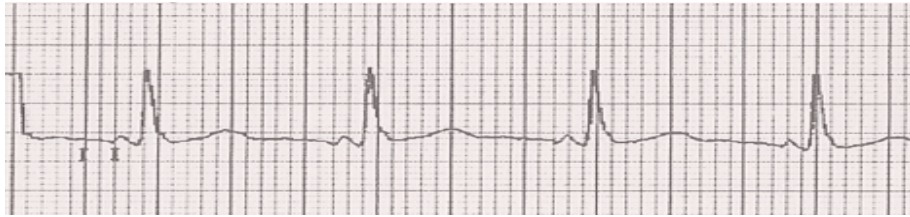
Pre-excitation syndromes refer to clinical Conditions in which the wave of depolarization bypasses the atrioventricular node as it passes from the atria to the ventricles. The time required for the wave to leave the sinoatrial node and arrive at ventricular muscle (P-R interval) is, therefore, shortened. Two pre-excitation syndromes exist (1) the Wolff-Parkinson-White syndrome, and (2) the Lown-Ganong-Levine syndrome.

**Wolff-Parkinson-White Syndrome (WPW):** Patients with WPW possess an accessory pathway of depolarization, the bundle of Kent. Three electrocardiographic criteria for WPW are: (1) a short P-R interval, (2) a wide QRS complex, and (3) a delta wave.

The QRS complex is widened by the delta wave in exactly the same amount as the P-R interval is shortened. The delta wave is a slurring of the initial portion of the QRS complex produced by early depolarization. The major clinical manifestation of WPW is recurrent tachycardia.



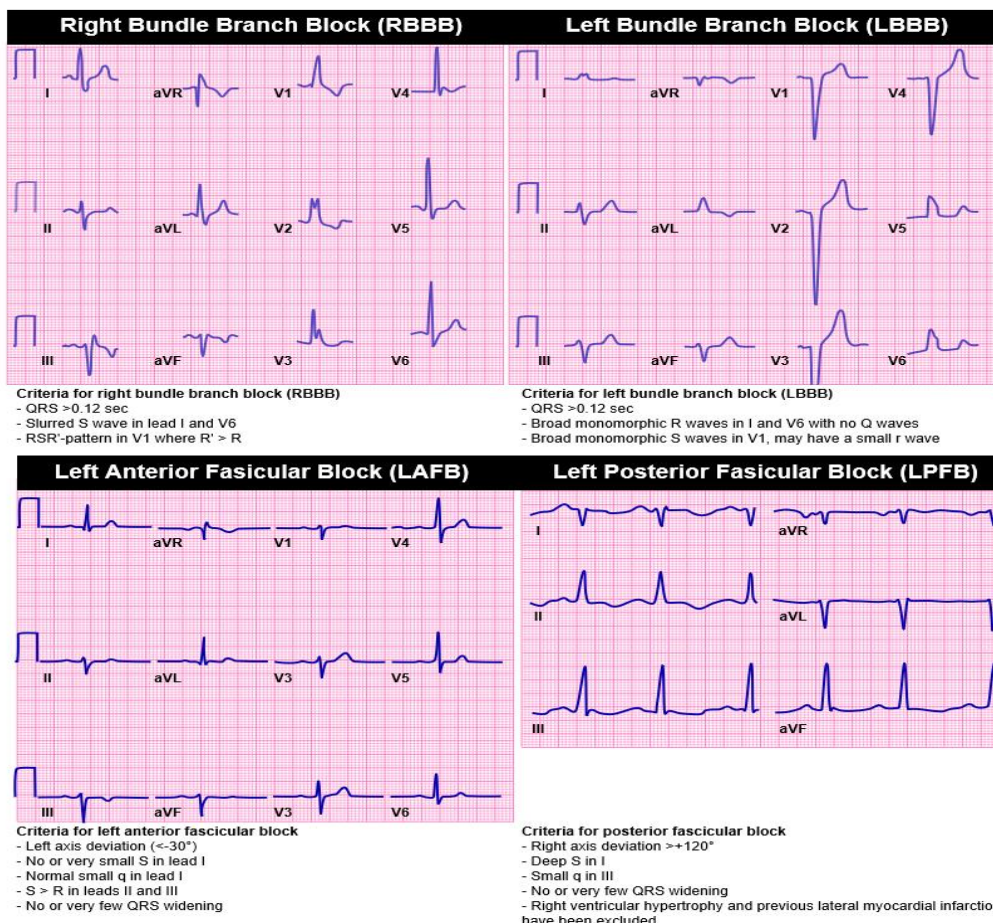
**Lown-Ganong-Levine Syndrome (LGL):** LGL is the result of some of the internodal fibers' (James fibers) bypassing the major portion of the atrioventricular node and terminating in the bundle of His.



The three criteria for LGL are: (1) a short P-R interval without a delta wave, a) a normal QRS, and (3) recurrent paroxysmal tachycardia. It should be noted that, unlike in WPW, episodes of tachycardia are required for the diagnosis of LGL.

## **INTRAVENTRICULAR CONDUCTION DISTURBANCE**

In the normal process of ventricular depolarization, the electrical stimulus reaches the ventricles by way of the atrioventricular (AV) junction. Then the depolarization wave spreads to the main mass of the ventricular muscle by way of the right and left bundle branches. The right bundle branch is undivided, while the left divides into anterior and posterior fascicles. Normally the entire process of ventricular depolarization occurs in less than 0.1 seconds. Any process that interferes with normal depolarization of the ventricles may prolong the QRS width.



**Right Bundle Branch Block (RBBB):** Septal depolarization results in a small R wave in V1. Left ventricular depolarization results in an S wave. Right ventricular depolarization produces a second R wave. The delayed depolarization of the right ventricle causes an increased width of the QRS complex to at least 0.12 seconds. Hence, RBBB is characterized by an R-R1 configuration in lead V1 with a QRS complex > 0.12 seconds. RBBB occasionally can be seen in normal subjects.

**Incomplete RBBB:** This shows the same QRS pattern as a complete RBBB; however, the QRS duration is between 0.1 and 0.12 seconds.

**Left Bundle Branch Block (LBBB):** Blockage of conduction in the left bundle branch prior to its bifurcation results primarily in delayed depolarization of the left ventricle. In LBBB, the septum depolarizes from right to left, since its depolarization now is initiated by the right bundle branch. Next the right ventricle depolarizes, followed by delayed depolarization of the left ventricle, giving an R-R1 configuration in lead V6 and a QRS interval 0.12 seconds. Hence, LBBB is characterized by an R-R1 configuration in lead V6 and a QRS interval > 0.12 seconds. Unlike RBBB, LBBB always is a sign of organic heart disease.

**Incomplete LBBB:** This shows the same QRS pattern as a complete LBBB; however, the QRS duration is between 0.1 and 0.12 seconds.

#### **Fascicular Blocks (hemi-blocks):**

These are blockages of transmission that also may occur in the anterior or posterior branches (fascicles) of the left bundle branch. The main effect of a fascicular block is to markedly change the QRS axis without changing the shape or duration of the QRS wave form.

**Left Anterior Hemiblock:** This results in left axis deviation (-30 degrees or more).

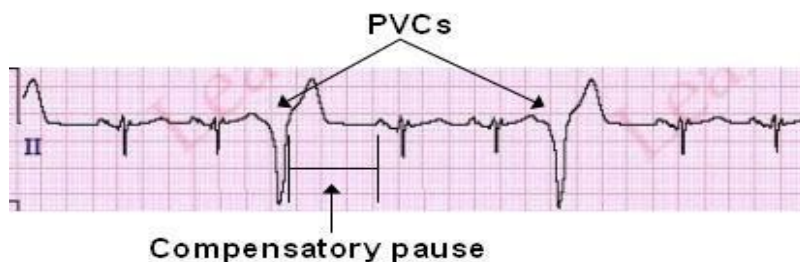
**Left Posterior Hemiblock:** This results in right axis deviation (+90 degrees or more).

### **VENTRICULAR ARRHYTHMIAS**

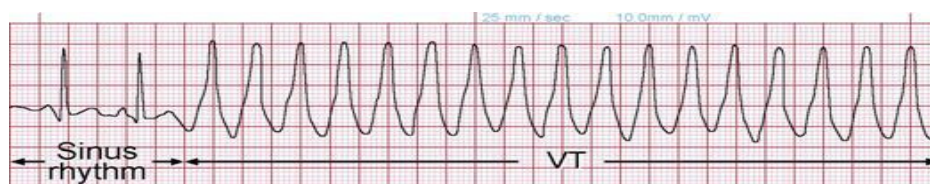
Ventricular tissue is capable of spontaneous depolarization. When this occurs, a premature ventricular contraction (PVC) is initiated. Because the depolarization wave arises in the myocardium, it usually does not follow the normal path of ventricular depolarization. Therefore, the QRS complex is prolonged and bizarre in shape. In addition to PVCs, ectopic ventricular beats produce ventricular

tachycardia and sometimes ventricular fibrillation. Ventricular escape rhythms also occur.

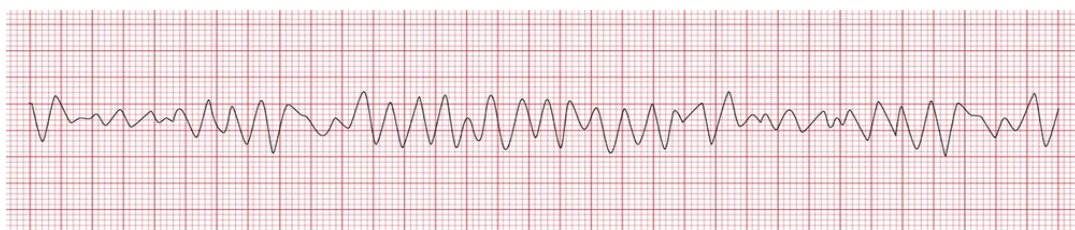
**Premature Ventricular Contractions (PVC):** PVCs are premature beats arising from the ventricles, and are analogous to premature atrial contractions and premature junctional contractions. PVCs have two major characteristics: (1) they are premature and arise before the next normal beat is expected (a P wave is not seen before a PVC), and (2) they are aberrant in appearance. The QRS complex always is abnormally wide; the T wave and the QRS complex usually point in opposite directions. The PVC usually is followed by a compensatory pause. PVCs may be unifocal or multifocal. Unifocal PVCs arise from the same ventricular site, and as a result have the same appearance on a given ECG lead. Multifocal PVCs arise from different foci and give rise to different QRS patterns.



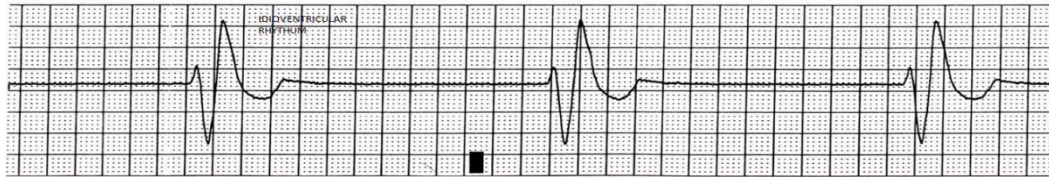
**Ventricular Tachycardia:** This is defined as a run of 3 or more PVCs and may occur in bursts or paroxysmally. They may be persistent until stopped by intervention. The heart rate is usually 120 to 200 beats per minute. Ventricular tachycardia is a life-threatening arrhythmia.



**Ventricular Fibrillation:** This occurs when ventricles fail to beat in a coordinated fashion and, instead, twitch asynchronously. The beats are sometimes divided into coarse and fine rhythms.



**Ventricular Escape Beats:** A ventricular focus may initiate depolarization when a faster pacemaker does not control the rate. They occur after a pause in the regular rhythm. If a higher focus fails to pick up the rhythm, ventricular escape beats may continue. When this occurs, the rhythm is called **idioventricular** and has a rate usually less than 100 beats per minute. The QRS complex is wide and bizarre; P waves will not be present. Idioventricular rhythms are usually of short duration and require no intervention.



IDIOVENTRICULAR RHYTHMS

**Aberrant Ventricular Depolarization:** Here the depolarization wave is initiated above the ventricular level and, because it is premature, reaches the ventricles when they are in a partially depolarized state, resulting in a wide QRS complex. The following rules can be used to determine aberrant ventricular depolarization: (1) the beat is aberrant if a P wave precedes the wide QRS complex, (2) the preceding R-R interval usually is longer than the other ones, (3) most aberrant beats are conducted via the left bundle branch, giving the appearance of right bundle branch block in lead V1, and (4) the initial deflection of the wide QRS is in the same direction as that of the normal QRS complex.

## **ATRIAL ENLARGEMENT**

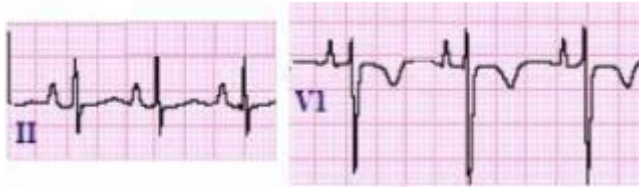
To evaluate atrial enlargement, look at the P waves in leads II and V1. The right atrium generates the left portion of the P wave, the left atrium generates the right as you view the ECG.

**Lead II:** Generally parallel to the axis of the atrial depolarization vector force. Would expect the P wave configuration to be a positive deflection from the baseline that is symmetric to its return to the baseline.

**Lead V1:** Generally closest to the atria and perpendicular to the axis of the atrial depolarization vector force. Would expect first a positive deflection and then a negative deflection from the baseline, resulting in a sinusoidal curve.

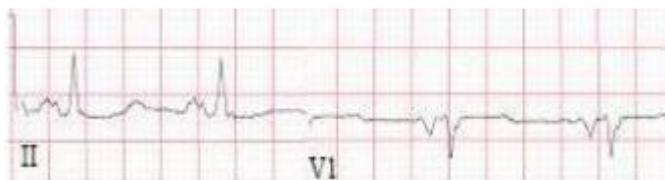
**Right Atrial Enlargement:** Generates an accentuated left-sided portion of the P wave.

#### Right Atrial Enlargement



**Left Atrial Enlargement:** Results in an accentuated right-sided portion of the P wave.

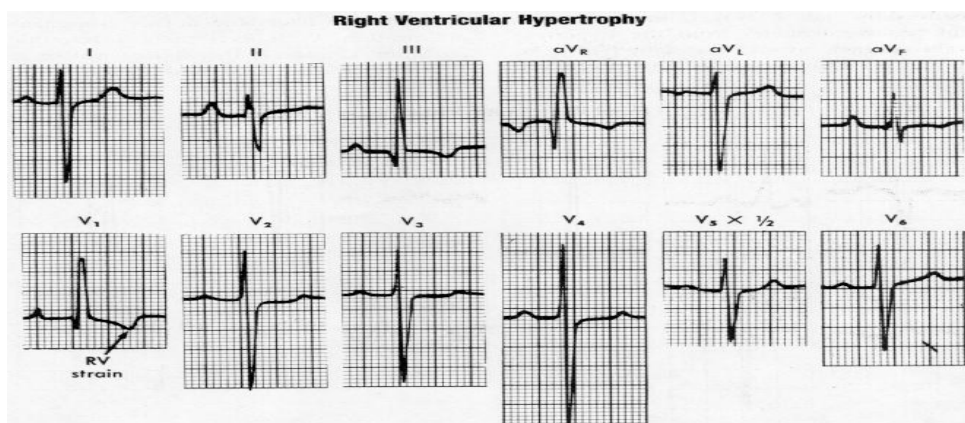
#### Left Atrial Enlargement



### **VENTRICULAR HYPERTROPHY**

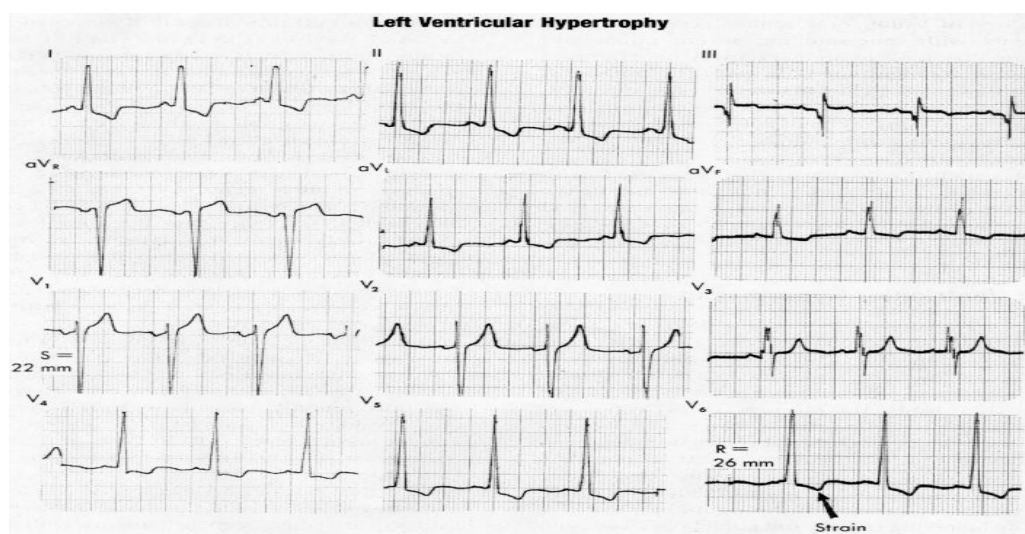
The ECG normally reflects left ventricular depolarization because left ventricular mass is much greater than right ventricular mass.

**Right Ventricular Hypertrophy (RVH):** When right ventricular muscle mass become great enough, it causes alterations in the positivity of the right chest leads. In the absence of myocardial infarction or right bundle branch block, the diagnosis of RVH can be made when right axial deviation is present and when  $R > S$  in lead V1 or  $S > R$  in lead V6.



**RVH with Strain (systolic overload):** In addition to RVH criteria, T wave inversion and usually ST segment depression are present in the right chest leads. (ST segment T wave changes are not present in diastolic overload.)

**Left Ventricular Hypertrophy (LVH):** Hypertrophy of the left ventricle causes an increase in the height and depth of the QRS complexes. LVH is present when the sum of the S wave in V1 and the R wave in V5 or V6 (whichever is larger) > 35 mm. Accuracy in diagnosing LVH can be improved by considering limb lead criteria; i.e., if the sum of the R wave in lead I and the S wave in lead III > 25 mm., LVH is said to be present when either the chest lead criteria or limb lead criteria is met



**LVH with Strain (systolic overload):** In addition to criteria for LVH, T wave inversion and ST segment depression occur in the left chest leads. (ST segment and T wave changes are not present in diastolic overload.)

## **MYOCARDIAL ISCHEMIA**

Due to insufficient oxygen supply to the ventricular muscle. It may be transient, causing angina pectoris, or more severe, causing the death of a portion of heart muscle (myocardial infarction).

**Subendocardial Ischemia:** Produces classic angina and subendocardial myocardial infarction. Involves the inner layer of ventricular muscle.

**Transmural Ischemia:** Produces Prinzmetal's angina and transmural myocardial infarction.

Involves the entire thickness of the ventricular wall.

**Classic Angina:** Produces transient ST segment depression (except in lead aVR, which may show reciprocal ST segment elevation). Not all patients with coronary artery disease show ST segment depression during chest pain.

**Prinzmetal's Angina:** Atypical angina that occurs at rest or at night and results in ST segment elevation. Thought to be caused by transient transmural ischemia due to vasospasm. May occur in individuals with otherwise normal coronary arteries.

## **MYOCARDIAL INFARCTION**

**Transmural Infarction:** The infarcted area remain in a depolarized (negative) state. A normal variant - early repolarization - often occurs in younger individuals and may be confused with myocardial infarction. With early repolarization, however, the T wave is distinct from the elevated ST segment, whereas with myocardial infarction, it is incorporated into it. The loss of positivity in the infarcted area is responsible for the characteristic Q waves that develop in the leads exploring the infarcted area. Keep in mind that a normal ECG may exhibit small Q waves in leads I, V5, and V6 that represent only normal septal depolarization. Q waves, to be considered diagnostic of acute myocardial infarction, must (1) have a duration of at least 0.04 seconds or (2) have a depth equal to 25% or more of the height of the R wave.

**Time sequence of myocardial infarctions:** 3 stages:

(1) acute phase-ST segment elevations generally appear within a few minutes and may last 3 to 4 days. During this period of time, Q waves appear in the leads showing the ST segment elevations.

(2) evolving phase-ST segments begin returning to their baseline, and the T waves become inverted.

(3) resolving phase-In the weeks to months that follow, the T waves again return to the upright position. In most cases, the abnormal Q waves persist for months or even years.

**Localization of Myocardial Infarction:** MIs tend to be localized to left ventricular areas supplied by particular branches of the coronary arteries. They are described by their locations: anterior, inferior, and posterior.

**Anterior Infarction:** Subdivided into strictly anterior, anteroseptal, and anterolateral infarctions.

- **Strictly Anterior Infarction:** Diagnostic changes in V3 and V4.
- **Anteroseptal Infarction:** Results in loss of the normal small septal R waves in V1 and V2 as well as diagnostic changes in V3 and V4.
- **Anterolateral Infarction:** Results in changes in more laterally situated chest leads (V5, V6), as well as left lateral limb leads (I, aVL).

**Inferior Infarction:** Produces changes in the leads that explore the heart from below: leads II, III, aVF.

**Posterior Infarction:** Does not generate Q wave formation or ST segment deviation in the conventional 12-lead ECG since there are no posterior exploring electrodes. Instead, subtle reciprocal changes in the magnitude of R waves in V1 and V2 may occur. In posterior infarction, the R waves in V1 and V2 become taller than or equal to the S waves ( $R/S > 1$ ) Unlike RVH, right axis deviation is not present. ST segment depression also may occur in these leads.

**Subendocardial Infarction:** Affects only repolarization (ST-T complex) and not depolarization (QRS complex). Hence, Q waves are not characteristic of subendocardial infarction. When subendocardial infarction occurs, the ECG may show persistent ST segment depression instead of the transient depression seen with classic angina. Persistent T wave inversion without ST segment depression may occur. The ST-T change slowly returns to normal as the infarction resolves. ECG findings must be combined with the clinical circumstance and cardiac enzymes to make the diagnosis of subendocardial infarction.

**Pseudo Infarction Syndromes:** LBBB and Wolff-Parkinson-White usually have significant Q waves. Left ventricular aneurysm after extensive infarction may show persistent ST segment elevation. Pericarditis may show ST segment elevation and subsequent T wave inversion; however, there is no Q wave formation. Patients with idiopathic hypertrophic subaortic stenosis often may have significant Q waves due to distortion of the normal pattern of depolarization. Dramatic alterations of ST segments and T waves may occur with increased intracranial pressure.

## **PATTERNS CAUSED BY DRUG AND ELECTROLYTE EFFECTS**

The drugs digitalis and quinidine produce major effects on an ECG that have considerable clinical significance. Two electrolytes-potassium and calcium-also produce significant ECG effects.

**Digitalis:** Changes include modification of the ST-T contour, slowing of AV conduction, and enhancement of ectopic automaticity. Digitalis may produce characteristic scooping of the ST-T complex. The ST segment and T wave are fused together, and it is impossible to tell where one ends and the other begins. This may occur when digitalis is in the therapeutic range. With toxicity, digitalis can cause virtually any arrhythmia and all degrees of atrioventricular block.

**Quinidine:** Increases repolarization time and, hence, prolongs the Q-T interval. In toxic doses, may widen the QRS complex and cause ST segment depression.

**Potassium:** Hyperkalemia produces tall, peaked T waves, widening of the QRS complex, and prolongation of the P-R interval. Hypokalemia produces flattening of the T waves, which may unmask U waves. T waves may become inverted, and ST segment depression may occur.

**Calcium:** Hypercalcemia shortens ventricular repolarization time, resulting in a shortened Q-T interval. Hypocalcemia prolongs the Q-T interval.

## **NON-SPECIFIC ST-T WAVE ABNORMALITIES**

Non-specific abnormalities of the ST-T wave segment are diagnosed when the repolarization complex is abnormal but does not indicate a particular diagnosis. Factors such as temperature, hyperventilation, and anxiety can influence the ST-T complex.

## **LOW VOLTAGE COMPLEXES**

Can be caused by pericardial effusion, obesity, diffuse myocardial fibrosis, infiltration of the heart muscle by substances such as amyloid, and hypothyroidism.

# **ECHOCARDIOGRAPHY**

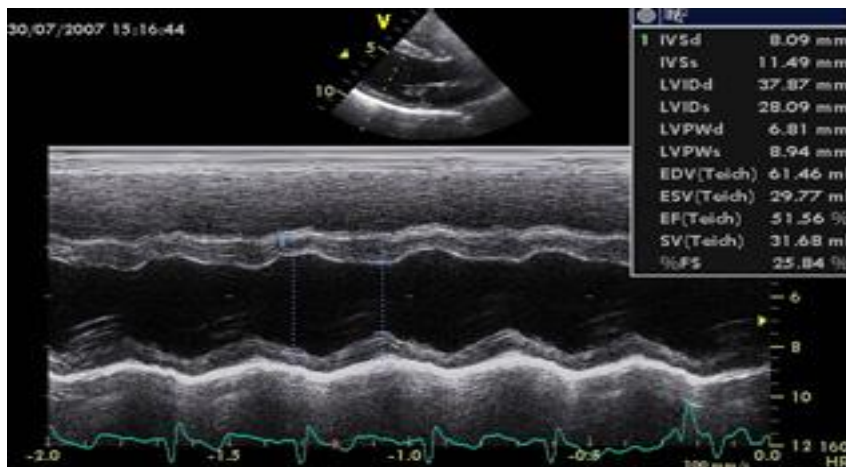
## **PRINCIPLES AND TECHNIQUES OF ECHO**

Ultrasound is sound with a frequency above 20,000Hz cycle per second. This sound is outside of the range of the human ear, diagnostic ultrasound for cardiovascular imaging uses frequencies ranging from 2 to 30 Mhz ; adult transthorasic frequencies range from 2 to 4 MHZ , tansesophagal frequencies from 5 to 7 Mhz ,and intravascular ultrasound frequencies from 20 to 30 Mhz

Sound waves are generated at the transducer, the hand held probe that is applied to the body part of interest. Today, transducers contain a piezoelectric crystal, which when applied to an electric current, will cause the crystal to deform . This deformation results in the generation of a sound wave, which is transmitted to the body. Returning sound waves can also deform the crystal and thus be detected by the transducer .The transducer receives sound waves that are generated from the interaction of the transmitted sound waves and the tissue of the body.

Sound moves through media in the form of waves and may interact with the tissue in different ways, there two of the more common interactions, reflection and attenuation .Reflection occurs when a transmitted sound wave interacts with tissues of different density within the body. Attenuation is degradation of the of the sound wave as it propagates from the transducer .Sound waves pass through tissues and attenuate with greater distances from the transducer. This attenuation results in a finite ability of the transducer to capture reflected sound waves from greater depths. The greater the distance the transducer is from the heart, the greater the number of sound waves that will be attenuated, and the result will be poor image quality. Sound wave attenuation for echo caused by greater depth include obesity and breast tissue, bone and air also result in considerable attenuation.

## M-MODE



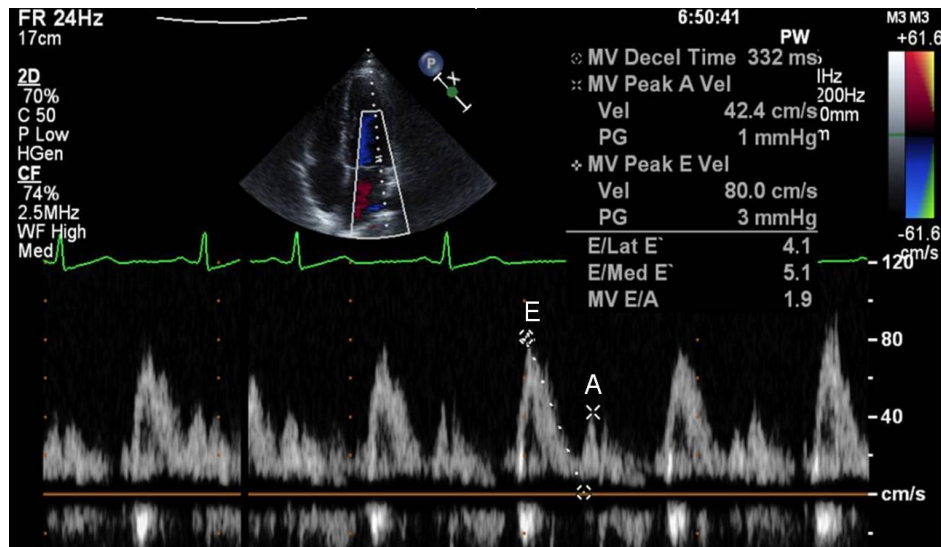
M-mode (motion) echo displays a narrow ultrasound beam of information within the heart along the Y-axis (vertical axis) and displays it according to time on the X-axis (horizontal axis). Heart structures are displayed with respect to motion and time. M-mode echo provides high temporal resolution and provides information regarding both the structure and function of the heart. M-mode echo predated the existence of two-dimensional echo and although it is not as commonly used in the past, M-mode can still be useful to describe motion of structures of the heart with respect to cardiac cycle.

## 2-D

2-D echo was developed from similar concepts of M-mode. Because M-mode only allowed a very narrow and focused area of interrogation of the heart, it was limited, 2-D echo provided a wider area investigation into the structure and function of the heart within a 90-degree scanning sector. Thus, 2-D echo provides a more complete investigation of the entire structure and function of the heart.

## DOPPLER

Doppler affords clinician a powerful and integral tool for assessing heart function. This is based on the Doppler principle. It describes the change in reflected sound wave frequency compared with the transmitted sound wave frequencies generated from the transducer. These sound waves are reflected off of moving red blood cells. This change in frequency is related to the velocity of moving red blood cells through the heart, which can be used to describe the hemodynamics of blood flow through the heart.



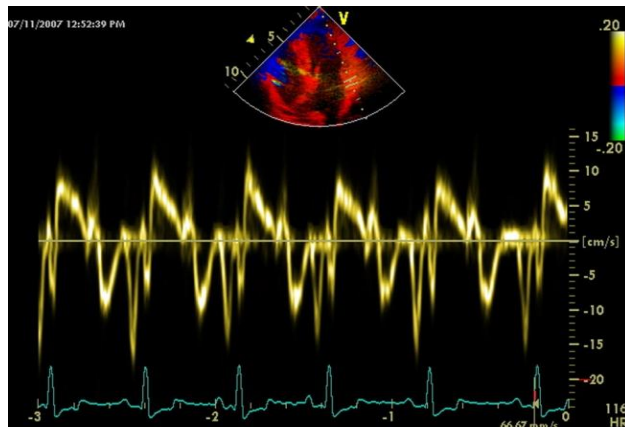
One important feature of Doppler interrogation is the angle of the transmitted frequency as compared to blood flow. To achieve the most accurate estimate of the velocity of blood flow, the angle of the transmitted sound wave should be parallel to blood flow. As the angle increases, so does the error, which results in underestimation of blood flow velocity. Because lungs and bones limit the number of imaging spaces that can be used to interrogate blood flow through the heart.

There are three types of Doppler techniques: pulse wave, continuous wave, and color. Pulse wave Doppler is used for the assessment of blood flow at specific location and is useful for velocities less than 2 m/s. Continuous wave Doppler is used for assessing velocities along the entire pathway of the sound wave and is used for velocities up to 8 m/s. Continuous wave Doppler as its name suggests is continuously transmitting and receiving sound waves using separate crystals. This technique is unlike all other echo techniques, such as 2-D echo, pulse wave Doppler, and color Doppler, which all use the same crystal to transmit and receive sound waves and predominantly spend the majority of time receiving sound waves.

Color Doppler is a pulse wave technique in which multiple points in a specified sector are sampled. Depending upon the direction and turbulence of blood flow, a color is encoded upon a 2-D image. This technique is useful for visualizing the presence of blood flow, the presence of turbulent blood flow, and shunt.

## TISSUE DOPPLER AND STRAIN IMAGING

Tissue Doppler imaging records the motion of tissue or other structures with a velocity or frequency shift much lower than that of blood flow. Doppler echocardiography for blood flow measures the velocities of red blood cells. However, the velocities of myocardial tissues are much lower but with large amplitudes than those produced by blood. Therefore pulsed wave Doppler was modified to record the low velocities of myocardial tissue and to reject the high velocities generated by blood flow. TDI can also be displayed in color mode. A major limitation of tissue velocities recording is that tissue velocities measured by TDI may overestimate or underestimate the active component or function of the tissue because of translational motion or tethering, respectively. Strain and strain rate imaging can overcome this limitation by measuring the actual extend of stretching or contraction.



The clinical application of TDI and strain imaging are increasing and provide incremental diagnostic and prognostic value over standard 2D and blood pool Doppler echocardiography. They have been used successfully in assessing regional and global systolic and diastolic function. Myocardial strain becomes abnormal during the early stage of myocardial ischemia as well as in myopathies and appears to be more sensitive for identifying ischemic segments during stress echocardiography. TDI has been used most commonly to evaluate diastolic function and to estimate diastolic filling pressures. Both strain and tissue Doppler imaging allow reliable determination of cardiac timing intervals, which is useful in assessing cardiac function and LV interventricular mechanical dyssynchrony.

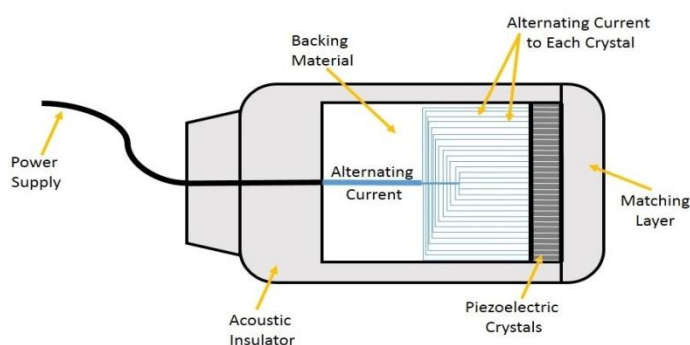
## PATIENT PREPARATION

Transthoracic echo is performed by placing an ultrasound transducer on the patient's chest and images are obtained through the chest wall. The patient is positioned in the left lateral decubites position for the examination and then is moved to the supine position to complete the image set. Occasionally, the patient is positioned in the right lateral decubitus position. Electrocardiogram electrodes are placed on the patients's skin to acquire a continues ECG rhythm. The blood pressure and heart rate should always be recorded at the time of the examination as these measurements affect cardiovascular hemodynamic. Ultrasound waves have significant attenuation through air, a coupling gel is used between the transducer and the patient's skin to eliminate any air.

## AXIS OF THE HEART

The heart situated obliquely in the chest with the apex toward the left. Imaging is not therefore performed in a straight axial or sagittal orientation. Instead, most of the cardiovascular imaging is performed along the axis of the heart and not the axis of the body. There are two standard axes of the heart; long and short. In the long axis views, the heart is imaged from the base to the apex. The short axis of the heart perpendicular to this axis.

## TRANDSUCERS



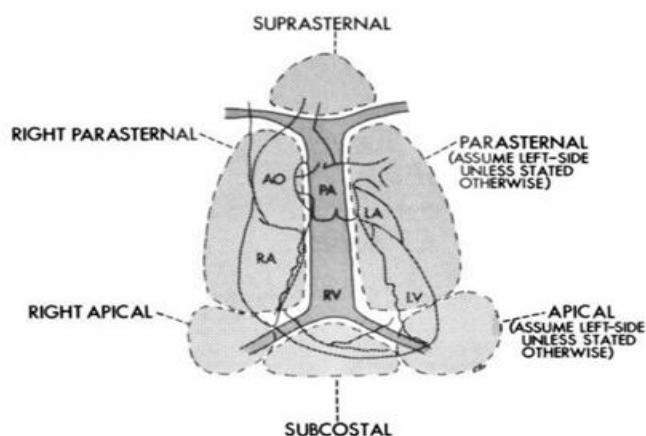
The use of ultrasound for imaging became practical with the development of piezoelectric transducers. Piezoelectric substances or crystals rapidly change shape or vibrate when an alternating electric current is applied. It is the rapidly alternating expansion and contraction of the crystal material that produce the sound waves. Equally important is the fact that a piezoelectric crystals will produce an electric impulse when it is deformed by reflected sound energy. Such piezoelectric

crystals form the critical component of ultrasound transducers. Although a verity of piezoelectric materials exist. Most commercial transducers employ ceramics, such as ferroelectric, barium titan, and lead zirconate titanate.

Ultrasound transducer very small carefully arranged piezoelectric elements that are inter connected electronically. The frequency of transducer is determined by the thickness of these elements. Each element is coupled to electrodes which transmit current to the crystals, and then record the voltage generated by the returning signals. An important component of transducer design is the dampening materials, which shortens the ringing response of the piezoelectric material after the brief excitation pulse. Transducer design is critically important to optimal image creation. The proximal or cylindrical portion of the beam is referred to as the *near field* or Fresnel zone. When it begins to diverge, it is called the **far field** or **Fraunhofer zone**.

Most ultrasound systems are equipped with a selection of transducer with a range of capabilities and limitations. The frequency of transducer used for cardiac imaging often depends on body habitus and patient size. For large patient or thick-chested individuals, a 2.0 or 2.5-MHZ transducer may be necessary to provide adequate penetration. Children and smaller adults can generally be adequately imaged using a 3.5 or 5.0 MHZ transducer. For infants and children, a 7.0 or 7.5 MHZ transducer is often ideal.

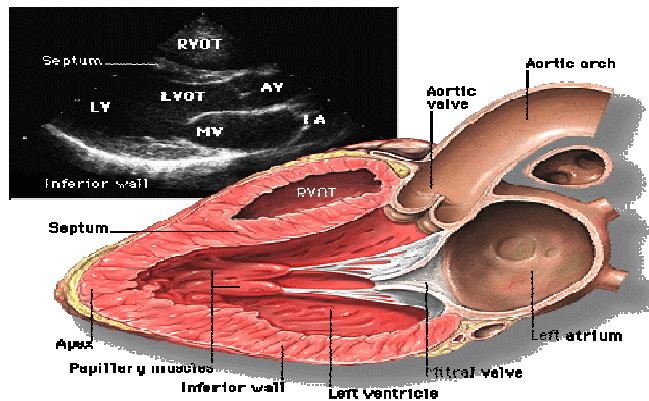
## IMAGING WINDOWS



Ultrasound waves have significant attenuation through air and bone and therefore, care must be taken to avoid the areas over the sternum, ribs, and lungs. Imaging is there by limited to the spaces between the ribs. There are four

standardized anatomic windows for the echo examination and are usually acquired in the following order: parasternal, apical, subcostal and suprasternal

## **PARASTERNAL LONG- AXIS VIEWS**



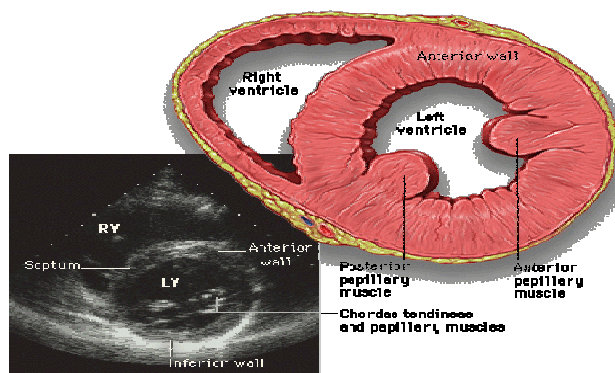
The patient is positioned in the left lateral decubitus position and imaging is performed in the rib spaces left of the sternum. An imaging plane aligned parallel to the long axis of the left ventricle will not, in most cases, be exactly parallel to the left ventricular out flow tract and aortic root. The slight counter clockwise rotation of the transducer is needed to follow the long axis of the left ventricle into the long axis of the aorta. In this illustration, the true dimensions of the proximal aorta are underestimated in the left panel, which shows a properly aligned parasternal long axis view. By slight rotating the transducer , the aortic root is opened up and the true long axis of the aorta is demonstrated. In most patients, some angulations of the scan plane from medial to lateral is required to obtain a complete interrogation of the aortic valve, including the leaflets, annulus , and sinus .

Doppler evaluation of the parasternal long axis view is useful to record blood flow through the mitral aortic valves. Because the flow of blood is not parallel to the ultrasound beam, quantitation of flow velocities generally not possible. However, color flow Doppler from this views is routinely used to detect aortic or mitral regurgitation.

## **PARASTERNAL SHORT- AXIS VIEWS**

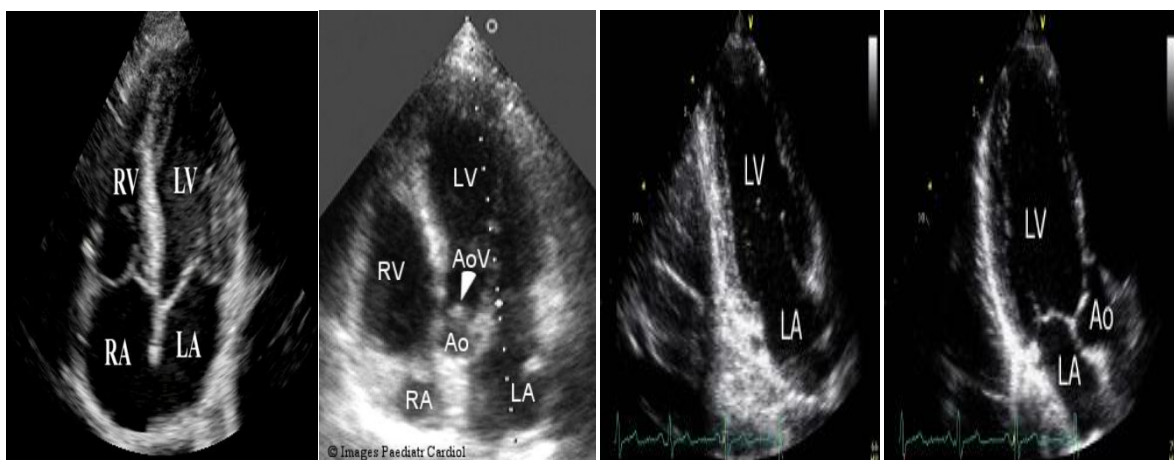
From the parasternal long axis transducer position, clockwise rotation of the transducer approximately 90 degrees moves the imaging plane to the short axis view. By rotating the transducer clockwise, the patient's lateral wall is placed to the observer's right and the medial wall is to the observer's left. A useful reference point

to begin the short axis examination is the tip of the anterior mitral valve leaflet. By rotating the transducer slightly and adjusting the tilt of the plane, the left ventricle can be made to appear circular and both leaflets of the mitral valve will demonstrate maximal excursion. As in all short axis views, the left ventricle is displayed as is viewed from the apex of the chamber. When properly recorded, the short axis view in this plane corresponds roughly to the mid left ventricular level and allows optimal recording of mitral leaflet excursion, mid left ventricular wall motion, and visualisation of a portion of the right ventricle.



Moving to a more basal plane, the short-axis view approaches the level of the aortic annulus and the aortic valve, right ventricular outflow tract, coronary Ostia, left atrium, right atrium, interatrial septum, tricuspid valve, pulmonary valve, and proximal pulmonary artery can also be recorded. By moving the transducer to a lower interspaced and angling the scan plan more apically, the image will sweep through the papillary muscle level and then the left ventricular apex.

## **APICAL VIEWS**

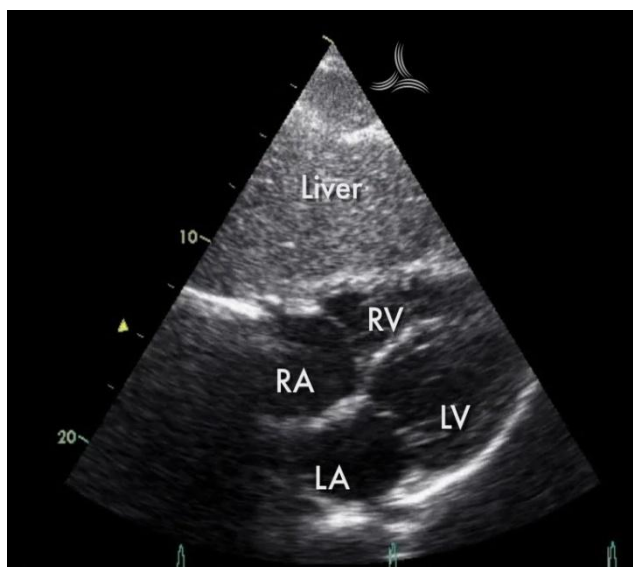


With the patient rotated to the left and the transducer placed at the cardiac apex, a family of long axis images is available. Once the apical window is

located, the transducer is pointed in the general direction of the right scapula and then rotated until all four chambers of the heart are optimally visualized. This occurs when the full excursion of the both mitral and tricuspid valves is recorded and the true apex of the left ventricle lies in the near field. The normal true apex can be identified by its relatively thin walls and lack of motion. When properly adjusted, this image includes the four chambers, both atrioventricular valves, and the interventricular and interatrial septa.

By tilting the transducer into a shallower angle relative to the chest wall, resulting in a more anterior scan plane the left ventricular outflow tract, aortic valve, and aortic root can be recorded. This is frequently referred to as the five chamber view. By rotating the transducer counterclockwise approximately 60 degrees, an apical two chamber view is recorded. If the transducer position is returned to the four chamber orientation and then rotated clockwise 60 degrees, an apical long axis view is recorded, characterized by the presence of both mitral and aortic valves in the same plane.

## **THE SUBCOSTAL EXAMINATION**

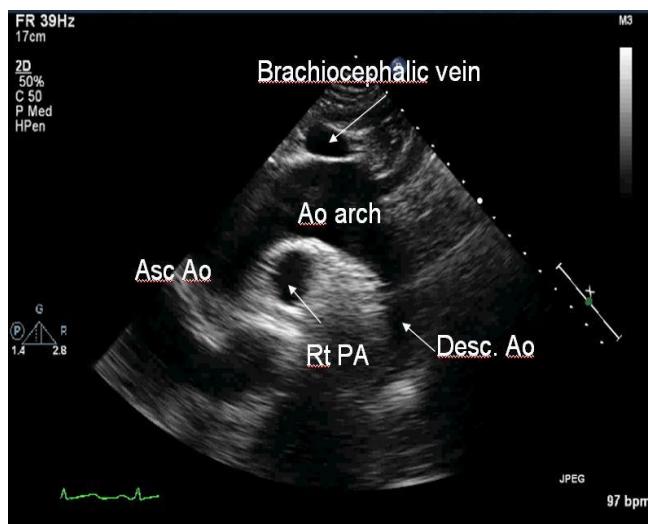


In most patients, placement of the transducer in the subcostal location provides an opportunity to record a four chamber and a series of short-axis planes. First, the ultrasound beam is oriented perpendicular to the long axis of the left ventricular and thus often provides better endocardial definition of the ventricular walls. Second because of the position of the transducer relative to the cardiac apex, fore shortening or inability to visualize the left ventricular apex is more likely from

the subcostal position. Because of the orientation of the interventricular and interatrial septa relative to the scan plane, this view is particularly useful to examine these structures and to search for septal defects.

From the four chamber view, the transducer can be rotated approximately 90 degrees counter clockwise to record a series of short axis images. The plane can usually be adjusted to provide an excellent view of the right ventricular outflow tract, pulmonary valve, and proximal pulmonary artery. The subcostal view is also useful for direct recording of the inferior vena cava and hepatic veins by modification of the short axis plane.

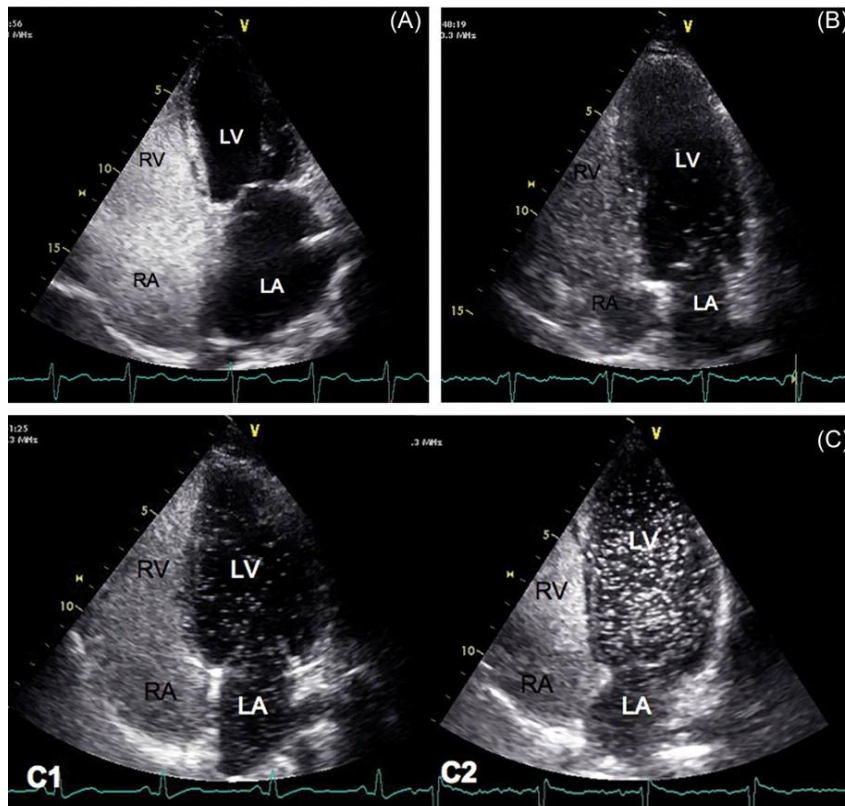
## **SUPRASTERNAL VIEWS**



The primary use of the suprasternal view is to examine the great vessels. When the plane is often possible to visualize both ascending and descending segments of the aorta as well as the origin of the innominate, left common carotid, left subclavin, and right pulmonary arteries. Because of the proximity of the arch to the transducer, a 90 degrees sector may not be wide enough to simultaneously record both ascending and descending segment of the aorta. Angulations of the transducer is necessary for a complete recording in such patients. From this position , the transducer can be rotated 90 degrees to provide the perpendicular plane, which demonstrates the arch in short axis orientation. From ,this view , the right pulmonary artery and left atrium can usually be recorded. By adjusting the scan plane leftward and slightly anteriorly, the superior venacava also be visualized.

## SPECIAL ECHO TECHNIQUES

### CONTRAST ECHO



There are several purposes for the use of contrast in echocardiography . The diagnostic indication will dictate the specific type of contrast. One simple classification system of echo contrast agents is whether the contrast agent crosses the pulmonary vasculature microcirculation. Some contrast agents remain in the venous circulation while others will be in the venous and arterial circulation Echo contrast agents are composed of bubbles. The size of the bubbles determines whether they will cross the pulmonary vasculature microcirculation. Red blood cells cross the pulmonary capillaries

Saline micro bubbles are commonly used for detection of shunts, primarily because the bubbles are too large to cross the pulmonary vasculature microcirculation. Saline micro bubbles are injected into an intravenous catheter and opacify the right side of the heart. Because the micro bubbles are larger than red blood cells , they cannot cross the pulmonary vasculature and are absorbed by the lungs. Therefore they should not opacify the left heart structures. Saline micro bubbles that do appear in the left side of the heart are indicative of a right to left

shunt(ASD,PFO, pulmonary arterial venous malformation). Saline micro bubbles are created by connecting a two-way stopcock to an intravenous catheter with two 10-cc syringes. One syringe is filled with 9-cc of normal saline and 1-cc of air and then transferred to the empty syringe back and forth. This action makes bubbles of air through out the saline . the full 10-cc is then quickly injected into the intravenous catheter. Emphasis is placed on quickly so as to achieve bolus opacification of contrast and not streaming of contrast of the right heart structures .

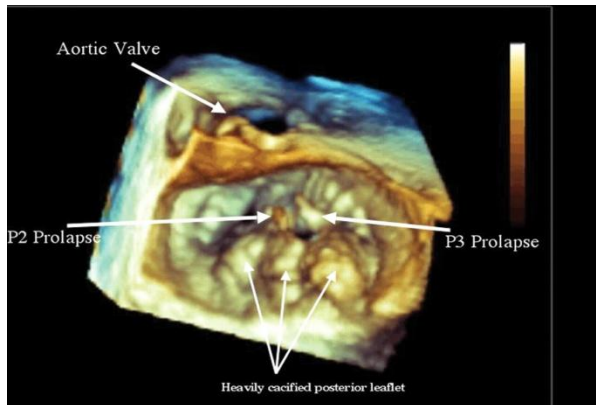
## **STRESS ECHO**

Stress Echo is performed in combination with continuous 12- lead ECG monitoring to improve the diagnostic accuracy of coronary artery detection or risk stratification of patents with known coronary artery disease. Image acquisition is performed in the same standard views as, described previously and optimal endocardial definition is necessary. Sometimes, contrast is needed to provide endocardial definition to visualize wall motion. Global and regional wall motion is compared from rest to stress periods. A normal finding: a myocardial segment has normal normal function at rest and become hypo kinetic or akinetic at stress.

The preferred method of stress testing is exercise, provide the patient is able. With echo, exercise is usually done on a treadmill or supine bicycle. For treadmill exercise, rest images are performed while the patient is lying on the examination bed. The patient then exercise on the treadmill with continues ECG monitoring. When peak exercise is achieved, the patient is quickly moved from the treadmill back to the examination bed and imaging is repeated. This sequencing requires practice and coordination. The longer it takes to perform the imaging after peak exercise, the heart rate decreases and so does the sensitivity of the test. Image acquisition should occur within 60 seconds of the termination of peak exercise.

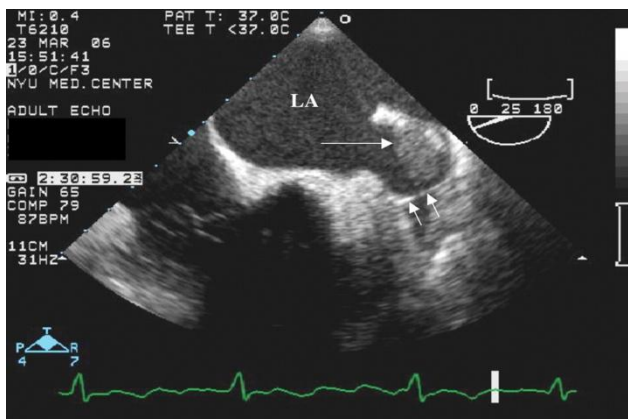
For those patients who cannot exercise, dobutamine is the most common stress agent used; however, it should be understood that dobutamine does not completely simulate the physiological state of exercise. A nurse should be present during dobutamine infusion since medication need to be given intravenously. Starting doses are between 5 and 10mcg/kg/min, increasing by 10 mcg/kg/min increment every 3 minutes to a peak of 40 mcg/kg/min. Doses of atropine can be given and physical manoeuvres can be performed in addition to dobutamine infusion to achieve 85% of the maximal predicted heart rate

### 3-D



3-dimensional echo displays a volume of data within 3 spatial orientations. This field is in much flux and clinical applications of this technique are being investigated. Some applications that may hold promise include improved assessment of ventricular volumes, improved assessment of the valvular apparatus, and improved detection of thrombus within the left atrial appendage. It is important to remember though that the same artifacts and limitations that apply to 2-D echo also applied to 3-D echo.

### TRANSESOPHAGEAL ECHO (TEE)



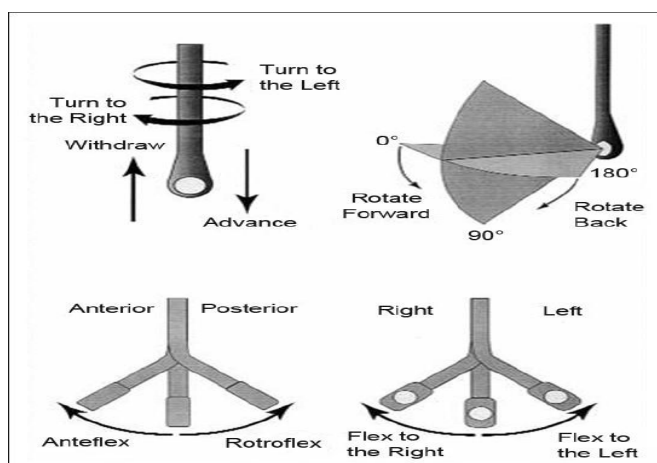
Transesophageal echo uses an imaging crystal placed on the end of a flexible probe that is inserted into the oesophagus and stomach to image the heart. Because the distance between the transducer and the heart is reduced, the spatial resolution of TEE is much improved for some structures of the heart, resulting in superior image quality. Image quality with transthoracic echo is not always of

diagnostic quality and TEE can improve it. The specific clinical circumstances may suggest whether TEE is needed but some indications include aortic dissection, valvular endocarditis, prosthetic valve malfunction, left atrial appendage thrombus, interatrial septal defects, and patent foramen ovale.

TEE is usually performed by physician with the help of sonographers who aid in image acquisition. Depending upon the risk of conscious sedation, a nurse or anaesthesiologist is also present to monitor the patient during the procedure. A detailed patient history should be obtained as there are contraindications to TEE. Dysphagia, esophageal strictures or webs, esophageal or gastric cancer, upper gastrointestinal bleeding, cervical neck trauma, thrombocytopenia, or coagulopathy are some contraindications that require consultation with gastroenterologist first. Anticoagulation with warfarin or heparin is not an absolute contraindication but the internationalized normalized ratio and partial thromboplastin time should be checked beforehand to ensure that supratherapeutic levels are not present. The patient should be fasting postprocedure until there is an appropriate level of consciousness and the local anesthetic of the posterior pharynx has dissipated.

For the procedure, the patient is positioned in the left lateral decubitus position to minimize the risk of aspiration. A topical anesthetic agent is used on the posterior pharynx to suppress the gag reflex, allowing easier passage of the probe into the esophagus. Typically, TEEs are performed under conscious sedation. Conscious sedation requires that heart rate, blood pressure, respiration and arterial oxygen saturation are monitored throughout the procedure. An intravenous catheter is needed to administer analgesics and sedatives.

Risks of TEE include, but are not limited to, aspiration, bronchospasm, respiratory depression, or hypotension from sedation, bleeding and trauma to the teeth, esophagus or stomach such as perforation.



## TRANSESOPHAGEAL VIEWS

VALVE	VIEW	PROBE POSITION	ROTATION ANGLE
Aortic	Long-axis	High oesophageal Transgastric	120-130 90(turn probe to visualize LVOT)
	Short-axis Five chamber	High oesophageal High oesophageal or Transgastric apical	30-50 0(anteriorly angulated)
	3D view	High oesophageal	3D zoomed image to show aortic valve from LV and aortic side with non coronary sinus at bottom of the image
Mitral	Long axis	High oesophageal Transgastric	120-130 90
	Short axis Four chamber	Transgastric High oesophageal or Transgastric	0 with probe flexed 0
	3D view	High oesophageal	3D zoomed image to show mitral valve from LV or LA side with aortic valve at top of the image
Pulmonic	Long-axis Out flow view	Very high esophageal High oesophageal	0(looking straight down PA from bifurcation) 90(turn probe to left)
Tricuspid	Four chamber view	High oesophageal	0
	RV inflow(esophageal) RV inflow(transgastric)	High oesophageal Transgastric	90(turn probe to right) 90(turn probe to right)
LEFT VENTRICLE	Four chamber	High esophageal	0
	Two chamber	High esophageal Transgastric	60 90
	Long axis Short axis	High esophageal transgastric	120 0 with angulation of the probe tip
Left atrium	Four chamber	High esophageal	0 , also allows assessment of all four pulmonary veins with medial and lateral turning and slight angulation of the transducer 60 120
	Two chamber Long axis	High esophageal High esophageal	
Right ventricle	Four chamber RV inflow view	High esophageal High esophageal or Transgastric	0 90 with probe turned toward patient's right side
	Right atrium	Four chamber RA view Low atrial view	0 with posterior angulation to visualize coronary sinus 90 with probe turned toward patient's right side 0 with visualize entry of coronary sinus into RA
Atrial septum	Rotational view	High esophageal	Rotation from 0 to 120, patent foramen ovale often best seen at 90
Aorta	Long axis	High esophageal	Long( 120) and short axis view of aortic sinuses and ascending aorta
	Posterior view of aorta	Trans gastric to high esophageal pull back	Short axis view o pullback along length of descending aorta
Pulmonary artery	RV out flow view	High esophageal	90
	Long axis of PA to bifurcation	Very high esophageal	0

**AMBULATORY  
ELECTROCARDIOGRAPHY  
(HOLTER)**

## **HOLTER MONITORING**

In medicine, a Holter monitor (often simply "Holter" or occasionally ambulatory electrocardiography device) is a portable device for continuously monitoring various electrical activity of the cardiovascular system for at least 24 hours (often for two weeks at a time).

The Holter's most common use is for monitoring heart activity (electrocardiogram or ECG), but it can also be used for monitoring brain activity (electroencephalography or EEG) or arterial pressure. Its extended recording period is sometimes useful for observing occasional cardiac arrhythmias or epileptic events which would be difficult to identify in a shorter period of time. For patients having more transient symptoms, a cardiac event monitor which can be worn for a month or more can be used.

The Holter monitor is named after physicist Norman J Holter, who invented telemetric cardiac monitoring in 1949. Clinical use started in the early 1960s.

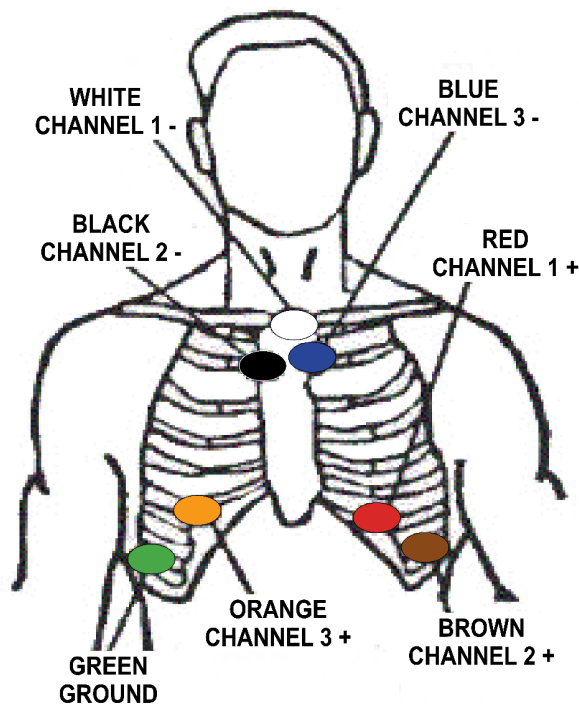
When used for the heart, (much like standard electrocardiography) the Holter monitor records electrical signals from the heart via a series of electrodes attached to the chest. Electrodes are placed over bones to minimize artifacts from muscular activity. The number and position of electrodes varies by model, but most Holter monitors employ between three and eight. These electrodes are connected to a small piece of equipment that is attached to the patient's belt or hung around the neck, and is responsible for keeping a log of the heart's electrical activity throughout the recording period.

## ELECTRODE PLACEMENT CHART 7 -LEAD 3 -CHANNEL

Seven leadwires are utilized to create a three channel ECG recording

- WHITE:** Channel 1 (-). Place at the top of the sternum
- RED:** Channel 1 (+). Place on the left side at the V3 position on a rib
- BLACK:** Channel 2 (-). Place at the top of the sternum, adjacent to the white lead
- BROWN:** Channel 2 (+). Place on the left side at the V5 position on a rib
- BLUE:** Channel 3 (-). Place at the top of the sternum, adjacent to the white lead
- ORANGE:** Channel 3 (+). Place on the right side at the V1 position on a rib
- GREEN:** Ground. Place on the right side opposite V5 position on a rib

**NOTE:** CHANNEL 1 = WHITE (-) RED (+)  
CHANNEL 2 = BLACK (-) BROWN (+)  
CHANNEL 3 = BLUE (-) ORANGE (+)



## **DATA STORAGE**

Older devices used reel to reel tapes or a standard C90 or C120 audio cassette and ran at a 1.7 mm/s or 2 mm/s speed to record the data. Once a recording was made, it could be played back and analyzed at 60x speed so 24 hours of recording could be analyzed in 24 minutes. More modern units record an EDF-file onto digital flash memory devices. The data is uploaded into a computer which then automatically analyzes the input, counting ECG complexes, calculating summary statistics such as average heart rate, minimum and maximum heart rate, and finding candidate areas in the recording worthy of further study by the technician.

## **COMPONENTS**

Each Holter system consists of two basic parts – the hardware (called monitor or recorder) for recording the signal, and software for review and analysis of the record. Advanced Holter recorders are able to display the signal, which is very useful for checking the signal quality. Very often there is also a “patient button” located on the front site allowing the patient to press it in specific cases such as sickness, going to bed, taking pills.... A special mark will be then placed into the record so that the doctors or technicians can quickly pinpoint these areas when analyzing the signal.

## **RECORDER**

The size of the recorder differs depending on the manufacturer of the device. The average dimensions of today’s Holter monitors are about 110x70x30 mm but some are only 61x46x20 mm and weigh 99 g. Most of the devices operate with two AA batteries. In case the batteries are depleted, some Holvers allow their replacement even during monitoring.

Most of the Holvers monitor the ECG just in two or three channels. Depending on the model (manufacturer), different counts of leads and lead systems are used. Today’s trend is to minimize the number of leads to ensure the patient’s comfort during recording. Although 2/3 channel recording has been used for a long time in the Holter monitoring history, recently 12 channel Holvers have appeared. These systems use the classic Masun-Likar lead system, thus producing the signal in the same representation as during the common rest ECG and/or stress test measurement. These Holvers then allow to substitute stress test examination in cases the stress test is not possible for the current patient. They are also suitable when analyzing patients after myocardial infarction. Recordings from these 12-lead monitors are of a significantly lower resolution than those from a standard 12-lead

ECG and in some cases have been shown to provide misleading ST segment representation, even though some devices allow setting the sampling frequency up to 1000 Hz for special-purpose exams like the late potential.

Another interesting innovation is the presence of a triaxial movement sensor, which records the patient physical activity, and later shows in the software three different statuses: sleeping, standing up, or walking. This helps the cardiologist to better analyze the recorded events belonging to the patient activity and diary. Holter monitoring is a very useful part of an ECG.

Some modern devices also have the ability to record a vocal patient diary entry that can be later listened to by the doctor.

### **ANALAZING SOFTWARE**

When the recording of ECG signal is finished (usually after 24 or 48 hours), it is up to the physician to perform the signal analysis. Since it would be extremely time demanding to browse through such a long signal, there is an integrated automatic analysis process in each Holter software which automatically determines different sorts of heart beats, rhythms, etc. However the success of the automatic analysis is very closely associated with the signal quality. The quality itself mainly depends on the attachment of the electrodes to the patient body. If these are not properly attached, electromagnetic disturbance can influence the ECG signal resulting in a very noisy record. If the patient moves rapidly, the distortion will be even bigger. Such record is then very difficult to process. Besides the attachment and quality of electrodes, there are other factors affecting the signal quality, such as muscle tremors, sampling rate and resolution of the digitized signal (high quality devices offer higher sampling frequency).

The automatic analysis commonly provides the physician with information about heart beat morphology, beat interval measurement, heart rate variability, rhythm overview and patient diary (moments when the patient pressed the patient button). Advanced systems also perform spectral analysis, ischemic burden evaluation, graph of patient's activity or PQ segment analysis. Another requirement is the ability of pacemaker detection and analysis. Such ability is useful when one wants to check the correct pacemaker function.

## Characteristics of monitoring modalities

	Recording type	Monitoring period	Event activation	Transmission	Data analysis
Holter monitoring	Continuous, full disclosure	Typically 24-48 hours	Manual	Typically none	Delayed
Loop recorder	Intermittent pre and post-event	Typically up to 30 days	Manual and automatic	Dial-in trans-telephonic	Delayed
Event recorder	Intermittent post-event		Manual	Dial-in trans-telephonic	Delayed
ILR	Intermittent	Upto 3 years	Manual and automatic	Dial-in trans-telephonic	Delayed
MCOT	Continuous, full disclosure	Individualized, upto 3 days	Manual and automatic	Automatic and dial-in wireless	Immediate

ILR- Implantable loop recorder; MCOT- Mobile cardiac outpatient telemetry

### Why the Test is performed:

Holter monitoring is used to determine how the heart responds to normal activity. The monitor may also be used:

- After a heart attack
- To diagnose heart rhythm problems
- When starting a new heart medicine

It may be used to diagnose:

- Atrial fibrillation or flutter
- Multifocal atrial tachycardia
- Palpitations
- Paroxysmal supraventricular tachycardia
- Reasons for fainting
- Slow heart rate (bradycardia)
- Ventricular Tachycardia

**Normal Results:**

Normal variations in heart rate occur with activities. A normal result is no significant changes in heart rhythms or pattern.

**What Abnormal Results Mean:**

Abnormal results may include various arrhythmias. Changes may mean that the heart is not getting enough oxygen.

The monitor may also detect conduction block, a condition in which the atrial electrical activity is either delayed or does not continue into the ventricles of the heart.

**Risks:**

There are no risks associated with the test. However, you should be sure not to let the monitor get wet.

**PRESSURE MEASURING DEVICES****Sensitivity:**

The sensitivity of a measuring system is defined as the ratio of the amplitude of the recorded signal to the amplitude of the input signal. The more rigid the sensing membrane, the lower the sensitivity; conversely the more flaccid the membrane; the higher the sensitivity (Hurtle Manometer). This general principle applies to manometers currently in use.

**STRESS**  
**ELECTROCARDIOGRAM (TMT)**

## **INTRODUCTION**

Exercise is the body's most common physiologic stress, and it places major demands on the cardiopulmonary system. For this reason exercise can be considered the most practical test of cardiac perfusion and function. Exercise testing is a non invasive tool to evaluate the cardiovascular system's response to exercise under carefully controlled conditions.

### **Bayes' theorem:**

'The post test probability is proportional to the pretest probability'

## **BASIC PRINCIPLES**

Two basic principles of exercise physiology are physiologic principle and path physiology

The physiologic principle is total body oxygen and myocardial oxygen uptakes are distinct in their determinants and in the way they are measured are estimated. Total body or ventilator oxygen uptake is the amount of oxygen that is extracted from inspired air as the body performs work. Myocardial oxygen uptake is the amount of oxygen consumed by the heart muscle. Myocardial oxygen uptake estimated by the product of heart rate and systolic blood pressure.

The second principle is the path physiology, considerable interaction takes place between the exercise test manifestations of abnormalities in myocardial perfusion and function.

The electro physiologic response and angina are closely related to myocardial ischemia, where as exercise capacity. Systolic blood pressure and heart rate responses to exercise can be determined the presence of myocardial ischemia.

## **INDICATIONS**

There are many indications for exercise testing which includes

- Evaluation of patient with chest pain
- Determination of prognosis and severity of disease
- Evaluation of the affects of medical and surgical therapy
- Screening for latent coronary disease
- Early detection of labile hypertension
- Evaluation of congestive heart failure

- Evaluation of arrhythmias
- Evaluation of functional capacity and formulation of an exercise prescription
- Evaluation of congenital heart disease

## **CONTRAINDICATIONS**

There are many contraindications for exercise testing which includes absolute contra indication and relative contra indication

Absolute contra indications

- Patient with an acute MI
- Patients suffering from acute myocarditis or pericarditis
- Patients exhibiting signs of unstable progressive angina
- Patients with second or third degree heart block
- Patients with known severe left main disease

Relative contra indications

- Aortic stenosis,
- Suspected left main equivalent
- Severe hyper tension ,idiopathic hypertrophy
- Sub aortic stenosis
- Severe ST segment depression at rest
- Congestive heart failure

## **PROCEDURE**

- Standard 12 lead ECG- leads distally
- Torso ECG + BP
- Supine and Sitting / standing
- HR ,BP ,ECG
- Before, after, stage end
- Onset of ischemic response
- Each minute recovery (5-10 mints)

## **EQUIPMENT NECESSARY IN EXERCISE LABORATORY**

- Treadmill with specially designed electrode and cables
- 12 channel continuous ECG monitor and recorder

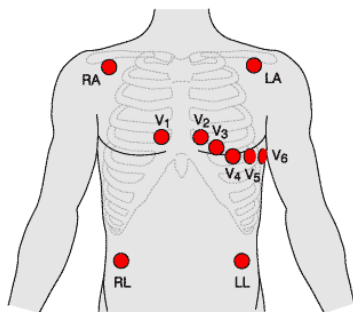
- Sphygmomanometer and stethoscope
- Cardio-pulmonary resuscitative equipments including defibrillator, oxygenator etc
- Emergency drugs

## **PATIENT PREPARATION**

The patient should be instructed not to eat or smoke at least 2 to 3 hours prior to the test and to come dressed for exercise. A brief history and physical examination should be performed to rule out any contra indications to testing .Specific questioning should determine which drugs are being taken, and potential electrolyte abnormalities should be considered.It is generally no longer considered necessary .The patient should receive careful explanations of why the test is being performed and of the testing procedure. Including its risk and possible complications

Proper skin preparation is essential for the performance of an exercise test. The general areas for electrode placement should be shaved if they have hair and should be clean with an alcohol-saturated gauze pad

## **MASON-LIKAR ELECTRODE PLACEMENT**



Because of a 12-lead ECG cannot be obtained accurately during exercise .The electrodes are placed at the base of the limbs for exercise testing. Right and left arm electrodes should be placed far laterally on the edge of the shoulders. The ground electrode can be on the back of the cardiac field and the left leg electrode should be below the ambilicus. The V1,V2 and V4 precordial electrodes should be placed in the appropriate interspaces and V3,V5andV6 aligned according to them.

## HEART RATE

The maximum heart rate with exercise is a fundamental physiologic parameter. The maximum achievable heart rate is unique for each patient but can be estimated by using regression equations that adjust for the patient age, the most familiar equations is  $HR_{max}=220-Age$ .

There is considerable variability with this equations, especially in patients with CAD who are taking beta-blockers, Newer equation is  $HR_{max}=164-(0.7*age)$

## BLOOD PRESSURE MEASUREMENT

Although, numerous devices have been developed to measure the blood pressure during exercise. The time proven method of the physician holding the patients arm with a stethoscope placed over the brachial artery remains the most reliable method to obtain the blood pressure. If systolic BP appears to be increasing slightly or decreasing, it should be taken again immediately, If a drop in systolic BP of 10 to 20mm Hg or more occurs, or if it drops below the value obtained in the standing position prior to testing, the test should be stopped .This is particularly important in patients who have heart failure, a prior myocardial infarction, or are exhibiting signs or symptoms of ischemia. An increase in systolic blood pressure to 115mmHg are also indications to stop the test.

## TREAD MILL PROTOCOL

- Bruce protocol
- Naughton protocol
- Weber protocol
- ACIP(asymptomatic cardiac ischemia pilot)
- Modified ACIP

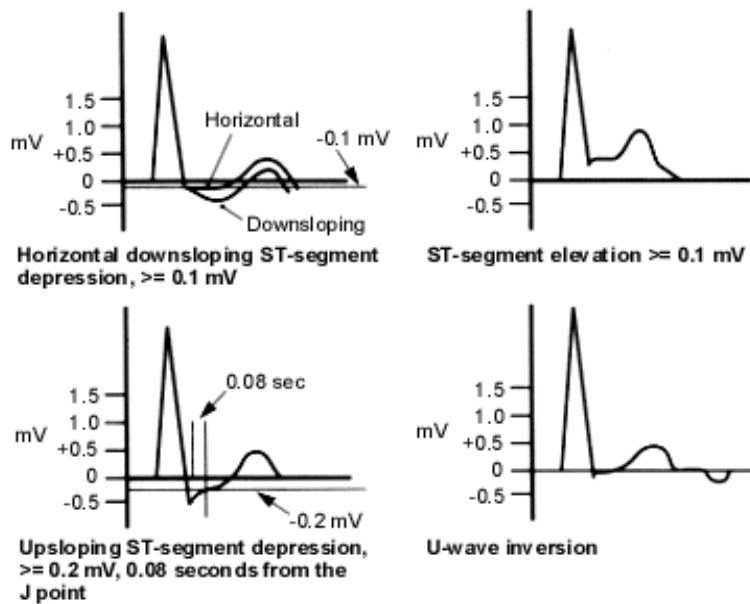
The treadmill protocol should be consistent with the patient's physical capacity and the purpose of the test. In healthy individuals, the standard **Bruce protocol** is popular, and a large diagnostic and prognostic data base has been published using this protocol. The Bruce protocol has 3- minute periods to allow achievement of a steady state before work -load is increased, In older individuals or those whose exercise capacity is limited by cardiac disease, the protocol can be modified by two 3-minute warm-up and 5%grade(**modified Bruce**)

# Bruce Protocol

Stage	Minutes	% grade	km/h	MPH	METS
1	3	10	2.7	1.7	5
2	6	12	4.0	2.5	7
3	9	14	5.4	3.4	10
4	12	16	6.7	4.2	13
5	15	18	8.0	5.0	15
6	18	20	8.8	5.5	18
7	21	22	9.6	6.0	20

## **ELECTROCARDIOGRAPHIC RESPONSES**

In normal persons the PR, QRS and QT intervals shorten as heart rate increases, P amplitude increases, and the PR segment becomes progressively more down sloping in the inferior leads. J point depression is a normal finding during exercise. In patients with CAD, exercise can cause an imbalance between myocardial oxygen supply and demand, which can result in an alteration in the ST segment of the electrocardiogram. These changes are the foundation of the exercise test clinically. The diagnostic electrocardiographic criteria and leads that exhibit abnormalities during exercise have been the source of significant debate.



1.00 mm or greater ST segment depression that is horizontal or downsloping 60 to 80 millisecond after the J-point .ST-segment depression greater than 1 mm that is downsloping is generally indicative of more severe CAD. Most ischemic ST changes occur in the lateral precordial leads .The significance of ST-segment elevation depends on the presence or absence of Q waves. When ST elevation occurs in the presence of resting electrocardiogram, it is usually indicative of severe transmural ischemia ,it can be arrhythmogenic ,and it localizes the ischemia .conversely ,exercise –induced ST-segment elevation occurring in lead with Q waves is more common and is related to the presence of dyskinetic areas .

## **TEST TERMINATION**

### **ABSOLUTE**

- Drop in systolic BP >10mmHg from baseline despite an increase in workload, when accompanied by other evidence of ischemia
- Moderate to severe angina
- Increasing nervous system symptoms
- Signs of poor perfusion
- Technical difficulties in monitoring electrocardiogram or systolic blood pressure
- Subject's desire to stop
- Sustained VT
- ST elevation >=1mm in leads without diagnostic Q waves

## **RELATIVE**

- Drop in systolic BP  $\geq 10$ mmHg from baseline despite an increase in workload, in the absence of other evidence of ischemia
- ST or QRS changes such as excessive ST depression
- Arrhythmias other than sustained VT ,including multifocal PVCs,SVT,triplets of PVCs, heart block or bradyarrhythmias
- Fatigue, shortness of breath ,wheezing ,leg cramps, or claudication
- Development of bundle branch block or intraventricular conduction delay that cannot be distinguished from VT
- Increasing chest pain

## **FALSE POSITIVE AND FALSE NEGATIVE RESPONSES**

The factors associated with false –positive or false – negative responses should also be considered before the test. A false positive response is defined as an abnormal exercise test response in a person without significant heart disease and causes the specificity to be decreases. A false negative response occurs when the test is normal in person with disease and causes the sensitivity of the test to be reduced

### **False – Positive**

- Resting repolarisation abnormalities ,cardiac hypertrophy ,accelerated conduction defects
- Digitalise
- Non ischemic cardiomyopathy ,hypokalemia ,vasoregulatory abnormalities ,mitral valve prolapse
- Pericardial disease ,coronary spasm in the absence of CAD,anemia female gender

### **False – Negative**

- Failure to reach ischemic threshold secondary to medications
- Monitoring an insufficient number of leads of leads to detect ECG changes
- Angiographically significant disease compensated by collateral circulation
- Musculoskeletal limitations preceding cardiac abnormalities

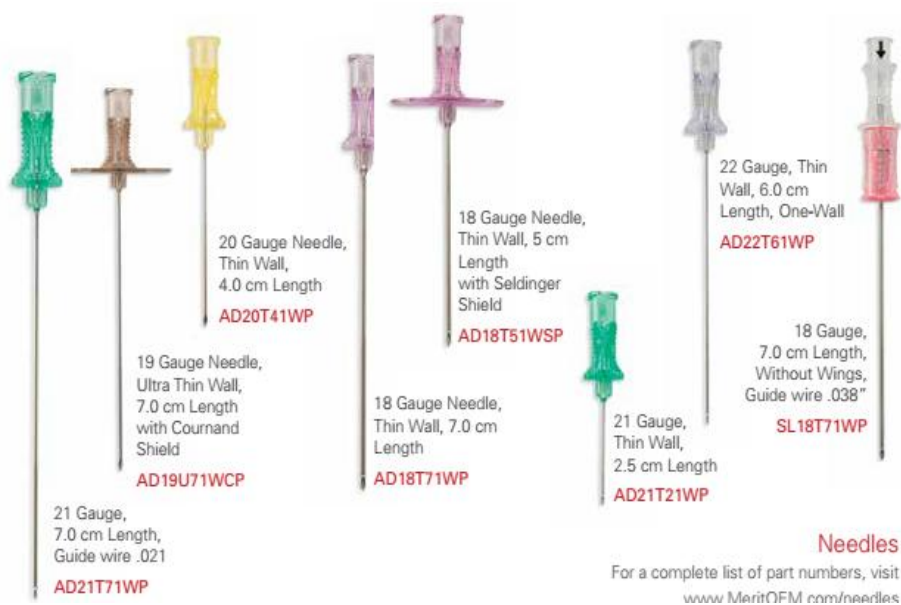
# **HARDWARES**

## TOOLS FOR CATHETERIZATION

Tools for catheterization, for either diagnostic or monitoring purposes consists of catheters, guidewires, needle, introducers, transducers, and protective sleeve adaptors.

### VASCULAR ACCESS NEEDLE

Percutaneous vascular access into either the artery or the vein is gained via introduction of a needle. Percutaneous cannulation needles frequently referred to as Seldinger needle. Vascular needles are constructed of rigid stainless steel with a bevelled tip possessing two sharp cutting edges. This type of point aids in puncturing the vessel and smoothly sliding through it. Percutaneous entry needles can be categorized according to the number of parts: One-part needle, Two-part needle and Three-part needle.



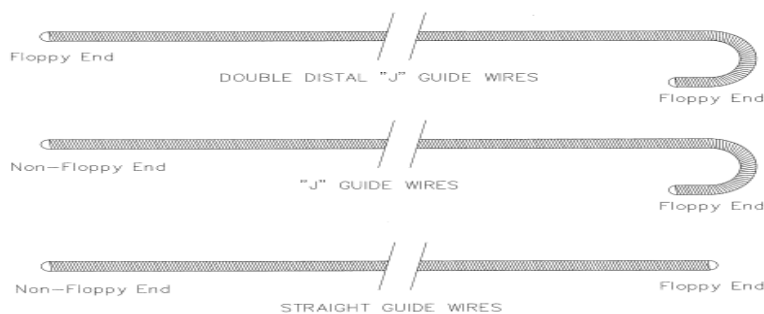
**Sizes:** The size of a needle is measured in needle gauge, which refers to outside diameter.

**Types:** Reusable stainless needles, such as the Courmand, Riley, and Potts-Courmand needles have been traditionally used in the cardiac catheterization laboratory for percutaneous cannulation of the femoral or brachial artery or vein. The peel-away needle is used most commonly for transvenous pacemaker insertion into the subclavian vein.

## GUIDEWIRES

Guidewires are very delicate devices used in cardiac catheterization to straighten a catheter curve, traverse vessels, and permit percutaneous insertion of an introducer or catheter. Guidewires are constructed of the stainless steel. Some guidewires are also coated a thin film of Teflon to reduce the friction coefficient of the guidewire within the catheter. Some Glidewire is a hydrophilic coated guidewire. The Terumo Glide Technology hydrophilic coating allows smooth and rapid movement of the guidewire through tortuous vessels, and it enables crossability over difficult lesions. It is able to resist kinks and retains its shape for consistent reliability. It has a 1:1 torque ratio and enhanced radiopacity.

Guidewires basically are of two shapes, straight and 'J' curve, and may have either a fixed or movable core.



**Straight guidewire:** It has a flexible tip (generally 3 cm) and is appropriate for passage through vessels of linear configuration.

**J-Curve guidewire:** It has generally a 1.5, 3, or 6 mm curved radius at its tip. Use of the J-curve guidewire for negotiating the external jugular vein has been associated with a higher incidence of successful passage than the use of a standard straight wire.

**Fixed core guidewire:** It is a type of guidewire with a rigid core that is fixed at the proximal end of the wire but is usually unattached at the distal end.

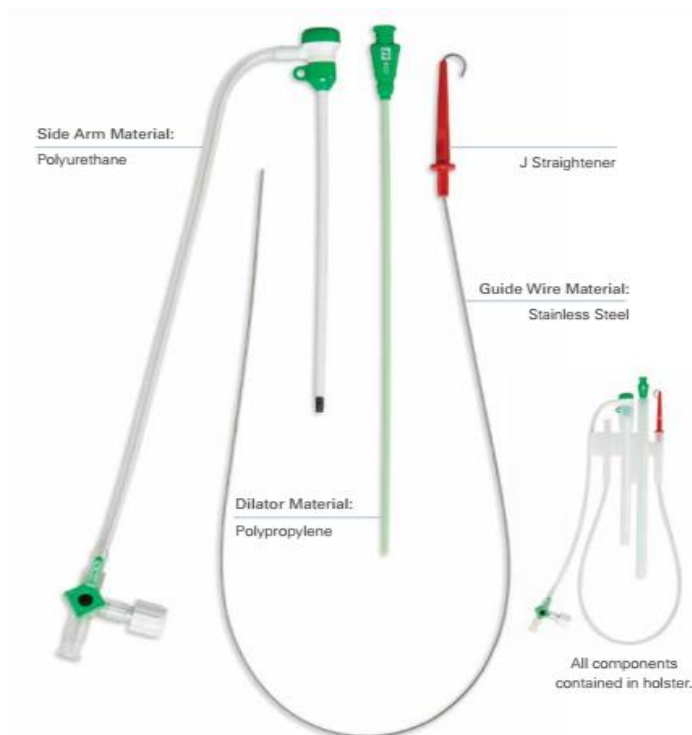
**Movable core guidewire:** Guidewires that have the straight core attached only at the distal end are designed to allow movement of the tip of the core for the purpose of increasing or decreasing the length of flexible tip.

**Sizes:** Most guidewires are available in sizes ranging from 0.018 to 0.038 inch (0.4 to 1.0 mm).

Guidewires are available in length varying from 50 to 300 cm. In cardiac catheterization laboratory, a 145 cm long guidewire is commonly used.

**Desired features:** Important considerations in guidewire selection include stiffness, flexibility, and smoothness.

## SHEATHS AND DILATOR



Vascular sheaths generally contain a removable dilator, a diaphragm that prevents leakage of blood or air into the sheath, and a sidearm connected to a three-way stopcock, which allows the operator to record pressure measurements, flush the sheath, and infuse medications. The dilator is made up of stiff plastic that allows it to pass through fibrous subcutaneous tissue or atherosclerotic/calcified vessel. For femoral and brachial diagnostic catheterizations, 7F, 6F and 5F catheter sheaths are most commonly used. For radial cases 4F or 5F or 6F catheter sheath, although larger sized sheaths are sometimes used in interventional cases.

The length of sheath used routinely varies from 6 to 35 cm. For most cases, an 11 cm sheath is adequate. Longer sheaths of 25 to 35 cm are selected when one encounters tortuous femoral and iliac arteries to facilitate torque control of the diagnostic catheter.

## **FRENCH CATHETER SCALE**

The French catheter scale (most correctly abbreviated as Fr, but also often abbreviated as FR or F) is commonly used to measure the outer diameter of cylindrical medical instruments including catheters, needles etc. In the French Gauge system as it is also known, the diameter in millimeters of the catheter can be determined by dividing the French size by 3, thus an increasing French size corresponds with a larger diameter catheter. The following equations summarize the relationships:

$$D \text{ (mm)} = \text{Fr}/3 \text{ or } \text{Fr} = D \text{ (mm)}*3$$

$$1 \text{ Fr} = 0.335 \text{ mm or } 0.013 \text{ inches}$$

### **Size specification for cardiovascular catheter**

Size (Fr)	Inside diameter		Outside diameter	
	Inch	Mm	Inch	mm
<b>Standard wall</b>				
<b>4</b>	0.018	0.46	0.052	1.33
<b>5</b>	0.026	0.66	0.065	1.67
<b>6</b>	0.036	0.91	0.078	2.00
<b>7</b>	0.046	1.17	0.091	2.33
<b>8</b>	0.056	1.42	0.104	2.67
<b>9</b>	0.064	1.63	0.118	3.00
<b>10</b>	0.072	1.83	0.131	3.33
<b>11</b>	0.083	2.11	0.144	3.67
<b>12</b>	0.094	2.39	0.157	4.00
<b>14</b>	0.144	2.90	0.183	4.67
<b>Thin wall</b>				
<b>4</b>	0.023	0.58	0.052	1.33
<b>5</b>	0.034	0.86	0.065	1.67
<b>6</b>	0.046	1.17	0.078	2.00
<b>7</b>	0.058	1.47	0.091	2.33
<b>8</b>	0.068	1.73	0.104	2.67
<b>9</b>	0.078	1.98	0.118	3.00
<b>10</b>	0.088	2.24	0.131	3.33
<b>11</b>	0.098	2.49	0.144	3.67
<b>12</b>	0.108	2.74	0.157	4.00
<b>14</b>	0.128	3.25	0.183	4.67

## **CATHETERS**

A catheter is a hollow flexible tube that can be inserted into a body cavity, duct or vessel. Catheters thereby allow injection of fluids. The process of inserting a catheter is catheterization.

The ideal catheter is one that provides the most accurate information (hemodynamic pressure and angiographic opacification) with no risk to the patient. Some basic design features that are important for successful catheterization include material used, curve, shape, flexibility, memory, catheter tip, end and side holes, catheter hub, and radiopacity.

### **MATERIAL**

**Dacron:** Catheter made of woven Dacron are very maneuverable and flexible. Most woven Dacron catheter are covered with a polyurethane coating to increase surface smoothness and reduce vascular trauma. Examples: Goodale-Lubin catheter, and Sones catheter.

**Polyurethane:** Catheters extruded from polyurethane have an excellent tensile properties memory (they recover their original shape well at body temperature). Which reduce the vascular trauma or perforation. Polyurethane can be reshaped if immersed in boiling water or exposed to steam for varying periods of time, depending on wall thickness. Examples: pigtail angiographic catheters and the original Judkins coronary catheters.

**Polyethylene:** Polyethylene is utilized in both performed and custom-made catheters. Its degree of stiffness lies somewhere between the stiffness of polyurethane and that of Teflon. Because polyethylene dose not soften much at body temperature, it also maintains its shape and thus is very popular for selective catheterization. Examples: National institute of health catheter (NIH), Cournand catheter.

**Teflon:** Teflon catheters are stiffest vascular catheters. The advantage of is its extremely low friction coefficient, which reduces vascular trauma, increases ease of insertion and passage, and improves flow rates of contrast media. Examples: Introducer sheath.

**Polyvinylchloride:** PVC catheters are softer than catheters of the aforementioned materials. This characteristic makes the material quite supple and flexible and

therefore ideal for flow directed catheters. PVC has a high friction coefficient. Examples: Flow directed catheters

### **CURVE SHAPE**

The curve shape of catheter tip is an important consideration in catheters used for selective angiographic studies. Performed catheters are available in an array of primary and secondary curvatures to facilitate selective placement and positional stability of the catheter. A nonspecific, gentle curve in performed catheters is adequate for many purposes, including pressure measurements and nonselective catheter placement.

### **FLEXIBILITY**

The construction of the catheter determines its flexibility and the safety and ease with which it can be manipulated. The ability to finely control the rotation or torque of the catheter's tip by manipulation of the catheters hub is an essential feature for successful selective catheterization.

### **MEMORY**

Memory is the ability of the catheter to resume or keep its original performed shape and is a function of the material used in catheter construction. Catheters with performed curves often must be straightened with a guidewire to permit passage through the vascular system. It is important that upon removal of the guidewire, the catheter resumes its original performed curve.

### **TIP**

The catheter tip should be neither blunt nor too sharp and should be soft and flexible. Catheters with a slightly tapered ("bullet-nose") tip produce the least amount of trauma during insertion and reduce the risk of vascular dissection, which can occur with the passage of blunt-tip catheter.

### **END AND SIDE HOLES**

Most multipurpose cardiac catheters have an end hole at the tip of the catheter, permitting percutaneous introduction over a guidewire. Although the presence of an end hole at the tip of the angiographic catheter allows more complete flushing of the catheter, thus reducing the risk of thrombus formation at the tip, the absence of an end hole ( with only side holes) reduces the risk of intramural injection of contrast medium and catheter recoil during angiography.

## **HUB**

Whether the catheter hub is made of plastic or material, it should not be significantly smaller than the lumen of the catheter. Tapered hubs permit easier insertion of a guidewire.

## **SIZES**

**Diameter:** The outside diameter of cardiac catheter continues to be measured in French (Fr) gauge (1 Fr = 0.335 mm). The inside diameter of the catheter will vary depending on the thickness of the catheter wall.

The catheter size selection represents a compromise between use of the largest size possible for more accurate pressures and faster delivery of large boluses of dye and use of the smallest size possible to reduce the risk of vascular trauma, thrombus formation, or bleeding.

## **LENGTH**

Catheter length selection is determined by the insertion site and the desired eventual location of the catheter tip. In general, the catheter should be no longer than necessary to reach the intended location. Right heart catheters for adult are generally 100 to 125 cm long, with a shorter catheter suitable for internal jugular vein insertion. Left heart catheters are generally 100 to 110 cm long; this is usually sufficient for placement of the catheter tip in the left ventricle via the femoral artery approach.

## **DIAGNOSTIC RIGHT HEART CATHETERS**

### **COURNAND CATHETER**

Originally designed by Andre Cournand in 1939. The Cournand catheter is a standard wall, end-hole radiopaque woven Dacron catheter with an outer coating of polyurethane. This is an all purpose right heart catheter. Te Cournand catheter is available in sizes 5 through 8 Fr, with 100 and 125 cm length.

### **LEHMAN CATHETER**

The Lehman catheter is a thin wall variation of the Cournand catheter with a slightly shorter distal curve. Its thinner wall increases the inside diameter of the catheter and decreases its stiffness. It is reusable.

## **GOODALE-LUBIN CATHETER**

The Goodale-lubin is constructed of woven Dacron coated with polyurethane. Unique characteristics are the two laterally opposed side holes near the distal open end. It is reusable. The Goodale-Lubin catheter is a standard catheter used in cardiac catheterization laboratory for routine right heart pressure measurements and blood sampling. It available in sizes 4 through 8 Fr, with 80, 100, and 125 cm lengths.

## **BALLOON FLOTATION CATHETER**

Balloon flotation catheters are PVC, multilumened, right heart catheters with a balloon at the tip, which, when inflated with air, carries the catheter along with the blood flow through the right side of the heart and into the pulmonary artery, allowing measurement of PA pressure and PAWP. The balloon flotation catheter is particularly useful for catheterization in children, in whom exact anatomy is not always predictable. Standard adult sizes are 5, 6, and 7 Fr, 110 cm long. Pediatric sizes are 4 and 5 Fr, 60 cm long. The balloon capacity of the different sizes varies and is marked on the hub of the catheter.

## **ANGIOGRAPHIC CATHETERS**

### **GENSINI CATHETERS**

The Gensini catheter is made of woven Dacron with a polyurethane coating and three pairs (six) of laterally opposed oval side holes within 1.5 cm of its open tip. The tip is tapered to provide a close fit over the appropriate-size guidewire. The catheter is intended specifically for percutaneous insertion into the right or left side of the heart for purposes of retrograde aortic and ventricular as well as pulmonary and vena caval angiographic studies. The Gensini catheter is available in sizes 5 through 8 Fr and lengths of 80, 100, and 125 cm.

### **NATIONAL INSTITUTES OF HEALTH CATHETER (NIH)**

NIH catheter is closed-end, side-hole catheter with a gentle curve. It is a thin-wall catheter constructed of woven Dacron reinforced with a nylon core, the NIH catheter has six side holes near its flexible tip. The NIH catheter is used for angiographic visualization of either the RV or LV, the arterial or pulmonary vasculature, and the great veins. NIH catheter is available in sizes 5 through 8 Fr and length 50, 80, 100 and 125 cm.

## **LEHMAN VENTRICULOGRAPHY CATHETER**

It's a thin-wall, closed-end, woven Dacron catheter with polyurethane coating. The unique feature of this catheter is its slightly curved tip, tapered to 5 Fr, with four side holes beginning 2.5 cm from the tip. This catheter is usually fairly stable in the LV and is designed for primarily ventriculography. Sizes 5 through 8 Fr, with 80, 100 and 125 cm lengths.

## **PIGTAIL ANGIOGRAPHIC CATHETERS**

A pigtail angiographic catheter is made of polyurethane or polyethylene with a tapered tip, the terminal 5 cm of which is coiled back onto itself in a tight loop ("pigtail"). The catheter is available with an open or closed end with 4 to 12 non-laterally opposed side holes located in the terminal 5 cm of the catheter. This is most commonly used catheter for left ventricular and aortic angiography and is also successfully used for pulmonary angiography. Pigtail catheter to allow safer passage across cardiac valves and safer injection of contrast medium into ventricles and great vessels.

The Van Tassel angled pig tail catheter is employed for angiographic studies of the LV and aorta in patients with normal or stenosed aortic valves. This design is particularly helpful for crossing a stenotic aortic valve. The unique feature of this end hole catheter is a 145° or 155° angle 7 cm from the tip.

## **BERMAN ANGIOGRAPHIC CATHETER**

The Berman angiographic catheter is a double-lumen PVC catheter with side holes near the balloon tip. The catheter is intended selective pulmonary angiography in adults or for right and left heart catheterization and angiography in infants and small children.

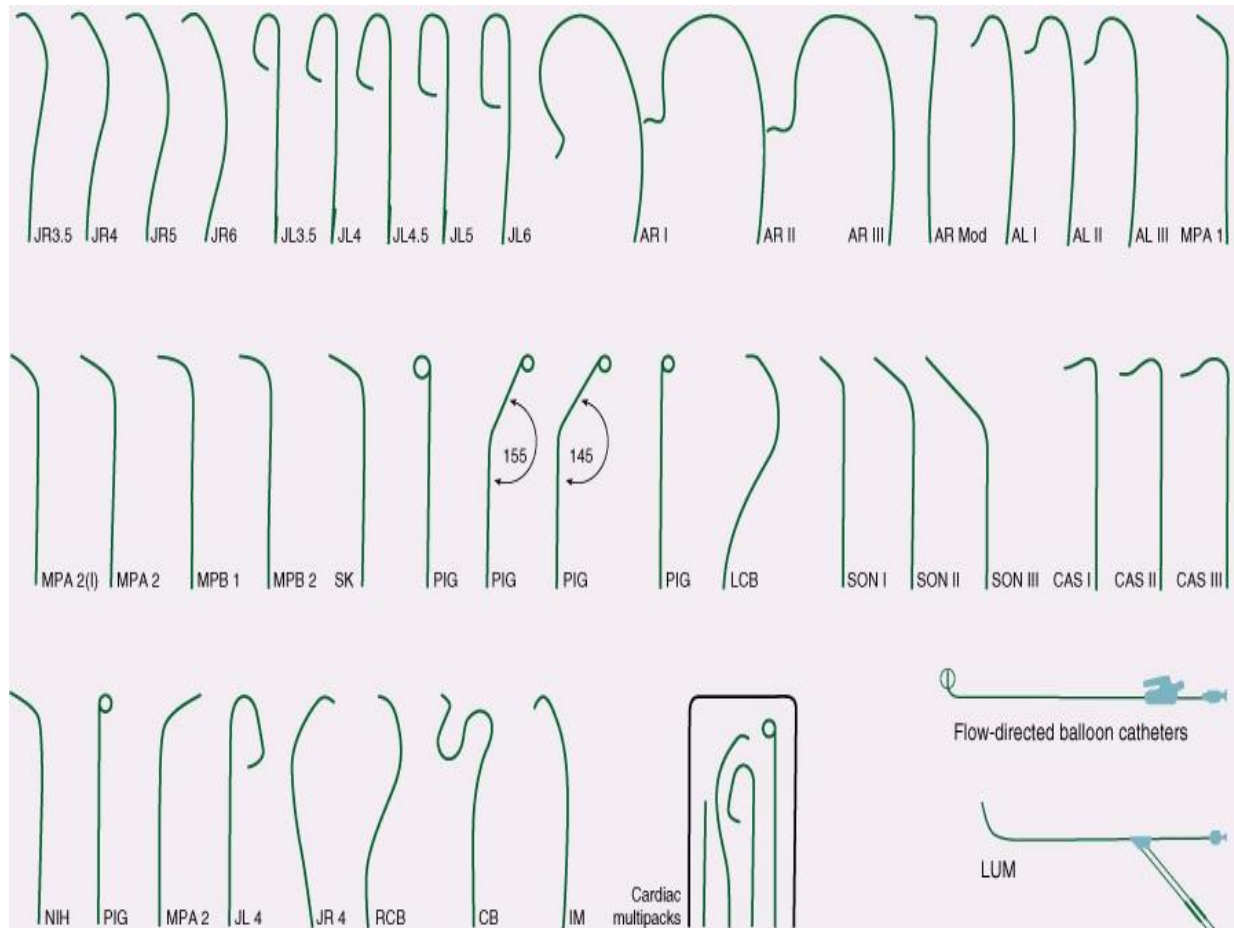
## **CORONARY ANGIOGRAPHIC CATHETER**

### **JUDKINS-TYPE CORONARY CATHETER**

Coronary angiography can be completed using Judkins catheters from the femoral approach in more than 90% of patients. Judkins catheters have special preshaped curves and tapered end-hole tips. The Judkins left coronary catheter has a double curve. The length of the segment between the primary and secondary curve determines the size of the catheter (i.e., 3.5, 4, 5, or 6 cm). The proper size of the left

Judkins catheter is selected depending on the length and width of the ascending aorta.

The Judkins right coronary catheter is sized by the length of the secondary curve and comes in 3.5, 4 and 5 cm sizes. The 4cm catheter is adequate in most cases.



### **THE BRACHIAL TYPE OR RADIAL TIG CATHETER**

The TIG is an end-hole catheter, with a single side hole and is well suited for the transradial approach. This catheter is user friendly; a single catheter completes coronary and left ventricular angiography.

### **AMPLATZ-TYPE CATHETER**

The left Amplatz-type catheter is a preshaped half-circle with the tapered tip extending perpendicular to the curve. Amplatz catheter sizes (left 1, 2 and 3 and right 1 and 2) indicates the diameter of tip curve. The catheter for selective

catheterization of the left or right coronary artery from the percutaneous femoral approach.

### **MULTIPURPOSE CATHETER**

MP catheters are catheters that are primarily straight with an end-hole and two side holes placed close to the tapered tip. Preshaped, mildly angled configurations are also available. The MP catheter can be used for left and right coronary injections and left ventriculography.

### **CORONARY BYPASS CATHETERS**

It is specifically designed and curved for post-operative opacification of right and left coronary bypass graft from the femoral percutaneous approach.

Left coronary bypass catheter: This catheter for visualization of a left coronary bypass graft affixed to the left anterior descending or circumflex artery. The tip has a 90° bend with a secondary curve of approximately 70°.

Right coronary bypass catheter: This catheter is the same as the left, except for a 110° to 120° bend of the catheter tip. It is used for visualization of either right or left coronary bypass graft.

Internal mammary bypass catheter: Designed for opacification of both right and left internal mammary artery bypass grafts, this is similar to the Judkins right coronary catheter with a shallower primary curve (80° to 85°) and a 1.5 to 2 cm tip.

### **PACING ELECTRODES**

These are no-lumen catheters with two platinum electrodes located 1 or 2.5 cm apart at the tip of the catheter and two electrode connectors at the base. They are employed for temporary atrial or ventricular pacing. Standard pacing electrodes come in sizes 5, 6 and 7 Fr, 110 cm long.

### **MANIFOLD**

A variety of manifold systems exist. One common design is a three component manifold that



has three stopcocks attached. The first stopcock is connected to a pressure transducer, the second is attached to flush solution and third is attached to the contrast agent choice.

## **GUIDE CATHETERS**

Guiding catheters are like angiography catheters only difference is that guiding catheters are more stiffer & firm as it carries Balloon catheters, PTCA wires and stent delivery system. Mild stiffness comes due to the wire braided design.

- Most designs are derived from standard Judkins and Amplatz diagnostic catheters with some relaxation of acuteness.
- Soft or atraumatic tip
- The ideal guide catheter align co axially with the proximal portion of the target vessel without obstructing it and bracing sufficiently against other parts of aortic root to provide axial support to pass dilating catheter.
- Stiffer shaft, larger internal diameter, a shorter and angulated tip (110 vs 90 degree) and reinforced construction (3 vs 2 layers).
- Larger catheter – better opacification, guide support and pressure monitoring at the cost of increased risk of ostial trauma, vascular complications and possibility of kink of shaft.
- Outer layer – polyurethane or poly ethylene for overall stiffness, middle layer composed of a wire matrix for torque generation and inner coating of Teflon for smooth passage of balloon catheter.

### **Limitations of Judkins**

- Primary curve is fixed – may not be co axial with index artery.
- Difficult to pass balloons – catheter takes 90 degrees to treated artery.
- Point of contact with aorta is very high and narrow for JL and nil for JR.

### **EBU catheter (Extra Back Up catheter)**

- Larger lumen guide balancing flexibility and support
- Workhorse construction suitable for various anatomies and takeoffs
- Flexible distal segment enables you to engage for backup support
- Supportive secondary curve for backup support and curve retention
- Enhanced visualization
- Larger lumens to maximize contrast flow for enhanced visualization
- Radiopaque marker band and nylon shaft
- Full-wall technology construction
- Robust, thinner walls without compromising support or curve retention
- Full range of coronary and peripheral curves

- 5F – 8F sizes available

### **RCA interventions**

- JR or hockey stick guide usually preferred
- If extra support needed – CTO, tortuosity – AL1 – larger secondary curves rests on aortic root.
- MP guide – abnormal take off of RCA from aorta especially inferior orientations
- 3DRC (Three dimensional right curve) – tortuous or bend anatomy, posterior and superior take off of RCA.

### **SVG (saphenous vein grafts) and LIMA**

- Usual – JR
- MP or AL1 – abnormal positions and take offs
- Left coronary bypass catheter or right coronary bypass catheter
- Internal mammary artery (IMA) catheter is designed for both right and left Internal Mammary arteries. It is shaped like a JR catheter but with a steeply angled tip (80 to 85<sup>0</sup>).

### **BACK UP FORCE**

Three factors were found to be associated with back up force:

1. Catheter size
  2. Angle (theta) of the catheter on the reverse side of the aorta
  3. Contact area
- The angle (theta) determines the vertical vector that can dislodge the guiding catheter. A smaller  $\text{Cos}\theta$  results in a greater backup force. This suggests that the lower position is preferable as the point of contact on the reverse side of the aorta because the angle approaches 90 degrees.
  - The larger French size guiding catheter produced a significantly greater backup force
  - Backup (EBU/XB) type catheters have greater backup force than a JL4 with deep engagement.

## **SIDE HOLES**

Side holes are useful where the pressure gets frequently damped as in RCA interventions, CTO interventions or sole surviving artery or left main interventions

Advantages:

- Prevent catheter damping (occlusion of the coronary ostium)
- Allow additional blood flow out of tip, to perfuse the artery.
- Avoid catastrophic dissections in the ostium of the artery

Disadvantages:

- False sense of security because now, aortic pressure, and not the coronary pressure is being monitored.
- Suboptimal opacification
- Reduction in back up support provided because of weakness of catheter shaft and the kinking at side holes

## **Dampening of Arterial Pressure**

Guide can cause

- fall of diastolic pressure - ventricularization
- fall of both systolic and diastolic pressure - dampened pressure

Can be due to

- significant lesion in the ostium
- coronary spasm
- non-coaxial alignment
- mismatch between diameter of the guide and of the arterial lumen

## **MOTHER AND CHILD TECHNIQUE**

- Improve the delivery of coronary stents to complex lesions
- Child catheters 4/5 F 120 cm
- Mother catheter - 6 F guiding catheter 100cm
- Superior trackability of the 4F child catheter
- Increased backup support of the mother-child system
- 4F mother-child system provided > 90% success rate

## **TORTUOUS ARTERIES**

- At least two or more than 75 degree bend proximal to the target lesion or one proximal bend 90 degrees.
- LAD – XB, XB LAD, EBU
- LCX – Voda or EBU
- Deep seating of guide – RCA and Cx clockwise or retract balloon.
- Soft tip.

## **TECHNIQUES TO STABILIZE A GUIDE**

1. Second angioplasty wire/ Buddy Wire - advanced parallel to the first one

- Straightens tortuous vessel and provides better support for device tracking

2. Second wire in a side branch - useful in anchoring the guide (second wire in LCX when dilating LAD lesion)

- Provides for better backup and allows retraction of the guide when necessary, without loss of position
- Also prevents the guide from being sucked in beyond the LM when pulling back balloon catheters
- Cause unnecessary denudation of endothelium in that vessel

3. Change to stronger guide

4. Anchoring Balloon

- Second small balloon (1.5–2 mm diameter) inserted in a small proximal branch
- Inflated at 2 ATM - anchor the guide

5. Change the current sheath to a very long sheath

6. Double guide technique

- insert a smaller guide in current guide

## **COMPLICATIONS**

- Embolism – air, atheroma, thrombus
- Dissection of coronary, aorta, abdominal aorta or iliac artery
- Frequent bleed backs

- Aortic debris – 24 – 65%, JL and MP
- Least with JR
- Less forceful injections till guide is coaxial
- More aggressive guide – more chance of dissection

## **CORONARY GUIDE WIRES**

Guidewire selection is an essential component of success fulcoronary intervention.

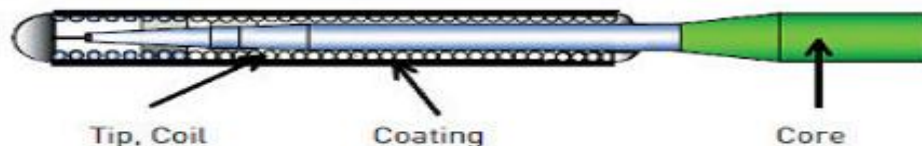
### **PURPOSE OF THE GUIDEWIRE**

Guidewires are used to facilitate successful delivery of interventional devices. Guidewires have the following functions:

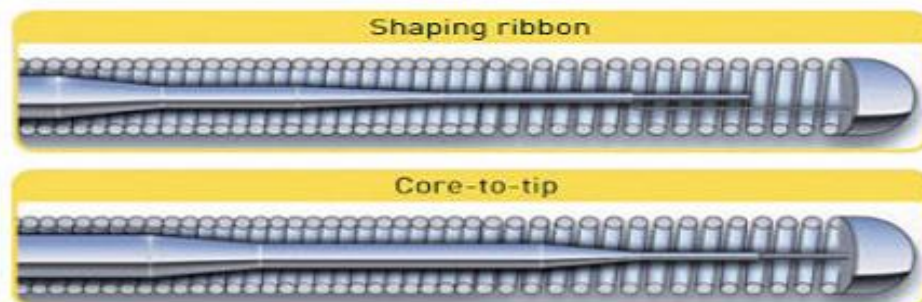
- To track through the vessel,
- To access the lesion,
- To cross the lesion atraumatically,
- To provide support for interventional devices.

### **STRUCTURE OF THE GUIDEWIRE**

A - Basic components of a guidewire



B - One-piece core (core-to-tip) vs. two-piece core (shaping ribbon) guidewire



C - Guidewire with polymer cover



## **CORE**

The inner part of the guidewire is referred to as the core. It extends through the shaft of the wire from the proximal to the distal part where it begins to taper. It is the stiffest part of the wire that gives the stability and steerability to the guidewire from its proximal end to the distal tip. The core material affects the flexibility, support, steering and trackability of the wire while its diameter influences the flexibility, support and torque of the wire.

### **Core material:**

The most popular core materials are stainless steel and nitinol, and other metal alloys.

- Stainless steel provides excellent support, transmission of push force and torque characteristics; these wires also have good shape ability, however it is less flexible in comparison to newer core materials and more susceptible to kinking.
- Nitinol is a super-elastic alloy of nickel and titanium designed for resiliency and kink resistance. It provides excellent flexibility and steering and is much more durable than stainless steel. Since nitinol maintains its shape and resists kinking, it is less susceptible to deformation during percutaneous coronary intervention (PCI) and could be used for treatment of multiple lesions and lesions with tortuous anatomy. However, it has less torqueability than stainless steel.

### **Core diameter:**

The diameter of the core influences the performance of the wire. Larger diameters improve the support, while smaller diameters have the opposite effect and enhance the flexibility of the wire. Larger diameters allow 1:1 torque response where the distal tip of the wire turns one turn for every turn on the proximal end for optimal steerability.

### **Core taper:**

The core of a guidewire usually is tapered along its length. The taper may have variable length and it may be either continuous or segmental. Shorter taper and smaller numbers of widely spaced gradual tapers enhance the support and transmission of push force, while longer tapers and larger numbers of more segmental tapering enhance the flexibility.

**Distal tip:**

- Flexible, radio-opaque part
- Consists of spring coil extending from distal untapered part of central core to distal tip weld
- Integrates tapered core barrel (as well as shaping ribbon in 2-piece wire)
- Spring coil-variable length (1-25cm) with a radio-opaque section located at its terminal end
- Distal tip weld- short ( $\leq 2\text{mm}$ ) compact cap forming the true distal end of the wire - to decrease trauma while the wire is traversing vessels.

**COATING OF THE GUIDEWIRE**

The coating is the outer covering on the core that keeps the overall diameter consistent and influences the wire performance. It affects the lubricity and tracking of the guidewire. It creates the “tactile feel” of the guidewires. The purpose of the coating is:

- To reduce frictions by facilitating the movement of the wire within the coronary anatomy and across the lesion, helping the wire negotiate tortuous anatomy,
- To improve deliverability by facilitating the movement of interventional equipment over the wire.

The type and length of coating may vary. Most often coating is applied to the distal 30 cm of the wire. Two types of coatings are used:

- Hydrophilic coatings attract water and are applied over the entire working length of the wire, including tip coils. When dry, the coating is a thin, non-slippery solid. Upon contact with liquids, such as saline or blood, the coating becomes a slippery gel-like surface that acts to reduce friction with the vessel walls and increase trackability. Hydrophilic coating provides a lubricious, low friction feel inside the vessel and more trackability. They are recommended for operators with some experience as they carry the risk for subintimal movement, dissection and perforation of coronary artery.
- Hydrophobic coatings are silicone based coatings which repel water and are applied on the working length of the wire, with the exception of the distal tip. They require no activation by liquids to create a “wax-like” surface and to achieve the desired effect – to reduce friction and increase trackability of the wire. Silicone coating has higher friction, more stable feel inside the vessel.

## GUIDEWIRE MAIN CHARACTERISTICS

<b>Characteristics</b>	<b>Defenition</b>
<b>Torque control</b>	Is an ability to apply rotational force at a proximal end of a guidewire and have that force transmitted efficiently to achieve proper control at the distal end
<b>Trackability</b>	Is an ability of a wire to follow the wire tip around curves and bends without bucking or kinking, to navigate anatomy of vasculature
<b>Steerability</b>	Is an ability of a guidewire tip to be delivered to the desired position in a vessel
<b>Flexibility</b>	Is an ability to bend with direct pressure
<b>Prolapse tendency</b>	Tendency of the body of a wire not to follow the tip around bends
<b>Radiopacity/visibility</b>	Is an ability to visualise a guidewire or guidewire tip under fluoroscopy.
<b>Tactile feedback</b>	Is tactile sensation on a proximal end of a guidewire that physician has that tells him what the distal end of the guidewire is doing
<b>Crossing</b>	Is an ability of a guidewire to cross lesion with little or no resistance
<b>Support</b>	Is an ability of a guidewire to support a passage of another device or system over it

## CLASSIFICATION OF GUIDEWIRES

There is no uniform classification of coronary guidewires.

Based on:

1. Tip flexibility (floppy/soft, intermediate, and stiff).
2. Tip coating (hydrophilic, hydrophobic, no coating).
3. Tip style (one-piece core-to-tip, two-piece core with shaping ribbon).
4. Tip tapering (tapered, untapered).
5. Core construction material (stainless steel, Nitinol, high-tensile stainless steel).
6. Device support (light, moderate support, extra support).

7. Target lesion type (workhorse/frontline wires, CTO wires, wires for tortuous lesions, etc.).
8. Specific purpose guidewires, e.g., pressure wire, marker wire (with markers or length indicators)), rotablator wire, wiggle wire, etc.

### Guide Wires Polymer – Coated (Hydrophilic Wires)

Manufacture	Wire	Shaft Diameter	Stiffness
<b>Guidant</b>	Whisper	0.014"	1 gram
	Pilot 50	0.014"	2 gram
	Pilot 150 &200	0.014"	4 & 6 gram
<b>Boston Scientific</b>	Choice PT & P2	0.014"	2 gram
	PT Graphix & P2	0.014"	3-4 gram
<b>Cordis</b>	Shinobi	0.014"	2 gram
	Shinobi Plus	0.014"	4 gram
<b>Medtronic Vascular</b>	Persuader	0.014"	3 & 6 gram
	Persuader 9	0.014" (tip 0.011")	9 gram
<b>AbottVasc Asahi</b>	Confianza Pro	0.014" (tip 0.009")	9 & 12 gram
	BMW Universal	0.014"	0.7 gram
	BMW Universal II	0.014"	0.7 gram

### Guide wires non coated (non lubricous) coil wires

Manufacture	Wire	Shaft Diameter	Stiffness
<b>Abott Vascular Asahi</b>	Medium	0.014"	2 gram
	Miraclebros	0.014"	3, 4, 5, 6, 12 gram
	Confianza	0.014"	9 & 12 gram
	Confianza Pro (Conquest)	0.014" (tip 0.009")	9 & 12 gram
<b>Medtronic Vascular</b>	Persuader	0.014"	3 & 6 gram
	Persuader 9	0.014"	9 gram
<b>Guidant</b>	HT Intermediate	0.014"	2-3 gram
	HT standard	0.014"	4 gram
	Cross-IT 100	0.014" (tip 0.011")	2 gram
	Cross-IT 200	0.014" (tip 0.011")	3 gram
	Cross-IT 300	0.014" (tip 0.011")	4 gram
	Cross-IT 400	0.014" (tip 0.011")	6 gram
<b>Terumo</b>	Runthrough	0.014"	1 gram
<b>Biotronik</b>	Galeo F	0.014"	1 gram
	Galeo M	0.014"	3 gram
	Galeo ES	0.014"	1 gram

<b>Asahi</b>	Sion blue	0.014"	0.5 gram
	Fielder XT	0.014" (tip 0.009")	0.8 gram
	Fielder FC	0.014"	0.8 gram
	Fielder XT-A	0.014" (tip 0.009")	1 gram
	Fielder XT-R	0.014" (tip 0.009")	0.6 gram
<b>Abbott</b>	Grandslam	0.014"	0.8 gram

## **CORONARY BALLOON**

The balloon catheter is an important component of therapeutic armamentarium of an interventional cardiologist. Coronary angioplasty began by using a balloon catheter to compress plaque within a clogged coronary artery, a procedure referred to as a plain old balloon angioplasty (POBA). The main uses of angioplasty balloon catheters are for predilatation of the lesion, post dilatation of the lesion and for stent delivery. In addition to these there are several other uses of the balloon catheters. Balloon catheters used in angioplasty now are either of Over-the-wire (OTW) or Rapid Exchange (Rx) design.

**Over-The-Wire (OTW) Balloon Catheters:** These are the classical balloon catheters which have two lumens running through the entire course of balloon catheter. One lumen is for passage of guidewire and the other lumen for connecting with an inflater for balloon inflation / deflation. This system is more useful when enhanced trackability is required and also in procedures requiring multiple guidewire exchanges and balloon upsizing i.e. chronic total occlusions (CTO).

**Monorail or Rapid Exchange (RX) Balloon Catheters:** Rapid-exchange (RX) or "monorail" balloon catheters have become the current standard for percutaneous coronary interventions (PCI). In this balloon catheter too there are two lumens, doesn't extend along the entire course of the balloon. It starts from distal end but finishes well before the proximal end of the balloon catheter. The main advantage of the system is that it allows a rapid exchange of interventional devices over the same standard length guidewire (rather than exchange of different guidewires over the same balloon). Thus the system has led to significant reduction in procedural and fluoroscopy time. Monorail system also seem to add to the safety of percutaneous interventions, due to a variety reasons, namely lower doses of contrast medium, shorter duration of fluoroscopy, and smaller devices diameters.

**Fixed Wire-Balloon Systems:** (the guidewire attached to the balloon can be rotated freely, but it cannot advance independently of the balloon) were used in the past, but they are not used.

**Perfusion Balloons:** is indicated for balloon dilatation of the stenotic portion of a coronary artery or bypass graft stenosis but still maintaining / improving myocardial perfusion. They may be especially useful in managing coronary perforations, where inflated balloon seals the perforation while central lumen provides perfusion to distal bed.

### **Balloon Catheter Construction Material**

The key requirements of angioplasty balloons are strength, flexibility and low profile. The materials typically used today are polyethylene terephthalate (PET) or nylon. PET offers advantages in tensile strength, and maximum pressure rating. One major advantage of PET is its unusual ability to be molded into ultra thin walls (a range from 5 to 50 microns) and very precise shapes while still retaining tensile strength. As such it is possible to achieve ultra low profile with these balloons. Angioplasty balloons may be coated for lubrication, for trackability, for abrasion resistance, or to deliver an antirestenotic / anticoagulatory drug. Balloon coatings include lubricious coating (hydrophilic and hydrophobic), tacky or high friction coatings, conductive coatings, drug release coatings, reflective coatings and selective coatings.

### **TERMS USED IN COTEXT OF ANGIOPLASTY BALLOONS**

**Balloon Diameter:** nominal inflated balloon diameter measured at a specified pressure

**Balloon Length:** typically refers to the working length or the length of the straight body section

**Nominal Pressure:** refers to the pressure at which when balloon is inflated it achieves the listed balloon diameter. It is usually 6-8 atm.

**Mean Burst pressure (MBP):** is the average pressure where 50% of balloons will burst (usually measured at the body temperature).

**Rated Burst Pressure (RBP):** the pressure below which 99.9% of the balloons will not burst upon single inflation.

**Balloon Profile:** is the maximum diameter of the balloon when mounted on a catheter in its deflated and wrapped condition or the smallest hole through which the deflated wrapped balloon can pass.

**Balloon compliance:** it is defined as change in balloon diameter per atmosphere of inflation pressure. It is an index of stretchability of the balloon. While more compliant balloons have the ability to mold according to vessel shape in general they have an inherent disadvantage because they can over-dilate a vessel (optimal balloon: vessel ratio is 0.9-1.1) making it prone to complications like dissection, vessel rupture, abrupt closure and other ischemic complications.

**Pushability:** It refers to the ability to advance the balloon across the lesion.

**Trackability:** It refers to the ease of tracking balloon over the guide wire up to the target lesion.

**Non Compliant Balloons:** They are ultra high-strength, thin walled balloons, generally fabricated from PET and used for coronary and peripheral angioplasty, stent delivery and other dilatation procedures. Rated burst pressure typically ranges from 18-24 atm, these balloons grow in diameter by <10% over nominal pressure upon inflation to high pressures. The RBP can be increased by increasing thickness of balloon, but this also increases stiffness of balloon and balloon profile.

**Semi Compliant Balloons:** These are standard balloons used for preparation /pre-dilatation of lesion before stent implantation. They have nominal pressure of 6-8 atm. And RBP of around 12-18 atm. Compliant balloons may increase in diameter by > 20% upon inflation to higher pressures.

**Cutting Balloon:** The cutting balloon is equipped with microatherotomes to incise the plaque at three or four points along its circumference. This scoring or cutting of the plaque is purported to produce the controlled and better dilation. The cutting balloon is commonly used for ostial lesions or in-stent restenotic lesions. Cutting balloon features three or four atherotomes (microsurgical blades), which are 3-5 times sharper than conventional surgical blades. The blades which are fixed longitudinally on the outer surface of a non-compliant balloon, expand radially and deliver longitudinal incisions in the plaque relieving its hoop stress.

**The AngioSculpt Scoring balloon:** Catheter from Abbott Vascular is essentially a modification of cutting balloon technique. It has a flexible nitinol scoring element with three rectangular spiral struts which work in tandem with a semi compliant balloon to score the target lesion. Balloon inflation focuses uniform radial forces

along the edges of the nitinol element, scoring the plaque and resulting in a more precise and predictable outcome. It has a low crossing profile (2.7F), and 0.014" system compatible with 6F guiding catheters, a semi-compliant balloon material.

**Drug Eluting Balloon:** Drug eluting balloons (DEB) could offer a viable alternative to drug eluting stents (DES) in the treatment of coronary artery disease. These balloons may also offer a valuable new option to treat patients in whom stent implantation is not desirable including small vessels, in-stent restenosis, bifurcation side-branch, and possible acute ST-elevation MI. currently 4 DEBs are available: B Braun's SeQuent™ Please, Medrad Interventional's Cotavance™ with Paccocath technology, Eurocor's DIOR™ Paclitaxel-coated and Invatec's IN.PACT™ Amphirion paclitaxel-eluting balloon for peripheral use.

## **Y CONNECTOR (ADJUSTABLE HEMOSTASIS DEVICE)**

The Y connector is an accessory device that minimizes back-beeding while the balloon catheter is inserted into the guiding catheter. This device allows the injection of contrast media and pressure monitoring through the guiding catheter, regardless of balloon catheter position. It comes with a rotating valve to prevent back bleeding while advancing the balloon/stent catheter through guide catheter.

## **INFLATION DEVICE**

A disposable syringe device is used to inflate the balloon on the balloon catheter with precise measurement of the inflation pressure in atmospheres (atm). Balloons are generally inflated at pressures of 4 to 20 atm. Although stents may be inflated at 10 to 18 atm. It features braided high pressure tubing with a rotating male luer fitting, a luminescent analog pressure gauge, and a handle. Pressure balloon inflation are generated by squeezing on the handle or by turning angle in clockwise.

## **TORQUE (TOOL) DEVICE**

A small cylindrical pin vise clamp slides over the proximal end of the angioplasty guidewire, permitting the operator to perform fine manipulations of the guidewire by turning the torque tool (i.e., pin vise on the guidewire).

## **GUIDEWIRE INTRODUCER**

A very thin, needle like tube with a tapered conical opening helps the guidewire to be inserted into balloon catheters and through Y adapters.

## **CORONARY STENTS**

Stents are small expandable tubes used to treat narrowed or weakened arteries in the body. In patients with coronary artery disease (CAD), stents are used to open narrowed arteries and help reduce symptoms such as chest pain (angina) or to help treat a heart attack.

There are currently five types of stents available:

- Dual Therapy Stent (DTS)
- Bioresorbable Vascular Scaffold (BVS)
- Bio-engineered Stent
- Drug Eluting Stent (DES)
- Bare Metal Stent (BMS)

### **Dual Therapy Stent (DTS)**

Dual Therapy Stent (DTS) is the latest type of coronary stent. It is a first-of-its-kind stent therapy designed to not only reduce the likelihood of the re-narrowing of the artery or of having to undergo a repeat procedure, but also help the healing process of the artery. It combines the benefit of DES and bio-engineered stents and is the only stent to contain a drug with active healing technology.

The DTS has coating both inside and outside, which reduces the likelihood of blood clots, inflammation and helps the healing process of the artery. The stent surface facing the artery wall contains a drug that is released to help stop the artery blocking again without the worry of swelling or an inflammatory response. The drug is delivered from a bioresorbable polymer that will degrade over time. The side of the stent which faces blood flow is coated with antibodies, which promote natural healing and helps the healthy artery function properly.

### **The Bio-Vascular Scaffold (BVS)**

The Bio-Vascular Scaffold (BVS) is a drug eluting stent on a dissolvable type of scaffold platform which can be absorbed by the body over time.

Like some of the currently available Drug Eluting Stents (DES), BVS is coated with a drug released from a polymer that disappears over time to reduce the likelihood of the artery re-narrowing (restenosis). The scaffold itself is absorbed overtime. Unlike with the DTS, there is no active element to promote artery healing.

## **Bio-engineered Stent**

Bio-engineered Stent is also known as antibody-coated stent. This type of stent differs from DES because it does not contain a polymer and does not use a drug. As a result, it helps to speed up the cell lining of the artery (endothelialization), promoting natural healing.

The antibody on the stent's surface attracts circulating Endothelial Progenitor Cells (EPCs) which come from human bone marrow and help speed up the formation of healthy endothelium. This provides rapid coverage over the stent's surface helping to reduce the risk of early and late thrombosis (blood clots).

## **Drug Eluting Stents (DES)**

Drug Eluting Stents (DES) are coated with medication that is released (eluted) to help prevent the growth of scar tissue in the artery lining. This helps the artery remain smooth and open, ensuring good blood flow and reduces the chances of the artery re-narrowing or restenosis. However, it also leads to a higher chance of blood clots (stent thrombosis).

Due to a relatively slower healing process, patients implanted with DES must strictly follow their doctor's recommendation on drug therapy (DAPT) to help reduce risk of stent thrombosis. Current American Heart Association recommendations are for a minimum DAPT therapy of at least 12 months after DES implantation.

## **Bare metal stents**

Bare metal stents are usually stainless steel and have no special coating. They act as scaffolding to prop open blood vessels after they are widened with angioplasty. As the artery heals, tissue grows around the stent, holding it in place. However, sometimes an overgrowth of scar tissue in the arterial lining increases the risk of re-blockage.

## DRUR ELUTING STENTS

BRAND	PLATFORM	DRUG	POLYMER	SIZES	LENGTHS
Endeavor sprint	Co Cr	Zotarolimus	Phosphoryl choline	2.25, 2.5, 2.75, 3, 3.5, 4.0	8, 9, 12, 14, 18, 24, 30
Endeavour resolute	Co Cr	Zotarolimus	Biolinx	2.25, 2.5, 2.75, 3, 3.5, 4.0	8, 9, 12, 14, 18, 24, 30
integrity	Co Cr	Zotarolimus	Biolinx	2.25, 2.5, 2.75, 3, 3.5, 4.0	8, 9, 12, 14, 18, 24, 30
Pronova XR	Co Cr	Sirolimus	biodegradable	2.25, 2.5, 2.75, 3, 3.5, 4.0	13, 18, 23, 28, 33, 38, 43, 48
Pronova SS	St Steel	Sirolimus	biostable	2.5, 2.75, 3, 3.5, 4.0	13, 18, 23, 28, 33, 38
Yukon DES	St Steel	Sirolimus	Null	2, 2.5, 2.75, 3, 3.5, 4.0	8, 12, 16, 18, 21, 24, 28, 32, 40, 50
Yukon choice PC	St Steel	Sirolimus	PLLA	2, 2.5, 2.75, 3, 3.5, 4.0	8, 12, 16, 18, 21, 24, 28, 32, 40, 50
Xience V	CoCr	Everolimus	Biocompatible	2.25, 2.5, 2.75, 3, 3.5, 4.0	8, 12, 15, 18, 23, 28
Xience PRIME LL	CoCr	Everolimus	Biocompatible	2.25, 2.5, 2.75, 3, 3.5, 4.0	8, 12, 15, 18, 23, 28, 33, 38
Excel	St Steel	Rapamycin	PLLA	2.5, 2.75, 3, 3.5, 4.0	14, 18, 23, 24, 28, 33, 36
Rapstrom	CoCr	Sirolimus	Bioabsorbable	2.25, 2.5, 2.75, 3, 3.25, 3.5, 4.0	8, 13, 18, 23, 28, 33, 38
Biomatrix	St Steel	Biolimus A9	PLLA	2.25, 2.5, 2.75, 3, 3.25, 3.5, 4.0	8, 11, 14, 18, 24, 28
Orsiro	CoCr	Sirolimus	PLLA	2.25, 2.5,	9, 13, 15,

				2.75, 3, 3.5, 4.0	18, 22, 26, 30
GenXSync	CoCr	Sirolimus	Biodegradable	2.25, 2.5, 2.75, 3, 3.5, 4, 4.5	8, 13, 16, 19, 24, 29, 32, 37, 40
Promus Element	Platinum Chromium	Everolimus	PBMA Co-polymer - PVDF	2.25, 2.5, 2.75, 3, 3.5, 4	8, 12, 16, 20, 24, 28, 32, 38
Supralimus Core	CoCr	Sirolimus	Biodegradable	2.5, 2.75, 3, 3.5	8, 12, 16, 20, 24, 28, 32, 36, 40
Nobori	St Steel	Biolimus A9	PLA	2.5, 2.75, 3, 3.5	8, 14, 18, 24, 28
Biomime	CoCr	Sirolimus	Biopoly	2.5, 2.75, 3, 4, 4.5	8, 13, 16, 19, 24, 29, 32, 37, 40
Superia	CoCr	Sirolimus	Biodegradable	2.5, 2.75, 3, 3.5, 4.0	8, 12, 16, 20, 24, 28, 32, 36, 40
BVS	PLA	Everolimus	Biodegradable	2.5, 3.0, 3.5	12, 18, 28,
Release	CoCr	Sirolimus	Biodegradable	2.5, 2.75, 3, 3.5, 4.0	10, 13, 15, 18, 20, 24, 28, 32, 36, 40

## BARE METAL STENT

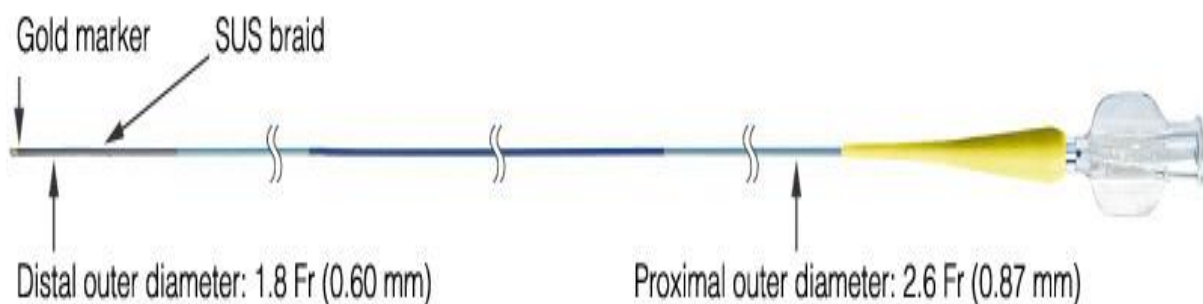
COMPANY	SIZES	PLATFORM	LENGTH
Flexy star	2.25, 2.75, 3, 3.5, 4, 4.5	Cobalt Chromium	7, 10, 13, 15, 17, 20, 24, 28, 33, 38, 42
Angstrom	2.5, 2.75, 3, 3.5, 4,	Stainless Steel	10, 13, 16, 19, 21, 24, 27
All cross	2.25, 2.5, 2.75, 3, 3, 3.5, 4	Cobalt Chromium	12, 15, 18, 21, 24, 30
Prokinetic	2, 2.25, 2.5, 2.75, 3, 3, 3.5, 4, 4.5, 5	Cobalt Chromium	8, 10, 13, 15, 18, 20, 22, 30
Microdriver(<3 mm)		Cobalt Chromium	
Driver(3-4 mm)	2.5-4	Cobalt Chromium	9-30
Satin Flex		Cobalt Chromium	

Vision	2.75, 3, 3.5, 4	Cobalt Chromium	8, 12, 15, 18, 23, 28
Mini Vision	2, 2.25, 2.5	Cobalt Chromium	8, 12, 15, 18, 23, 28
Prozeta	2.5, 2.75, 3, 3.25, 3.5, 4	Cobalt Chromium	13, 16, 18, 23, 28, 33, 38
Angstrom II	2.5, 2.75, 3, 3.25, 3.5, 3.75, 4	Cobalt Chromium	8, 13, 18, 23, 28
Flexy Rap	2.25, 2.75, 3, 3.5, 4, 4.5	Cobalt Chromium	7, 10, 13, 15, 17, 20, 24, 28, 33, 38, 42

## **MICROCATHETERS**

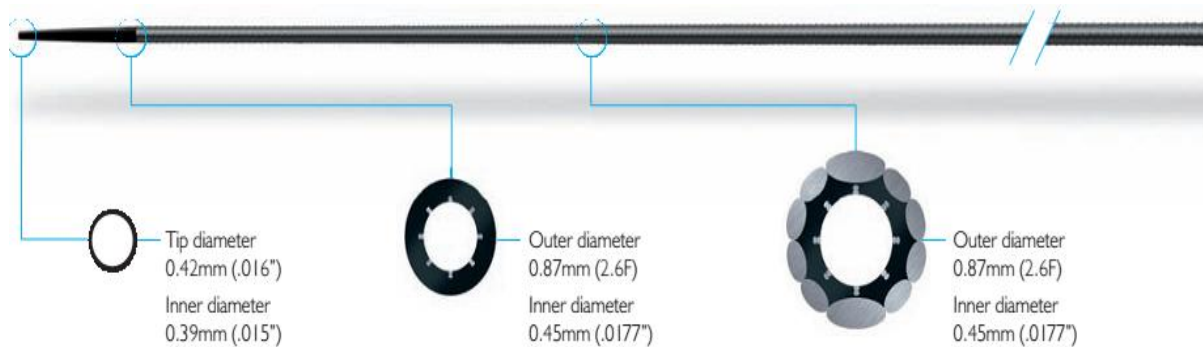
A microcatheter is a single-lumen device that can be loaded on the GW in order to track it to the target lesion. The TRACK FORCE (TRACKABILITY) needed to reach the lesion should be as low as possible. The microcatheter is used to help the physician to cross the lesion, previous to the balloon dilatation/stenting, giving mechanical support to the guidewire and enhancing its ability to transmit PUSH FORCE (PUSHABILITY) to the occlusion.

Fine cross (Terumo): Tapered inner and outer lumen provide an optimal balance between guide wire support and crossability. Fully stainless steel braided shaft provides strong guide wire support. PTFE coated inner layer facilitates manipulation of the guide wire 2.6 Fr (0.87 mm) proximal diameter enables buddy wire technique in 6 Fr (I.D.  $\geq$  0.070" - 1.78 mm) guiding catheter. Large inner diameter ensures optimal guide wire handling



Corsair (Asahi): For increased success with Antegrade and Retrograde approaches to CTO's:


- Kink resistant tapered tip (.016") eases access to complex channels
- Ease in crossing and dilating micro-channels or lesions
- Improves wire support and wire manipulation Hydrophilic coating applied to distal 60cm section



## **CRUSADE**

The Crusade Catheter is a dual lumen device studied for the treatment of stenosis close to the bifurcations, when the guidewire doesn't provide the right support to engage the side branch.

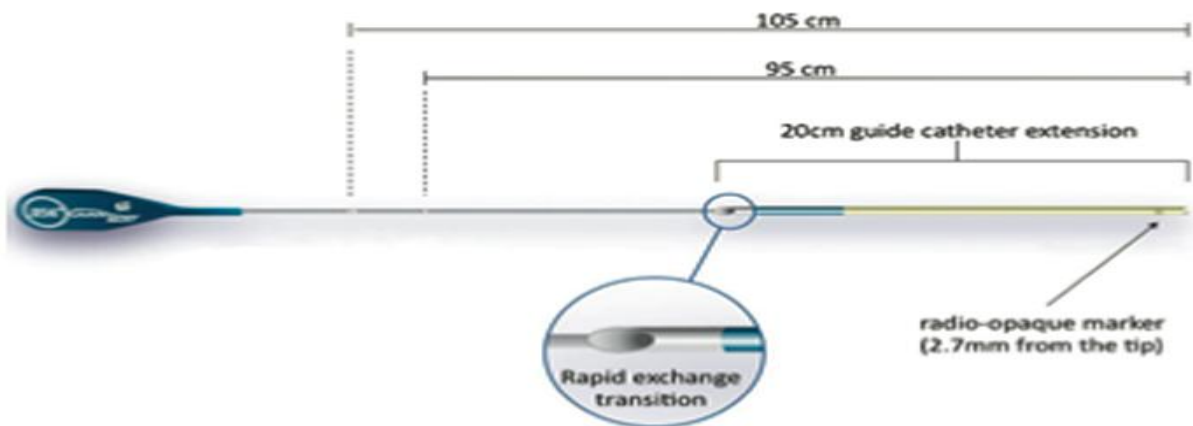
The Crusade catheter allows the operator to deliver a second guidewire through the OTW lumen while leaving the guidewire in the monorail lumen in place. The maximum supported diameter of the guidewires in the Crusade Catheter is 0.014"



## **GUIDELINER CATHETER**

- GuideLiner catheter is a coaxial guiding catheter extension delivered through a standard guiding catheter on a monorail
- Comprises a flexible yellow 20 cm straight extension connected to a stainless-steel push tube

- Permits very deep intubation of the target vessel, thus providing backup support to facilitate stent delivery across heavily calcified lesions in tortuous vessels



**Figure 1.** *The GuideLiner catheter. This consists of a flexible 20 cm straight guide extension connected to a stainless-steel push tube.*

## **CLOSURE DEVICE**

### **AMPLATZER DEVICES**

**Septal occluder:** This device consists of two self-expandable round discs made of 0.004 to 0.005 inch Nitinol wire mesh that are linked together by a short (4 mm) connecting waist, corresponding to the thickness of the atrial septum. The left atrial disc extends 7 mm radially around the connecting waist and the right disc 5 mm. The left disc is slightly larger than the right because of the higher left atrial pressure. Both discs are angled slightly toward each other to ensure firm contact with the atrial septum. The prosthesis is filled with Dacron fabric to facilitate thrombosis. Prostheses are currently available in sizes ranging from 4 to 32 mm at increments of 1 mm.

**Duct occluder:** The Amplatzer Duct Occluder is a self-expandable, mushroom-shaped device made from a 0.004 inch thick Nitinol wire mesh (a thin retention disc, 4 mm larger in size than the diameter of the device ensures secure positioning in the mouth of PDA). The PDA is closed by the induction of thrombosis, which is accomplished by polyester fibres sewn securely into the device. Platinum marker bands are applied to the wire ends and laser welded. The shape is then formed by heat treatment. All devices are cone-shaped and 7 mm in length, with a recessed screw, sizes are given from the larger to the smaller diameter.

Duct occlude II: the Amplatzer duct occlude II is self expanding Nitinol mesh device for the occlusion of the PDA. The device configuration is a central waist with 2 retention discs. The central waist is designed to fill the ductus and the two retention discs are designed to be deployed in the pulmonary artery and aortic side of the ductus.

### Cribriform device muscular VSDoccluder

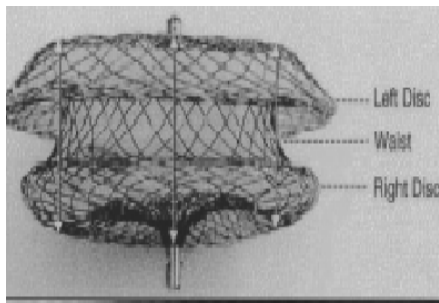
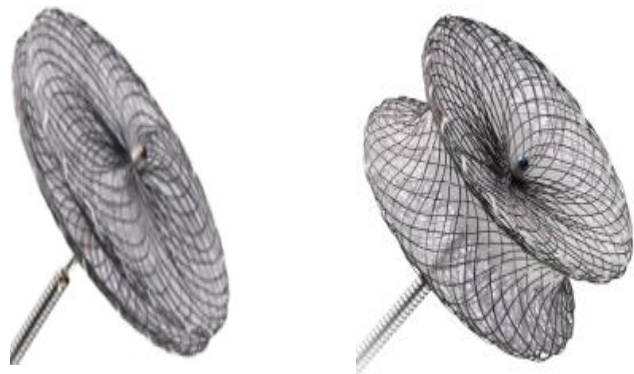


Fig. 1 : Amplatzer septal occluder



Cribriform device: Amplatzer Multi-Fenestrated Septal Occluder - “Cribriform” were specifically designed to seal ASDs and multi fenestrated ASDs respectively. Amplatzer Multi-Fenestrated Septal Occluder - “Cribriform” were specifically designed to seal ASDs and multi fenestrated ASDs respectively. The left atrial disc is smaller than the right atrial disc.

Muscular VSD occlude: the two disks are linked together by a short cylindrical waist corresponding to the size of the ventricular septal defect.

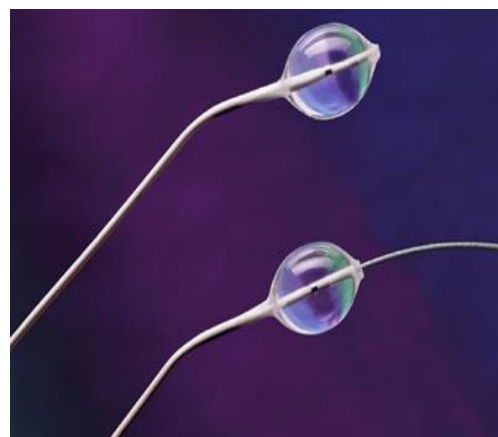## COCOON DEVICES

The devices are made from a Nitinol wire mesh and platinum coated self expandable material. The shapes are same for Amplatzer.

## ATRIOSEPTOSTOMY CATHETER

### Catheter Characteristics

The NuMED Z-5™ Atrioseptostomy catheter is engineered for maximum steering and tracking. The dual lumen shaft design provides pushability, coupled with exceptional pull strength. This new innovation in Atrioseptostomy catheter design is of potential importance in patients who are



subject to a small left atrium and in small neonates with congenital heart disease requiring Atrioseptostomy.

### **Radiopaque Catheter Body & Balloon Image Marker**

The NuMED Z-5™ Atrioseptostomy catheter body is Radiopaque to facilitate reliable positioning of the catheter. A platinum image marker band is placed under the balloon for clear identification under fluoroscopy.

### **Micro-Thin Non-Compliant Balloon**

The NuMED Z-5™ Atrioseptostomy balloon is micro-thin for low deflated profile that maintains tip flexibility. The Inflation of the balloon is controlled by volume. (see volumetric chart-Instructions for Use)

### **Reduced Balloon Size**

The reduced inflated balloon size should make Atrioseptostomy easier to perform on neonates with a small left atrium.

### **Tip Angulation**

The tip of the catheter is angled at 35° to facilitate passage into the left atrium.

### **Inner Lumen**


The NuMED Z-5™ Atrioseptostomy catheter has an inner lumen. The catheter end hole can accommodate a guidewire.

Balloon Diameter (MM)	Balloon Length (CM)	Introducer Size (FR)	Shaft Size (FR)	Usable Length (CM)	Guide Wire (Inches)	Maximum Volume (CC)
9.5	0.95	5	4	50	0.014	1
13.5	1.35	6	5	50	0.021	2

## **VALVULOPLASTY BALLOON**

### **Catheter Characteristics**

The Z-MED™ high pressure dilatation catheter is a coaxially constructed catheter with a distally mounted non-compliant high pressure balloon. The catheter exhibits a comparable



profile to other marketed catheters by also combines this profile with a high pressure balloon suitable for resistant stenosis. The Z-MED™ balloon catheter is available in over 50 configurations ranging in diameter from 2.0 to 40.0 mm.

### **Radiopaque Marker**

Platinum marker bands facilitate reliable positioning of the balloon.

### **Balloon**

The Z-MED™ PTV balloon has a low deflated profile that maintains tip flexibility. The exceptionally low profile balloon requires the smallest introducer possible. Nominal dimensions are maintained over the entire length of the balloon.

### **Maximum Trackability**

The distal shaft through the balloon is highly flexible for exceptional maneuverability. This, combined with the pushability of the coaxial shaft, provides outstanding tracking performance.

### **Sizes**

The balloon diameters are starting 4 up to 30 mm.

## **MOUNTED CP STENT**

The Mounted CP Stent™ consists of a bare CP Stent™ pre-mounted on a **BIB Catheter**. This system allows the physician the flexibility of using the pre-mounted complete system and will save the time required to mount the stent on the catheter. The CP Stent™ is composed of 0.013” platinum/iridium wire that is arranged in a “zig” pattern, laser welded at each joint and then over braided with 24K gold. It allows expansion from 12.0mm to 24.0mm. The **CP Stent** is pre-mounted on a BIB (balloon in balloon) catheter. The Mounted CP Stent™ is indicated for implantation in the native and/or recurrent coarctation of the aorta on patients with the following clinical conditions:



Stenosis of the aorta resulting in significant anatomic narrowing as determined by angiography or non-invasive imaging, i.e. echocardiography, magnetic resonance imaging (MRI), CT Scan;

Stenosis of the aorta resulting in hemodynamic alterations, resulting in systolic pressure gradient, systemic hypertension or altered left ventricular function;

Stenosis of the aorta where balloon angioplasty is ineffective or contraindicated;

Stenosis diameter >20% of the adjacent vessel diameter.

### **Covered Mounted CP Stent**

The Covered Mounted CP Stent™ consists of a Covered CP Stent™ pre-mounted on a BIB Catheter. This system allows the physician the flexibility of using the pre-mounted complete system and will save the time required to mount the stent on the catheter. This may be critical in some cases of aneurysmal repair or in cases where vascular damage has occurred. The Covered CP Stent™ is comprised of the bare CP Stent™ that is covered with an expandable sleeve of ePTFE.

The Covered Mounted CP Stent™ is indicated for implantation in the native and/or recurrent coarctation of the aorta on patients with the following clinical conditions:

- Stenosis of the aorta resulting in significant anatomic narrowing as determined by angiography or non-invasive imaging, i.e. echocardiography, magnetic resonance imaging (MRI), CT Scan;
- Stenosis of the aorta resulting in hemodynamic alterations, resulting in systolic pressure gradient, systemic hypertension or altered left ventricular function;
- Stenosis of the aorta where balloon angioplasty is ineffective or contraindicated;
- Stenosis diameter <20% of the adjacent vessel diameter;
- Stenosis that would present increased risk of vascular damage or disruption;
- Aneurysm associated with coarctation of the aorta.

### **BIB Stent Placement Catheter**

The BIB Catheter allows for the controlled expansion of the CP Stent™ by utilizing an incremental expansion of the stent. The inner balloon of the BIB Catheter is ½ the diameter of the outer balloon and is 1.0cm shorter in length. When the inner balloon is inflated, the stent expansion begins from the center of the stent. The stent is firmly gripped on to the balloon to allow for fine positioning

before the final expansion by inflating the outer balloon. All BIB Catheters are 110cm in length and utilize a 0.035" guidewire.

## **COILS**

Percutaneous transcatheter occlusion of unwanted vascular communications has played an important role in pediatric interventional cardiology since first described by Gianturco and colleagues 5 more than 20 years ago. The most commonly used coil embolization materials available include the Gianturco stainless steel coil (Occluding Spring Emboli; Cook, Bloomington, Indiana) and the platinum microcoil (Target Therapeutics, Santa Monica, California). The Gianturco coil is constructed of stainless steel wire of varying helical diameters and lengths to which Dacron fibers have been attached to increase thrombogenicity. There are at least 15 different loop sizes and lengths of the wire Gianturco coils from the smallest diameter of 1mm to the largest 15 mm.

## **BIOPTOME**

There are two basic types of bioptomes: (a) stiff devices that are maneuvered independently through the vasculature and (b) more flexible devices that can be positioned only with the aid of a long sheath or introducing catheter.

### **The Konno bioptome:**

Sakakibara and Konno developed a biopsy catheter capable of transvascular introduction and retrieval of endomyocardial biopsy samples from either the left or right ventricular chamber. The original device consisted of a 100-cm catheter shaft with two sharpened cups (diameter either 2.5 or 3.5 mm) at its tip. These cups could be opened or closed under the control of a single wire, activated by a sliding assembly attached to the proximal end of the catheter. Because of the large size of the catheter head, it was usually introduced by cutdown entry of the saphenous or basilic vein (or the femoral or brachial artery).

### **The Stanford (Caves-Schulz) Bioptome:**

The original Stanford bioptome was modified for left ventricular biopsy by doubling its length to 100 cm and reducing its outer diameter to 6F. With this reduction in shaft diameter, the catheter is no longer capable of independent movement through the vasculature and must be positioned with the aid of an 8F 90-cm curved Teflon sheath, which is itself introduced into the left ventricle over a

conventional 100-cm 6.7F pigtail catheter (Stanford Biopsy Set, Cook Inc., Bloomington, IN). The tip of the sheath is positioned distal to the mitral apparatus and away from the posterobasal wall and apex, which are thinner and more easily perforated than other areas of the leftventricle. The pigtail catheter is then removed, the sheath is flushed, and the biptome is introduced.

## **THROMBUS ASPIRATION SYSTEM**

Intravascular, and especially intracoronary thrombus, can be aspirated manually with several available manual aspiration catheters or a high pressure rheolytic thrombectomy system (Angiojet, Possis, Minneapolis, MN). The Angiojet catheter uses high-pressure water jets directed backward into the catheter to create a strong suction at the space near the tip and effective thrombus evacuation occurs. Manual aspiration thrombectomy catheters are used to remove thrombus and have been shown to reduce mortality in patients with MI who undergo primary PCI.

## **INOUE TYPE BALLOONS**

The Inoue balloon catheter has a unique design that allows inflation of the balloon to facilitate crossing the mitral valve. A calibrated syringe produces a step-wise incremental valve dilation. Selection of balloon size is based on patient height.

## **ACCURA BALLOON**

The accura double lumen PTMC balloon dilation catheter has an 11 F, 80 cm shaft and three stages of expandable balloon.

## **INFERIOR VENA CAVA FILTERS**

IVC filters are typically collapsible cone-shaped arrays of six struts (wires) of stainless steel, titanium, or nickel-titanium (nitinol), with hooks (barbs) on the wire ends to secure the filter to the vena cava wall. Other filter shapes are also used—for example, the bird's nest IVC filter, which is a random array of wires extending in various directions; the shape is reminiscent of a bird's nest. There are basically two types of IVC filters, permanent and optional, commonly referred to as retrievable. Permanent filters are designed to remain in the patient without the ability to be removed. Permanent filter design should permit significant fixation to the vena cava wall to prevent migration over the patient's life. Optional (retrievable) filters are designed to remain permanently in the patient or to be removed when it is no longer

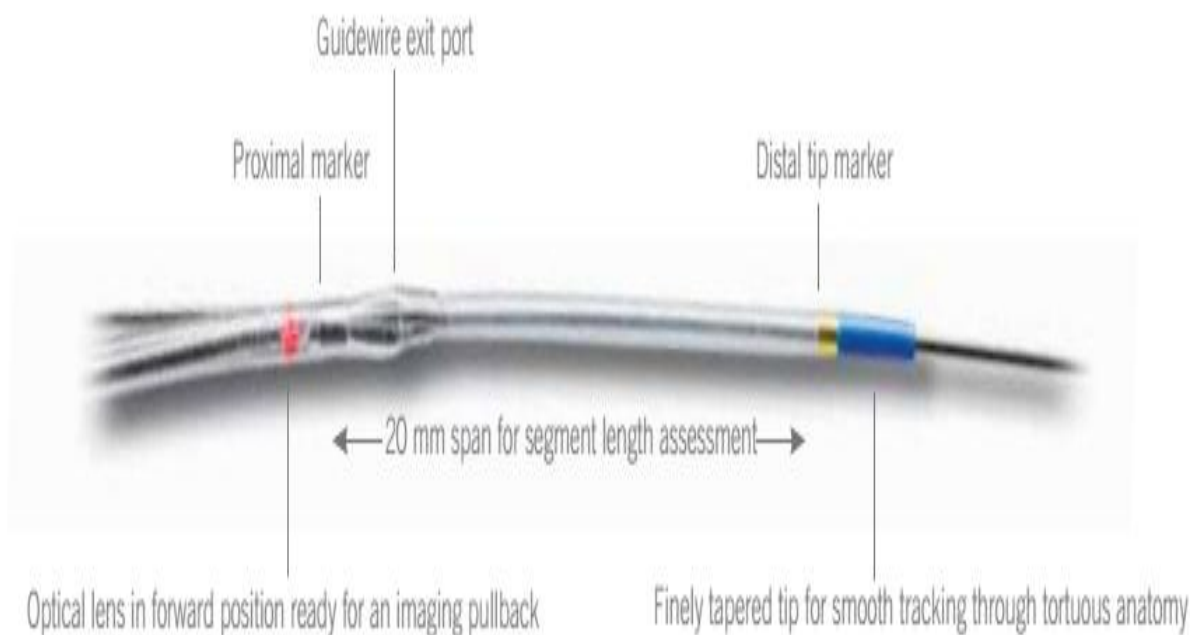
warranted, such as when the risk of PE has subsided or when the patient no longer has a contraindication to anticoagulation therapy. Retrievable filters should also achieve fixation to the vena cava wall, but their structure must have the ability to be altered (e.g., collapsible) at the time of removal with catheter-based retrieval devices to facilitate safe removal.

## **C7 DRAGONFLY OCT CATHETER**

The C7 Dragonfly catheter provides unprecedented magnification and detail in intravascular imaging. Using Optical Coherence Tomography(OCT), the C7 Dragonfly emits near-infrared light for a data sampling rate of 100 MB per second to produce real-time, ultra-high definition images. Combined with the C7-XR™ OCT intravascular imaging system, the C7 Dragonfly offers a new standard for lesion assessment, classification and diagnosis.

- Extreme Resolution imaging based on OCT technology
- Low-profile minirail tip for fast placement
- Hydrophilic coating reduces drag
- Dual marker bands for precise positioning
- Compatible with standard 0.014" steerable guidewires
- Imaging speed up to 25 mm per second

### C7 DRAGONFLY IMAGING CATHETER



## FOREGIN BODY RETRIEVAL CATHETERS


The tools available for foreign body retrieval have rapidly evolved in the past decade...



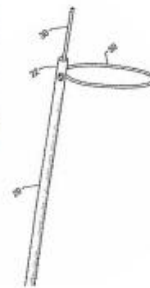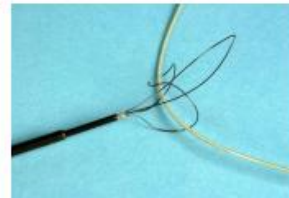EN Snare , Merit Medical Systems




Alligator Retrieval Device , eV3



In-Time Retrieval Device ,Boston Scientific



Segura Basket



Loop snares



Texan Foreign Body Retrieval Device , IDEV

## CUVETTE

The fundamental principles upon which oximetry is based are the facts as demonstrated by "Kramer2"<sup>4</sup> that (1) oxyhemoglobin transmits visible red light (620-770 m<sup>μ</sup>) to a much greater degree than does reduced hemoglobin, and (2) that Beer's law of optical absorption may be applied to the hemoglobin of whole blood in

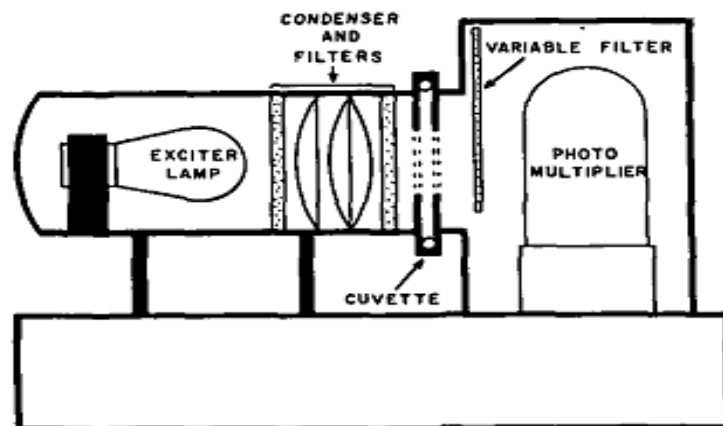


Fig. 1. Diagrammatic illustration of densitometer.

various saturations with oxygen.

The instrument employed consists basically of a light source with transmission of light through a cuvette containing blood to a photosensitive element. The light source is of a wavelength of 630 nm, and at this wavelength the transmission of light through blood is directly related to its oxygen saturation. The photosensitive element consists of a multiplier tube capable of a gain of one million and with an output sufficiently high to permit the use of a fast-response galvanometer (125 c.p.s.). The cuvette is constructed so that the entering blood changes its course in a 90° turn just prior to reaching the photosensitive area. This creates turbulence in the flow and prevents streaming of the blood. The light source, cuvette and phototube form a small unit remote from the power supply, permitting the use of the densitometer close to the field of operation.

## **ACTIVATED CLOTTING TIME TEST**

### **PRINCIPLE:**

The ACT test was first described by Paul Hattersley, M.D., in 1966. Although the test was originally a manual method, automated ACT instruments were later introduced which improved the convenience of the test. Automated test systems like Actalyke feature pre-loaded, disposable test tubes to which a blood sample is added; the test tube is then inserted into the instrument where the tube is rotated and warmed to 37°C (±0.5°C) until a fibrin clot is mechanically detected. Upon clot detection the test terminates, a buzzer is sounded, and the ACT result is displayed (in seconds) on the instrument LED. Each Actalyke test tube has a barcode label affixed to it, which is read by the Actalyke instrument to determine the test activator type. [Barcode reader not available on Actalyke MINI models]. The lot number and expiration date of each tube are also identified on the barcode label.

## **CLEANING AND STERILIZATION**

Most catheters used today are intended for one-time use only. Catheters suitable for reuse should be cleaned in the following way:

- Immediately after use, flush the catheter manually with 20 to 40 ml of tap water and rinse the outer surface with tap water.
- Connect the catheter to a pressure flush system and flush with water for 30 to 45 minutes.
- Cleanse the catheter by soaking in Detergicide solution for 30 minutes or by ultrasonic cleaning in Detergicide solution for 15 minutes.

- Flush the catheter with 1000 ml of Detegicide solution with either a pressure flush system or gravity drip setup.
- Rinse the catheter with 100 ml of distilled water using a pressure flush system or a gravity drip setup.
- Dry the catheter.

Sterilization is best achieved with ethylene oxide followed by an appropriate aeration period. Other methods of sterilization (autoclaving or cold sterilization with glutaraldehyde) subject the catheter to temperatures or chemicals that could damage it. Care must be exercised when clean catheters are packaged for sterilization to prevent the coiling of the catheter more than 8 inches in diameter. This not only would shape the catheter introduce stress points and increase the risk of catheter damage. Radiation sterilization may degrade certain plastics depending on the polymer and the radiation dose and duration

### **Ethylene Oxide:**

Ethylene Oxide (EO) is a low temperature sterilization method that has been used for many years. The low temperature process makes it suitable for the sterilization of heat and moisture sensitive medical devices that cannot tolerate the high temperatures and moisture associated with steam sterilization. EO is a colorless gas, which destroys microorganisms by a process called alkylation. The EO penetrates the cells membrane and reacts with the nuclear material rendering it unable to metabolize and reproduce. EO does have some disadvantageous including a relatively long sterilization cycle and the need for aeration for a specified amount of time. EO is toxic and porous materials exposed to EO will absorb the toxic gas requiring aeration following the sterilization process to allow the residue to escape from the medical devices before they are handled and used. EO sterilizers are designed and programmed to operate at the required concentration and humidity levels for the established routine hospital cycles parameters.

- Relative humidity 50 – 75% (items should be completely dried prior to packaging and being placed in sterilizer)
- Temperatures range from 85-145° F depending on cycle chosen, chamber size, and gas blends (manufacturer's instructions to be followed)
- Exposure Time is usually 2 hours or longer depending on load capacity, density and porosity
- Aeration times and temperatures; 8 hours at 140° F and 12 hours at 122°F.

## **Hydrogen Peroxide Gas Plasma:**

Gas Plasma is a low temperature sterilization alternative that has been available for several years and is suitable for many heat sensitive and moisture sensitive or moisture stable medical devices. Unlike EO sterilization, gas plasma sterilization is devoid of the occupational, environmental and patient safety concerns. Gas plasma is also less expensive and total cycle times are significantly less than EO. Medical devices are ready for use following sterilization without the need for aeration. This method disperses a hydrogen peroxide solution in a vacuum chamber, creating a plasma cloud, reactive species are generated from the hydrogen peroxide that are reactive with microorganisms. Gas Plasma sterilizes by oxidizing key cellular components of the microorganisms, which inactivates and destroys them. There are some restrictions on lumen devices validated for sterilization by this method based on gauge and length of the device. Users should obtain documentation from the manufacturer for appropriate use and restrictions. Gas plasma is not compatible with highly porous absorbers, such as cellulose, and paper products and cannot be utilized to process liquids.

### **Hydrogen Peroxide Gas Plasma Parameters:**

- Temperature range varies but is maintained between 104-131°F
- Total cycle time will range between 28 - 75 minutes depending on the sterilizer model and size.

## **Seven steps of instrument processing**

### **GLUTARALDEHYDE (CIDEX)**

#### **FEATURES & BENEFITS:**

- **EFFECTIVE** – achieves high-level disinfection in 20 minutes at 20°C.
- **ECONOMICAL** – offers value efficacy.
- **LONG-LASTING EFFICACY** – reusable for up to 14 days when monitored with CIDEX® Solution Test Strips.
- **EXCELLENT MATERIALS COMPATIBILITY** – can be used safely to disinfect a wide range of instruments, reducing risk of damage and associated cost of repairs.
- **EASY CONTROL OF EFFICACY** with CIDEX® Solution Test Strips.

CIDEX® Activated Glutaraldehyde Solution offers excellent materials compatibility and can therefore be used to disinfect a wide range of medical instruments, made of

aluminum, brass, copper, stainless steel, plastics and elastomers. Refer to instructions for use for complete details. CIDEX® Activated Glutaraldehyde Solution provides a wide spectrum efficacy against bacteria, mycobacteria, viruses and fungi. The solution can also achieve some sporicidal activity with longer exposure time.

- In-use concentration : 2.4% Glutaraldehyde
- Soak time High-level Disinfection : 20 minutes at 20°C, Sporicidal activity: 10 hours at 25°C
- Use Life : Up to 14 days
- Shelf Life : 2 years
- Open Bottle Shelf Life : 14 days (when open and activated)
- Storage : 15-30°C
- Disposal : Drain or as per hospital policy. Flush thoroughly with water.

### **DISINFECTION OF LAB (FUMIGATION)**

Disinfection of lab is done by formaldehyde (formalin). Formalin is an aqueous solution containing 37 to 40% formaldehyde, this may diluted with water or alcohol (1:1). This solution is vaporous in the room. The room has to be airtight for effective disinfection. The vapors are allowed to be in the cabin for 12 hrs.

Step	Technique
1. Transport	Transport contaminated instruments to the processing area in a manner that minimizes the risk of exposure to persons and the environment. Use appropriate PPE and a rigid, leakproof container.
2. Cleaning	Clean instruments with a hands-free, mechanical process such as an ultrasonic cleaner or instrument washer. If instruments cannot be cleaned immediately, use a holding solution.
3. Packaging	In the clean area, wrap/package instruments in appropriate materials. Place a chemical indicator inside the package next to the instruments. If an indicator is not visible on the outside of the package, place an external process indicator on the package.
4. Sterilization	Load the sterilizer according to the manufacturer's instructions. Label packages. Do not overload the sterilizer. Place packages on their edges in single layers, or on racks to increase circulation of the sterilizing agent around the instruments. Operate the sterilizer according to the manufacturer's instructions. Allow packages to cool before removing them from the sterilizer. Allow packages to cool before handling.
5. Storage	Store instruments in a clean, dry environment in a manner that maintains the integrity of the package. Rotate packages so that those with the oldest sterilization dates will be used first.
6. Delivery	Deliver packages to point of use in a manner that maintains sterility of the instruments until they are used. Inspect each package for damage. Open package aseptically.
7. Quality assurance program	An effective quality assurance program should incorporate training, record keeping, maintenance, and use of biologic indicators.

**CARDIAC CATHETERIZATION  
DIAGNOSTIC STUDIES AND  
PROCEDURES**

## **INTRODUCTION TO THE CATHETERIZATION LABORATORY**

Cardiac catheterization is the insertion and passage of small plastic tubes (catheters) into arteries and veins to the heart to obtain X-ray pictures (angiography) of coronary arteries and cardiac chambers and to measure pressures in the heart (hemodynamics). The cardiac catheterization laboratory performs angiography to obtain images not only to diagnose coronary artery disease but also to look for disease of the aorta and pulmonary and peripheral vessels. In addition to providing diagnostic information, the cardiac catheterization laboratory performs catheter-based interventions (e.g., angioplasty and stents, now called percutaneous coronary intervention) or catheter-based treatments of structural heart disease for both acute and chronic cardiovascular illness.

## **INDICATIONS FOR CARDIAC CATHETERIZATION**

Cardiac catheterization is used to identify structural cardiac diseases such as atherosclerotic arterial disease, abnormalities of heart muscle (infarction or cardiomyopathy), and valvular or congenital heart abnormalities. In adults the procedure is used most commonly to diagnose coronary artery disease. Other indications depend upon the history, physical examination, electrocardiogram (ECG), cardiac stress test, electrocardiographic results, and chest radiograph.

**Elective Procedures:** For most patients, cardiac catheterization is performed as an elective diagnostic procedure. It should be deferred if the patient is not prepared either physiologically or physically.

**Urgent Procedures:** If the patient's condition is unstable because of a suspected cardiac disorder, such as acute myocardial infarction, catheterization must proceed.

## **CONTRAINDICATIONS**

Contraindications to cardiac catheterization include fever, anemia, electrolyte imbalance (especially hypokalemia predisposing to arrhythmias), and other systemic illnesses needing stabilization.

## **PREPARATION OF THE PATIENT**

- Consent for the procedure (Explain about each step of the procedure and the risk for routine cardiac catheterization).
- Communication with patients: a nonmedical person understands.

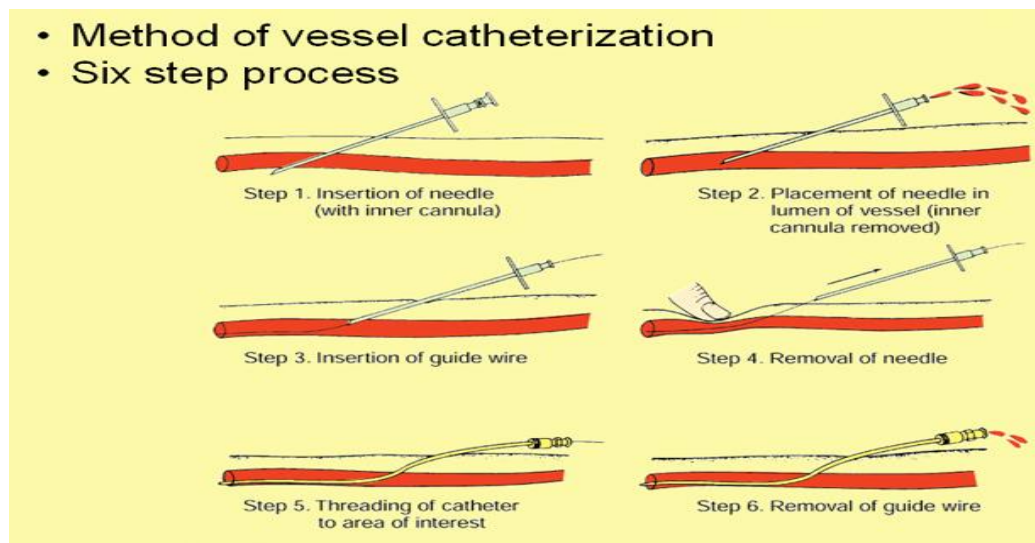
- Laboratory atmosphere: the patient's confidence builder.
- In Laboratory Preparations
  - Check patient's ID band, known allergies.
  - Check laboratory results (blood urea nitrogen, creatinine, prothrombin time, partial thromboplastin time, electrolytes).
  - Check blood pressure, all pulses (arms and legs), baseline ECG.
  - Anticoagulant status. Check the international normalized ratio (INR) and partial thromboplastin time (PTT) and if on heparin, the activated clotting time (ACT).
  - Assess the patient's understanding of the procedure and answer the patient's questions.
  - Verify the proper paperwork has been copied and filled out for the procedure.
  - Check that the intravenous (IV) line is patent.
  - Check that the patient has ingested nothing by mouth before the procedure.
  - Check whether the premedications were given as ordered.
- Sterile preparations: Cardiac catheterization is performed using aseptic technique in an operating room setting with personnel in scrubs, protective hats, masks and gowns.
  - Vascular access site preparation: clipping the area of hair and vigorously applying an antiseptic solution.
  - Sterile field preparation and patient draping: The physician in the procedure puts on hair and shoe covers and surgical mask and washes the hands and forearms as a surgical scrub, then puts on a sterile surgical gown and gloves and drape with Betadine. A sterile drape is placed over the patient, starting at the patient's upper chest and extending to the foot, covering the entire examination table.
- Crash cart and defibrillator: The crash cart contains emergency drugs (atropine, meperidine (Demerol), fentanyl or morphine, naloxone (Nacran), midazolam (versed)), oxygen, airway, suction apparatus and other emergency equipment. A defibrillator should be charged and ready for use during procedure. Electrode gel, temporary pacemakers, and new electrode patches should be on every cart.

## **PERCUTANEOUS VASCULAR ACCESS**

The site of access is determined by the planned investigation and the anticipated anatomic and pathologic conditions of the patient.

### **THE SELDINGER TECHNIQUE**

Modified Seldinger only punctures one side of vessel – this Percutaneous method can be used for arteries or veins - describes the method of catheter introduction that is not a direct stick.



### **FEMORAL ARTERY APPROACH**

The operator should identify anatomical landmarks prior to giving local anesthesia, such as the inguinal ligament, which traverse from the anterior superior iliac spine to the pubic tubercle. The femoral artery generally crosses the inguinal ligament at an imaginary point that is located one-third from the medial aspect and two thirds from the lateral aspect of the ligament. The femoral pulse is then palpated approximately two finger breadths (2 to 3 cm) below the inguinal ligament, marking the site of arterial access. One can also use fluoroscopy to identify the femoral head. The optimal access location would be at the site over the inferior border of the femoral head. This approach is especially useful in obese patients.

Locating the optimal site of entry is important. Entry sites above the inguinal ligament may lead to an increased risk of retroperitoneal bleeding, while entry sites that are too low may result in development of arteriovenous fistula or pseudoaneurysm.

## **FEMORAL VEIN APPROACH**

The femoral arterial pulse is the landmark for the femoral vein. The femoral vein is located approximately 1 cm medial to the femoral artery; sometimes it is located partially behind the artery. Vein puncture may be successful only after several attempts, because venous pressure is low, it may be difficult to see unassisted back bleeding from the needle on entry. A 10 ml syringe with 5 ml of saline can be attached to the Seldinger needle and gently aspirated during the needle advancement.

## **RADIAL ARTERY APPROACH**

Compared with the femoral artery, the radial artery is easily accessible in most patients and is not located near significant veins or nerves. The superficial location of the radial artery enables easy access and control of bleeding. No significant clinical sequelae after radial artery occlusion occur in patients with a normal Allen's test because of the dual blood supply to the hand through the ulnar artery. The results of the oximetric Allen test are divided into three grades of waveform during radial artery occlusion: type A, no change in pulse wave; type B, a damped but distinct pulse wave; type B, a damped but distinct pulse wave; and type C, loss of phasic pulse waveform. Radial artery cannulation can proceed with either type A or type B and is not recommended for type C.

The patient should be well sedated and comfortably positioned. Several positioning techniques have been suggested. Arm abduction at a 70-degree angle on the arm board or placement immediately next to the femoral access site has been used for sheath insertion. Before complete sheath introduction, use of a vasodilator (nitroglycerin, verapamil) and intra-arterial lidocaine reduces artery spasm and improves patient comfort and there are several "radial cocktails" used.

## **BRACHIAL ARTERY APPROACH**

The brachial and radial pulses of both arms should be palpated. The Allens test should also be performed. The brachial artery is approximately 3 to 5 diameter. The strongest brachial pulse is generally located 1 to 2 cm above the elbow crease. The antecubital fossa is then sterilized and draped.

## **BRACHIAL VEIN APPROACH**

The antecubital vein anatomy varies greatly among patients a successful vein puncture depends on visual identification of an adequately sized antecubital vein. The vein located on the lateral antecubital area should not be used because of their course through the cephalic venous system over deltoid muscles, making catheter advancement through the relatively sharp turns in the shoulder area difficult. Application of tourniquet several centimeters above the elbow may facilitate the identification of a suitable vein.

## **INTERNAL JUGULAR VEIN APPROACH**

The internal jugular vein is lateral to the carotid artery, medial to external jugular vein, and usually just lateral to the outer edge of the medial head of the sternocleidomastoid muscle. To identify landmarks, the operator instructs the patient to lie supine without a pillow under the head and, in the case of right internal jugular, with the head turned 30 degrees to the left. Patient with low venous pressure may be placed in the Trendelenburg (head lower than feet) position. Many physicians and critical care societies recommend the use of ultrasound to guide access.

## **HEPARIN**

Catheterization from the femoral artery had a higher incidence of major complications than catheterization from the brachial artery. One difference was that brachial catheterization used systemic heparinization to avoid thrombosis in the smaller diameter brachial artery. When systemic heparinization was adopted in femoral procedures, the rates of complications became standard practice to achieve full intravenous heparinization (5000 U) immediately left sided sheath was inserted. Lesser amounts of heparin (2,500 to 3,000) were used, particularly in smaller patients, and additional heparin (up to a total 50 to 70 U per Kg) was given procedure went on to a coronary intervention. This type of higher heparin dosing is routinely monitored by an activated clotting time (ACT) machine in the cardiac catheterization laboratory, and titrated to an ACT of roughly 300 seconds.

## **RIGHT HEART CATHETERIZATION**

Only the right heart catheterization can provide data regarding mean left heart filling pressure (the pulmonary capillary wedge, rather than just the post-A wave left ventricular end diastolic pressure), detect pulmonary arterial hypertension, measure the cardiac output, and detect left-to-right intracardiac shunts.

### **Indications for right heart catheterization:**

- Congenital heart disease, including atrial septal defect, ventricular septal defect, patent ductus arteriosus
- Pulmonary thromboembolic disease
- Suspected pericardial tamponade or constriction
- As part of endomyocardial biopsy or electrophysiologic studies
- As part of left heart catheterization and coronary angiography in complicated cases with left ventricular failure, previous myocardial infarction, or cardiomyopathy
- Valvular heart disease

The right heart can be approached through the femoral, internal jugular or subclavian veins. Once the inferior vena cava or superior vena cava is reached, the catheter is advanced through the right atrium, right ventricle, and pulmonary artery to a distal pulmonary vessel. Right ventricular irritability may be noted when the catheter tip passes through the right ventricle. The course of the catheter is followed with pressure monitoring through the catheter and with fluoroscopy. When indicated, blood samples are taken, and pressure are recorded as the catheter is advanced. If left heart catheterization is planned, the catheter may be left in the distal pulmonary vessel, so that simultaneous left ventricular and pulmonary artery wedge pressure waveforms can be recorded. As the catheter is removed, pull-back pressure can be measured and recorded from the pulmonary artery to the right ventricle and from right ventricle to the right atrium. These measurements are used to determine valve gradients and to evaluate pulmonic and tricuspid valve function. Blood sample can also be taken as the catheter is withdrawn for detection of left to right shunts. If pulmonic or tricuspid valve disease is suspected, contrast can be injected for digital imaging of the right atrium, right ventricle, or pulmonary artery.

## **CARDIAC OUTPUT STUDIES**

The method of cardiac output determination includes the Fick oxygen method, indicator dilution technique, and the thermodilution method.

**Direct Fick Method:** The Fick method, which has historically been used in the catheterization laboratory for calculation of cardiac output determination. The Fick method requires measurement of arterial oxygen saturation mixed venous saturation. Oxygen consumption is ideally is a measured value obtained value during catheterization. Fick method of cardiac output determination is helpful in cases where the patient is in atrial fibrillation, has significant tricuspid regurgitation, or a low cardiac output state.

**Thrombodilution and Indicator Dilution Method:** thermodilution and indicator dilution methods are based on principle that if a known amount of an indicator is added to a unknown quantity of flowing liquid and concentration of the indicator is then measured downstream, the time course of its concentration gives a quantitative index of the flow. Applied to the circulatory system, the amount of indicator, and the time during which the first circulation of the substance occurs can be used to compute cardiac output.

The thermodilution technique using cold or room temperature dextrose or saline injectate solution is the most frequently used cardiac output determination method in cardiac catheterization laboratories. The benefits of the thermodilution technique are that (1) it is performed over a short period and is, therefore, more likely to be recorded during a period of study state; (2) it is most accurate in patients with normal or high cardiac output; (3) the indicator used is inert and inexpensive; (4) it does not require an arterial puncture; and (5) the computer analysis curve is reasonably simple to interpret. Drawbacks of this method include its unreliability in the presence atrial fibrillation, significant tricuspid regurgitation, and its tendency to overestimate cardiac output in patients with low cardiac output.

## **LEFT HEART CATHETERIZATION**

Left heart catheterization is used to perform coronary angiography for the evaluation of coronary anatomy, to obtain pressure measurements to evaluate mitral and aortic valve function, and to perform left ventriculography to evaluate left ventricular function.

The two main approaches into the left heart are retrograde entry through the aortic valve by either percutaneous femoral, which is the most common, or brachial approach and transseptal entry from the right atrium. The progress of the catheter in both approaches is followed by fluoroscopy and pressure measurement. For mitral valve studies, simultaneous pulmonary artery wedge and left ventricular pressures or simultaneous left atrial and left ventricular pressures are recorded to evaluate pressure difference across the valve. To evaluate aortic valve function, pull-back pressure is recorded as the catheter withdrawn from the left ventricle to the aorta. Digital imaging may be performed during contrast injection of the left atrium, left ventricle, or aortic root to evaluate valve function further.

**Transseptal Left Heart Catheterization:** The transseptal approach to left heart catheterization involves crossing from the right atrium to the left atrium through the fossa ovalis. This technique is infrequently done for diagnostic catheterizations but can be used in the rare situation when retrograde left heart catheterization is not possible due to severe aortic stenosis or a prosthetic valve that cannot be adequately evaluated by echocardiogram or transesophageal echocardiography. More common uses of the transseptal approach include mitral valvuloplasty, electrophysiology studies requiring access to the left atrium or left ventricle, and transcatheter closure of patent foramen ovale or atrial septal defect.

## **VENTRICULOGRAPHY**

The left ventriculogram is an integral part of every coronary arteriographic study and provides information about LV wall motion and overall function of the heart. Abnormal wall motion indicates the presence of coronary ischemia, infarction, aneurysm, or hypertrophy. Left ventriculography also provides quantitative information, such as the ventricular volumes during systole and diastole, the ejection fraction, the rate of ejection, the quality of contractility, the presence of hyperdynamic hypertrophic contraction, and valvular regurgitation.

Ventriculography may be performed before or after coronary angiography. Coronary angiography is routinely performed first because ventricular function can be obtained through noninvasive methods in case of complications that terminate the study prematurely. In patients with LMCA or aortic stenosis, left ventriculography has often been when postprocedural hypotension is anticipated. Low-volume, non-ionic, low-osmolar contrast ventriculograms can be performed while little or no induced hypotension.

## **Setup of Contrast Media Power (High-Pressure) Injectors**

Because contrast media is viscous and great force is necessary to inject contrast rapidly through small catheters, power injectors are always used to deliver a preset contrast volume over a brief period. Three steps are critical to safe ventriculography: (1) contrast loading, (2) air bubble clearing from the injection syringe and high-pressure connecting tubing, and (3) correct injector settings. The most important step of the setup is to clear all air and bubbles from the transparent pressure injector syringe and tubing before an injection. This is an obligation of all physicians and nurses in the laboratory. There is no excuse for injection of air during contrast ventriculography.

Typical injection pressure settings for ventriculography are as follows:

- Flow rate (10 to 15 ml/sec)
- Total volume (20 to 50 ml)
- Pressure limit (900 to 1200 psi)
- Rise time (0.2 to 0.5 second)

### **Indications of and Complications of Ventriculography:**

Indications of left ventriculography:

- Identification of LV function for patients with coronary artery disease, myopathy, or valvular heart disease
- Identification of ventricular septal defect
- Quantitation of the degree of mitral regurgitation
- Quantitation of the mass of myocardium for regression of hypertrophy or other similar research studies

Indications of right ventriculography:

- Documentation of tricuspid regurgitation
- Assessment of pulmonary stenosis
- Assessment of RV dysplasia for arrhythmias
- Assessment of abnormalities of pulmonary outflow tract
- Assessment of right to left ventricular shunt

Complications:

- Cardiac arrhythmias, especially nonsustained brief VT do not require treatment. Sustained VT and ventricular fibrillation require immediate cardioversion.
- Intra myocardial contrast media “staining” during power injection
- Embolism (thrombi or air)
- Contrast-related complications
- Transient hypotension (<15 to 30 seconds) was common with ionic high osmolar contrast media.

### **Catheter Position**

The optimal catheter position for left ventriculography is one of that avoids contact with the papillary muscles or is positioned too close to the mitral valve so that mitral regurgitation is not produced artificially. For most catheters a mid-cavity position seems best because contrast material fills most of the LV chamber and apex, and catheter during injection does not interfere with mitral valve function. In this position pigtail catheter side holes are well below the aortic valve, which improves chamber opacification. Angled (145 degree) pigtail catheters and helical tip designs (halo catheter) may provide better quality ventriculography with less induced ectopy and mitral regurgitation. Standard left ventriculographic views are (1) a 30 degree RAO that visualizes the high lateral, anterior, apical, and inferior LV walls and (2) a 45- to 60-degree LAO, 20-degree cranial angulation that best identifies the lateral and septal LV walls. The LAO with cranial angulation provides a view of the interventricular septum.

For right ventriculography a berman balloon tipped or NIH catheter produces excellent opacification. The angiographic projection of right ventriculography is not standardized. An AP cranial or lateral projection is commonly used to visualize the septum and right ventricular outflow tract (RVOT). Injection rates range from 8 to 10 ml/sec for volume of 20 to 30 ml.

**Regional Left Ventricular Wall Motion:** The normal pattern of LV contraction has been defined as a uniform, concentric, inward motion of all points along the ventricular inner surface during systole. Uniform wall motion depends on the cooperative and sequential contraction of the heart muscle, producing maximal effective work at minimal energy costs. This coordinated contraction is called synergy. Uncoordinated contractions of LV wall motion are given names according to the severity of asynergy. Abnormal LV motion is particularly obvious in patients with

severe coronary artery disease or cardiomyopathy. Several methods exist to analyze LV wall motion. The RAO and LAO left ventriculograms are divided into five segments. Points are assigned to the following wall motion abnormalities.

- Normal contraction
- Moderate hypokinesis (a diminished, but not absent, motion of one part of the LV wall is weak or poor contraction)
- Severe hypokinesis
- Akinesis (total lack of motion of a portion of the LV wall, i.e., no contraction)
- Aneurysm-dyskinesis (paradoxical systolic motion or expansion of one part of the LV wall, i.e., an abnormal outward bulging during systole)

## **ASCENDING AORTOGRAPHY**

Ascending aortography may be necessary in the course of coronary angiography and interventions.

Indications:

- Aortic aneurysm or aortic dissection
- Aortic insufficiency
- Nonselctive visualization of coronary bypass graft
- Supravalvular aortic stenosis
- Brachiocephalic or arch vessel disease
- Coarctaion of the aorta
- Aortic –PA or aortic to right sided heart (e.g., sinus of valsalva fistula) communication
- Aortic periaortic neoplastic disease
- Arterial thromboembolic disease
- Arterial inflammatory disease

Contraindications:

- Contrast media reaction
- Injection to false lumen of aortic dissection
- End hole catheter malposition
- Inability of the patient to tolerate additional radiographic contrast media

**Left anterior oblique or lateral projection:** The LAO view is excellent for identifying dissection of the ascending aorta extending up to the neck vessel, optimally

delineating the aortic arch; opening of the aortic curvature; and providing clear views of the innominate, common carotid, and left subclavian arteries. The coronary arteries at the root of the aorta are displayed in semilateral projection.

**Right anterior oblique projection:** The descending thoracic aorta and the ascending aorta may be superimposed across the arch in the AP or LAO projection.

**Injection rates and catheter position:** Aortography can be performed by use of a minimum flow rate of 15 to 20 ml/sec for total volumes of 40 to 60 ml. Use of multiple side hole catheters reduces the risk of extending or inducing a dissection during contrast medium injection. The catheter should be positioned just above the aortic valve but not close enough to interfere with the valve opening or closing.

## **PULMONARY ANGIOGRAPHY**

Pulmonary angiography provides visualization of vascular abnormalities of the lung vessels (e.g., intraluminal defects representing pulmonary emboli, shunts, stenosis, arteriovenous (AV) malformation, and anomalous connections). It should be preceded by the measurement of pressures of the right side of the heart. Indications of pulmonary angiography include the following:

- Pulmonary embolism
- Peripheral pulmonic stenosis or pulmonary AV fistula
- Anomalous pulmonary venous drainage
- Follow-through for left atrial opacification (suspected atrial myxoma, large thrombi)

Contraindications:

- Allergy to contrast agent
- Pulmonary hypertension with PA systolic pressure (>60 mm Hg)
- Acute RV volume overload (after injection of contrast medium, increased volume may produce RV failure, low cardiac output state, shock, or death)

## RADIO CONTRAST MEDIA IN PERCUTANEOUS CORONARY INTERVENTION

Radiographic contrast agents, or contrast media, are compounds that are injected during coronary angiography to render intravascular structures visible. The issues surrounding CM selection extend beyond coronary visualization and include consideration of all the properties, potential adverse effects, and outcomes from comparative clinical trials.

They are classified based on their osmolality and ionicity into-

- a) High-osmolar (HO) >1,600 mOsm/l – no longer recommended
- b) Low-osmolar (LO) <850 mOsm/l- ionic and non ionic
- c) Iso osmolar (IO) 290 mOsm- non ionic

List of commonly used contrast agents is given below,

Product	Type of contrast agent concentration	Mg (l/ml)	Osmality (mOsm/l)
Monomers			
Iohexol (Ominipaque)	Nonionic LOCM	350	844
Iopamidol (Isovue)	Nonionic LOCM	370	796
Ioxilan (Oxilan)	Nonionic LOCM	350	695
Iopromide (Ultravist)	Nonionic LOCM	370	774
Iversol (Optiray)	Nonionic LOCM	350	792
Dimers			
Iodixanol (Vsipaque)	Nonionic IOCM	320	290
Ioxaglate (Hexabrix)	Ionic LOCM	320	600

Major adverse outcomes related to the use of current generation contrast media are, contrast induced nephropathy, anaphylactoid reaction and left ventricular failure. The other complications like arrhythmia, anticoagulation and negative inotropic effects are no longer encountered with use of non ionic contrasts.

## **Anaphylactoid Reactions**

Incidence is approximately 1%, and the incidence of severe reactions may be as low as 0.04%. Reaction is not related to iodine or IgE sensitization. It is usually due to mast cell degranulation induced by non iodine component of contrast media. Mild reactions like urticaria and mild bronchospasm can be managed with antihistaminics and steroids. Severe reactions like karioedema, shock and severe bronchospasm requires adrenaline, endotracheal intubation and fluid resuscitation. Rerecurrence rate without prophylaxis is 16% to 44%, reduced close to zero with pretreatment. Pretreatment with prednisolone 50 to 60 mg at least 2 to 3 times (12 hr, 6 hr and 1 hr) prior to contrast exposure and antihistaminics is recommended in patient with prior history of contrast induced anaphylactoid reaction.

## **Contrast- induced nephropathy (CIN)**

CIN has become a leading cause of in-hospital acute renal failure. It has been shown to have a significant adverse impact on the short- and long-term outcome of patients. Rihal et al reported 22% of patients with CIN died during the index hospitalization compared with only 1.4% of patients without CIN. CIN is defined as increase in serum creatinine over baseline by 48 hr, such as 25% above baseline or an absolute increase of 0.5 mg/dl. The course of CIN generally transpires over a period of about 10 days with a rise in creatine most often with 24 hr, peaking at 3-5 days, and the returning to baseline over the next 5 days.

### **Risk factors for CIN:**

<b>Patient-related Risk Factors</b>	<b>Procedure-related Risk Factors</b>
<ul style="list-style-type: none"><li>• Renal insufficiency</li><li>• Diabetes mellitus with renal insufficiency</li><li>• Age (&gt;75 years)</li><li>• Volume depletion</li><li>• Hypotension</li><li>• Low cardiac output</li><li>• Class IV CHF</li><li>• Other nephrotoxins</li><li>• Renal transplant</li><li>• Hypoalbuminemia (&lt;35 g/l)</li></ul>	<ul style="list-style-type: none"><li>• Multiple contrast media injection within 72 hrs</li><li>• High volume of contrast media</li><li>• High osmolality of contrast media</li></ul>

## **CORONARY ANGIOGRAPHY**

The first attempt to image the coronary artery began in the late 1940s. In 1953, Seldinger first introduced a method of percutaneous arterial catheterization to the coronary arteries. However, this percutaneous approach was not initially widely adopted. In the late 1950s, Sones developed a safe and reliable method of selective coronary angiography using a brachial cutdown approach to arterial access. In the late 1960s, Amplatz et al. and Judkins developed modifications of catheters for selective coronary angiography while also employing the percutaneous method previously introduced by Seldinger. This combination and modification of previous approaches ushered in the beginning of the modern era of coronary angiography as we recognize it today.

## **INDICATIONS FOR CORONARY ANGIOGRAPHY**

The American College of Cardiology/American Heart Association (ACC/AHA) Task force has established indications for coronary angiography in patients with known or suspected coronary artery disease.

Class I: There is evidence and/or general agreement that coronary angiography should be performed to risks stratify patients with chronic stable angina in the following settings:

- Disabling angina symptoms (Canadian Cardiovascular Society (CCS) class III and IV) despite medical therapy
- High-risk criteria on noninvasive testing independent of the severity of angina
- Survivors of sudden cardiac death or serious ventricular arrhythmia
- Symptoms and signs of heart failure
- Clinical features suggest that the patient has a high likelihood of severe coronary artery disease

Class IIa: The evidence or opinion is in favour of performing coronary angiography to risk stratify patients with chronic stable angina in the following settings:

- Left ventricular ejection fraction less than 45%, CCs class I or II angina evidence, on noninvasive testing, of ischemia that does not meet high-risk criteria
- Noninvasive testing does not reveal adequate prognostic information

Class IIb: The evidence or opinion is less well established for performing coronary angiography to risk stratify patients with chronic stable angina in the following settings:

- Left ventricular ejection fraction greater than 45%, CCS class I or II angina and evidence, on noninvasive testing, of ischemia that does not meet high-risk criteria
- CCS class III or IV angina that improves to class I or II with medical therapy
- CCS class I or II angina but unacceptable side effect to adequate medical therapy

Class III: there is evidence and/or general agreement that coronary angiography should not be performed to risk stratify patients with chronic stable angina in the following settings:

- CCS class I or II angina that responds to medical therapy and, on noninvasive testing, shows no evidence of ischemia
- Patient preference to avoid revascularization

## **CORONARY ANATOMY**

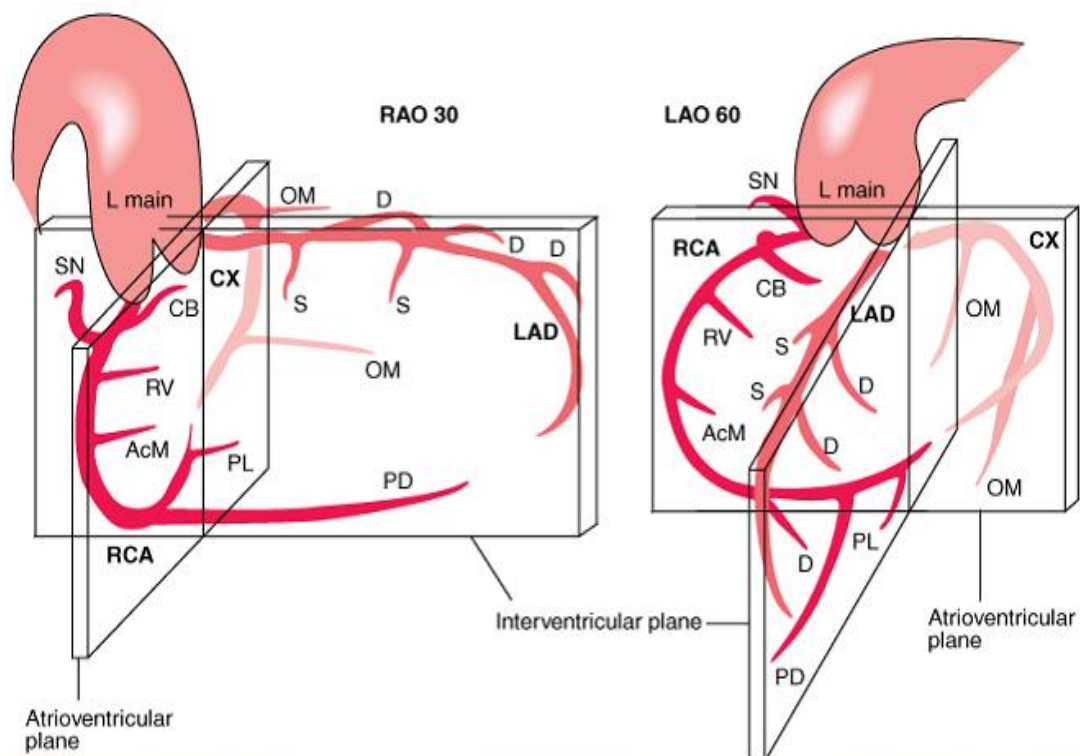
The coronary artery arises from the sinuses of Valsalva. The left main coronary artery arises from the left sinus. After a short course, the left main trunk (LMT) usually bifurcates into the left anterior descending (LAD) and left circumflex (LCX) coronary arteries. In some instances, it may trifurcate, with the ramus intermedius being the intermediate vessel in the trifurcation. The current classification of coronary anatomy is based on the CASS (Coronary Artery Surgery Study) system.

The LAD follows a course along the anterior interventricular groove to the apex of the heart, supplying blood the anterior wall, the septum via septal perforators, and the anterior wall via diagonal branches.

The LCX courses along the left atrioventricular groove, supplying the lateral wall of the left ventricle. The branches arising from the LCX are called obtuse marginals, with the first branch arising from the atrioventricular (AV) LCX called obtuse marginal 1, the second marginal called obtuse marginal 2, and so forth.

The right coronary artery (RCA) arises from the right sinus of Valsalva and travels along the right AV groove. The first branch that arises from the RCA is the conus branch, which supplies the right ventricular outflow tract. In approximately

50% of the cases, the conus branch has a separate origin. Localizing the conus branch may be important in selected cases because it is often a critical source of collateral circulation to the LAD. Other branches include the artery to the sinus node, which arises from the RCA 60% of cases; the acute marginal branches, which supplies the right ventricle; the artery AV node; the diaphragmatic artery; and terminal branches (i.e., the posteroventricular branches and the posterior descending artery (PDA) in most cases).



**Representation of coronary anatomy relative to the interventricular and atrioventricular valve planes.** Coronary branches are indicated as L main (left main), LAD (left anterior descending), D (diagonal), S (septal), CX (circumflex), OM (oblique marginal), RCA (right coronary artery), CB (conus branch), SN (sinus node), AcM (acute marginal), PD (posterior descending), PL (posterolateral left ventricular). RAO, right anterior oblique, LAO, left anterior oblique. [From DS Baim in *Grossman's Cardiac Catheterization, Angiography, and Intervention*, 7th ed, DS Baim (ed). Baltimore, Lippincott Williams &

The PDA, which courses along the posterior interventricular groove, determines coronary dominance. In 85% of the cases, the PDA arises from the RCA, making the coronary circulation right dominant. In 7% of the cases, the circulation is codominant, with the posterior posterior interventricular groove being supplied by both the RCA and the LCX. In 8% of the cases, the PDA arises from the left circumflex, making it the dominant artery.

Network of small anastomotic branches interconnect the major coronary arteries and serve as precursors for the collateral circulation that maintain

myocardial perfusion in the presence of severe proximal atherosclerotic narrowings. Collateral channels may not be seen in patients with normal or mildly diseased coronary arteries because of their small (<200  $\mu$ m) calibre. But, as CAD progresses and becomes more severe (>90% stenosis), a pressure gradient is generated between the anastomotic channels and the distal vessel that is hypoperfused. The trans-stenosis channels, which progressively dilate and eventually become visible with angiography as collateral vessels.

### **Injection Technique**

The contrast medium, a viscous, iodinated solution used to opacity the coronary arteries, can be injected by hand through a multivalve manifold the tip of the syringe is kept pointed down so that any small bubbles float up and are not injected into the circulatory system.

RCA: 6 ml at 3 ml/sec; maximal psi 450

LCA: 10 ml at 4 ml/sec; maximal psi 450

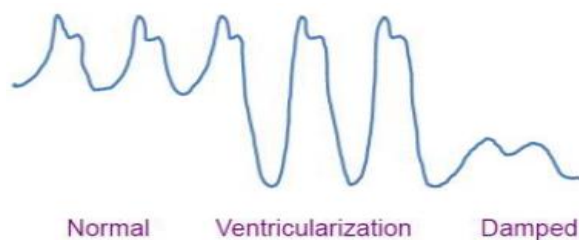
### **Cineangiographic Frame Rates**

Images may be acquired at different frame rates. A frame rate of 30frames/sec is commonly used. In some pediatric cases or if the heart rate is greater than 95 beats/min, the rate of 60 frames/sec can be used. In many adult laboratories, 15 frames/sec is standard.

### **Panning Techniques**

Most laboratories use X-ray image screen sizes (e.g., 7 inches or less in diameter) that may preclude having the entire coronary artery course visualized without panning over the heart to include the late filling portions of the arterial segments and any collaterals filling. In addition, in most views some degree of panning is necessary to identify regions that are not seen from the initial setup position. Some branches may unexpectedly appear later from collateral filling or other unusual arterial input sources.

## Damping and Ventricularization of the Pressure Waveform



A fall in overall catheter tip pressure (damping) or a fall in diastolic pressure only (ventricularization) during catheter engagement in a coronary ostium indicates obstruction of the catheter tip or interference with coronary inflow.

## ANGIOGRAPHIC PROJECTIONS

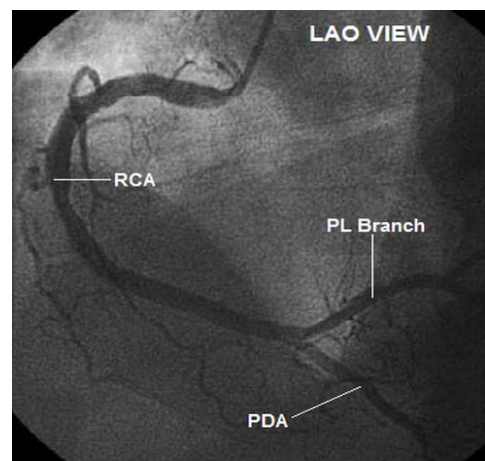
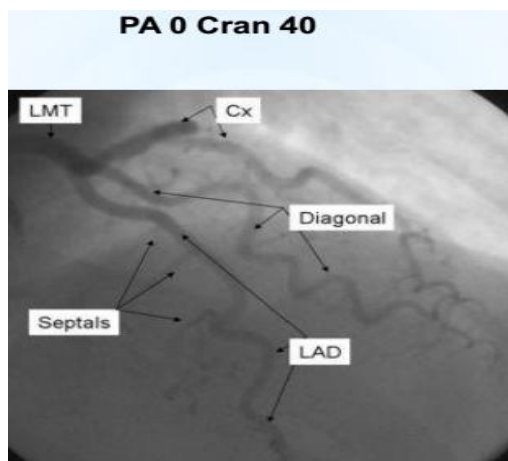
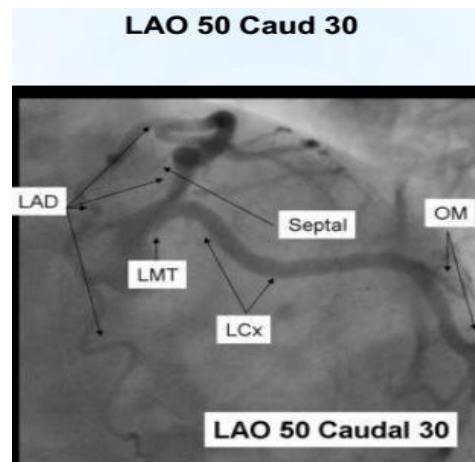
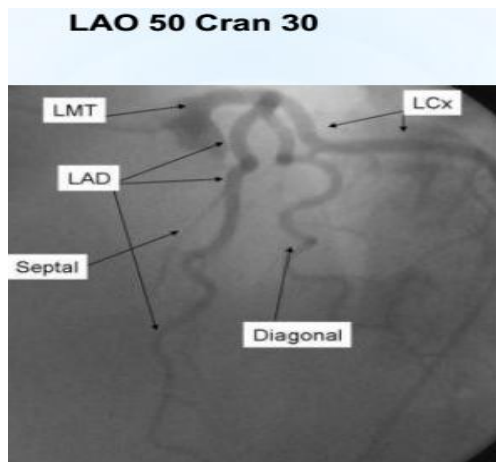
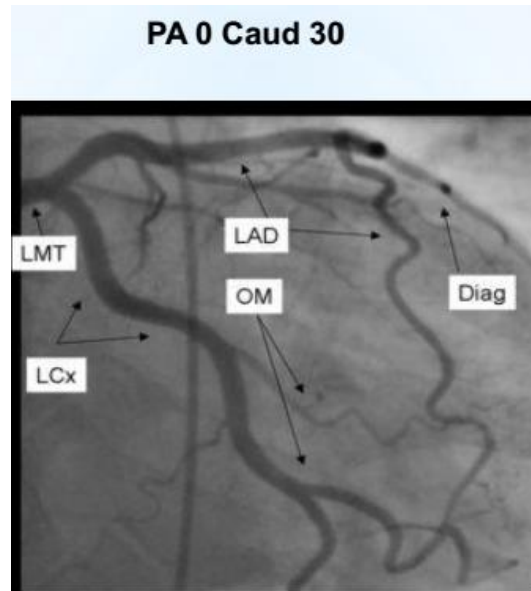
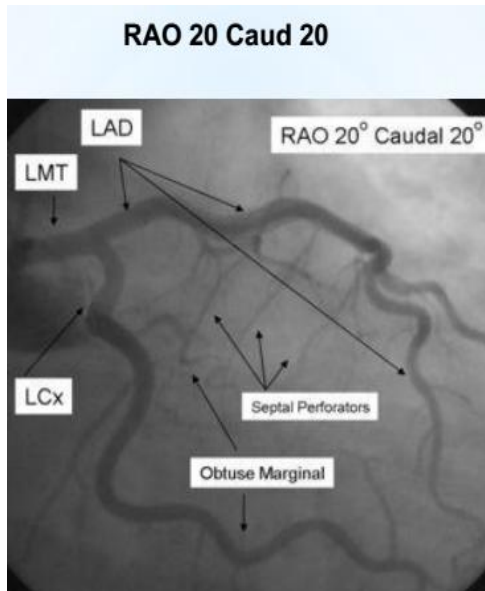
### **Nomenclature for angiography:**

- Anteroposterior (AP) position: the image intensifier is directly over the patient with the beam travelling perpendicularly back to front (i.e., from posterior to anterior) to the patient lying.
- RAO position: the image intensifier is on the right side of the patient.
- LAO position: the image intensifier is on the left side of the patient.
- Cranial /caudal position: this nomenclature refers to image intensifier angles in relation to the patient's long axis.
- Cranial: the image intensifier is tilted towards the head of the patient.
- Caudal: the image intensifier is tilted toward the feet of the patient.

### **Angiographic views for specific coronary artery segments:**

- |                       |   |                                     |
|-----------------------|---|-------------------------------------|
| • Left main           | - | AP, LAO cranial, LAO caudal         |
| • Proximal LAD        | - | LAO cranial, RAO caudal             |
| • Mid LAD             | - | LAO cranial, RAO cranial, Lateral   |
| • Distal LAD          | - | AP, RAO cranial, Lateral            |
| • Diagonal            | - | LAO cranial, RAO cranial            |
| • Proximal circumflex | - | RAO cranial, LAO caudal             |
| • Obtuse marginal     | - | RAO caudal, LAO caudal, RAO cranial |
| • Intermediate        | - | RAO caudal, LAO caudal              |
| • Proximal RCA        | - | LAO, Lateral                        |
| • Mid RCA             | - | LAO, Lateral, RAO                   |
| • Distal RCA          | - | LAO cranial, Lateral                |

- PDA - LAO cranial
- Posterolateral - LAO cranial, RAO cranial



## **BYPASS GRAFT ANGIOGRAPHY**

**Saphenous Vein Grafts:** The proximal anastomosis of most aortocoronary SVGs lies on the anterior surface of the aorta, several centimeters above the sinuses of Valsalva. Usually, the location of the various grafts in the relation to one another follows a predictable sequence. Grafts to the left circumflex artery (LCX) are typically placed most superior, followed by grafts to the diagonal branches, LAD, and RCA. Typically grafts to the right coronary artery can be best visualized and cannulated while in the left anterior oblique (LAO) projection; grafts to the left coronary artery (LCA) system are most easily found while in the right anterior oblique (RAO). If graft cannot be located, do not assume that the graft is occluded. Other catheters with different angulation may be necessary. If further attempts fail, aortography may be helpful in locating difficult to find grafts.

**Internal Mammary Artery Grafts:** The LIMA is often anastomosed to the mid-or distal LAD, although it is sometimes attached to the diagonal branches or the LCX instead. It typically arises anteroinferiorly from the left subclavian artery, 1 to 3 cm beyond the vertebral artery. Once engaged, the LIMA graft is injected in at least two projections, paying special attention to the anastomotic site. Forceful injections are discouraged. Straight RAO and LAO projections are most commonly employed. Cranial angulation can be added to either projection to better visualize the distal aspect of the LAD. A cross-table lateral view is sometimes helpful to gain an additional view of the anastomotic site.

Selective visualization of the right internal mammary artery (RIMA) is similar to that of the LIMA above, but it is more difficult. A JR4 or LIMA catheter is advanced into the proximal aortic arch past the origin of the innominate artery. The RIMA is often used as a “free” graft, with its proximal anastomosis in the ascending aorta. In this case, the procedure for cannulating the graft is the same as that for saphenous grafts.

## **LESION QUANTIFICATION**

### **QUANTITATIVE ANGIOGRAPHY**

Although visual estimations of coronary stenosis severity are used by virtually all clinicians to guide clinical practice, “eyeball” estimates of percent diameter stenosis are limited by substantial observer variability and bias. The assessment of intermediate coronary lesions (40-70%), having been largely supplanted by physiological measures of stenosis significance, most often fractional

flow reserve (FFR). Using hand drawn arterial contours, reference vessel and minimal lumen diameters were measured and were used to evaluate the effect of pharmacological intervention for a number of angiographic plaque regression studies.

### **LESION COMPLEXITY**

Heterogeneity of the composition, distribution and location of atherosclerotic plaque within the native coronary artery results in unique patterns of stenosis morphology in patients with CAD. Characteristics of type A, B, and C coronary lesions,

Type A lesions (high success, > 85%; low risk)	
Discrete (<10 mm) Concentric Readily accessible Non-angulated segment, <45° Smooth contour	Little or no calcium Less than totally occlusive Not ostial in locations No major side branch involvement Absence of thrombus
Type B lesions (moderate success, 60-85%; moderate risk)	
Tubular (10-20 mm length) Eccentric Moderate tortuosity of proximal segment Moderately angulated segment, ≥45°, <90° Irregular contour	Moderate to heavy calcification Total occlusion < 3 months old Ostial in location Bifurcation lesion requiring double guidewire Some thrombus present
Type C lesions (low success, < 60%; high risk)	
Diffuse (> 2 cm length) Excessive tortuosity of proximal segments, ≥ 90°	Total occlusion > 3 months old Inability to protect major side branches Degenerated vein grafts with friable lesions

### **LESION LENGTH**

Lesion length may be measured using a number of methods, including measurement of the “shoulder-to-shoulder” extent of atherosclerosis narrowed by more than 20%, quantifying the lesion length more than 50% narrowed, and estimating the distance between the proximal and the distal angiographic “normal” segment. The last method is used most commonly in clinical practice and provides a longer length than more quantitative methods.

## **OSTIAL LESION**

Ostial lesions are defined as those arising within 3 mm of the origin of a vessel or branch and can be further characterized into aorto-ostial and non-aorto-ostial. Aorto-ostial lesions are often fibro calcific and rigid, sometimes requiring additional ablative devices – such as rotational atherectomy (RA) in the presence of extensive calcification – in order to obtain adequate stent expansion.

## **BIFURCATION LESIONS**

The optimal strategic approach for bifurcation lesions remains controversial. The risk for side branch occlusion during PCI relates to the relative size of the parent branch vessel, the location of the disease in the parent vessel and the stenosis severity in the origin of the side branch. In general, placement of one stent in the larger vessel (usually the parent) is preferable to stent placement in both parent vessel and the side branch.

## **ANGULATED LESION**

Vessel angulations should be measured in the projection with the least amount of foreshortening at the site of maximum stenosis. Balloon angioplasty of angulated lesions increases the risk of dissections, although with the advent of coronary stenting, this is now most often readily treated.

## **LESION CALCIFICATION**

Coronary artery calcium is an important marker for coronary atherosclerosis.

**THROMBUS:** conventional angiography is a relatively insensitive method for detecting coronary thrombus. However, its presence is associated with a higher risk of procedural complications, primarily relating to embolization of thrombotic debris into the distal circulation. Large intracoronary thrombi are most often noted as intraluminal filling defects during angiography in STEMI and may be treated with a combination of pharmacological agents (e.g., glycoprotein IIb/IIIa inhibitors) and mechanical devices (e.g., rheolytic thrombectomy, manual aspiration catheters).

**TOTAL OCCLUSION:** Total coronary vessel occlusion is identified as an abrupt termination of an epicardial vessel. Anterograde and retrograde collaterals may be present and are helpful in quantifying the length of the totally occluded segment. The success rate of passage of a coronary guidewire across the occlusion depends on the occlusion duration and on certain lesion morphological features.

**CORONARY PERFUSION:** Perfusion distal to a coronary stenosis can occur anterograde by means of the native vessel, retrograde through collateral, or through a coronary bypass graft. The rate of anterograde coronary flow is influenced by both the severity and complexity of the stenosis and status of the microvasculature.

## PHYSIOLOGIC ASSESSMENT OF ANGIOGRAPHICALLY INDETERMINATE CORONARY LESIONS

### FRACTIONAL FLOW RESERVE (FFR)

Fractional flow reserve (FFR) is a widely employed technique in the evaluation of the significance of a coronary artery stenosis identified during coronary angiography. Coronary lesion assessment when hemodynamic significance is unknown or in doubt. Angiographic lesions, especially eccentric or of intermediate severity (40%-70% diameter narrowed), are most commonly assessed. For accurate FFR measurements, the following are essential requisites:

- Accurate pressure measurement.
- Appropriate placement of pressure wire distally.
- Adequate hyperemia

Definition of FFR:

$$\frac{\text{Maximum achievable blood flow in stenotic coronary artery}}{\text{Maximum blood flow in the same artery without stenosis}}$$

- FFR is the ratio of hyperaemic myocardial flow in the stenotic territory ( $Q_s^{\max}$ ) to normal hyperaemic myocardial flow ( $Q_N^{\max}$ ):  $FFR = Q_s^{\max} / Q_N^{\max}$
- Since the flow (Q) is the ratio of the pressure (P) difference across the coronary system divided by its resistance (R), Q can be substituted as following:

$$FFR = [(P_d - P_v) / R_s^{\max}] / [(P_d - P_v) / R_N^{\max}]$$

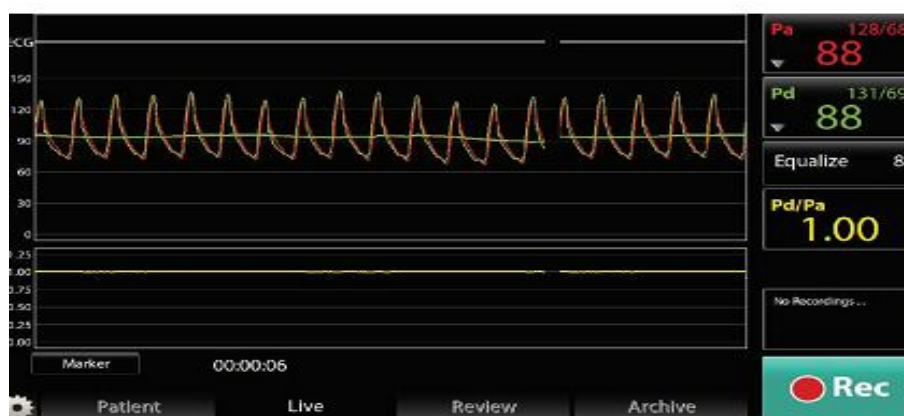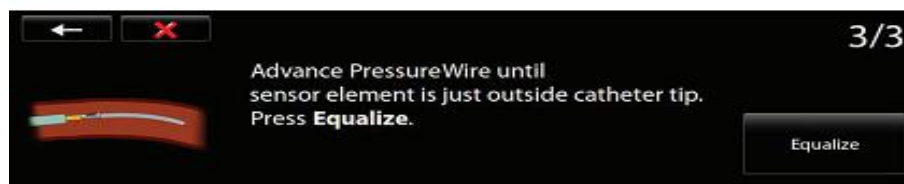
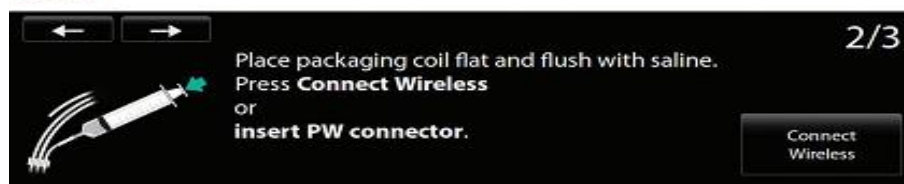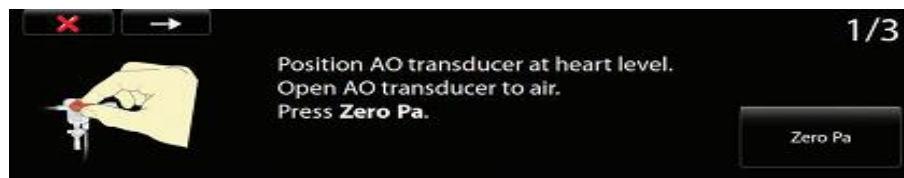
- Since measurements are obtained under maximal hyperaemia, resistances are minimal and therefore equal, and thus they cancel out. In addition  $P_v$  is negligible as compare to  $P_a$  or  $P_d$ , therefore:

$$\mathbf{FFR = Pd/Pa, at maximum hyperaemia}$$

## Procedural Details

The following steps are advised in the set up for accurate FFR measurements.

1. Ensure that connection of the pressure wire to the connector is finger-tight. Adequate flushing of wire while still in package with normal saline, and connection of the wire-system to the console and pressure transducers.
2. Administer heparin for anticoagulation; an activated clotting time more than 250 seconds is generally recommended.
3. When the pressure wire is advanced into the coronary artery and the transducer is at the level of the guide catheter tip, pressure equalization is performed. Thereafter, wait for 1 minute to determine that the signal is constant and drift is absent. If there is significant change of the ratio 1.00 during this brief period of wait, the operator may opt to repeat equalization or use another pressure wire.



Avoid guide catheter with side holes or which causes wedging with damping of the guide catheter waveform. The pressure waveforms as obtained by the guide catheter and pressure wire should be of classical morphology with your typical dicrotic notch and perfect super imposition. Although it is possible to perform an FFR study using a pressure wire inserted via a diagnostic catheter, this is generally not advised because wire manipulation is more difficult from the increased friction and reduced support.

4. Advance pressure wire across the stenosis and place it in the distal third of the vessel. Where there are several branches distally, choose the largest branch for placement of the guide wire. The pressure wire transducer should be positioned at least 3 cm beyond the distal lesion (this is usually the length of the distal marker).
5. Ascertain the ratio of the distal pressure (Pd) to the central aortic pressure (Pa): resting Pd/Pa ratio. Although a value less than 0.80 would suggest hemodynamic significance, a formal FFR measurement is useful in evaluating improvement following coronary intervention.
6. Administer intracoronary nitrate 200 mcg to remove coronary artery spasm, which may contribute to a reduced Pd. Thereafter administer the hyperaemic agent:
  - Intravenous (IV) adenosine at 140 mcg/kg/min via a central vein
  - Intracoronary (IC) adenosine 40-80 mcg
  - IC papaverine 15-20 mg for the left coronary artery and 10-15 mg right coronary artery.

For drugs administered intracoronary, remember to disengage the guide catheter after administration if there is a possibility of ostial disease. This is to ensure that the guide catheter measures the true central Pa and not result in a falsely elevated FFR from guide catheter damping in ostial disease.

Wait several seconds to ensure a stable signal before recording the FFR value. The lowest value as given by the pressure wire console may be spurious and due to artifacts. It is important that the interventional cardiologist look at the pressure data and calculation of FFR be performed only during steady state hyperaemia. With IV adenosine or IC papaverine, a pullback gradient can be performed to assess for the performance diffuse coronary artery disease. A pullback of the pressure wire back to the original position where equalization was performed should always be done to exclude drift.

Pressure wire drift refers to the situation where signal instability results in a drift of the baseline pressure as measured by the pressure wire. This will result in a different pressure measurement and an erroneous FFR value.

## **INTERPRETATION**

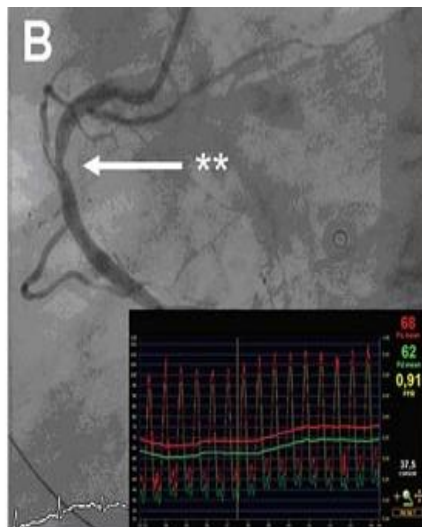
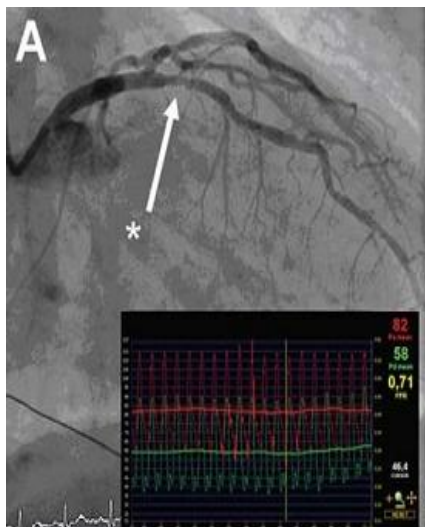
The FFR tracing on pullback provide information on the interrogated coronary artery. In general, a pressure gradient of 10 mm Hg indicates a hemodynamically significant stenosis and this can be useful when pullback is performed across serial stenoses. Where there is a gradual normalization of the pressure gradient on pullback of the pressure wire, this indicates diffuse atherosclerotic disease and the patient is unlikely to benefit from coronary artery stenting, which addresses focal stenotic lesions.

The advantage of the pressure wire pullback is to ascertain for the presence of diffuse disease and exclude pressure wire drift, which can results in a significant deviation of the FFR from the true value.

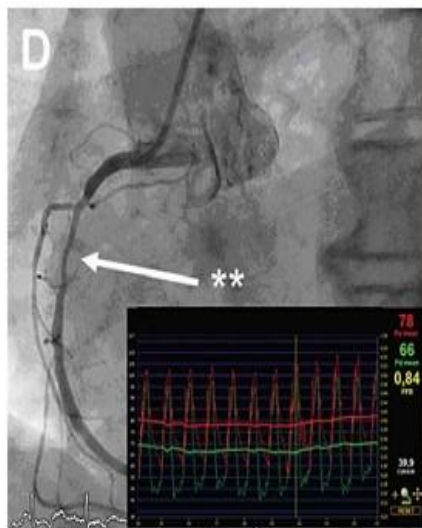
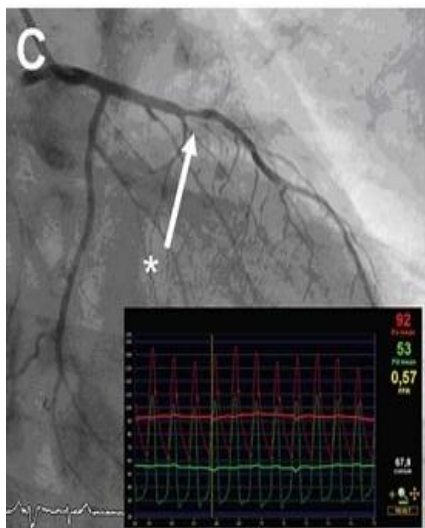
Beat averaging may be useful in situations where the patient's heart rate is irregular. This will result in a more consistent Pd/Pa ratio. The default setting for most consoles is to average the pressure measurement over three beats. The console offers the option of changing this from one or higher beat averaging. This may be useful in situations when the patient has irregular heart rate.

Currently, a threshold FFR value of less than 0.80 is used indicate hemodynamic significance. An FFR value of less than 0.75 is through to have 100% sensitivity to detecting ischemia as compared to noninvasive tests. The range 0.75-0.80 represents a "gray-zone" where interpretation should especially be considered with the patient's clinical context. Like any medical test, FFR measurements should never be considered isolation.

In a patient with an active lifestyle presenting with unstable angina symptoms and an isolated type A lesion of the proximal left anterior descending artery with an equivocal FFR value, the interventional cardiologist may be more inclined to ad hoc interventions. In contrast, an elderly sedentary patient with diffuse disease of a branch vessel and equivocal FFR value may not justify ad hoc coronary intervention.



(A, B) Two lesions in one patient from the FAME trial, both categorized as 50–70% stenosis by angiography. FFR demonstrated only lesion A was functionally significant ( $\leq 0.80$ ). (C, D) Two lesions in one patient from the FAME trial, both categorized as 70–90% stenosis by angiography. FFR demonstrated only lesion C was functionally significant and so was stented.



FFR is the best choice for assessing functional significance of lesions and identifying what to treat.

Several caveats should be considered when interpreting FFR values. These can be classified into three main categories:

- Technical issues: These may include the use of guide catheters with side holes or pressure wire drift.
- Suboptimal hyperaemia: This problem commonly arises from intracoronary administration of adenosine. It is not addressed by escalating bolus dose of adenosine.
- Physiological interpretations: with few exceptions, the FFR is an accurate measure of the hemodynamic significance of a stenosis. In the presence of multi-vessel coronary artery disease, an alternative culprit lesion should be considered if an angiographically “significant” stenosis turned out not to be so on FFR measurement. Alternative explanations could include the presence of collateral, infarcted myocardium, and small territory involvement.

Situations where measured FFR is spuriously elevated (i.e., falsely negative) include the presence of severe left ventricular hypertrophy, during the context of a ST-elevation myocardial infarction (STEMI) and coronary artery spasm as cause of the patient's symptoms. Conversely, the measured FFR may be spuriously low (i.e., falsely positive) when the patient is grossly fluid-overloaded. In these situations, the interventional cardiologist would have to consider the measured FFR value in the context of the physiological states that may affect the FFR value.

## **PERCUTANEOUS CORONARY ARTERY INTERVENTION**

Coronary balloon angioplasty was first performed in 1977.

Percutaneous:- refers to the nonsurgical insertion of a catheter into the body through a small puncture site in the skin, into an artery.

Coronary:- identifies the specific artery to be dilated

Intervention:- a technique for remodelling a blood vessel through the introduction of an expandable stent, balloon catheter, or other specialized tool treating a diseased artery

Percutaneous transluminal coronary angioplasty (PTCA) expands the coronary lumen by stretching and tearing the atherosclerotic plaque and vessel wall and, to a lesser extent, by redistributing atherosclerotic plaque along its longitudinal axis. Elastic recoil of the stretched vessel wall generally leaves a 30-35% residual diameter stenosis, and the vessel expansion can result in propagating coronary dissections, leading to abrupt vessel closure in 5-8% of patients.

### **Indications for PCI:**

- Angina pectoris causing sufficient symptoms despite optimal medical therapy
- Mild angina pectoris with objective evidence of ischemia (abnormal stress testing or physiology) and high-grade lesion (>70% diameter narrowing) of a vessel supplying a large area of myocardium
- Unstable angina
- Acute myocardial infarction (MI) as primary therapy or in patients who have persistent or recurrent ischemia after failed thrombolytic therapy
- Angina pectoris after coronary artery bypass graft surgery
- Restenosis after successful PCI
- Left ventricular dysfunction with objective evidence of viability of a vessel supplying the myocardium

- Arrhythmia secondary to ischemia

### **Contraindications for PCI:**

- Unsuitable coronary anatomy
- Extremely high-risk coronary anatomy in which closure of vessel would result in patient death
- Contraindications to coronary artery bypass graft surgery (however, some patients have PCI as their only alternative to revascularization)
- Bleeding diathesis
- Patient noncompliance with dual antiplatelet therapy and unwillingness to follow post-PCI instructions
- Multiple in stent restenosis
- Patient who cannot give informed consent

### **PCI procedure**

- Guiding catheter selected for angle of vessel takeoff and optimal backup
- Guiding catheter is seated; coaxial alignment is best
- Guidewire is advanced beyond target vessel stenosis to distal position
- Balloon stent is inserted through hemostasis valve on guiding catheter
- Balloon stent is advanced into center of lesion
- Balloon stent is inflated; adequate inflation pressure (to remove dumbbell indentation of lesion on partially inflated balloon) must be used; a balloon may be inflated for 10 to 30 seconds as tolerated; stents are usually inflated for 10 to 20 seconds
- Assessment of the balloon/stent dilation result: enlarged artery lumen, good angiographic flow, observe for adverse angiographic markers and no residual ischemia

### **CORONARY ATHERECTOMY**


Because the atherosclerotic plaque remains in the artery after balloon dilation, physical removal of the plaque from inside the coronary artery may improve procedural and clinical results. Three devices are developed for this purpose, but only the high speed rotator remains in use today. Directional atherectomy catheter (DCA) is used for peripheral vascular disease, and the transluminal extraction catheter has been retired.

## **ROTATIONAL ATHERECTOMY (ROTABLATOR)**

Utilizes a high speed rotating diamond coated burr to ablate atherosclerotic plaqued and restore luminal patency. Rotates 160,000 rpm for smaller burrs and 140,000rpm for burrs bigger than 2 mm. The plaque is ablated into small particles which are removed by the reticulo-endothelial system of the body. The resultant lumen is often smooth and free smooth and free of dissection Vs PTCA where there are significant dissections.

The rotation works on two principles:

1. Differential cutting and
2. Orthogonal displacement of friction



### **THE ROTABLATOR SYSTEM**

The rotablator works on a compressed air / gas system. Either we can use a higher pressure compressed air / nitrogen cylinder or we can use an online system of air compressor. There should be a pressure of 6.5 to 7.5 bar in the cylinder, otherwise the system is better because it is often difficult to maintain the required pressure in the high pressure gas cylinders and other logistic issues like transportation etc.

In addition to the console and the high pressure gas system, there is the foot pedal for activating the rotablator and the dynaglide. There should be a saline

flush continuously flowing to allow smooth rotation and also to cool the rotating parts. The pressure in the saline flush system should be 300 mmHg.

## HARDWARE FOR ROTABLATION

### Console

rotational speed display (tachometer)

procedure timer

reset button

turbine pressure gauge (delivered to advancer)

event timer

turbine pressure control knob (adjusts RPM)

power switch

power lamp

Dynaglide™ connector

advancer turbine (pneumatic) connector

### Air Supply Set Up

Dual Gauge Regulator Byrme

- Monitors gas delivered to console (90 - 110 PSI)
- Monitors gas contained in tank (minimum 500 PSI per case)

H Cylinder Tank

Compressed Air or Nitrogen

power cord

Dynaglide™ connectors

### Foot Pedal

Dynaglide button

Dynaglide indicator illuminated on RPM display on console

### Disposables

#### Components

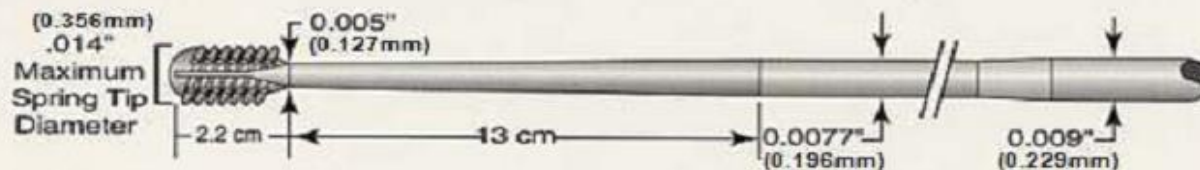
Advancer

Burr catheter

WireClip® Torquer & Guidewires

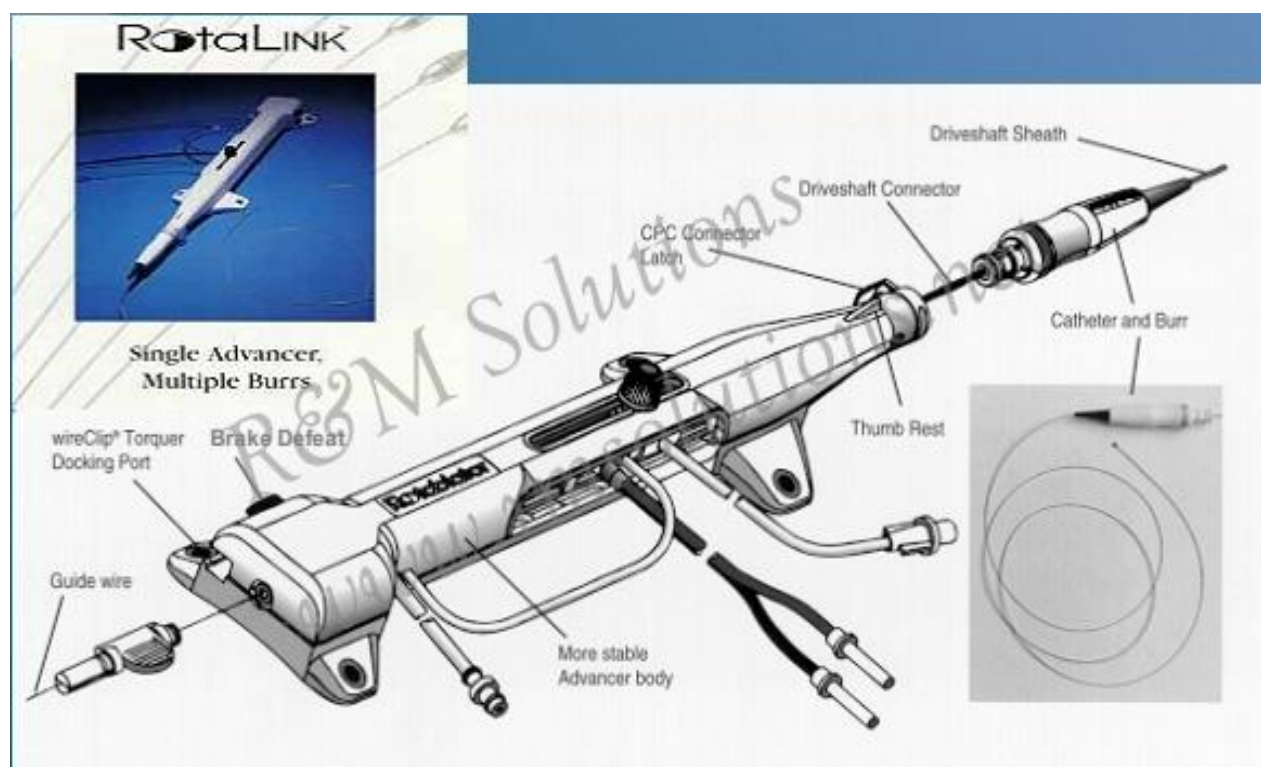
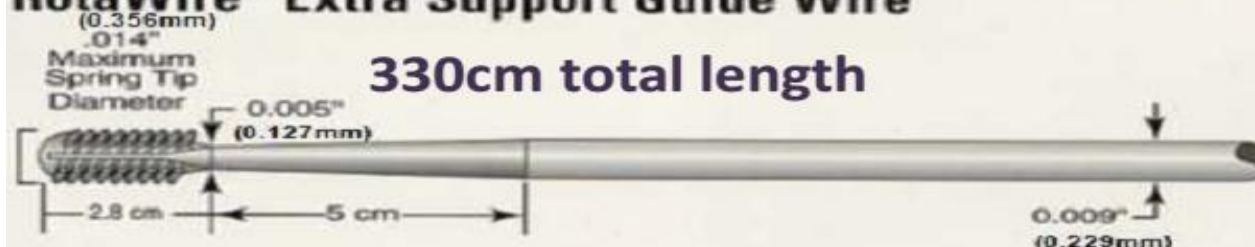
## RotaWire™ Floppy Guide Wire

330cm total length



## RotaWire™ Extra Support Guide Wire

330cm total length



**Rota wire:** Tip is 0.014, body is 0.009. There are two types of wires. Floppy and Extra-support. The tip of the wire has a short soft spring tip, 2.2 cm in length.

**Rotablator burrs:** Vary in size from 1.25 to 2 mm at 0.25 mm increments. After 2mm, the sizes available are 2.15, 2.25, 2.38 and 2.50 mm.

### INDICATIONS FOR ROTABLATION

- Calcified lesions, for facilitating stent delivery and expansion;
- Un-dilatable lesions, (fibrotic) for facilitating stent delivery and expansion;
- Ostial lesions, for reducing plaque shift and side-branch occlusion;

- In selected cases of diffuse in-stent restenosis – (for decreasing intimal hyperplasia volume and subsequent balloon slippage and for subsequent balloon slippage and for reducing the need for re-stenting).

### **Main Precautions – Before Rotablation**

- Patients who are not candidates for coronary artery bypass surgery
- Patients with severe, diffuse three-vessel disease (multiple diseased vessel should be treated in separate sessions);
- Patients with unprotected left main coronary artery disease
- Patients with ejection fraction less than 30%
- Lesions longer than 25 mm
- Angulated > 45° lesions
- Post balloon dilatation, if there is significant dissection

### **Procedure**

- Guide catheter – 7F-9F (depending on the final expected burr size)
- Prophylactic pacing catheter – rota on RCA or dominant LCX
- 0.65 to 0.85 final burr- to-artery ratio
- Smaller burr may be used to begin treatment
- Setup burr sizes in maximum of 0.5mm increments.
- Smaller burr should be selected on: tortuosity, eccentricity, angulations >60°

### **THROMBECTOMY**

Intravascular, and especially intracoronary thrombus, can be aspirated, manually with several available manual aspiration catheters or a high pressure rheolytic thrombectomy system. The Angiojet catheter uses high-pressure water jets directed backward into the catheter to create a strong suction at the space near the tip and effective thrombus evacuation occurs. Manual aspiration thrombectomy catheters are used to remove thrombus and have been shown to reduce mortality in patient with MI who undergo primary PCI.

### **EMBOLIC PROTECTION DEVICES FOR VENOUS BYPASS GRAFT PCI**

**Distal embolic filters:** distal filter devices are advanced across the target lesion over a standard coronary wire in their smaller collapsed state and retaining sheath is withdrawn, allowing the filter to open and to expand against the vessel wall.

**Distal occlusion device:** the device is passed across the target lesion and the balloon is gently inflated to occlude flow. The PCI then performed and the debris liberated by intervention remains trapped in the stagnant column of blood.

**Proximal occlusion devices:** the third type of EPD occludes flow into the vessel with a balloon in the proximal part of the graft. Two proximal occlusion devices are currently use: (1) the proxies catheter (2) the Kerberos embolic protection system.

### **PRIMARY ANGIOPLASY**

ST elevation MI accounts for 25 to 40% of acute coronary syndrome events worldwide. ST elevation MI is caused by the total occlusion of an epicardial artery by a thrombus. The nidus for thrombous formation could be an ulcerated plaque or erosion on the endothelial surface of the vessel. Reperfusion strategies have been tailored to re-establish flow in the occluded artery. The two reperfusion strategies available are fibrinolysis and primary PCI. Primary PCI is the catheter based reperfusion modality geared to re-establish flow.

Reperfusion therapy has to be administered to all patients with STEMI within the windows period of 12 hours and primary PCI is the preferred mode of reperfusion.

### **INTRAVASCULAR ULTRASOUND (IVUS)**

Intravascular ultrasound (IVUS) is a tool with many applications. It identifies and better characterizes plaques which are not visualized by angiography, which essentially a lumenogram.

#### **Principle of IVUS**

The IVUS probe is essentially designed as a catheter with a miniaturized ultra song probe at its distal tip which has a piezoelectric crystal capable of emitting ultrasonic waves in the 20-50 MHz range. The reflected ultrasound waves are interpreted by a computer based algorithm and are used to recreate two-dimensional cross-sectional tomographic views of the vessel wall. These images can be used to calculate cross-sectional area, diameters of the vessel wall at various points of the vessel of interest and thus help in assessing the true severity of the atherosclerotic lesion together with a fair idea of its underlying morphology.

## **Basic Setup of IVUS**

Consider of two basic components:

1. Catheter with miniaturized ultrasound probe
2. Console and electronics for reconstructing and interpreting the image.

The ultrasound probe in use have a frequency between 20 MHz and 50 MHz, which gives them an axial resolution of 150  $\mu\text{m}$  and come in different sizes varying from 2.6 to 3.5 French which can be placed through 6F guide catheter. There two available transducer designs-mechanically rotated devices and phased array/solid state transducers.

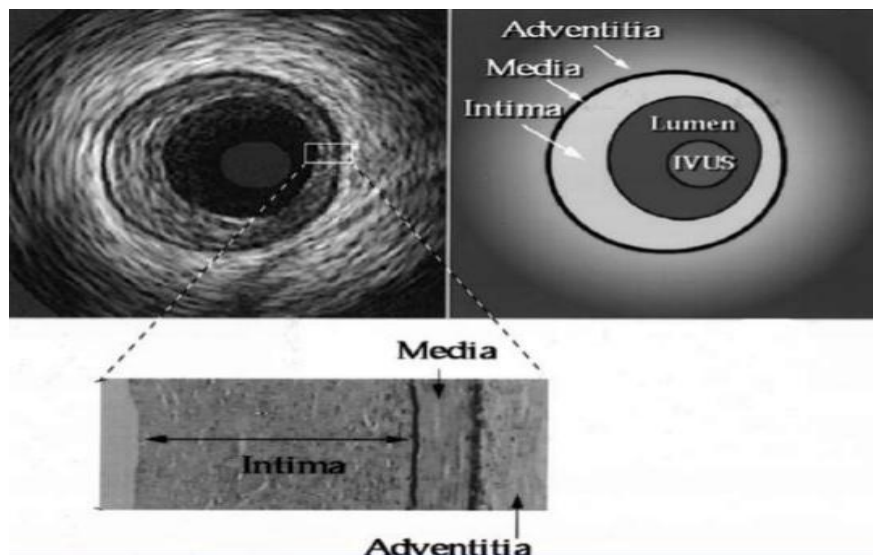
## **Indications:**

- Evaluation of lesion severity at a location difficult to image by angiography in a patient with a positive functional study and a suspected flow-limiting stenosis
- Assessment of a suboptimal angiographic result after PCI
- Diagnostic and management of coronary disease after cardiac transplantation
- Assessment of the adequacy of deployment of coronary stent, including the stent apposition and determination of the minimal luminal diameter within the stent
- Determination of plaque location and circumferential distribution
- Determination of the mechanism of stent restenosis (inadequate expansion versus neointimal proliferation) and to enable selection of appropriate therapy (plaque ablation versus repeat balloon expansion)
- Preinterventional assessment of lesion characteristics as a means of selecting an optimal revascularization device

## **Examination Technique**

The ultrasound transducer which has a radiopaque marker is positioned beyond the point of interest and a pullback examination is done. Pullback can be manual or motorized (0.5 mm/sec). The latter has smoother image acquisition. Side branches useful landmarks to facilitate interpretation and comparisons in sequential examinations.

The coronary artery is essentially a trilaminar structure, the normal intima gives a thin bright echo and is the innermost structure nearest to the transducer. The media which comprises muscle cells gives a dark signal just underlying the intima. The adventitia is the outermost structure and has an onion skin appearance. The onset of atheroma formation leads to thickening of the intima.



### **Plaque characterization**

Plaque can be broadly classified based on their appearance as – soft, fibrotic or calcific. The soft plaque has an echogenic signal which is lighter than the adventitia. The fibrous plaque on the other hand throws a brighter signal which is equal or brighter than the adventitia. Majority of the plaque observed in IVUS are fibrotic. The calcified plaque is the brightest of the three and gives reverberating negative shadows. A soft plaque with a dark signal suggesting the presence of a necrotic core, one see this plaque in its ruptured form called the “ruptured plaque”.

With the use of IVUS, it is easy to calculate the minimal lumen area (MLA) and plaque burden of concentric or eccentric lesions at single/multiple points.

## **OPTICAL COHERENCE TOMOGRAPHY (OCT)**

The intravascular ultra sound (IVUS) and optical coherence tomogram (OCT), both these technologies have advanced rapidly to achieve a tomographic reconstruction of the coronaries without significantly interrupting the coronary perfusion.

### **Principles and Basics**

The basic principles of OCT consist of a single mode optic fiber that transmits and receives infrared light waves at a bandwidth of 1,250-1350 nm which is the ideal spectral range for imaging biological tissue. The received signal depending on the tissues characters (that determines the back scatter and attenuation) is reconstructed and displayed in cross section. The back scattered optical echoes are processed based on the frequency change (frequency domain) or time change (time domain). As the speed of light is extremely high a reference mirror is used in the time domain OCT to calculate the relative rather than the absolute change. Processing of frequency domain OCT signals has better spatial and temporal resolution. The present generation OCT use only FD-OCT. optical resolution is the measure of the smallest physical feature that can be detected using an imaging system and it is dependent on the wave length and band width light. The light speed of light waves produces an axial resolution of 10-20  $\mu\text{m}$  that is ten times higher than IVUS. As blood is opaque to light it has to be replaced with a transparent medium like the angiography contrast or dextran.

### **Hardware**

The present OCT system that available in India is from St. Jude Medical and it has a console that can be connected to rapid exchange imaging catheter through a Drive Motor & Optical Controller (DOC) for motorized automatic pull through. The console has two monitors with user interface for feeding patient data, reviewing the archive, manual and automated measurements and for zooming and switching the planes of the port for connecting the sterile single use imaging catheter.

## DOC Controls Optis

- 1 Emergency shutoff – stops rotation, pullback and scanning
- 2 Enable scanning; second push will start pullback in manual trigger mode
- 3 Toggle between Live and Standby
- 4 Unload catheter



The imaging catheter consists of an optical fiber core mounted in a rapid exchange catheter system measuring 135 cm in length and 2.7F maximum cross sectional diameter that is compatible with a guide catheter of 6F or more. The distal end of the catheter has two radio-opaque markers 20 mm apart that facilitates angiographic measurement of the segment to be imaged target. The optical lens in its forward position is just proximal to the proximal marker up to 50 mm or 75 mm with the present generation catheters. The time for image acquisition is about 3 seconds and only transient interruption of blood flow is required. In the newer catheters an additional radio-opaque marker is placed over the optical fiber for angiographic visualization of the automated pull through which helps to correlate the image in relation to angiography.

During pull through the imaging the core rotates rapidly and acquires continuous lines of images (1024 pixels/line). One complete (360 degree) spin of the optical fiber acquires 500 image lines and constitutes one frame. Axial resolution is along the line of acquisition (10  $\mu$ ), lateral resolution is between the line in the same frame (25  $\mu$ ) and longitudinal resolution between different frames. As the core is simultaneously pulled back during rotational acquisition a cylinder of vessel is imaged in a spiral manner which can be displayed axially, longitudinally and in 3 dimensions also.

### Image Interpretation

The reflected optical echoes depending on the property of tissues attenuate or backscatter the light. A high attenuation reduces the depth of penetration and makes the deeper structures darker. Borders are created at the interface between two different issue types.

**Normal vessel:** all the three layers can be seen clearly as a trilaminar appearance. The intima is signal rich and bright, the media is relatively signal poor and homogeneously dark whereas the adventitia is heterogeneously signal rich. The internal and external elastic lamina can also be seen in some cases as small bright lines at the borders. Intimal thickness up to 300  $\mu\text{s}$  considered normal and visualization of media is a prerequisite to measure the intimal thickness.

**Fibrous plaque:** homogenous bright signal rich finely textured area with low attenuation, i.e. deeper structures will also be seen easily through the plaque.

**Lipid plaque:** lipid core produces a higher attenuation and hence the deeper structures beyond a lipid rich plaque may not be visible and the margins are not well defined.

**Calcified plaque:** A calcified plaque has low attenuation and low back scatter hence appears as a heterogeneous dark area (signal poor) with well-defined margins.

**Red thrombus:** An intraluminal filling defect with high back scatter from the surface with the darker core and poor visualization of deeper structures due to high attenuation.

**White thrombus:** irregular intraluminal filling defect with high back scatter and low attenuation, hence deeper structures would be visible.

**Thin cap fibro-atheroma (TCFA):** similar characteristics of a lipid rich plaque with an intimal cap are less than 65  $\mu$ . Accumulation of macrophages can also be seen as signal rich linear areas.

**Evaluation of stents:** the leading edges of metallic stents have high attenuation and back-scatter hence produces bright short arcs with dark shadows behind due to attenuation. The struts of bioresorbable scaffolds (BVS) produce rectangular box like appearances with brighter outer border and a darker central area.

**Stent apposition, coverage, tissue prolapse, neointimal hyperplasia and neoatherosclerosis:** Immediately after deployment of a stent, the stent artifacts can be seen at the luminal surface. If there is a separation of stent struts from the vessel wall that is not across a side branch it qualifies for incomplete stent apposition. Malapposition can be considered only when the distance from the endoluminal surface of the strut to the vessel wall is higher than the sum of the metal and the polymer thickness together. With the formation of neointima the stent struts get buried and the artifacts are seen starting deeper from the vessel wall and any

amount of neointima is considered coverage and is more than 90% complete by 6 months after any DES. Percentage of neointima is calculated by the fraction of the difference between the stent area and the lumen area to the stent area. If this is more than 50% it is called significant neointimal hyperplasia. Accumulation of lipids within the neointima leads to neo atherosclerosis which can rupture and present as very late stent thrombosis. There can be structures seen protruding through the stent struts on OCT imaging which may be thrombus or tissue prolapsed.

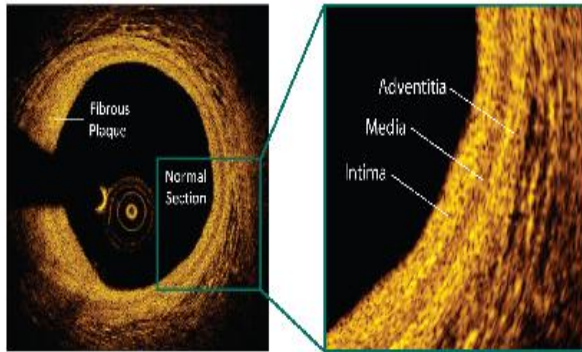
The development and utilization of OCT imaging has led to deeper insights and understanding of coronary artery disease, in particular the nature of atherosclerotic plaque, the vessel wall interactions with the artificial stents, drugs and polymers incorporated in it, the immediate and long-term outcomes of percutaneous interventions. In general, IVUS with good penetration is considered good for preprocedural evaluation and OCT with high resolution is considered good for evaluation of post PCI as it shows endoluminal structure clearly. These technologies continue to evolve at an exponential pace and future sophisticated catheterization laboratories are predicted to have integrated intravascular imaging systems.

#### **Comparison of OCT and IVUS**

	OCT	IVUS
Axial resolution	12-15 mm	100-200 mm
Frame rate	100 frames/sec	30 frames/sec
Pullback speed	20 mm/sec	0.5-1 mm/sec
Maximum scan diameter	10 mm	15 mm
Tissue penetration	1.0-2.0 mm	10 mm
Lines per frame	500	256
Lateral resolution(3 mm artery)	19 mm	225 mm
Blood clearing	Required	Not required

# IMAGE GUIDE

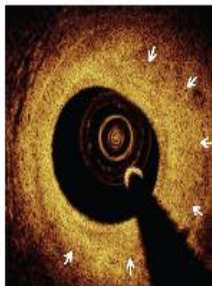
## Coronary Anatomy by OCT



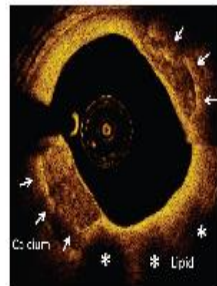
Coronary Artery Anatomy

Zoom-in View Normal Section

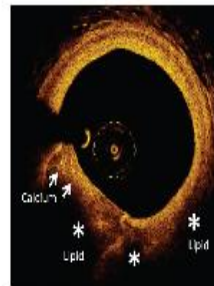
## Coronary Plaque Characterization



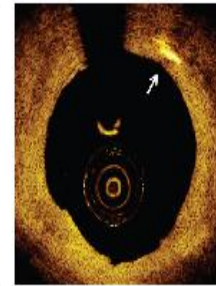
Fibrous Plaque



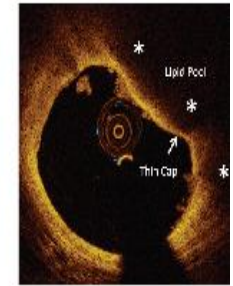
Calcium & Lipid Plaques



Mixed Plaque

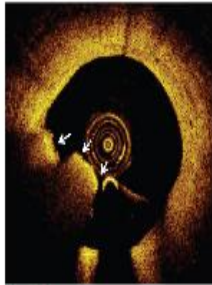


Cholesterol Crystal

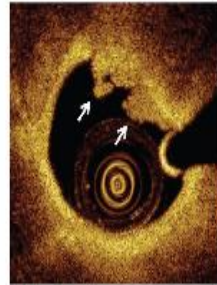


Thin Cap Fibroatheroma

## Acute Coronary Syndrome



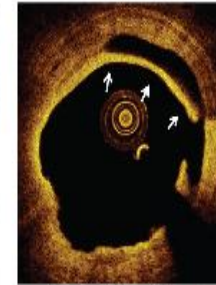Red Thrombus



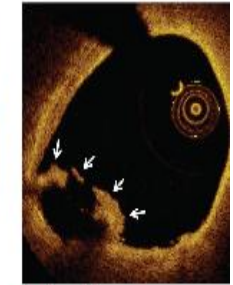White Thrombus



DES Late Stent Thrombosis



Spontaneous Intimal Dissection



Ruptured Plaque

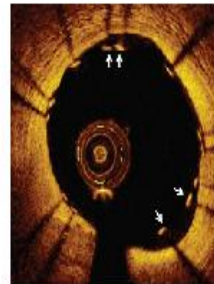
## Stent Optimization



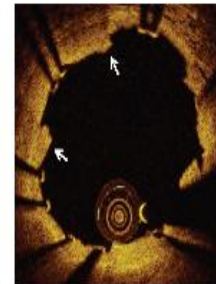
Proper Stent Apposition



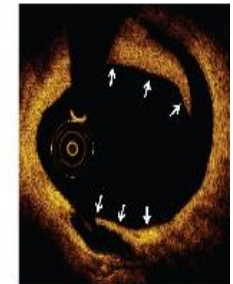Undersized Stent



Malapposed Stent Struts

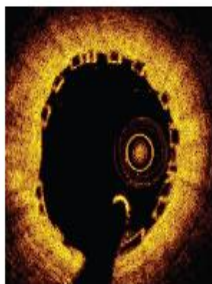

Tissue Prolapse




Distal Stent Edge Dissection

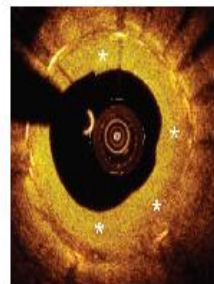
## Post-Stenting Follow-Up




Newly Implanted BVS



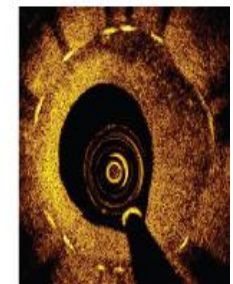
Optimal Strut Coverage



Neointimal Proliferation



DES Non-healing & Positive Remodeling



DES Neo-atherosclerosis

## **TRANSLUMINAL ALCOHOL SEPTAL ABLATION FOR HYPERTROPHIC OBSTRUCTIVE CARDIOMYOPATHY**

Some patients with hypertrophic obstructive cardiomyopathy (HOCM) have refractory symptoms resulting from outflow obstruction produced by hyperdynamic LV contraction with a hypertrophied septum. Controlled septal infarction can be produced with a new method of nonsurgical septal mass reduction that uses alcohol. In brief, a small balloon catheter is inserted into the septal artery with angioplasty technique and alcohol is instilled. This causes the septal muscles to infarct, become noncontractile, and scar, which eliminates the LV outflow tract gradient.

Criteria for alcohol septal ablation for HOCM include (1) refractory symptoms on maximal medical therapy, (2) a septal thickness of 1.8 cm or more, (3) an outflow tract gradient greater than 40mmHg at rest and greater than 60 mm Hg with provocation, and (4) the gradient localized to the septal obstruction. Other considerations should be moderate or mild mitral regurgitation with no organic abnormalities of the mitral valve and minimal coronary artery disease responsible for the symptoms.

### **Technique of Alcohol Septal Ablation:**

Complete hemodynamic and angiographic study should precede alcohol-induced septal ablation. Right and left femoral arteries and veins are cannulated. A 5F pigtail catheter is positioned in the left ventricle, pacemaker is positioned in the right ventricle for prophylactic pacing if complete heart block induced. After the catheters are positioned, coronary angiography identifies the large septal artery originating in the proximal left anterior descending artery. The echocardiographic technician performs imaging of the LV septum and LV outflow tract gradient. Heparin 40 U/Kg as a bolus, is administered because manipulations of guide after the procedure.

A 0.014-inch angioplasty guidewire is used to cannulate the large first septal artery. An over the wire balloon catheter is inflated in the septal artery. The guidewire removed, a small amount of contrast material is injected into the septal balloon to (1) ensure no reflux of contrast material or, later, alcohol and (2) opacify the septal artery and subbranch distribution. Confirmation of correct septal branch occlusion, 1 to 2 ml of 98% denatured alcohol is delivered slowly over 3 minutes into the septal artery followed by a 5-minute observation period. Complete heart block may occur with the need for temporary pacing. After the observation period the

balloon catheter is aspirated and then deflated. Suction is kept on the catheter lumen, the catheter is withdrawn from the LAD, and angiography is repeated. Final hemodynamic values are again measured. In most cases, the LV outflow gradient is abolished; 10% to 20% of patients may need permanent ventricular pacing.

## **PERCUTANEOUS TRANSLUMINAL MITRAL VALVULOPLASTY (PBMV)**

Balloon valvotomy is a non-surgical procedure performed in the cardiac catheterization laboratory by a cardiologist and a specialized team of nurses and technicians. Balloon valvotomy is used to increase the opening of a narrowed (stenotic) valve. It is used for:

- Select patients who have mitral valve stenosis with symptoms
- Older patients who have aortic valve stenosis, but are not able to undergo surgery
- Some patients with pulmonic valve stenosis

This balloon valvotomy procedure can be performed on the mitral, tricuspid, aortic or pulmonary valves.

### **BALLOON MITRAL VALVOTOMY ( BMV)**

Percutaneous balloon mitral valvuloplasty (BMV) was first reported by Inoue and associates<sup>1</sup> in 1984. Since then, BMV has become an alternative to surgery in the treatment of symptomatic mitral valve stenosis. Although BMV was initially restricted to young adults without severe valvular calcification. It was soon extended to the general adult population, including some elderly patients with calcific mitral stenosis. The mechanism of BMV is similar to that of surgical commissurotomy, in that both methods relieve valvular stenosis by splitting the fused mitral commissures.

A catheter with a special balloon is passed from the right femoral vein, up the inferior vena cava and into the right atrium. The interatrial septum is punctured and the catheter passed into the left atrium using a "trans-septal technique". The balloon is sub-divided into 3 segments and is dilated in 3 stages. 1st the distal portion (lying in the left ventricle) is inflated and pulled against the valve cusps. Second the proximal portion is dilated, in order to fix the centre segment at the valve orifice. Finally the central section is inflated. This should take no longer than 30 seconds since full inflation obstructs the valve and causes congestion, leading to circulatory arrest and flash pulmonary edema.

**Indications:**

In asymptomatic patients, intervention is recommended in moderate to severe MS and pulmonary hypertension (pulmonary artery systolic pressure >50 mmHg at rest or >60 mmHg with exercise). When intervention is indicated in patients with rheumatic MS, is preferred to surgery if the valve morphology is favorable and the patient does not have left atrial thrombus or moderate to severe (3+ to 4+) mitral regurgitation. Valve repair is performed if possible and preferred over valve replacement which has higher preoperative mortality and morbidity. Valve repair includes both open commissurotomy and placement of an annuloplasty ring after direct visualization of the valve.

The decision of whether valvuloplasty is superior to surgery depends on age (<60 favors valvuloplasty), and Cath/ECHO findings (e.g. LVEDP, degree of mobility, thickening and calcification). The average end result for the mitral valve surface area with both strategies is about 2 cm<sup>2</sup>. Moderate or greater MR (mitral regurgitation) and LA thrombus are contraindications to valvuloplasty.

Mitral stenosis is amenable to percutaneous mitral valvuloplasty if the echocardiography demonstrates: Thickening confined to valve tips, good mobility of anterior mitral valve leaflet, little chordal involvement, no more than trivial mitral regurgitation, no left atrial thrombus, and no commissural calcification.

Symptoms of shortness of breath and valve area or less than 1.5 cm<sup>2</sup> are indications for commissurotomy

Unlike with the surgical approach, elevated pulmonary pressures or depressed LV function are not contraindications

**Contraindications**

- Mitral regurgitation +2
- Left atrium thrombus
- Severe calcifications of the mitral valve

## Selection of Appropriate Balloon Size

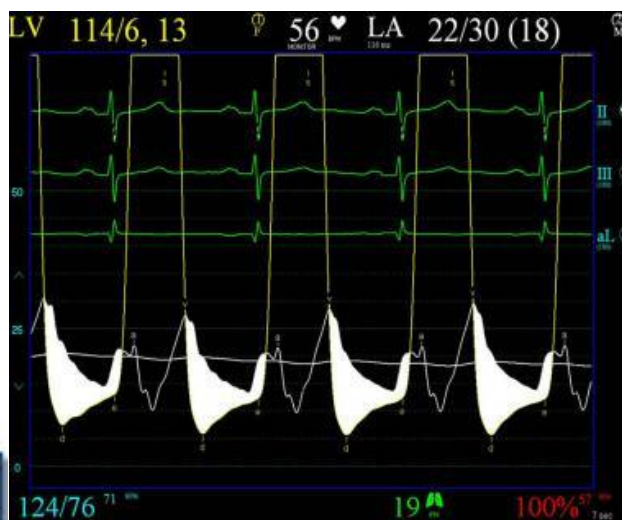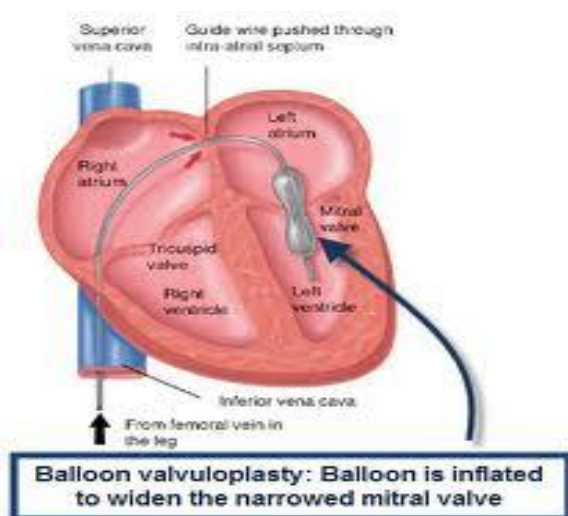
### **The Inoue Balloon:**

The Inoue balloon is constructed of two layers of latex in between there is a nylon mesh.

### **The Accura Balloon:**

The accura double lumen PTMC blood dilation catheter has 11F, 80 cm shaft and three stages of expandable balloon. In our hospital we are using the accura balloon.

Selection of the appropriate balloon size is one of the most critical factors for accomplishing this procedure (i.e., for releasing the stenotic mitral orifice without causing extensive damage to the commissures, leaflets, and subvalvular apparatus leading to excessive mitral regurgitation). For selecting the appropriate balloon size, some researchers have advocated methods to select balloon size with the patient's height or body surface area as a reference. **A simple equation to obtain the reference size (height [cm]/10+10) has been proposed.** The obvious point should be made, however, that the relationship of one's height to the diameter of the mitral valve orifice is not necessarily linear. Furthermore, the operator must remember that annular calcification will affect the size of the mitral valve orifice regardless of the patient's physical constitution. To avoid undesired extensive injury to the mitral valve apparatus, we select the balloon size by directly measuring the mitral annular diameter using 2-dimensional echocardiography. The mitral annular diameter can be measured on the apical 4- or 2-chamber view during mid- to end-systole. Measuring



mitral annular diameter at different planes gives different values owing to the noncircular, nonplanar shape of the annulus. Theoretically, a diameter close to the

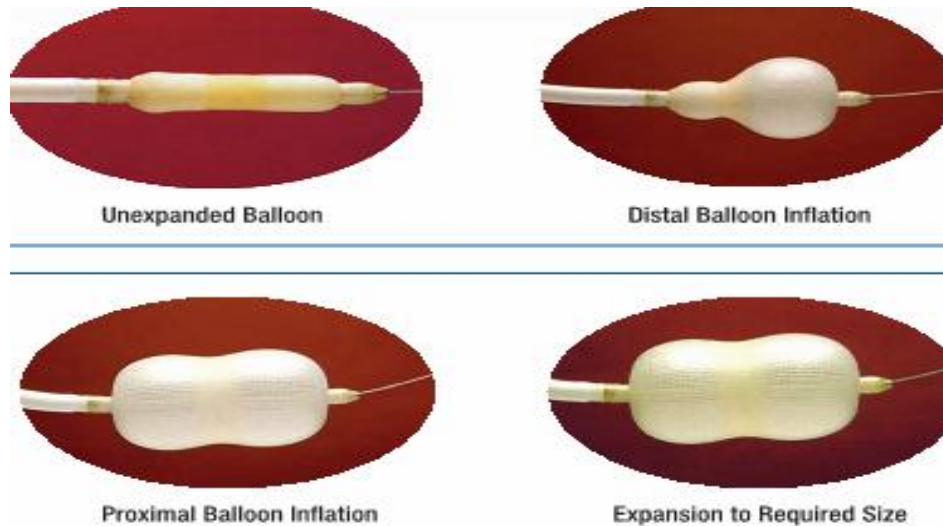
distance between 2 commissures (probably annular diameter on the apical 2-chamber view) could serve as the reference size for the Inoue balloon. However, the minimal mitral annular diameter should be adopted to avoid the risk of tearing the leaflets.

BALLOON SELECTION MAX Balloon Diameter	PATIENT'S HEIGHT
29mm	> 180 cm
28mm	> 160 cm
26mm	> 150 cm
24mm	> 150 cm
22mm	> 150 cm
BALLOON SIZES FORMULA	
$\frac{\text{Height in cm}}{10} + 10 = \text{_____ mm}$	

### **PREPARATION OF THE SEPTAL PUNCTURE SYSTEM AND THE BALLOON**

The cardiac technologist should be very cautious and should change over to the sterile cathlab dress while doing the hardware preparation. The balloon which is taken out from the cidex solution is thoroughly cleaned with sterile cotton gauze soaked in saline. Also the balloon lumen is flushed with saline few times. The hardware is thoroughly checked for any damage. The tip of the balloon and the knob are specially looked at as it can get detached on multiple uses. The pigtail shaped wire is thoroughly checked to look for the integrity in the welded area. A contrast-saline mixture under 1:4 concentration is required. The balloon hub is connected to a 20ml syringe containing the contrast-saline mixture with 10mm extension tubing connected to a 3-way stop cock. The contrast mixture is pushed into the balloon which is kept vertically down and the 3-way is locked. Tap the balloon properly so that air inside the balloon comes up. Release the 3-way and pushed out the air coming into the syringe. Once we make sure that the balloon is completely air free, and then proceed the next step. Measure the balloon diameter with vernier caliper. Adjust the volume of contrast to get the adequate sized balloon. Usually an addition f 1ml of contrast, will increase the size of the balloon by 1mm, but this varies with the size of the balloon. Release the lock of the 3-way, let the contrast-saline mixture come into the syringe by itself. Don't aspirate further. Now turn the 3 way and lock the required amount of contrast mixture into the syringe. Close the 3 way hub, to prevent leakage of the contrast. Introduce the straightener in to the balloon and slenderize it. Now the balloon is ready for introduction into the left atrium.

Transesophageal echocardiography is recommended before the procedure to determine the presence of left atrial thrombus, with specific attention paid to the left atrial appendage. If a thrombus is found, 3 months of anticoagulation with warfarin may result in resolution of the thrombus.



### **HARDWARES USED DURING BMV**

Trans-septal puncture is an essential step in percutaneous mitral valvotomy (PMV) through the antegrade route. This technique was developed by Ross, Braunwald and Marrow at the National Heart Institute.

To perform a septal puncture use a mullins sheath or dilator (7 F), brokenbrough needle, three way stop cock with saline and contrast.

#### **Mullins sheath and Dilator:**

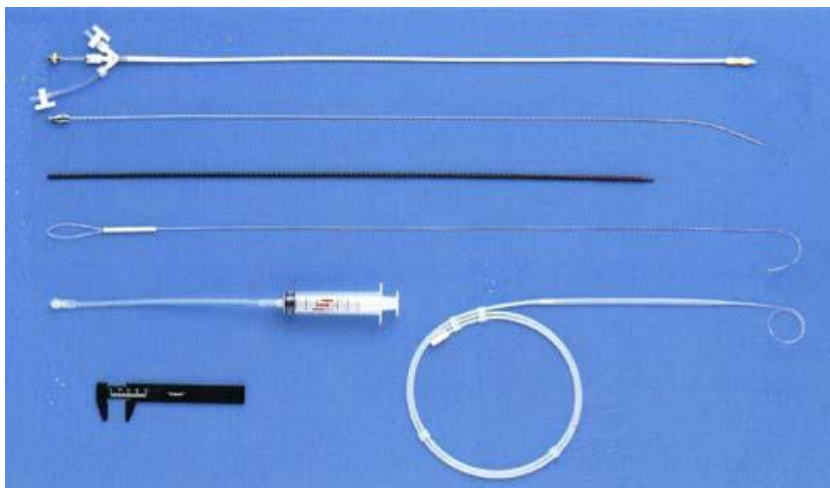
The catheter has a 270<sup>0</sup> curve at the end that is straightened by the dilator.

Description	Size	
	Outer Diameter	Length
Balloon stretching tube	1.2mm	80cm
Dilator	14Fr.	70cm
Guidewire	.025"	175cm
Stylet	.038"	80cm
Ruler	—	—

### **Brockenbrough Needle:**

This needle is an 18-gauge hollow tube that tapers distally to 22-gauge. The proximal end has a flange with an arrow that points to the position of the needle tip.

The interventional cardiologist gains access to the mitral valve by making a puncture in the interatrial septum during cardiac catheterization. Inflation and rapid deflation of a single balloon or a double-balloon opens the stenotic valve. This mechanism is similar to that of surgical commissurotomy.



### **PROCEDURE**

- Transvenous transeptal technique is most commonly used with the Accura balloon system.
- Fossa ovalis lies usually at 1-7 o'clock but this orientation can be distorted in the presence of mitral stenosis where the interatrial septum becomes more flat, horizontal and lower.
- For the femoral vein approach a 70 cm Brockenbrough needle should be used or an 8 Fr Mullins sheath and advanced under fluoroscopic guidance with pressure monitoring.
- The latter is necessary to monitor for puncture into adjacent structures such as aorta.
- Further catheter manipulation may be necessary to direct the catheter into the left ventricle through the mitral valve rather than towards one of the pulmonary veins.
- The Mullins sheath is exchanged for a solid-core coiled 0.025 inch guidewire over which a 14 Fr dilator is placed.
- This is exchanged for the Accura balloon (24-30 mm) which inflates in three stages allowing for balloon self-positioning with the last inflation resulting in commissural splitting.

A transthoracic echocardiography should be done to measure the mitral valve area and assess the severity of regurgitation as a complication of the procedure. PMBV should be stopped if adequate valve area has been achieved or if the severity of mitral regurgitation has been increased.

## **BALLOON ATRIAL SEPTOSTOMY**

Balloon atrial septostomy (BAS) was first described by Rashkind and Miller in 1966 and remains an important interventional procedure in the palliation of certain forms of congenital heart disease (CHD). Creating an atrial septal defect in patients with transposition of the great arteries (d-TGA) will enhance bidirectional mixing of the pulmonary and systemic venous blood, hence improving oxygen saturation.

### **INDICATIONS**

- D-TGA
- Hypoplastic left heart syndrome
- Double outlet right ventricle

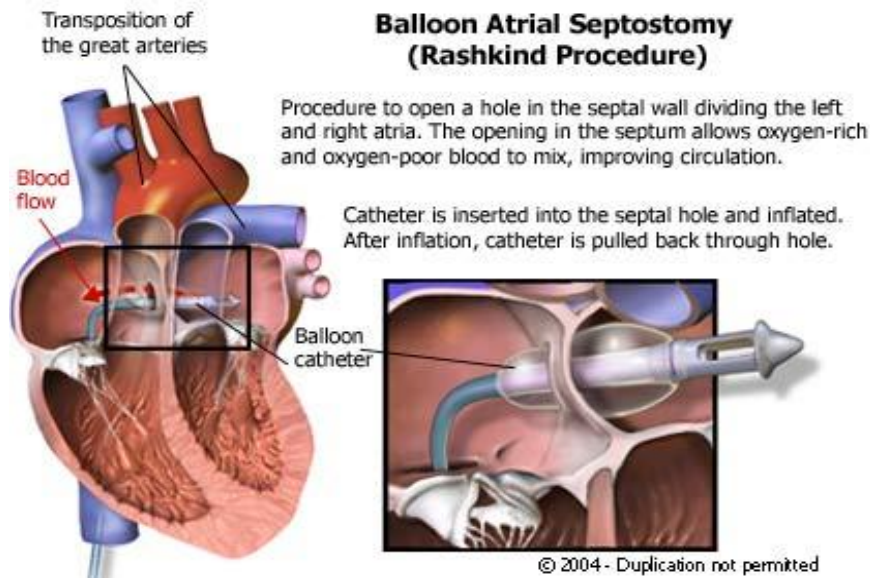
### **CATHETER DESCRIPTION**

A variety of catheters are in use for balloon atrial septostomy. The most commonly used catheter at the present time, the 5F Miller balloon atrial septostomy catheter, needs a 7F to 8F introducer. The low profile, dual lumen Z-5 atrioseptostomy catheter, comes in 4F or 5F sizes, depending on the balloon diameter, and requires a 5 or 6F introducer, respectively. The Z-5 catheter is advanced over a guide wire, as opposed to the Miller catheter.

### **PROCEDURE**

The access can be achieved via the femoral or the umbilical vein. The femoral vein is punctured in the typical way, a 4 or 5F introducer is placed in the vessel, and then exchanged for a 7F or 8F introducer, when the Miller catheter is used. The balloon catheter is advanced into the right atrium. Then the foramen ovale is crossed and the catheter is positioned in the left atrium. Correct position is documented via biplane fluoroscopy or two-dimensional echocardiography. In the anteroposterior fluoroscopic projection, it is sometimes advantageous to position the catheter tip in the orifice of the left upper pulmonary vein, to confirm its left atrial location. The balloon is quickly inflated with 3-4 ml of dilute radiopaque solution, locked, and then sharply withdrawn into the right atrium down to the junction of the

inferior caval vein. The catheter is then advanced into the body of the right atrium, so as not to obstruct inferior caval return, and then deflated rapidly. This maneuver



may be repeated two to three times. The size of the interatrial communication can be measured directly by echocardiography at the table. The efficacy is usually immediately obvious, from the rise in systemic arterial saturation.

## **PERCUTANEOUS BALLOON AORTIC VALVULOPLASTY**

Balloon aortic valvuloplasty is now the treatment of choice for children with congenital aortic stenosis.

### **INDICATIONS FOR BAV**

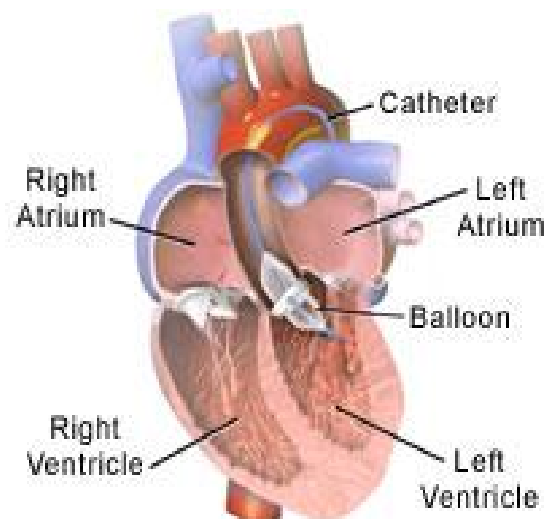
- Bridge to AVR
- Evaluate for reversibility of severe LV dysfunction and severe MR
- Temporizing for percutaneous AVR
- Urgent therapy for patients is severe CHF

### **PROCEDURE**

Diagnostic right and left heart catheterization was performed on all patients. Heparin was administered in all patients 10 to 70 U/kg after 9- to 13-F sheath insertion in the femoral artery. BAV was performed according to standard techniques via the retrograde femoral approach in all patients except 1. In that individual, axillary artery access was employed because of severe peripheral vascular disease. Equalization of pressures was documented before entering the left ventricle.

The gradient was confirmed with pullback gradient measurements. Peak and mean gradients were measured, and AVA was calculated with the Gorlin formula.

The sinotubular junction is the site prone to rupture during a BAV procedure. We analyzed the minimal diameter of the sinotubular junction by aortogram in the left anterior oblique with a marker pigtail and by echocardiography. The chosen balloon size was 3 to 5 mm under this measurement. To stabilize the balloon position across the valve, the heart was paced at a high rate (180 to 200 beats/min) until the blood pressure fell to <50 mm Hg before inflation. Pacing was continued until the balloon was fully deflated. Additional BAV procedures were performed subsequently in cases in which the mean gradients did not decrease significantly (~30% to 40%), and a larger balloon was employed in selected cases in which the initial balloon size failed to significantly decrease gradients (~30% to 40%). At the end of the procedure, measurements of cardiac output and pressure gradients and calculations were repeated. After BAV, an aortogram was performed to assess aortic regurgitation. Arterial puncture sites were closed with closure devices (6-F Perclose [Abbott Laboratories, Abbott Park, Illinois] or 12-F Prostar [Abbott] or 8-F Angio-Seal [St. Jude Medical, St. Paul, Minnesota]). If the device failed, manual



### **Balloon Valvuloplasty for Aortic Stenosis**

compression was applied. Serious adverse events were defined as intraprocedural death, stroke, coronary occlusion or dissection, moderate-to-severe aortic regurgitation, profound hypotension requiring resuscitation and intubation or cardioversion, tamponade, permanent pacemaker requirement, and vascular complication requiring intervention.

## **COMPLICATIONS**

The potential risk of valvuloplasty include myocardial infarction, stroke, aortic valve perforation or regurgitation, myocardial rupture, mitral valve damage, arterial wall damage or occlusion and arrhythmia.

## **BALLOON PULMONARY VALVULOPLASTY**

BPV is a safe, effective and reliable treatment for patients with congenital valvular PS. The pulmonary balloon valvuloplasty is the treatment of choice for patients with symptomatic pulmonary stenosis.

## **INDICATIONS**

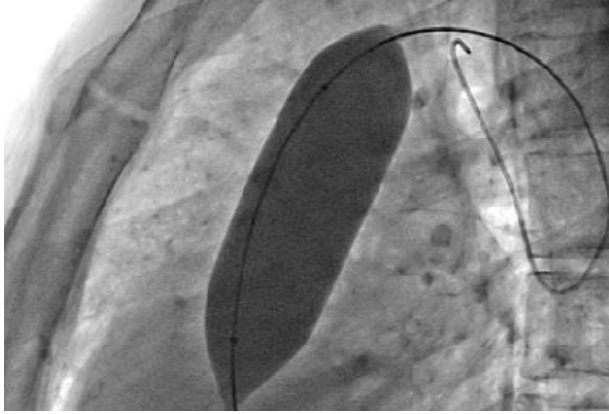
- Patients with exertional dyspnea, angina, syncope, or presyncope.
- Asymptomatic patients with normal cardiac output (estimated clinically or determined by catheterization) and transvalvular peak systolic pressure gradient more than 30 mmHg.<sup>9</sup>
- Tetralogy of fallot

## **TECHNIQUE OF PULMONARY BALLOON VALVULOPLASTY**

Vascular access via femoral vein, right ventricular (RV) angiography was done with a Berman balloon catheter initially. Hemodynamic data including RV pressure and pulmonary artery (PA) pressure were documented during catheterization with Swan-Ganz catheter. BPV was performed basically according to the method of Kan et al<sup>5</sup> and Al Kasab et al<sup>6</sup> briefly; a long J tipped exchange guide wire (260 cm) was used to advance the balloon to the pulmonary valve site. Single-balloon technique was performed via femoral vein, with the balloon sized about 25% greater the annulus diameter. Usually, repeated balloon dilatation 2-3 times was performed and each inflation-deflation time was no more than 30 seconds.

## **RISKS**

- Damage of tricuspid
- Perforation of right ventricular outflow tract
- Embolization



## **DEVICE CLOSURE FOR ATRIAL SEPTAL DEFECT**

An atrial septal defect (ASD) is a communication or opening between the atria that results in shunting of blood between the two chambers. There are 4 anatomic types:

- Ostium primum - low in atrial septum, may involve a cleft mitral valve.
- Ostium secundum - center of the atrial septum. Most common type of ASD.
- Sinus venosus - high in the atrial septum. Associated with P-TAPVR.
- Coronary sinus - large opening between the coronary sinus and left

## **SYMPTOMS OF ASD**

Severity of symptoms often depends on the size of the hole. Large ASDs may cause fatigue, shortness of breath, pulmonary hypertension, arrhythmia and/or an enlarged heart.

## **PROCEDURE**

This procedure is performed in the cardiac catheterization lab. The patient will be given an anesthetic which may be general (GA) or local (LA) depending on the technique used. Once anaesthetized, an imaging probe (TEE) will be passed into your gullet (oesophagus) for accurate sizing of the ASD and to assist during deployment of the device. A multipurpose was used to perform hemodynamic measurement will be inserted via a vein in the groin and navigated until it reaches the heart. Sometimes, the catheter is positioned at different chambers of your heart to measure the pressure and oxygen content prior to device closure. In certain circumstances, balloon sizing of the ASD may be required. The appropriate size device is connected onto a cable, put into a special delivery tube, advanced through your ASD and carefully deployed. Your doctor will study the device's position and stability before

releasing the device. The catheter and imaging probe are removed and the procedure is completed.

## **COMPLICATIONS**

Air embolism, LA disk deformation, Arrhythmia, AV block, Device embolization, Cardiac perforation.

## **DEVICE CLOSURE OF VENTRICULAR SEPTAL DEFECT**

A ventricular septal defect (VSD) is a communication (or multiple communications) between the right and left ventricles. VSD's are classified by their location in the ventricular septum. There are 4 anatomic types:

- Perimembranous - upper portion of septum (most common).
- Subpulmonary - below pulmonary valve.
- Muscular - muscle portion of ventricular septum. Usually low in the ventricular septum. Multiple muscular defects may be referred to as 'swiss cheese' defects.
- Atrioventricular canal - located beneath the tricuspid valve. Also called an inlet VSD

## **Device Implantation Technique**

Different from the atrial septum, the right ventricular trabeculae make crossing a muscular VSD difficult from a venous approach. Therefore a double-catheter approach has been widely used for the muscular VSD closure.

The procedure is done under general endotracheal anesthesia and TEE. Access is obtained in the femoral vein, the femoral artery and the right internal jugular vein. The patients are fully heparinized. Routine right and left heart catheterization is performed to assess the degree of shunting and to evaluate the pulmonary vascular resistance. Axial angiography is performed to define the location, size and number of VSD. However, for catheter closure of multiple muscular VSDs, TEE guidance should be routine. The VSD is measured. The appropriate device size is chosen to be equal to or 1-2 mm larger than the VSD size as assessed by TEE or TTE

The next step in the closure sequence is placement of a long sheath (6-8 French) across the VSD. This can be accomplished in a variety of ways. The most common approach used for mid muscular VSDs is to advance a curved end-hole catheter (Judkins right, or Cobra) into the VSD from the left ventricular side. An

exchange length 0.035" Amplatz wire is then advanced through the VSD and the right ventricle into the pulmonary artery. This wire is snared in the pulmonary artery or in the right atrium using the Amplatz gooseneck snare and is exteriorized out the right internal jugular sheath. This provides a stable rail to allow advancement of the 6-8 French long sheath across the VSD. The sheath is preferentially advanced from the jugular approach to limit the sheath size in the artery. The sheath can then be advanced from a retrograde approach through the femoral artery. On occasions to eliminate kinking of the sheath in the aortic arch or the septum area, a 0.018" glide wire is left inside the sheath while advancing the delivery cable and device. Once the device reaches the tip of the sheath, the wire is removed prior to deployment of the ventricular disk. In some patients with larger VSDs, the catheter could cross from the right ventricular side. If the VSD is crossed and a catheter can be placed in the body of the left ventricle the stiff wire is advanced into the left ventricle and the sheath is advanced through the right internal jugular vein into the left ventricle.

Once the sheath is in proper position the appropriate sized VSD device is then screwed onto the delivery cable and pulled into the loader under water. The loader is then flushed with saline through the side arm of the valve supplied with the delivery system to prevent any air embolism. The loader is placed into the proximal end of the long sheath and the device is advanced with short pushes of the delivery cable to the distal tip of the sheath. The cable should be advanced without rotation to prevent premature unscrewing of the device. The device is then slowly advanced out the sheath to allow the distal disc to expand. In the cavity of the LV, repeat small injections using the pigtail catheter positioned in the LV after each step is of paramount importance. These injections are used for optimal device positioning. The device and sheath are then retracted against the septum with gentle tension and the sheath is retracted to open the waist of the device in the VSD and open the proximal disc against the opposite side of the septum. The device position is then assessed using TEE. If device position is satisfactory, the pin vise is then fixed onto the delivery cable and the device is released with counter clockwise rotation.

## **PATENT DUCTUS ARTERIOSUS CLOSURE**

A patent ductus arteriosus (PDA) is a blood vessel connecting the aorta with the pulmonary artery. This channel is important prior to birth to allow oxygen-rich blood from the mother to circulate throughout the fetus's body.

### **INDICATIONS**

Severity of symptoms often depends on the size of the PDA. Small PDAs may cause no symptoms and are sometimes only detected by the doctor hearing a heart murmur through a stethoscope. Medium to large PDAs may cause fatigue, poor

growth and eventually lead to heart failure. 2, 3 All sizes of PDAs may increase a patient's risk for a bacterial infection.

## **DEVICE DESCRIPTION**

The Amplatzer Duct Occluder (AGA Medical Corporation, Golden Valley, MN) is a self-expanding and self-centering device, made from 0.0004 to 0.0005 inch Nitinol wire mesh. It is mushroom-shaped with a low profile and consists of a flat retention disk and a cylindrical main body, into which polyester fibers are sewn. Platinum marker bands are laserwelded to each end and a steel sleeve with a female thread is welded into the marker band. The retention disk is 4 mm larger than the main body, which itself has a conical structure. The delivery system consists of a delivery cable, a Mullins-type sheath, loader and a pin vise. The device comes in different sizes, requiring sheath sizes from 5 to 7 F for delivery. The size of device chosen is generally such that the diameter of the pulmonary end of the device is at least 2 mm larger than the narrowest diameter of the duct. Device sizes are categorised according to the diameters of the aortic and pulmonary ends of the device. The devices are all 7mm long. The device can be delivered through sheath sizes ranging from 5F (for devices upto 8/6) to 7F.

## **Implantation technique**

The procedure can be performed under conscious sedation in older patients, or using general anesthesia. A single dose of intravenous antibiotic is administered (usually a cephalosporin), as is standard practice for all interventional implantation procedures. The femoral vein and artery are cannulated percutaneously. The size and configuration of the duct are determined by descending aortic angiography, using a 4F or 5F pigtail catheter. The minimum diameter, the diameter of the aortic ampulla and the length of the duct are measured. An end hole catheter (usually 5F) is passed through the duct from the pulmonary side into the descending aorta, if necessary with the help of an 0.035" guidewire. An end-hole 5F multipurpose catheter has been advanced anterogradely from the femoral vein and through the duct into the descending. The endhole catheter has been exchanged over a exchange wire for a 6F delivery sheath, with the tip of the sheath in the descending aorta. The appropriate ADO device is chosen, such that the diameter of the pulmonary end is at least 2 mm larger than the narrowest diameter of the duct, and immersed into saline solution. The delivery cable is passed through the loader and the device is screwed on clockwise to the tip. The delivery cable for the ADO has been passed through the loading sheath. After attachment of the ADO to the delivery cable, the cable is gently withdrawn to allow the device to pass into the loading sheath. Thereafter, the whole system is immersed into saline again. The device is

now pulled into the loader and the loader is introduced into the delivery sheath. The ADO is completely within the loading sheath, and the entire system is flushed with saline to remove any air bubbles. The device is advanced through the delivery sheath into the descending aorta. An aortogram is performed to confirm correct device position, taking care in particular to ensure that the retention disc is sitting entirely on the rim of the ductal ampulla, is not obstructing the descending aorta, and has not partially prolapsed into the body of the duct. If the position is correct, the device is released by rotating the delivery cable in an anticlockwise direction (as indicated by the arrow on the vise) with the pin vise.

## **PATENT FORAMEN OVALE CLOSURE (PFO)**

PFO is one of the most common congenital defects. PFO as a factor in cerebrovascular accident, migraine and transient ischemic attacks.

### **PROCEDURE**

Use a wedge catheter (end-hole catheter) of 7F diameter. The inner lumen of the catheter admits a stiff wire. In order to provide stiffness to the catheter, an Amplatzer super-stiff wire through it (advanced to the tip of the catheter-not outside of the catheter). Then cross the PFO while coming from the inferior vena cava, a gentle clock-wise torque while advancing the catheter is helpful in crossing almost all defects. The primary trick is that the interventionalist should be able to propagate the torque while advancing the catheter in. Then gone to the SVC and pulled the catheter tip in the right atrium to cross the PFO. Sometime, a multi-purpose or Judkin's right coronary artery catheter can be used. A Terumo guide wire is very helpful in teasing the catheter through the PFO. Once the catheter is across the PFO, a wire is advanced through it into the left upper pulmonary vein. Once, the wire is in the left upper pulmonary vein, the catheter is removed and the delivery sheath advanced over the wire. The sheath may or may not be advanced into the pulmonary vein. Its position can be easily checked with echocardiography. The dilator and the wire are removed. The sheath is allowed to bleed back and then flushed with saline. The device is advanced through the delivery sheath and under fluoroscopy and echocardiography, the device is deployed. Since the PFO is a slit-like opening, it is important that the right atrial disc overlaps the limbus. If there is no right atrial disc overlap, the risk of device embolization to the left atrial side increases.

## **PDA STENTING**

The stenting can be done through femoral access, axillary access, jugular access. The access taken based on the origin of PDA. 'Vertical' ductus arteriosus generally is not amenable to stenting via the retrograde, femoral artery route as it is very difficult to engage, axillary access is taken for this. Heparin is given before the procedure.

A 5F Judkin's Right guide catheter is maneuvered into the ampulla and a hand injection is done under fluoroscopy to visualize the duct. A 0.014 coronary wire is used to cross the ductus and enter into the pulmonary artery. It is important to have a Y-connector secured at the hub of the catheter to prevent blood loss. The choice wire short, hydrophilic and stiffer wire for tracking the balloon across the ductus. The wire is passed to LPA. Based on the angiogram the length and diameter is measured. Stent size is taken based on this length and size of PDA and a bare metal stent is taken. Stent is advanced through the guide wire towards the ampulla, it is necessary to ensure that the guide wire remains as straight as possible. Once the tip of the stent is across the narrowest part of the ductus contrast injections are repeated in the same projections and fine adjustments are made to position the stent. Once the position is satisfied, inflate rapidly and deflate rapidly. The stent is inflated only on the nominal pressure, because over inflation makes it to produce thrombosis. It is important to look for branch pulmonary artery stenosis and ensure both the pulmonary and the aortic ends of the ductus are covered.

## **COMPLICATIONS**

- Acute thrombosis
- Spasm of ductus arteriosus
- Migration of the stent

## **MAPCA COILING( Major Aorta-Pulmonary Collateral Arteries)**

### **INDICATION FOR COILING**

MAPCA are required to be closed before surgery of TOF and for hemostasis.

### **PROCEDURE**

The arterial access is taken and usually femoral access is taken. A 5fr pigtail is advanced and placed in DTA and a DTA angiogram is taken. The collaterals are visualized. A 5fr RCA or MPA is taken to hook up MAPCA and the diameter of MAPCA is measured. The coil is taken based on the diameter we measured. The

appropriate coil is taken it is advanced through the catheter and dilated. The DTA angiogram is taken after the procedure to check the residual flow.

## **DEVICE CLOSURE OF RUPTURED SINUS OF VALSALVA (RSOV)**

Rupture of aneurysm of the sinus of Valsalva (RSOV) is an uncommon condition with a wide spectrum of presentation, ranging from an asymptomatic murmur to cardiogenic shock or even sudden cardiac death.

### **TECHNIQUE**

All the patients underwent a detailed clinical evaluation and echocardiographic assessment, to determine their hemodynamic status, the origin and exit site of the RSOV, presence of associated lesions such as VSD and aortic regurgitation (AR), and evaluation of biventricular contractility. After assessing the suitability for device closure, informed consent was obtained. The procedure was done under general anesthesia with transesophageal echocardiographic (TEE) and fluoroscopic guidance. All the patients were heparinized (100 IU/kg) after obtaining vascular access (femoral artery and vein).

Detailed TEE evaluation was done prior to proceeding with the hemodynamic study and angiography. This included assessment of the maximum diameter of the aortic end of the RSOV, the minimum diameter and the length of the windsock, and the distance of the aortic end of the RSOV from the coronary ostium. Presence of AR and VSD were also ruled out. An aortogram was done to confirm the TEE findings pertaining to the RSOV and to assess the degree of AR. A left ventricle angiogram was done to exclude any VSD. The RSOV was crossed with a 6F Judkin Right catheter and a 0.035" × 260 cm straight tipped Terumo wire from the aortic side. The wire was manipulated into the superior vena cava (SVC) and snared through the right femoral vein with a 10 mm Goose Neck Snare, to form an arteriovenous loop. The delivery sheath was passed from the venous end and pushed over the wire across the RSOV. The device was loaded into the sheath. The aortic retention disc was opened into the ascending aorta and the entire system was pulled back till it anchored at the aortic end of the RSOV. At this point, the other end of the device was delivered by stabilizing the loading cable and pulling back the sheath. The entire maneuver was performed under fluoroscopic and transesophageal echo guidance. Once it was found to be optimum, the device was released. All the patients underwent an aortogram ten minutes post procedure to look for residual flow and to quantify AR.

## **COIL OCCULSION**

Percutaneous transcatheter occlusion of unwanted vascular communications has played an important role in pediatric interventional cardiology since first described by Gianturco. The most commonly used coil embolization materials available include the Gianturco stainless steel coil (Occluding Spring Emboli; Cook, Bloomington, Indiana) and the platinum microcoil (Target Therapeutics, Santa Monica, California). The Gianturco coil is constructed of stainless steel wire of varying helical diameters and lengths to which Dacron fibers have been attached to increase thrombogenicity. After implantation of the Gianturco coil, occlusion of the vascular communication occurs as the result of thrombus formation and subsequent organization. A detachable Gianturco coil-delivery system is also available (Cook) that can facilitate some occlusion procedures because the coil can be withdrawn if it is not in optimal position. Platinum microcoils can be delivered through 3F delivery catheters (eg, Tracker 18, Target Therapeutics) introduced coaxially through 5F catheters positioned subselectively to occlude very small vessels. The technique of therapeutic coil embolization varies, depending on the type of vascular connection to be occluded and the specific pathophysiology. General technical comments can be made, however. Embolization is always performed through a vascular sheath to allow multiple catheter exchanges and coil withdrawal or retrieval if necessary. It is essential that selective angiography be performed before embolization to define the size and structure of the vascular connection to be occluded. Preferably angiography is performed with the same catheter in the same position used for coil delivery. In general, coil occlusion is performed with a coil with a helical diameter 20% to 30% larger than the diameter of the target vessel or malformation. Approximately 5 to 10 minutes after coil implantation, selective angiography is performed to document vessel occlusion. If necessary, additional coils may be implanted. Systemic heparinization has been shown not to adversely affect the coil occlusion process.

### **Aortopulmonary Collaterals**

Perhaps the most common use of coil embolization techniques in pediatric cardiology is transcatheter occlusion of aortopulmonary collateral vessels. Aortopulmonary collaterals occur most commonly in children with tetralogy of Fallot or pulmonary atresia with VSD and may require transcatheter embolization before and/or after surgical intervention. Aortopulmonary collaterals are also observed in children with a univentricular heart after a bidirectional Glenn or modified Fontan procedure and in children with D-transposition of the great vessels. Occlusion of

aortopulmonary collateral vessels can be physiologically advantageous by diminishing competitive pulmonary blood flow, reducing systemic ventricular volume overload, and assisting in the complex process of pulmonary artery unifocalization. Aortopulmonary collateral vessels to be occluded must supply a segment of the pulmonary arterial tree that receives dual arterial supply (i.e., from the central pulmonary artery as well as from the collateral) and must not be required for adequate systemic arterial oxygen content.

## **PATENT DUCTUS ARTERIOSUS**

For decades cardiologists have sought an effective transcatheter method of closing the PDA. A variety of devices have been investigated, including Ivalon plugs and umbrella devices, but all require large delivery catheters and are expensive. Coil occlusion of the patent ductus is simple and effective. It requires only a 4F or 5F catheter and is relatively inexpensive. Since first described in 1992, coil occlusion of the restrictive PDA has rapidly become the treatment of choice at many institutions. It provides effective therapy for the large majority (more than 90%) of restrictive PDAs when the minimum angiographic diameter is less than 4 mm. Coil embolization has also been described for the larger but still restrictive PDA with a minimum diameter of 4 to 7 mm. The coil occlusion technique is not appropriate for the nonrestrictive PDA, and its use in the clinically silent PDA has also been questioned. Coil occlusion of PDA can be performed transarterially or transvenously and may require implantation of one or more coils. The use of a snare catheter to hold the pulmonary artery end of the coil during transarterial delivery may facilitate successful PDA occlusion. Follow-up data have shown that tiny residual shunts noted immediately after coil implantation often resolve spontaneously. A recent retrospective study has found that hospital charges are substantially lower for coil occlusion than surgical ligation even when charges associated with surgery for residual PDA after coil occlusion are taken into account. Complications related to PDA coil occlusion include a persistent residual shunt in 5% to 10% of cases, embolization of a coil to the pulmonary artery or rarely to a systemic artery requiring catheter retrieval, occasional femoral artery injury following cannulation with a 4F to 5F catheter, and very rarely hemolysis associated with a residual shunt. Important left pulmonary artery stenosis, coarctation, clinical thromboembolism, endarteritis, or late recanalizations have not been reported after PDA coil occlusion.

## **COARCTATION OF AORTA AND STENTING**

It is not uncommon for newborns and young infants with severe coarctation of aorta to present with cardiogenic shock, metabolic acidosis and end organ dysfunction when the ductus arteriosus closes.

### **PROCEDURE**

After explaining the details of the procedure, complications and alternative options, an informed consent was taken from parents. Conscious sedation was given. A 4F pediatric introducer sheath was inserted in one of the femoral arteries and 100 U/kg of heparin administered. A 4F right coronary catheter with 0.018 Terumo wire was used to cross the coarctation segment. No difficulty was encountered during attempts to cross the segment. Pressure gradients were recorded across the coarctation segment. An aortic angiogram straddling coarctation segment was done using a 4 F pigtail in both posterior-anterior and lateral views. Isthmus and transverse arch measurements were made. The balloon diameter for dilatation was determined by the echocardiographic or angiographic (whichever was larger) measurement of the isthmus. The narrowest coarctation diameter was not used to determine balloon size. Balloon was upsized if residual gradients were present, but did not exceed distal transverse arch dimension. Coronary and renal stent balloons were used for dilatation using an inflator with a pressure gauge. The balloon dilatation was graded and the nominal inflation pressures recommended for the balloons were not exceeded. Pressure gradients were recorded across the dilated/stented segment and repeat angiograms were done to assess the efficacy of the procedure. The decision to stent the coarctation segment depended on the aortic arch anatomy, degree of arch hypoplasia and associated cardiac lesions. The criteria for stenting were not predefined and not uniform. In general stent was used when the isthmus was hypoplastic. Stent was deployed primarily and not after balloon dilatation. Balloon dilatation alone was preferred when the coarctation was thought to be discrete with a good sized isthmus. Essentially any premounted bare metal renal or coronary stent of appropriate diameter (4-5 mm) with a length of 8-13 mm was used. All stents were deployed at the recommended pressure. After balloon dilatation or stent deployment final angiograms and pullback gradients were obtained.

## **ENDOMYOCARDIAL BIOPSY**

Endomyocardial biopsy is an uncommon procedure in the catheterization laboratory and used mostly for monitoring of cardiac transplant rejection.

### **INDICATIONS**

Monitoring cardiac transplant rejection and determinind anthracycline cardiotoxicity, myocarditis, restrictive or infiltrative cardiomyopathy.

### **CONTRAINDICATIONS**

Anticoagulation and anatomic abnormalities.

### **BIOPSY DEVICES**

There are two basic types of bioptomes are stiff shaft devices and floppy shaft devices that are positioned with the aid of a long sheath. The femoral sheath dilator is 94cm long, and the long sheath is 85cm long. Biopsy sheaths come in 5 and 7cm curves.

### **TECHNIQUE**

Endomyocardial biopsy can be performed under fluoroscopic or echocardiographic guidance from the femoral or internal jugular approach.

### **FEMORAL APPROACH**

After the patient is given local anesthesia, the right or left femoral vein is punctured by the modified Seldinger technique and a 0.038 inch guidewire is advanced into the femoral vein. A 7F biopsy sheath with a 7F dilator is advanced into the guidewire. A large curve sheath (7cm) sheath is used when the atrium is dilated. The sheath and the dilator are advanced into the right atrium. The dilator is withdrawn into the sheath. With the help of the guidewire, the sheath is advanced across the tricuspid valve and into the right ventricle. The sheath is flushed and connected to the pressure monitor, and a RV pressure tracing is identified. A floppy shaft biopsy forceps is advanced into through the sheath and into the right ventricle. The sheath is pointed horizontally towards the intraventricular septum, which should be confirmed in the left anterior oblique projection to outflow tract and the inferior and RV wall should be avoided.

To reduce the chance perforation, the operator always opens the biptome jaws inside the sheath before the biptome exits the sheath. The biptome is carefully advanced with the jaws fully open until contact with the ventricular wall is made and the biptome shaft is slightly bent. The biptome jaws are then closed. A tugging sensation is often felt by the operator on full extraction of the biptome into the sheath. After the biptome is removed, the sheath should be aspirated and flushed to eliminate air bubbles. RV pressures are measured before and after the biopsy. The biopsy sheath is removed, and hemostasis is secured.

## **COMPLICATIONS**

- Access site related
- Biopsy related
- Arrhythmia
- Conduction abnormalities
- Perforation
- Death

## **CARDIAC TAMPONADE**

Cardiac tamponade is pressure on the heart that occurs when blood or fluid builds up in the space between the heart muscle (myocardium) and the outer covering sac of the heart (pericardium).

### **Causes**

In this condition, blood or fluid collects in the pericardium, the sac surrounding the heart. This prevents the heart ventricles from expanding fully. The excess pressure from the fluid prevents the heart from working properly. As a result, the body does not get enough blood.

Cardiac tamponade can occur due to: Dissecting aortic aneurysm (thoracic), end-stage lung cancer, Heart attack (acute MI), Heart surgery, Pericarditis caused by bacteria or viral infections, wounds to the heart. Other possible causes include: Heart tumors Hypothyroidism, Kidney failure, Leukemia, Placement of central lines Radiation therapy to the chest, recent invasive heart procedures, Recent open heart surgery.

### **SYMPTOMS**

Anxiety, restlessness, sharp chest pain that is felt in the neck, shoulder, back, or abdomen. Chest pain that gets worse with deep breathing or coughing,

problems breathing, Discomfort, sometimes relieved by sitting upright or leaning forward, Fainting, light-headedness. Pale, gray, or blue skin, Palpitations, Rapid breathing, Swelling of the abdomen or other areas. Other symptoms that may occur with this disorder: Dizziness, Drowsiness, Weak or absent pulse.

## **PROCEDURE**

Pericardiocentesis is usually proceeding by echocardiographic confirmation of pericardial fluid. The patient will be given a mild sedative. An IV (intravenous) line is inserted in your hand or arm in case fluids or medications are needed. The operator will use a local anesthetic to numb an area on your chest. A needle will be inserted and then a 6F pigtail catheter (a thin plastic tube) will be threaded into the pericardial sac around your heart. Then will drain the fluid that has collected around your heart. When the fluid has been removed, the catheter may be removed. Sometimes it is left in place for more drainage.

## **COMPLICATIONS**

Pericardiocentesis is usually fairly safe, especially when imaging is used to guide the needle. But there is a risk that the procedure may:

- Induce an irregular heart rhythm
- Cause cardiac arrest
- Cause a heart attack
- Puncture the heart, liver, lung, stomach

## **CORONARY ARTERY FISTULAE**

Coronary fistulae are uncommon abnormal connections between coronary arteries and cardiac chambers, the coronary sinus, or the pulmonary artery, bypassing arterioles, capillaries, and venules. They may be congenital or the result of previous surgery (e.g., cardiac transplantation or right heart biopsies) or trauma. The most common feeding coronary artery is the right (52%), followed by the left anterior descending (30%) artery, and then the left circumflex coronary artery. The receiving structure is most commonly the right ventricle, followed by the right atrium, coronary sinus, left ventricle, and pulmonary artery. Occasionally, multiple fistulous tracts are encountered. Although there is significant variability, when the fistula originates from the distal left anterior descending coronary artery and drains into the left ventricle, or when it connects the proximal right coronary artery to the

coronary sinus, its course is often more tortuous than if it originates from the proximal coronaries and enters the right atrium.

## **INDICATIONS**

Fistulae are often asymptomatic and discovered during childhood related to a murmur on routine examinations. The murmur may have resemblance to that of a patent ductus arteriosus. When symptoms occur they are most commonly related to high-output heart failure, ischemia (the consequence of a steal phenomenon), or thrombus formation with distal embolization. In addition, ventricular or atrial arrhythmias and infectious endocarditis have been reported, as has rupture (rarely). Adequate contrast opacification of the fistulous tract may be difficult because of the fistula size and high-flow characteristics. In this case, the use of a large guide catheter and power injector for delivery of larger contrast boluses or the use of a pigtail catheter positioned in the fistula origin (if this accommodates the pigtail tip) may be helpful.

## **PROCEDURE**

Smaller fistulae (<5 mm) can be occluded with coils. These can be delivered by a guide catheter if this can be safely positioned into the fistula. If there is concern of injury to the coronary artery feeding the fistula, then a delivery catheter (e.g., 4F to 5F coronary catheter or 2F to 3F microcatheter, depending on the size and tortuosity of the feeding vessel) can be positioned into the fistula over a guidewire or coronary wire and the coils placed via the delivery catheter. The sizes and characteristics of coils are usually described by three numbers: the first indicates the profile expressed in thousands of an inch; the second represents the unconstrained diameter in millimeters; and the third is the length in its stretched state (when it is pulled apart into a straight line) in centimeters. Thus an 18-4-5 coil has a 0.018-inch profile, a 4-mm diameter in its unconstrained state, and a 5-cm length when pulled apart. Coils should be slightly oversized with respect to the target vessel diameter. For example, when the fistulous tract has a diameter of 4 mm, a coil with an unconstrained diameter of 5 to 6 mm should be chosen. The larger size will wedge the coil in position and minimize the risk of distal embolization. When placed via a delivery catheter, the coils are usually pushed into the vessel by a pusher wire. However, some coils (controlled release or detachable) can be delivered into the desired location, and if a size mismatch is recognized or the position is suboptimal, they can be removed before release. The choice of delivery method depends on the coil size and the anticipated coil location. A 7F or 8F guide catheter with a 4F or 5F

delivery catheter is required for most large (0.035-inch) coils, whereas a 6F guide catheter can be used for delivery of smaller (0.018-inch) coils. When more distal delivery of the coils is desirable, it may be best to use a 7F or 8F guide catheter with a 5F catheter that can be advanced more distally and a 2F to 3F microcatheter for coil delivery. The mechanism by which the coils eventually cause occlusion of the fistulous tract is vessel (endothelial) injury and thrombogenicity of the coil itself rather than flow limitation because of the coils. Most coils are composed of nitinol or stainless steel. In addition, some have attached fibers to promote thrombosis. It is important to recognize that it may take some time for a vessel to close after coiling. Hence allowing some time before final angiography may prevent overzealous coiling. Of note, not all coils are compatible with MRI, and if an MRI is necessary, it is recommended to clarify compatibility with the manufacturer. Alternatively, placement of a covered stent across the origin of the fistula can be considered. However, currently available coronary covered stents are bulky, which can cause problems with delivery, particularly into more distal coronaries or through tortuous segments. More importantly, however, covered stents are associated with significant risks of in-stent restenosis and thrombosis and therefore should be considered only if all other alternatives are not feasible.

Medium sized and large fistulae (>5 mm) often require a different approach. Embolization with vascular plugs or large profile coils is often necessary. The most commonly used plugs are Amplatzer vascular plugs, which are composed of self-expandable, multilayered, double-lobed nitinol mesh. The size is chosen approximately 30% larger than the vessel diameter to allow secure anchoring. The vascular plugs are attached to a delivery wire and are positioned into the fistula via a guide catheter or sheath. When the desired position is confirmed, they are released by counterclockwise rotation of the delivery wire via a microscrew. If the position is suboptimal or the size is inappropriate, as long as the plug is not released it can be pulled back into the guiding catheter or sheath and repositioned or removed entirely. The size of the guide catheter or sheath required depends on the profile of the vascular plug. Some newer generation plugs can be delivered via 4F or 5F guide catheters. There are two basic delivery techniques. The plugs can be delivered antegradely through a guide catheter positioned via the feeding coronary into the fistula or retrogradely via a guide catheter positioned into the distal aspect of the fistula. The latter approach is chosen when significant risk of injury of the native feeding vessel is anticipated. Positioning vascular plugs or coils retrogradely into the distal fistula via a guide catheter can be challenging because there may be difficulties establishing and maintaining a secure guide or sheath position in the distal fistula. In

this case, provided the draining chamber is the right atrium, ventricle, or coronary sinus, a guide catheter can be positioned in the coronary feeding the fistula, and a wire can be advanced through the fistula into the draining chamber where it is snared via a guide catheter or sheath positioned in the draining chamber. This loop then offers more support for a delivery catheter or sheath positioned in the distal fistula. The most feared complications using coils or vascular plugs are inadvertent obstruction of the feeding native coronary artery and embolization into unwanted vascular territories. If the coil position is anticipated in the more proximal fistula segment close to the native coronary, balloon occlusion of the anticipated segment can be considered to assess whether ischemia will occur. In case of embolization, most coils and vascular plugs can usually be retrieved.

Because of the rare occurrence of coronary fistulas that require percutaneous treatment and great variability in fistula anatomy, there are no official statements that guide postprocedural management. After closure of small fistulas, long-term antiplatelet therapy may be considered. In those patients with a persisting aneurysm stump or severe aneurysmatic dilation of the coronary vessel that originally fed the fistula, oral anticoagulation may be considered. Although infection of a coronary fistula has been reported, reported infection of the occluding device was not found by these authors. Nevertheless, after closure of fistulae larger than 3 to 4 mm in diameter double-bolus antibiotics (e.g., cephalosporin) are routinely administered on the day of the procedure. Thereafter antibiotic prophylaxis is not routinely administered. Although recurrent symptoms should guide reevaluation with noninvasive or invasive imaging, routine follow-up evaluation to assess for coronary ischemia may be considered, particularly in patients in whom ischemia was demonstrated before closure.

## **INTRAVASCULAR FOREIGN BODY RETRIEVAL**

Several catheter and wire loops have been designed to retrieve foreign bodies which are usually fragments of previous catheters or guidewire. Most catheter fragments result from injudicious insertion or removal of catheters from the subclavian, jugular, peripheral or rarely inferior venacava approaches.

### **RETRIEVAL DEVICES**

There are many kinds of commercially available snares and graspers for retrieval. It is easy to loop snare with a standard 5F angiographic catheter and a 18cm, 0.018 inch underwire. The advantages of this type of snare are that it has a variable size loop and it is inexpensive. Commercial devices include 0.038 inch single-

arm forceps, snares and graspers for IVC filter removal, stone retrieval baskets and loop snares designed for embolization coil retrieval.

Retrieval devices are available in small sizes which fit with any catheter or sheath used for diagnostic procedure. The use of guide catheters or large sheaths depends on the size of the device retrieve. Nitinol Goose-neck snares have no sharp edges, but very smooth and flexible. Forceps and baskets have rigid tips and can potentially grasp the vessel wall next to the foreign body and require more caution and experience. Snares can be effectively used when the foreign body or the device has free and/or located on the guidewire.

### **PROCEDURE**

In almost every case it is possible to remove the foreign body without resorting to open operation. Refined techniques are required for removal of fragments of angioplasty guidewires in coronary arteries. A catheter-housed wire loop or snare is commonly available. An intracoronary guide wire fragment can be retrieved from the coronary artery with the use of a loop passed through a small intracoronary guiding catheter. The snare and loop technique has been used successfully in venous and arterial applications. Extra care must be exercised with any snare that has a rigid tip that may damage surrounding structures as the catheter fragment is retrieved. The catheter fragment or guidewire material that is retrieved may scratch or tear the cardiac chamber unless it is captured at a distal end with the free, sharp edge of fragment contained.

**CARDIAC  
ELECTROPHYSIOLOGY AND  
DEVICE IMPLANTATIONS**

# **CARDIAC ELECTROPHYSIOLOGY**

## **INDRODUCTION**

The use of cardiac electrophysiology procedures includes diagnostic and interventional treatment procedures. In general, diagnostic EP studies are performed to determine an arrhythmia diagnosis or EP mechanism of known arrhythmia. Interventional or therapeutic EP studies consist of endocardial catheter ablation of supraventricular and ventricular arrhythmias.

## **SET-UP OF THE ELECTROPHYSIOLOGY LAB**

Setting up an electrophysiology laboratory for cardiac ablation requires specifics in the layout of laboratory, and equipments requirements. Conventional electrophysiology studies and ablation procedures should be performed with adequately trained personnel. One or two physicians are responsible for catheter manipulation and ablation. For most EP procedures, conscious sedation is preferred to allow for assessment of symptoms and minimization of risks associated with anaesthesia. Support for complications related to EP studies and ablations should be readily available, including cardiac and vascular surgery and neurologic imaging modalities.

## **JUNCTION BOX**

The junction boxes receive the intracardiac signals from the catheters and provide an interface in to the physiologic recorder. Multiple switches within the junction box are designated to a recording and stimulation channel which can be selected through the recording apparatus. The junction boxes are mounted at the foot of the patient table and connected to the physiologic recorder, which is kept as close as possible. This helps to minimize noise on the channels as well as reduce floor cutter.

## **RECORDING APPARATUS**

The physiologic recorder records, displays and stores intracardiac and surface recording. It consists of filters, amplifiers, display screens, and recording software. From the junction box, the physiologic signals are typically low in amplitude and require amplification recorder. These signals are typically low in amplitude and require amplification prior to displaying and recording. The recording system amplifies and filters each input channel separately, with most current

systems supporting up to 64 or more channels. The amplifiers have the ability to automatically or manually adjust gain control. The amplifiers should be mounted as close to the patient table as possible. This will reduce the cable length of the intracardiac connections and surface ECG, which minimize the signal noise. The amplifiers then connected to the main physiologic recorder through a floor channel, which, ideally, should run separately from electric power cables. Filters are used to eliminate unnecessary signals that distort electrograms. High pass filters eliminate signals below a given frequency and low pass filters eliminate signals above a given frequency. Most intracardiac electrograms are clearly identified when the signals is filtered between a high pass of 40 Hz and a low pass of 500 Hz. Several pages can be simultaneously recorded and one of these typically includes a 12-lead ECG. The page displayed during studies typically shows several intracardiac electrograms with 3 to 4 surface ECG leads which allow for axis determination, activation timing, and P, QRS morphology. Pressure channels if used, for simultaneous hemodynamic monitoring.

## **STIMULATOR**

A programmable stimulator is necessary to obtain electrophysiologic data beyond measurement of conduction intervals. Stimulators are capable of various modes of pacing, including rapid pacing, delivery of single or multiple extra stimuli following a paced drive train, and delivery of timed extra stimuli following sensed beats. Stimulators should be capable of delivering variable currents, ranging from 0.1 to 10 mA. With satisfactory positioning of catheters, current thresholds under 2mA can usually be achieved in both the atrium and ventricle. Higher outputs are seen with diseased myocardium, within the coronary sinus, and with the use of anti arrhythmic medications. Output is usually set at twice the diastolic threshold. Most stimulators have the ability to pace through more than one channel; however one channel generally suffices for all studies unless dual chamber pacing is required.

## **CARDIOVERTER**

A primary and back up defibrillator should be available throughout all EP studies. Current defibrillators deliver energy in a biphasic waveform which offers enhanced defibrillation success. Defibrillation pads are attached to the patient and electrically grounded. ECG can be recorded through the defibrillation pads separate from the data acquisition system.

## **RADIOFREQUENCY ABLATION**

Radiofrequency ablation uses alternating current delivered between the catheter tips and grounding source to deliver energy to tissue, resulting in necrosis. Radiofrequency generators deliver current with a frequency between 300 and 750 kHz, with generation of heat occurring as a result of resistive and conductive heating. Monitoring of time, power, and impedance is necessary to ensure safe and effective ablation lesions. Through the generator, limits on impedance and temperature are programmed and the desired power level is set.

## **MAPPING SYSTEMS**

Cardiac mapping is the process by which arrhythmias are characterized and localized. Conventional mapping involves acquiring electrogram data from fixed and moving catheters and creating mental activation maps with fluoroscopic two dimensional images. More sophisticated mapping techniques provide three dimensional anatomic localization of the catheter to assist in mapping and ablation. These technologies involve the acquisition of multiple electrogram location to provide a high resolution activation, voltage or propagation map. In addition to correlating local electrogram to 3D cardiac structures, these newer mapping techniques reduce the radiation exposure to the patient and physician. The most widely used the electro anatomic mapping by creating electrical fields between opposing pairs of patch electrodes located on the patient's chest. Six patches are placed on the body to create three orthogonal axes with the heart located centrally. A transthoracic electrical field is created through each pair of opposing patch electrodes and the mapping catheter delivers this signal for processing.

## **INDICATIONS**

### **SINUS NODE DISEASE**

For most patients with sinus node disease, the decision regarding whether to implant a pacemaker can be made on the basis of the history and ambulatory ECG monitoring; electrophysiology testing of the sinus node is not necessary. However, in some patients persistent symptoms may be associated with only mild ECG abnormalities. In these cases determination of sinus node recovery time may be helpful, as a markedly prolonged sinus node recovery time is an indication for implantation of a permanent pacemaker. However, a normal sinus node recovery

time does not exclude symptomatic sick sinus syndrome, and the significance of a mildly abnormal sinus node recovery time is established.

## **ATRIOVENTRICULAR BLOCK**

For most patients with atrioventricular block the decision regarding whether to implant a pacemaker can be made on the basis history and the surface ECG without intracardiac recording. Patients who have symptoms require a pacemaker. Patient who have no symptoms require pacemakers only for high-grade infranodal block. The mobitzII pattern during second degree block and the rate and morphologic characteristics of the escape rhythm during complete heart block are quite accurate in predicting the level of block. However, for some patients the diagnosis is not clear from the surface ECG. Specifically, intracardiac recording may be helpful in patients with AV Wenckebach block associated with bundle branch block, apparent Mobitz II pattern in the setting of a narrow QRS segment, and apparent Mobitz II pattern with frequent junctional extrasystoles, suggesting concealed junctional extrasystoles mimicking Mobitz II pattern.

## **INTRAVENTRICULAR CONDUCTION DELAY**

Patients who are free of symptoms who have bifascicular block have demonstrated slow progression to high- degree block and do not require specific therapy. Patients with symptomatic bifascicular block may have intermittend complete heart block that has escaped detection on monitoring. For these patients, demonstration during EPS of pacing induced infranodal block or of a markedly prolonged HV interval is an indication for pacemaker implantation. A normal study does not exclude the possibility of intermittent heart block but makes it much less likely. For some of these patients with bifascicular block and symptoms, EPS will reveal causes for syncope other than heart block.

## **SUPRAVENTRICULAR TACHYCARDIA**

Patient with supraventricular tachycardia (SVT) that is only mildly symptomatic may be treated with empiric drug therapy, if treated at all. EPS is needed for patients with rapid tachycardia associated with severe symptoms patients with recurrent symptomatic bouts of tachycardia refractory to empiric therapy. In such cases EPS allow selection of drug therapy, it allows the selection of nonmedical forms of therapy such as specific antitachycardia pacemaker and antitachycardia surgery.

## **WOLFF – PARKINSON – WHITE SYNDROME**

Patients with WPW syndrome constituted a significant portion of patients with SVT requiring study. Because of the complex interactions of drugs on the normal and anomalous pathways, prefer to study all patients with WPW in whom drug therapy is being started for tachycardias. Clearly, all patients with a very rapid ventricular response to atrial fibrillation require EPS. Patient with WPW who are free of symptoms may also have the potential for very rapid conduction during atrial fibrillation, but the risk of this appears to be quite small.

## **DIFFERENTIAL DIAGNOSIS OF WIDE QRS TACHYCARDIA**

EPS is the only definitive way to differentiate SVT with aberrancy from VT. In most patients, the tachycardia in question can be reproduced in the EP lab. Careful documentation of the relationship of the His bundle and the atrial electrogram allows a definitive diagnosis of the nature of the tachycardia.

## **VENTRICULAR TACHYCARDIA**

EPS is indicated for all patients with recurrent, sustained VT. This arrhythmia can be reproduced in the electrophysiology laboratory in 90% of patients using the technique of programmed stimulation. Moreover, drug testing during EPS predicted the clinical response to medications, with the possible exception of Amiodarone. EPS is mandatory if a pacemaker, the automatic implantable cardioverter, or surgical therapy is being considered

## **OUT OF HOSPITAL CARDIAC ARREST**

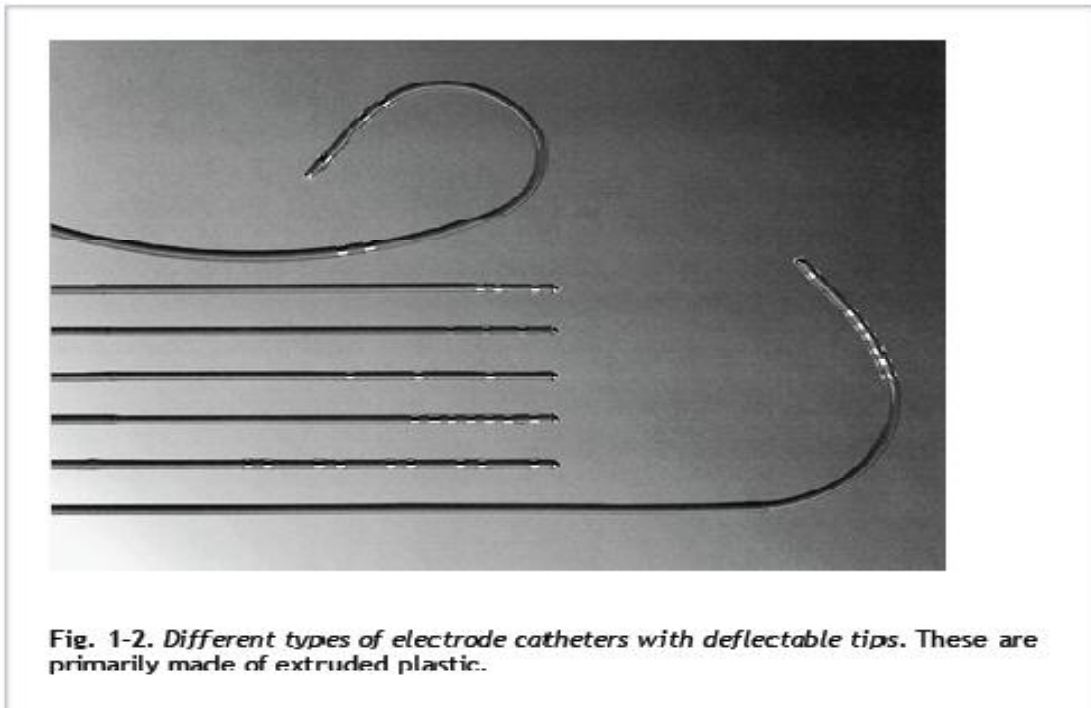
EPS is indicated for all patients who survive a cardiac arrest that is not related to acute factors such as MI or electrolyte imbalance. EPS can induce VT or VF in close to 70% survivors of cardiac arrest. In patients with inducible arrhythmias, drugs that prevent arrhythmia induction in the laboratory may be clinically effective.

## **SYNCOPE**

For most patients with syncope, a careful history, physical examination, and ECG will establish a diagnosis. When syncope remains unexplained after non invasive evaluation, and particularly when syncope is recurrent, EPS is indicated.

## ELECTRODE CATHETERS

A variety of catheters is currently available with at least two ring electrodes that can be used for bipolar stimulation and or recording. The catheter construction may be of the Woven Dacron variety or of the newer extruded synthetic materials such as polyurethane. As a general all-purpose catheter, we prefer the woven Dacron catheters because of their greater durability and physical properties. These catheters come with a variable number of electrodes, electrode spacing, and curves to provide a range of options for different purposes. Although they have superior torque characteristics, their greatest advantage is that they are stiff enough to maintain a shape and yet they soften at body temperature so that they are not too stiff for forming loops and bends in the vascular system to adapt a variety of uses. The catheters made of synthetic materials cannot be manipulated



and change shapes within the body, so they are less desirable.

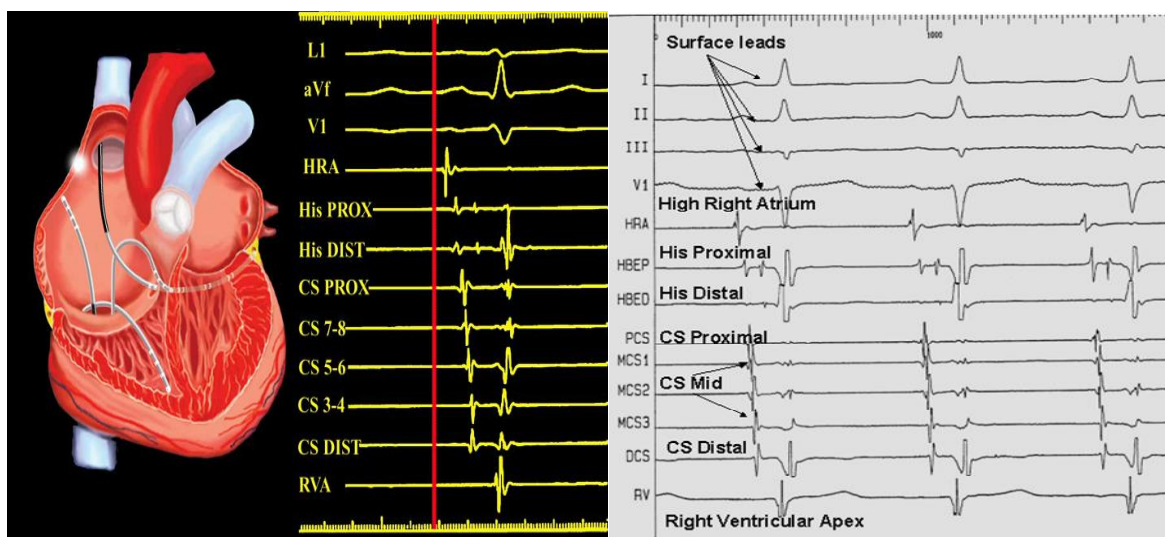
The advantages of the synthetic catheters are that they are cheaper and can be made smaller than the woven Dacron types. Currently, most electrode catheters are size 3 to 8 French. The smaller sizes are used in children. In adult patients, sizes 5 to 7 French catheters are routinely used. Other diagnostic catheters are routinely used. Other diagnostic catheters have deflectable tip. These are useful to reach and record specific sites. In general, a quadripolar polar catheter suffices for recording and stimulation of standard sites in the right atrium, right

ventricle, and for recording his bundle electrogram. Standard catheters with up to 24 poles that can be deflectable to map large and or specific areas of the atrium. Of particular note are catheters shaped in the form of a halo to record from around the tricuspid ring.

Ablation catheters generally have a larger tip (4mm) so that the energy is more efficiently distributed. They have flexible tips, are capable of independent tip rotation, flexion and extension, and have different curvatures that are suitable for application with small or large hearts. Some catheters have a cooled tip, one through which saline is infused to allow for enhanced tissue heating without superficial charring. Ablation catheters deliver RF energy through tips that are typically 4-5 mm in length but may be as long as 10 mm.

## **CATHETER PLACEMENT**

Most electrophysiologic catheters are placed via the femoral vein. The atrial catheter may be positioned at the junction of the superior vena cava and right atrium or in the right atrial appendage, where it is generally stable. The his catheter is positioned by prolapsing the catheter the catheter across the tricuspid valve into the right ventricle in the AP fluoroscopic position, where the tricuspid valve is seen in a profile and the His bundle is located at its summit.



The right ventricular catheter may be positioned in either the apex or the outflow tract. We prefer the use of the deflectable tip catheter for the right ventricular recording and pacing because it is easier to manoeuvre it to the desired position. Positioning of coronary sinus catheters may be accomplished either from the right femoral position or from the left subclavin or jugular approach. Coronary

sinus is located in the medial posterior septum of the right atrium and in the RAO view lies posterior to the inferior margin of the tricuspid valve.

Placement of catheter in the left ventricle may be accomplished by either the retrograde transaortic or transseptal approach. Occasional epicardial mapping needs to be done. In paediatric patients, due to limited access less number of catheters may be used and occasional oesophageal catheters for atrial signal recording may be used.

## **PATIENT PREPARATION**

Obtain informed consent. Explain to the patient the nature of the procedure and the risks involved. If the patient has ventricular arrhythmias, explain the possibility of inducing VF in the laboratory. We explain to that the occurrence of a ventricular arrhythmia in the laboratory is much preferable to its occurrence at home and that in the laboratory we are prepared to treat this arrhythmia immediately. Most patients undergoing these studies are aware of the serious nature of their arrhythmias and are able to accept this risk without undue anxiety.

Discontinue all antiarrhythmic drugs at least 4 half – lives before the study. Avoid premedication if possible because of the electrophysiologic effect may influence the study. The patient may take nothing for 6 hours before the procedure in case emergency cardioversion is necessary.

## **INTRACARDIAC ELECTROGRAMS**

Intracardiac electrograms (IEGMs) and surface electrocardiograms (ECG) both record cardiac electricity activity. However, there are some differences that one must understand for appropriate interpretation of intracardiac electrograms. The surface ECG, which is recorded outside of the body on the surface, provides information about the electrical activity of the entire heart. Intracardiac electrograms are recorded inside the heart by intracardiac multipolar catheters and display local electrical activity near the recording electrodes of the catheter (near field) as well as more remote significant cardiac electrical activity (far field). The IEGMs are usually filtered differently from the ECG to minimize noise and interference. The paper recording speed is also generally faster than the standard 25mm/s 12-lead ECG speed, 100 or 200 mm/s more frequently. The intervals measured during an EP study are generally expressed in milliseconds rather than beat per minute. To obtain the cycle length in ms, the following formula is used:

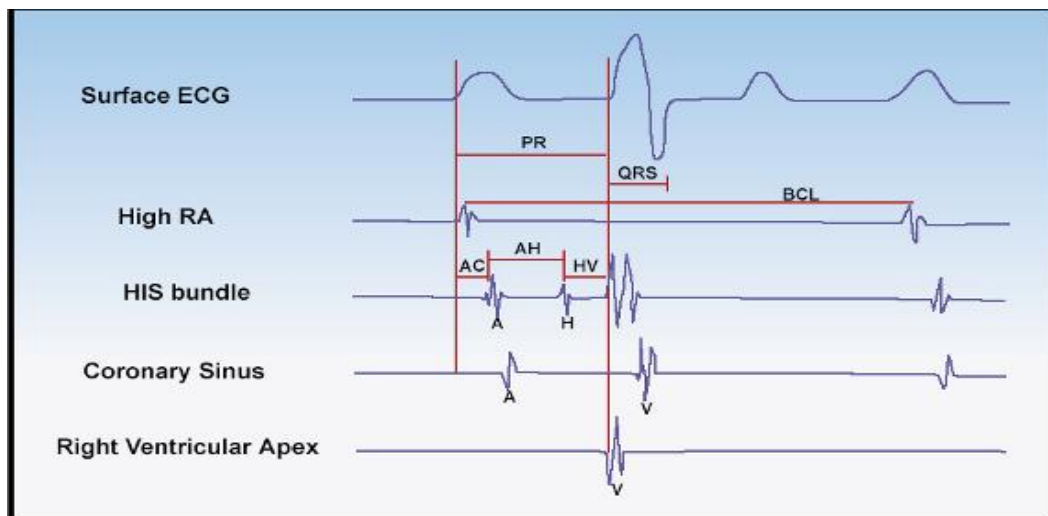
$$\text{Cycle length in ms} = 60,000/\text{rate in bpm}$$

Conversely, the rate is obtained as the Rate in bpm = 60,000/cycle length in ms

Like surface ECG, electrical potentials can be recorded between two electrodes within the heart (bipolar) or using one electrode in the heart (unipolar), the other being outside.

## **BASIC INTERVALS**

The A-H interval represents conduction time from the low right atrium at the interatrial septum through the A-V node to the His bundle. Thus the A-H interval is at best only an approximation of A-V nodal conduction time. The measurement should therefore, be taken from the earliest reproducible rapid deflection of the atrial electrogram in the His bundle recording to the onset of the his deflection. This time estimate the conduction time across the AV node and is generally between 50 and 120 ms.



The H-V interval represents conduction time from the proximal His bundle to the ventricular myocardium. The measurements of the interval is taken from the beginning of the his bundle deflection to the earliest onset of ventricular activation recorded from multiple-surface ECG leads or the ventricular electrogram in the his bundle recording. Reported normal values in adults range from 25 to 55 msec. They are shorter in children.

## METHODS OF PACING

### EXTRASTIMULUS TESTING

Typically, a drive train of 6 to 8 paced beats s1 is performed in the heart structure at a stable cycle length between 600 and 300 m, followed by a premature beat s2 with a coupling interval starting from 500 to 400 ms. The drive train is repeated with a progressive decrease of the coupling interval by 10 to 20 ms until the structure becomes refractory and is no longer captured. If needed, double (s2s3) or more extra stimuli can be delivered by repeating the same sequence with an s1 drive train sequence, an s1-s2 conducted beat and a decremental scanning interval of s3. The minimum coupling interval is commonly 200 ms because of the important risk of inducing arrhythmias with shorter coupling intervals.

### INCREMENTAL PACING

- Incremental pacing begins at a stable cycle length slightly below that of the sinus rhythm. The pacing cycle length is then shortened by 10 to 50 ms, a few beats are observed at the new pacing cycle length and the cycle length is again decreased by the same amount. This sequence is repeated to achieve the goal of incremental pacing, determination of the Wenckebach's cycle length in the AV node. Of note, the term 'incremental pacing' refers to a rate in beats per minute instead of a cycle length in ms.

### OTHER METHODS OF PACING

- BURST PACING; delivering a set number of pulses at a constant cycle length per sequence. The sequence can be repeated at progressively shorter cycle lengths. This method can be used in sinus rhythm to try to induce an arrhythmia or during a tachycardia to penetrate the circuit's arrhythmia. In this latter case, burst pacing cycle length is initially slightly shorter than the tachycardia or at a programmed percentage of the cycle length of the detected tachycardia. **Ramp pacing** is almost the same future, except that within a pacing sequence, each subsequent paced beat is decremented by a set amount.
- LONG SHORT PACING; a sequence with alternatively a long interval between two paced beats, followed by a short interval. It can be used to provoke arrhythmias or pattern of conduction block.

## **REFRACTORY PERIODS**

The refractoriness of a cardiac tissue can be defined by the response of that tissue to the introduction of premature stimuli. These periods are measured during an S1drive train and a progressive S2 decrement stimulus. When the refractory periods of a cardiac structure are measured, the input interval will be related to the upstream depolarized structure cycle length and the output to the downstream depolarized structure cycle length

The Relative refractory period (RRP) is the longest coupling interval of a premature impulse that results in prolonged conduction of the premature impulse relative to that of the basic drive. The output interval starts to be longer than the input interval.

The Effective refractory period (ERP) of a cardiac tissue is the longest coupling interval between the basic drive and the premature impulse that fails to propagate through that tissue. Longest input interval that fails to propagate, therefore no output.

The Functional refractory period (FRP) of a cardiac tissue is the minimum interval between two consecutively conducted impulses through that tissue. I.e., shortest output interval possible that can be elicited by any input interval.

## **BASELINE RECORDINGS**

Baseline recording during a typical electrophysiological study include surface ECG to time events from the body's surface, and IEGMs, all of which are recorded simultaneously. Electrical activation of the atrium is followed by that of the ventricle with a delay which occurs in the atrioventricular node.

The intracardiac recordings obtained from the electrodes are sharper unlike the wave forms of the surface ECG. These electrograms fall within the P wave or the QRS complex depending on the spread of activation within the chamber in which they are placed. Typical electrogram of the high right atrium electrode will show a sharp deflection in the early part of the P wave. Recording from the His electrode shows an A(Atrial) signals, a His signal and a V(ventricular) signal. As the coronary sinus is in the left AV groove, a coronary sinus catheter records both the left atrial and left ventricular electrograms. RV catheters records ventricular signals from the right ventricle. Activation of the left atrium at the CS ostium (CSP) electrode is normally earlier than at the CS distal (CSD) electrode. Catheters records the signal from all the four chambers directly or indirectly and the His bundle.

After baseline measurements are recorded, pacing is performed via intracardiac electrode catheters. Different chambers can be paced and the activation patterns noted.

## **ASSESSMENT OF SINUS NODAL DISEASE**

Sinus nodal (SN) function is assessed by sino-atrial conduction time and sinus nodal recovery time. Measuring sino-atrial conduction time (SACT) involves placement of a catheter near the sinus node from which progressively premature atrial extrastimuli are introduced after every eight to tenth beat of either a stable sinus rhythm, or atrial pacing for 8 beats is done at a rate just lower than the sinus rate. The difference of time of the recovery beat post pacing versus that of the sinus cycle length gives us 2 times the SACT value. Interval up to 250 msec is considered normal.

The sinus node recovery time (SNRT) is another method of assessing SN function and is performed by placing a catheter near the sinus node and pacing for at least 30 seconds at a fixed cycle length. This is repeated at progressively shorter cycle lengths. Pacing rates up to 200beats/minute may be employed. The maximum SNRT is the longest pause from the last pacing stimulus to the first spontaneously occurring sinus beat at any paced cycle length. As the sinus cycle length (SCL) affects the SNRT, it is often normalized or corrected. The corrected sinus node recovery time (CSNRT) is determined by subtracting the SCL from the SNRT. Normal values considered are  $SNRT/SCL < 150$  percent and  $CSNRT < 550$  milliseconds. A normal study however does not rule out clinical sinus nodal disease.

## **ASSESSMENT OF AV NODAL DISEASE**

During sinus rhythm higher than normal AH and HV intervals may represent abnormality in the conduction system. His bundle electrogram duration reflects conduction through the short length of compact His bundle that penetrates the fibrous septum. This interval is normally short, 15 to 25 msec. Fractionation and prolongation, or even splitting of the His bundle potential, is seen with disturbances of His bundle conduction.

The atrium then is paced at progressive faster rates and Wenchebach point is noted. Programmed atrial extra stimuli can be used to determine the effective refractory period of the AV node, which should be  $< 450$  milliseconds. If the block occurs in the AH segment at  $> 450$  msec, in the absence of other abnormalities, there still is no clearly demonstrated risk of progression to AV block, however having

a block in the HV segment suggests His Purkinje disease and pacemaker implantation is advised. Atropine and procainamide can be given if required to stress conduction system.

## **VENTRICULAR PACING**

Normally during ventricular pacing the impulse travels retrograde into the atrium through the AV node. VA dissociation is referred when while pacing the ventricle, no impulse travels back to the atrium. Ventricular pacing is then done at decreasing cycle length till VA conduction is blocked. Thereafter ventricular extra stimuli are given at decreasing interval till a VA block is obtained. During ventricular pacing atrial activation pattern whether central (His A is earliest) or eccentric (His A is later than A in RA or LA recording catheter) is seen. Lengthening of VA interval with decrement in the stimulus interval suggests decremental conduction. Central and decremental conduction generally suggests conduction through the nodal tissue. Eccentric and non decremental conduction suggests presence of retrograde conducting accessory pathway. Multiple (3 to 5) ventricular extra stimuli may be needed to induce ventricular arrhythmia some times. VA interval during RV apical and RV base pacing and VA interval of broad and narrow QRS during para- Hisian pacing is useful to detect presence of septal located bypass tract.

## **VENTRICULAR INCREMENTAL PACING**

When retrograde VA conduction is present, the ventricular cycle length is progressively shortened until the ventricle does not conduct to the atrium in a one to one relation. This cycle length is called the AV node retrograde Wenchebach cycle length. The classic pattern of Wenchebach is the most frequently observed with progressive prolongation of the VA interval prior to block. The His purkinje system is more likely to adapt its refractoriness when the pacing cycle length increases progressively during incremental pacing than during extra stimulus testing.

## **ATRIAL PACING**

Atrial pacing from either the right atrium or the left atrium as clinically indicates is done to see for antegrade conduction characteristics through the AV node. As discussed prior Wenchebach point is noted. Most of the time a SVT is induced at Wenchebach point. In presence of WPW syndrome, there can be eccentric activation with increasing preexcitation which can be easily appreciated on a 12 lead ECG during the study. Atrial extra stimuli are then given (single or multiple). Atrial extra stimuli may show an AH jump (where in there is AH prolongation of more

than 50 msec with a decrement of 10 msec on atrial extra stimuli interval), induce a tachycardia or bring out pre excitation with or without decremental antegrade conduction with a pre excited QRS complex.

### **ATRIAL INCREMENTAL PACING**

The atrial cycle length is progressively shortened until the atrium does not conduct to the ventricle in a one to one relation. This cycle length is called the AV node antegrade Wenchebach cycle length.

### **TACHYCARDIA STUDY**

Once tachycardia is induced relationship of the atrium and ventricular signals are noted. 1:1 AV activation generally suggest AVNRT, AVRT and atrial tachycardia but rarely ventricular tachycardia. A>V suggests atrial tachycardia and rarely AVNRT but never an AVRT or VT. V> A suggests ventricular tachycardia. During SVT atrial activation patterns helps to diagnose the nature of tachycardia.

### **MAPPING FOR LOCALIZING SITE OF ABLATION**

In many cases, catheter ablation immediately follows diagnostic electrophysiologic study. Mapping refers to careful movement of a mapping or ablation catheter in the area of interest, probing for the site at which radiofrequency ablation will be successful at curing the arrhythmia.

### **ACTIVATION MAPPING**

Where the activation signal in the mapping catheters shows earlier signals as compared to the surface P/QRS suggests the area to be near the origin of the arrhythmia and suggests an appropriate site for treatment

### **PACEMAPPING**

In a patient especially with ventricular tachycardia, pacing at the same cycle length as the tachycardia from the mapping catheter and comparing the 12 lead ECG obtained during pacing with that of tachycardia is called pace-mapping. If there is a 12/12 match is suggests the origin of the tachycardia to be nearby and is especially helpful for treatment of idiopathic ventricular outflow tachycardias.

## **ENTRAINMENT**

Pacing during tachycardia from the site of interest, when results in similar activation pattern to that of tachycardia, with difference in return cycle length of <20 msec from that of the cycle length of the arrhythmia, suggests the site of slow conduction and possible site for ablation. It is also called concealed entrainment. Presence of abnormal diastolic potentials, fractionated potentials or areas of continuous activity may suggest areas of slow conduction and possible sites of ablation.

## **RADIOFREQUENCY CATHETER ABLATION**

RF energy is a form of electrical energy that is produced by high-frequency alternating current. As the current passes through tissue, heat is generated. RF current used during endocardial catheter ablation is alternating current with a 500,000 to 750,000-Hz frequency range. The current passes from the electrode tip to a large surface area skin patch. The current is typically applied for 10 to 60 seconds at a time using 45 to 55 W. Catheter delivery of RF energy causes tissue heating in a small area around the electrode. The typical lesion is 3\*4\*5 mm. Alternate forms of energy for lesion generation are currently under development, including cryoablation, ultrasound and laser and microwave energy sources.

After a diagnosis is made, an ablating catheter is positioned at target area; catheter can be steered and has four to six electrodes 2 to 5 mm apart. The catheter tip is 4 to 8 mm long and serves as the electrode through which RF current is applied. The target area is located using fluoroscopy and by observing the electrogram patterns recorded by the distal mapping electrode pair.

## **POST ABLATION PROTOCOLS**

To confirm the success of ablation all pacing protocols need to be repeated after successful treatment of the arrhythmia with and without isoprenalin, atropine and adenosine whenever required.

## **COMPLICATIONS**

Complications related to the cardiac catheterization can be largely avoided by good technique and careful patient selection. Patients with left main artery stenosis, unstable angina, and critical aortic stenosis are the absolute contra

indications. Other complications are Local vascular complications, perforation and vasovagal reactions.

Radiofrequency ablation shares all the vascular risks and potential complications of EP studies. However, some unique complications may be associated with this technique. These include post ablation chest pain, pericarditis, AV block and radiation burns after prolonged procedures.

## **ADVANCED MAPPING AND NAVIGATION MODALITIES**

### **EnSite NavX Navigation System**

The EnSite NavX system (St. Jude Medical, Austin, Tex.) consists of a set of 3 pairs of skin patches, a system reference patch, 10 ECG electrodes, a display workstation, and a patient interface unit. The reference patch is placed on the patient's abdomen and serves as the electrical reference for the system. The EnSite NavX combines catheter location and tracking features of the LocaLisa system (Medtronic, Minneapolis, Minn.) with the ability to create an anatomical model of the cardiac chamber using only a single conventional EP catheter and skin patches.<sup>8</sup>

For 3-D navigation, 6 electrodes (skin patches) are placed on the skin of the patient to create electrical fields along 3 orthogonal axes (x, y, and z). The patches are placed on both sides of the patient (x-axis), the chest and back of the patient (y-axis), and the back of the neck and inner left thigh (z-axis). Analogous to the Frank lead system, the 3 orthogonal electrode pairs are used to send 3 independent, alternating, low-power currents of 350 mA at a frequency of 5.7 kHz through the patient's chest in 3 orthogonal (x, y, and z) directions, with slightly different frequencies of approximately 30 kHz used for each direction, to form a 3-D transthoracic electrical field with the heart at the center. The absolute range of voltage along each axis varies from each other, depending on the volume and type of tissue subtended between each surface-electrode pair. The voltage gradient is divided by the known applied current to determine the impedance field that has equal unit magnitudes in all 3 axes. Each level of impedance along each axis corresponds to a specific anatomical location within the thorax. As standard catheter electrodes are maneuvered within the chambers, each catheter electrode senses the corresponding levels of impedance, derived from the measured voltage.

The NavX system also allows for rapid creation of detailed models of cardiac anatomy. Sequential positioning of a catheter at multiple sites along the endocardial surface of a specific chamber establishes that chamber's geometry. The

system automatically acquires points from a nominated electrode at a rate of 96 points/sec. Chamber geometry is created by several thousand points.

## **MAPPING PROCEDURE**

NavX-guided procedures are performed using the same catheter setup as conventional approaches. Any electrode can be used to gather data, create static isochronal and voltage maps, and perform ablation procedures. Standard EP catheters of choice are introduced into the heart; up to 12 catheters and 64 electrodes can be viewed simultaneously. The system can locate the position of the catheters from the moment that they are inserted in the vein. Therefore, all catheters can be navigated to the heart under guidance of the EnSite NavX system, and the use of fluoroscopy can be minimized for preliminary catheter positioning.

Subsequently, 3-D intracardiac geometry is obtained. Respiratory compensation is collected just before mapping to filter low-frequency cardiac shift associated with the breathing cycle. Characteristic anatomical landmarks in the chamber of interest are initially acquired and marked. The system is then allowed to create the geometry automatically. A virtual anatomical geometry is acquired by moving the catheter in all directions throughout the chamber of interest, keeping contact with the endocardial wall. Additional tagging of sites of interest and ablation points can be done during the procedure. Point-to-point activation mapping is carried out to create static isochronal, voltage, and activation maps.

# **PACEMAKERS**

## **INDRODUCTION**

Arrhythmia device therapy is becoming more complex with every advance in technology, requiring clinicians to have more knowledge and greater responsibilities than ever before. Early pacemakers were single chamber devices designed to pace only in the ventricle, and the only programmable parameters were pacing rate and output. With the introduction of dual- chamber pacemakers with the capacity of pacing the atria and the ventricles, the number of programmable parameters increased dramatically. Antitachycardia devices were developed to terminate supraventricular and ventricular tachy arrhythmias using pacing techniques, cardio version, or defibrillation.

## **INDICATIONS**

The primary indication for a pacemaker is symptomatic bradyarrhythmias. In occasional instances, severe asymptomatic bradyarrhythmias are indications for pacemaker implantation.

The most common indications for permanent pacemakers can be classified as follows;

- Acquired atrioventricular block
  - Complete heart block, infranodal, persistent or intermittent. Mobitz type II second degree AV block, persistent or intermittent. AV nodal block, Mobitz type I, only when associated with symptoms. Atrial flutter or fibrillation with a slow ventricular response when associated with symptoms
- AV block associated with myocardial infarction.
  - Bundle branch block associated with fixed or transient mobitz type II AV block or complete block
- Sick sinus syndrome
  - Sinus bradycardia and arrest when associated with symptoms. Tachycardia – bradycardia syndrome, if drugs necessary to control the tachycardia produce symptomatic bradycardia.
- Hypersensitive carotid syndrome with syncope resulting from bradycardia

## **CONDRAINICATIONS**

There are very few contraindications to permanent pacemaker implantation. Implantations are contraindicated in patients with active infections; these patients should be managed with medications or temporary pacemaker until the infection is resolved.

## **RISKS**

The risks associated with permanent pacemakers are generally small. They include:

- Catheter dislodgement, lead fracture, or other causes of pacemaker system failure
- Pacemaker syndrome and pacemaker mediated tachycardia
- Infection or erosion of the pulse generator
- Cardiac perforation with very rare instances of tamponade
- Thrombosis of the superior vena cava or right atrium

## **EQUIPMENT FOR PERMENANT PACEMAKER IMPLANTATION**

The following equipment is necessary for implantation of a permanent pacemaker

- Pulse generator
- Ventricular and atrial leads
- 18 – guage vascular needle
- 0.035 inches J – tip safety guidewire
- Vein dilator with a peel away sheath
- Pacemaker system analyser to measure pacing thresholds and endocardial signals
- Pacemaker programmer
- Slandered surgical instruments and suture materials
- Back up equipment; external pacemaker, defibrillator, emergency cart with drugs, airways, suction equipment, and emergency sets for tube thoracostomy, open thoracostomy and pericardiocentesis

## **PATIENT PREPARATION**

Prepare the patient for pacemaker implantation as for any other major surgery. Inform the patient regarding the procedure, the risks, and what to expect. Obtain informed consent from the patient and from the relative, and what to expect. Keep in fasting for 6 to 8 hours before the procedure. Review result of blood count, electrolyte coagulation studies, chest radiograph and ECG. Administer a mild sedative half hour before the procedure. Establish an iv line before the procedure. Maintain continues ECG monitoring. Select the implant site. Both the left and right pectorial areas can be utilized. Any areas with abnormalities should be avoided. Prepare surgical field. Strict attention to aseptic techniques mandatory for all pacemaker insertions. Do not apply skin electrodes in the pacemaker field.

## **PACEMAKERS AND LEADS**

A pacemaker system for permanent pacing consists of a pacemaker and one or two leads implanted in the right atrium or right ventricle or both. The pacemaker contains a battery, the power source and a pulse generator, the electronic unit controlling the behaviour of the pacemaker

### **BATTERY**

The power source is usually constant –voltage lithium- iodine battery, which has a predictable voltage behaviour over time; the battery voltage remains relatively constant throughout most of its discharge. The potentials delivered by bradypacemakers are monophasic. Battery current drain is highly dependent on pacemaker programming. A pacemaker with a battery life of 6 years under nominal pacing parameters may reach its replacement time at 2 years at one extreme or at more than 10 years at the other extreme. Expected battery longevity for dual chamber pacemakers is 5-10 years; for a ingle chamber pacemaker it is 7-12 years.

### **PACEMAKER LEADS**

Pacemaker leads are unipolar or bipolar. In a unipolar system a single electrode (the cathode) is located at the lead tip, and the pacemaker can act as the other electrode ( the anode ). Bipolar systems have both electrodes near the distal end of the lead, the tip electrodes acting as the cathode and the more proximal ring electrode as the anode.

Bipolar leads have some advantage over unipolar leads. Bipolar leads reduce the risk of myopotential over sensing, far field sensing, cross talk and local skeletal muscle stimulation and they allow programmable switching between bipolar and unipolar configuration. The most important disadvantage of bipolar leads is that they have lower long term reliability than unipolar leads.

Most modern leads have a small tip surface area with porous surface, promoting low thresholds, low current drain and good sensing. Steroid eluting leads have a little reservoir of glucocorticoids, which diminishes the inflammatory reaction at the electrode- endocardial interface and thus improves acute and chronic pacing thresholds and sensing.

## **THRESHOLD**

The pacing threshold is defined as the minimum stimulus amplitude at any given pulse width that is required to achieve myocardial depolarization consistently outside the heart's refractory period. Threshold should be measured in volts. Threshold can be measured by increasing stimulus amplitude until capture occurs or by decreasing amplitude until loss of capture occurs. At pacing rates below 150 bpm, there is no significant difference between thresholds measured by these two methods. The thresholds depend on the pulse duration according to the strength – duration relationship. At implantation, an atrial threshold of <1.5v and a ventricular threshold of <1.0V at pulse width 0.5ms should be obtained. In most patients, the threshold rises during the first 2-4 weeks after implantation.

## **SENSING, SENSITIVITY AND IMPEDENCE**

Sensing is determined by the peak to peak amplitude in millivolts of the intracardiac electrogram. The amplitude of the ventricular R wave electrogram is larger than the size of the atrial P wave electrogram. At implantation, an atrial electrogram >1.5mV and a ventricular electrogram of a >6mV should be obtained. After implantation, the amplitude of the electrogram usually declines during the first week, then increases and reaches a chronic value slightly lower than that noted at implantation.

The slew rate defined as the change in intracardiac electrogram voltage over time ( $dV/dt$ ), should be >0.5V/s in both atrium and ventricle. Both the amplitude of the electrogram and the slew rate are important determinants for whether an electrical signal will be sensed by the pacemaker. In general, there are no

significant differences in sensing amplitudes or slew rates between leads with passive and active fixation.

Immediately after lead implantation, the sensed electrogram is distorted by an injury current –an ST elevation after the initial R-wave spike in the ventricular electrogram or an elevation after the P wave spike in the atrial electrogram. This injury current is thought to result from damage to the endocardial surface produced by contact with or pressure from the lead, and thus reflects good endocardial contact. The injury current disappears after a few days.

Sensitivity is the level that an intracardiac electrogram has to exceed in order to be sensed by the pacemaker. Sensitivity is programmable and acts as a filter for noise, ensuring that small are not sensed by the pacemaker and interpreted as cardiac electrograms. Sensitivity should be programmed after measurement of the intracardiac electrogram. Sensitivity should not exceed half that of the sensed electrogram. Sensitivity must be larger than unipolar leads than with bipolar leads because noise signals are larger in unipolar leads.

Impedance can be defined as the sum of all forces opposing the flow of current in an electric circuit. Impedance is measured in ohms. In Pacemaker systems, the lead impedance is determined by the resistance of the conducting lead, the tissue between the electrodes, and the tissue- electrode interface. Normal lead impedance is 250-1200 ohm at output 5.0V. Usually, lead impedance remains stable or decreases slightly after implantation. Very low impedance may indicate failure of lead insulation, whereas high impedance accompanied by a high pacing threshold indicates lead fracture.

## **PROGRAMMABILITY OF PACEMAKERS**

Programmability is the features by which the electronically controlled performance of a pacemaker can be noninvasively altered. This alteration is permanent until the pacemaker is otherwise reprogrammed. Programming is achieved by using an external programmer to transmit preselected messages in the form of binary code, via either radiofrequency waves or a pulsed electromagnetic field, to the implanted pulse generator. Features that can be programmed noninvasively include stimulus output, rate, amplifier sensitivity, escape rate, hysteresis, lower and upper rate limits, AV interval, refractory period and mode.

The voltage, current and pulse duration constitute the pulse generator output. The voltages of two batteries in series are added so it is a battery source of

about 5.6v. The automatic rate is the interval between consecutive atrial or ventricular paced stimuli. This setting is programmable between 30 and 150 bpm.

Sensitivity is the ability of the detection system of the pacemaker to recognize the intrinsic cardiac signal and to use that signal to control the output of the pacemaker. The sensing circuit recognizes the R or P wave by its amplitude and slew rate.

The Escape rate is the interval between the last sensed beat and the first pacemaker beat to follow. Hysteresis occurs when the escape interval is longer than the programmed interval, i.e. the pacemaker does not begin firing until the patient's rate drops below 60 beats per minute.

The lower rate limit is the lowest rate at which a pulse generator is programmed to track to the spontaneous atrial rate. The upper limit is the fastest rate at which a pulse generator is programmed to track the spontaneous atrial rate on 1:1 basis. The AV interval should be programmed within the physiologic rate 0.12 to 0.2 seconds for a maximal cardiac output.

## **REFRACTORY PERIOD**

The refractory period is the period during which a pulse generator a pulse generator is unresponsive to an input signal. The pacing refractory period follows a paced complex, and the sensing refractory period follows a sensed spontaneous complex.

## **MODES OF PACEMAKERS**

The current nomenclature used to describe the expected function of a pacemaker was established by members of the North American Society of pacing and electrophysiology and the British pacing and the electrophysiology group and is designated the NBG code for pacing nomenclature. The code describes the expected function of the device according to the site of the pacing electrodes and the mode of pacing.

The first letter describes the chamber that is paced: A, atrium: V, ventricle, D dual, O none. The second letter describes the chamber where intrinsic electrical activity is sensed: A, atrium V, ventricle D dual O, none. The third letter describes the pacemaker's response to sensing of intrinsic electrical activity. I inhibited, T triggered, D dual, O none. The fourth letter denotes the presence or absence of rate modulation, R rate modulation O none. The fifth letter specifies the location or

absence of multisite pacing, which includes either biatrial or biventricular pacing or more than one stimulation site in a single chamber. The most commonly used pacing modes are VVI and DDD.

## **PACEMAKER IMPLANTATION**

Most frequently in order to place a lead for permanent pacing, the cephalic vein is located and cannulated in the deltopectoral groove under local anesthesia. Less commonly, the internal or external jugular vein is used. Under fluoroscopic imaging the electrode can be guided into the apex of the right ventricle. Satisfactory thresholds are documented by measurement with a pacing system analyzer rather than with a temporary pacemaker. The minimum voltage necessary to capture the ventricle is determined. The electrical resistance in ohm can be calculated. This value reflects the resistance of the lead and the electrode – myocardial interface. The amplitude of the patient's intrinsically generated QRS pattern is then measured.

The leads are attached to the pulse generator and a pocket is fashioned by separating the pectorals muscle fascia from the overlying subcutaneous tissue. The subcutaneous and skin are closed in layers.

Endocardial fixation of leads can be either passive or active. Passive fixation is obtained using leads with tines or wings, which are trapped in the trabeculae of the right atrium or the right ventricle. Active fixation is obtained by screwing a tip –screw into the atrial or ventricular myocardium. Active fixation reduces the frequency of atrial lead dislodgement and is therefore recommended as standard in the right atrium. In the right ventricle leads with active fixation can be implanted in localities other than the apex, such as the outflow tract or the septum.

Atrial pacing leads are being implanted with increasing frequency. This kind of lead is almost always implanted simultaneously with a ventricular lead, but positioned in the atrial appendage. If the atrial J lead is used, the lead is advanced with the stylet in place to the lower right atrium near the tricuspid valve. The stylet should be withdrawn and the tip positioned anteriorly as the lead assumes its J shape. The lead then can be pulled back slightly to engage the right atrial appendage. The tip should be stable in the right atrial appendage with gentle rotational movement of the lead and with deep breaths by the patient.

A type of introducer with a peel away sheath is used often for permanent transvenous lead placement. A subclavian vein puncture is performed, a guide wire is

passed into the subclavian vein, and a dilator and a sheath are advanced over the guide wire into the subclavian vein. The guide wire and dilator are then removed, and the sheath is left in the vein for passage of the pacing lead. The lead can be advanced to the heart through the sheath, and sometimes both atrial and ventricular leads are placed through a single sheath. The sheath then can be split apart and discarded to allow connection of the lead to the generator.

## **LEAD AND GENERATOR CONNECTION**

The attachment of the electrode to the generator is an important step in pacemaker implantation, and problems with the connection are relatively common sources of pacemaker malfunction. The exposed metal portion of the connector is inserted into the pulse generator. The insertion must be complete, and the metal wire and insulating material should fit snugly in to the socket. The fit is tight to avoid fluid intrusion into the connection. A metal set screw is screwed down to complete the connection. Finally an insulating plastic plug is placed over the metal set screw to avoid fluid intrusion that could lead to a short circuit in the system or corrosion of the connection. Modifications of this type attachment are present in various pacemaker models.

## **COMPLICATIONS**

- Early failure to capture and sense
- Late failure to pace
- Pacemaker syndrome
- Pacemaker – mediated tachycardia
- Infection
- Myocardial perforation and tamponade
- Thrombosis and embolism
- Erosion of the pulse generator

## **PACEMAKER FOLLOW – UP**

Patient should have a thorough evaluation at 2 to 4 weeks after implantation. The history should document relief of pre pacing symptoms. A physical examination should be performed, with special attention to the pacemaker pocket. Pacemaker function should be checked by a rhythm strip with magnet if necessary and accurate records should be kept off the pacemaker analysis. Any necessary adjustment can be made by programming. Many physicians set the pacemaker at a

high output for the first 6 weeks to avoid exit block as the lead matures. After this time period the output can be decreased to preserve battery life. Most physicians check the pacemaker by one or the other modalities approximately every two months and increase this frequency to once monthly as the end of the pacemaker life approaches.

## **IMPLANTABLE CARDIOVERTER DEFIBRILLATOR**

### **INDRODUCTION**

An implantable cardioverter-defibrillator (ICD) or automated implantable cardioverter defibrillator (AICD) is a device implantable inside the body, able to perform cardio version, defibrillation and pacing of the heart. The device is therefore capable of correcting most life-threatening cardiac arrhythmias. The ICD is the first-line treatment and prophylactic therapy for patients at risk for sudden cardiac death due to ventricular fibrillation and ventricular tachycardia. Current devices can be programmed to detect abnormal heart rhythms and deliver therapy via programmable antitachycardia pacing in addition to low-energy and high-energy shocks.

### **INDICATIONS**

- With LVEF  $\leq$  35% due to prior MI who are at least 40 days post-MI and are in NYHA Functional Class II or III
- With LV dysfunction due to prior MI who are at least 40 days post-MI, have an LVEF  $\leq$  30%, and are in NYHA Functional Class I
- With nonischemic DCM who have an LVEF  $\leq$  35% and who are in NYHA Functional Class II or III
- With nonsustained VT due to prior MI, LVEF  $<$  40%, and inducible VF or sustained VT at electrophysiological study
- With structural heart disease and spontaneous sustained VT, whether hemodynamically stable or unstable
- With syncope of undetermined origin with clinically relevant, hemodynamically significant sustained VT or VF induced at electrophysiological study

## **GENERATOR**

Today, ICD generators are similar in size to the original pacemakers and can now be placed within the chest wall. The largest components of the generator are the capacitor and the battery. ICD are usually placed in the pectorial region, allowing the procedure to be performed in the catheterization laboratory.

The generator consists of two major components. One operates at low current, low voltage and low energy, and yields signal amplification, electrogram storage, arrhythmia sensing and detection, and decision making when therapy criteria are fulfilled. The other component operates at high current, high voltage, and high energy.

The battery used in the ICD is usually lithium silver vanadium oxide batteries providing 6.4V or 3.2V, which allows rapid discharge into a capacitor for the frequent rapid shocks that, may be required of the ICD device. Longevity is currently often estimated to be 4 years, depending on the frequency of use.

## **LEADS**

The lead would be placed in the right ventricle and would provide continuous sensing of the ventricular rate. The current systems incorporate both therapy and rate sensing function to a single transvenous endocardial lead for simplicity. The bipolar lead can pace in the ventricle and sense the ventricle rate, and the shocking portion of the lead can provide a larger electric charge between the coil and generator.

Current leads are generally dual coil; the generator and the proximal coil have the same polarity. Electricity flows in a three- dimensional configuration from the distal coil to both the proximal coil and generator. This greater dispersion of the electrical field increases the likelihood of depolarizing the entire ventricular myocardium at once leading to successful defibrillation.

## **SENSING**

Sensing in an ICD is much more complicated issue than in a pacemaker. In the ICD the sensing circuit must be dynamic. It must sense and count QRS complexes appropriately and avoid double counting by sensing the T wave, which can lead to inappropriate electrical therapy. The device must in addition be able to become more sensitive after sensing the QRS complexes so that if ventricular fibrillation

occurs, it can sense the defibrillatory waves. The device also must be programmable to deal with sensing.

## **TACHYCARDIA DETECTION**

The fundamental way that the ICD identifies the presence of a sustained ventricular tachyarrhythmia is by detecting that the heart rate has exceeded a critical value as measured in the ventricle. Because most episodes of sustained VT exhibit a rate in excess of 150 beats per minute, the device can be programmed to initiate therapy when this rate is reached. Programming decision regarding tiered therapy must take into account the hemodynamic status of the patient during the tachyarrhythmia episode.

For antitachycardia pacing, additional detection criteria may be programmed to enhance the certainty that a ventricular tachyarrhythmia is present rather than a supraventricular tachyarrhythmia, often AF, such detection enhancements include the identification of cycle length stability, the abruptness of onset of the tachyarrhythmia, morphology analysis, and the duration of sustained rate. The morphology of ECG as measured by the device may also be used to differentiate supraventricular tachycardia versus ventricular tachycardia.

## **THERAPY TIERS**

Because VF often manifests as rates in excess of 240 bpm, the ICD may be programmed to respond to such rates by defibrillation. With tiered therapy devices, rate ranges can be programmed that determine the type of therapy to be delivered. Thus with rates of 150 to 240 bpm, antitachycardia pacing or low energy cardioversion can be used for rates greater than 240 bpm defibrillations may be the programmed response.

## **BRADYCARDIA PACING**

Often patients successfully converted out of VT or VF is found to have marked sinus bradycardia immediately post conversion, posing another threat to hemodynamic stability. Therefore modern ICD devices often have the option of VVI, DDD, DDDR, pacing. After a shock, the threshold required to pace may increase. Therefore, as a precaution, a higher output can be programmed for several beats after the shock.

## **ANTITACHYCARDIA PACING**

Many ICDs are implanted as the first – line therapy for recurrent sustained monomorphic VT. It has been shown that a sustained VT can be reliably terminated by antitachycardia stimulation techniques. Delivery of antitachycardia pacing, either a **burst** or a **ramp** of stimuli, is coupled to the last sensed tachycardia beat that fulfilled detection algorithm criteria. The number of stimuli within a burst, the coupling interval and the burst cycle length are programmable. In general, more than one burst attempt is recommended for VT therapy. A scanning mode is a pacing modality in which the burst cycle length of subsequently firing bursts progressively shortens or lengthens. A ramp mode means that the cycle length within one burst shortens or lengthens from stimulus to stimulus. A combination of scanning and ramp pacing may also be applied.

## **LOW ENERGY CARIOVERSION**

Low level cardio version is occasionally the first line treatment for VT with rates greater than 150 to 180 and less than 240 bpm not responsive to tachypacing. The tiered ICD delivers the cardioversion synchronized with the QRS complex, thus avoiding the vulnerable period of the T wave and risking initiation of VF. The amount of energy may be programmed to a minimum of 0.1J. Significant reduction in pain perception may be noted below 2J, whereas no perceptible differences may be observed between 5 and 34 J in many patients.

More efficient cardioversion has been affected by improvement in lead design, lead arrangement, and the shape of the pulse waveform. If antitachycardia pacing or cardioversion fails to terminate the tachycardia after a programmed time interval or if the tachycardia accelerates, defibrillation therapy will be initiated.

## **DEFIBRILLATION**

Defibrillation is the first line therapy when VF is the presenting rhythm. For defibrillation, electric current delivery does not need to be synchronized with a given portion of the ECG complex. After the patient has been in VF for a programmed interval, shocks that may range between 50 and 850 V or 0.1 and 38 J will be delivered. If the first shock fails to terminate the rhythm, subsequent shocks will be delivered, usually up to five or six, depending on the manufacturer and what has been programmed.

## **COMPLICATIONS**

- Perioperative mortality and morbidity
- Infection
- Frequent ICD discharges
- Sudden cardiac death despite ICD therapy
- Quality of life and driving restrictions

## **PATIENT FOLLOW UP**

The fundamental objective of a follow up program for ICD patients is continues lifelong patient care, which must be distinguishing from pure device management. Compliance with follow-up visits is an important element in evaluating appropriate ICD function. Follow up must be performed in an organized program.

## **CARDIAC RESYNCHRONIZATION THERAPY**

### **INDICATIONS**

Basically the current indications are that the patient has a left ventricular ejection fraction of equal to or less than 35%. The source of the cardiomyopathy can be ischemic or non ischemic. The QRS duration should be greater than or equal to 120 msec. The patient should be in the AHA class III or IV congestive heart failure ranking and should be on optimal pharmacologic therapy for congestive heart failure. CRT has been advocated in patients with RBBB and heart failure and patients with LBBB and heart failure.

### **IMPLANTATION**

Patient undergoing CRT has a right atrial lead and ventricular lead placement. In the case of the AF, the atrial lead is not implanted. The more complex portion of the implantation is to place a lead through the coronary sinus and down a vein on the posterolateral side of the heart. The lead is an inactive with no tines or the ability to be secured with screw in leads. The curve at the end is built into the lead itself. There are different types of curves available, but the general principle is that the curve is designed to cause pressure of the pacemaker tip against the myocardium within the narrow vein. The lateral threshold may be higher than a typical threshold bur the difference is fairly minimal. The sensing is done through the right ventricular lead.

## **LEAD EXTRACTION**

The lead extractions are probably one of the most challenging procedures. The indication for transvenous lead extraction can be categorized into two groups, patients related and lead related. Patients related indications are infection, ineffective therapy, perforation, migration, embolization, induction of arrhythmias, venous thrombosis, unrelenting pain, device interactions, device upgrades. Lead related indications include lead recalls, lead failure, and lead interactions.

## **TECHNIQUES OF LEAD EXTRACTION**

- Control of the lead body and tip, which could be achieved by binding of its elements with the application of uniform force on the entire length of the lead, to remove it in once piece with minimal disruption
- Locking stylets provide tensile strength to the lead all the way to the tip electrode.
- Control disruption of the fibrous tissue using counterpressure
- Bracing the cardiac wall using countertraction, which involves opposing the traction placed on the lead by bracing the myocardium with the overlying blunt sheath. This focuses the traction force perpendicular to the heart wall and limits the counterpressure to the scar tissue immediately surrounding the lead tip.

## **DIRECT CURRENT CARIOVERSION AND DEFIBRILLATION**

Cardioversion is the procedure by which direct current (DC) that has been synchronized to discharge with the QRS complex of the ECG is delivered across the heart for the purpose of converting an atrial or ventricular arrhythmia to normal sinus rhythm. Defibrillation is nonsynchronized cardioversion and is used when QRS complex and T waves are not distinguishable or present, as in ventricular flutter or ventricular fibrillation.

## **THE VULNERABLE PERIOD**

The heart is particularly susceptible to ventricular fibrillation during the so called vulnerable period, an interval that begins and ends with the T wave but that is at its peak for about 30 msec just before the apex of the T wave of the ECG. At this point the current required to elicit ventricular fibrillation is at its lowest. In the ischemic heart the stimulus required to cause fibrillation is much less than it is in the normal heart.

## **TYPES OF DEFIBRILLATORS**

### **DAMPED SINE WAVE**

The damped sine wave defibrillator consists of a capacitor, inductor, and electrodes. The energy is stored in the capacitor and is discharged through the inductor to the electrodes and then directly through the heart or across the thorax and through the heart. The energy delivered to the heart is less than the stored energy because of the resistance in the inductor, the internal resistance of the defibrillator, and the transthoracic impedance, which varies considerable among humans. Thus the energy stored in a defibrillator can be accurately measured, as can the energy delivered into a test load, but the actual energy current delivered to the heart remains variable and not directly measured.

### **TRAPEZIODAL WAVE**

Defibrillators using the trapezoidal wave have been available for more than 10 years. Definitive data regarding their advantages and disadvantages are lacking. Maximal output from these defibrillators is 400 J, and the threshold current needed for defibrillation is approximately the same as for the damped sine wave. It has larger electrodes than do other defibrillation.

### **INDICATION**

- Atrial flutter or fibrillation of recent onset that cannot be converted to a sinus rhythm after the elimination or control of initiating or predisposing factors and after the use of antiarrhythmic medications.
- Supraventricular tachycardia that does not respond to vagal manoeuvres or antiarrhythmic therapy and is not caused by digitalis intoxication
- Ventricular tachycardia that is refractory to antiarrhythmic drug therapy or is associated with hemodynamic instability
- Ventricular flutter or ventricular fibrillation

### **CONTRAINDICATIONS**

Supraventricular tachycardia caused by digitalis toxicity is an absolute contraindication for synchronized cardioversion. It is relatively contraindicated either a low chance of success or high chance of recurrence of the arrhythmia, appreciable risk of precipitating a potentially more dangerous tachyarrhythmia, or risk of precipitating or unmasking of bradycardia or asystole.

## **SYNCHRONIZING THE CARADIOVERTER**

Connect the ECG to the oscilloscope of the cardioverter and monitor the ECG in the lead. Test the synchronous discharge of the cardioverter to be sure that discharge occurs during or slightly after the R wave of the ECG. The risk of provoking VF is the main danger in cardioversion if the procedure is done without proper synchronization.

## **PADDLE POSITION**

Correct paddle electrode placement is important; improper placement reduces intracardiac current flow and is an important cause of failure to cardiovert or defibrillate. The paddle may be applied to the chest in one of three ways; anteroapical, anteroposterior, apicalposterior. All three positions are probably equally effective.

For patients with dextrocardia, the position of electrodes should be a mirror image to reflect the change in the heart's position. In patients with heart malposition or chest wall deformity, allowances for paddle position should be made to permit positioning the heart between the paddles.

## **CHOICE OF ENERGY SETTING**

The initial setting of cardioversion in an adult may be 10 to 100 J delivered, depending on the arrhythmia. In VT 10 J may be a large enough charge for successful cardioversion, whereas 100 J is almost always effective. Atrial flutter may be converted to sinus rhythm at energy levels of 20 to 25 J. Very low energy levels may convert atrial flutter to atrial fibrillation and thus are not recommended.

Most SVT responds to verapamil or vagal maneuvers. When cardioversion is needed, a 50 to 100 J charge is almost always successful in converting it to sinus rhythm. Atrial fibrillation usually requires from 100 to 150 J delivered energy and sometimes over 200J. In case of possible or suspected digitalis excess or subclinical digitalis toxicity, it may be safer to start all electric cardioversion.

The first defibrillatory attempt should be with 200J delivered energy, nonsynchronized. Rapidly follow with 200 to 300j and 360 as needed. If refrillation occurs, repeat the shock at the previously successful energy level.

## **DEFIBRILLATION PROCEDURE**

- Turn on the defibrillator
- Apply the adhesive pads in proper electrode position
- Set energy level to 120 to 200 J for biphasic and 360 for monophasic defibrillators
- Charge capacitors, it make several seconds
- Ensure proper electrode placement on the chest. If using paddles apply pressure of 25 lb per paddle.
- Scan the area to ensure that no personnel are in contact directly or indirectly with the patient. State firmly “all clear”
- Check rhythm, if patient remains in VF, deliver shock by depressing discharge button
- Repeat assessment procedure

## **TEMPORARY PACEMAKERS**

A temporary pacemaker consists of a transvenous catheter electrode attached to an external pulse generator. Temporary pacemakers are used when the need for pacing is immediate. Temporary pacemakers may be followed by permanent pacers if the need for pacing persist or may simply be removed if the need for pacing is self- limited.

## **INDICATIONS**

- Complete heart block with slow ventricular escape
- Symptomatic sinus bradycardia, asystole, or prolonged sinus pauses
- Acute anterior myocardial infarction with complete heart block, Mobitz type II AV block, or new bifascicular block
- Selected tachyarrhythmias such as bradycardia-induced or drug induced torsades de pointes, atrial flutter, or recurrent sustained VT
- Malfunction of implanted pacemaker

## **TEMPORARY PACING CATHETER**

The most commonly used pacing catheter is a 6F bipolar catheter, which is relatively stiff and requires manipulation under fluoroscopy. Once properly positioned, it tends to be quite stable. Bipolar catheters have two wires terminating in two electrodes located 1 to 2 cm apart at the tip of the catheter. The distal

stimulating electrode is negative and the proximal electrode is positive. Unipolar catheters have one wire terminating in a distal electrode (cathode), which comes in direct contact with myocardium.

## **PROCEDURE**

Under fluoroscopic guidance, advance the pacing catheter to the right atrium, then through the tricuspid valve and into the right ventricle. Then advance catheter into the right ventricular apex. After achieving a satisfactory right ventricular position, connect the pacing catheter, using a sterile connecting cable, to the external pulse generator. Test the pacing threshold by turning on the pulse generator at a moderately high output and at a rate higher than the patient's intrinsic rate. After satisfactory capture is achieved, gradually reduce the output until capture is lost. This milliamperage level is the patient's pacing threshold. This is less than 1mA. Repeat the step to be sure that the threshold is consistent. The output should be set at 3 to 4 times this level for consistent capture. Set the pacing rate usually 70 to 80 bpm, although higher or lower rates may be preferred in certain circumstances.

During insertion of the pacing lead, atrial or ventricular arrhythmias may as a result of excessive catheter manipulations. Failure to capture may often be corrected by increasing the output of the pacemaker. Failure to sense can often be corrected by adjusting the sensitivity of the unit. If these maneuvers are not sufficient, then the pacing catheter requires repositioning for failure to pace. Cover the insertion site with antibiotic ointment and sterile dressing. Assess pacemaker function again.

# **INTRA-AORTIC BALLOON COUNTERPULSATION**

## **INTRODUCTION**

Intra-aortic balloon counterpulsation is a method of temporary mechanical circulatory support that attempts to create more favourable balance of myocardial oxygen supply and demand by using the concepts of systolic unloading and diastolic augmentation.

### **Current indications**

- Cardiogenic shock complicating MI
- Acute mitral regurgitation
- Ventricular septal defect (VSD) as a complication of myocardial infarction
- Intractable ventricular arrhythmias:

The indications of IABP are constantly changing. In the recently published 600-patient IABP SHOCK II trial, use of an intra-aortic balloon pump (IABP) offered no mortality benefits.

### **Indications with probable benefit**

- Decompensated critical aortic stenosis
- Perioperative support for coronary artery bypass surgery

### **Absolute contraindications**

- Significant aortic regurgitation (no consensus on what degree of aortic regurgitation is an absolute contraindication)
- Aortic dissection

### **Relative contraindications**

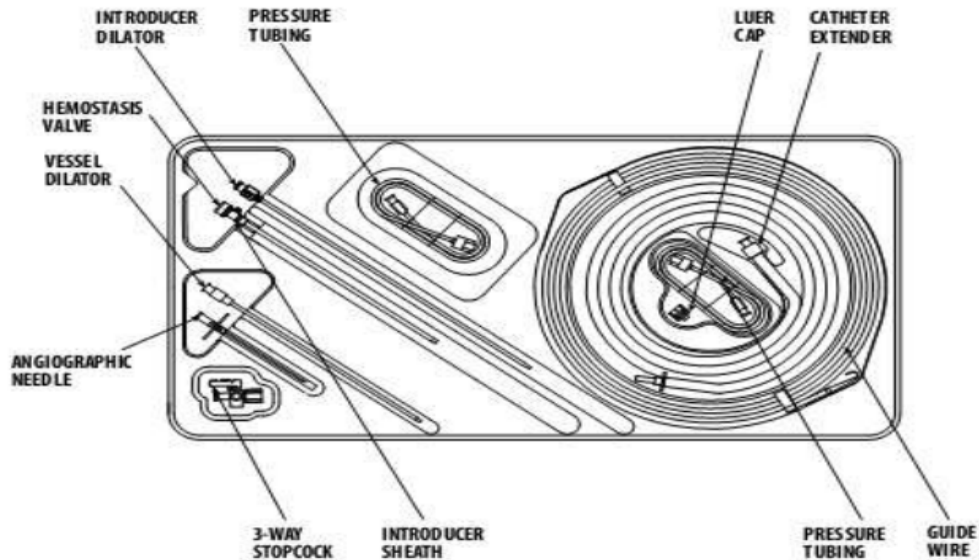
- Bilateral iliofemoral peripheral arterial disease
- Abdominal aortic aneurysm
- Presence of iliac arterial stents
- Prosthetic iliofemoral grafts
- Coagulopathy

## HARDWARE

There are two separate containers which contain all the hardware required for IABP insertion

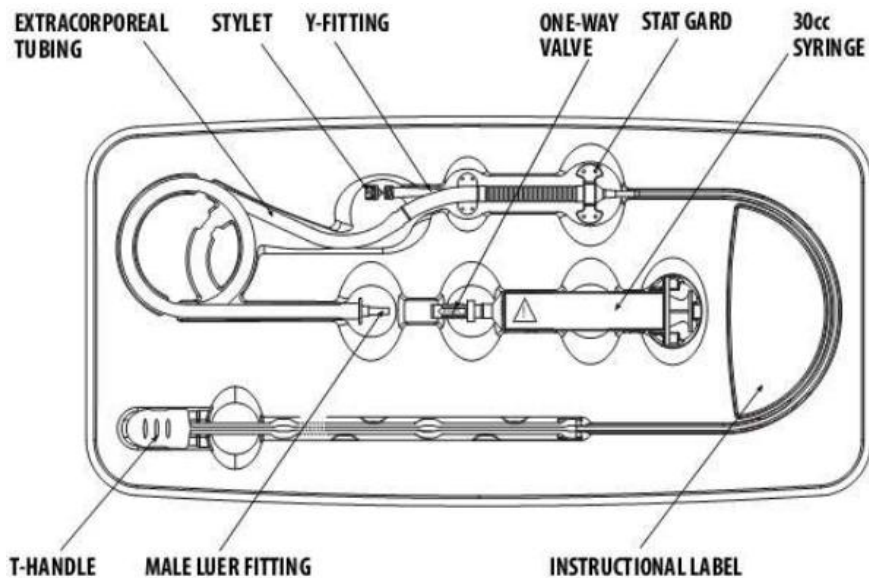
### 1. Insertion kit

#### **INSERTION KIT**



- a. It contains all the instrumentation required for arterial access
- b. It also contains the catheter extender and pressure tubing required for connecting IABP to the console

### 2. Intraaortic balloon



- a. This kit contains the balloon with stylet, one way valve and a 30 cc luer lock syringe.

## **IABP catheter**

- ~10-20 cm long polyurethane bladder
- 25cc to 50cc capacity
- Optimal 85% of aorta occluded (not 100%)
- The shaft of the balloon catheter contains 2 lumens: one allows for gas exchange from console to balloon;
- The second is used for catheter delivery over a guidewire and for monitoring of central aortic pressure after installation.

## **Techniques of insertion and operation**

IABP catheters are supplied with an instruction booklet that should be reviewed before use.

## **Things to note PRIOR to insertion**

1. Rule out peripheral vascular disease
  - a. Arterial Doppler both lower limb may be done in elective cases – BEFORE taking up high risk cases (unprotected LMCA stenosis)
2. Contralateral access (5F sheath – for instant access)

## **The selection of balloon size**

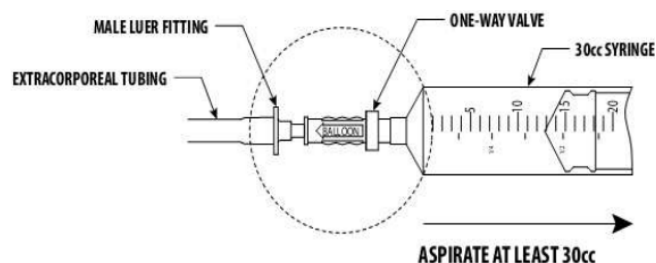
Selection of balloon size is determined by the height of patient.

<b>Patient height (approx)</b>	<b>Balloon size</b>
<b>Over 6 feet (183 cm)</b>	50 cm <sup>3</sup>
<b>From 5.4 – 6 feet (163 cm – 183 cm)</b>	40 cm <sup>3</sup>
<b>From 5-5.4 feet (152 cm – 163 cm)</b>	35 cm <sup>3</sup>
<b>Less than 5 feet (152 cm)</b>	25 cm <sup>3</sup>

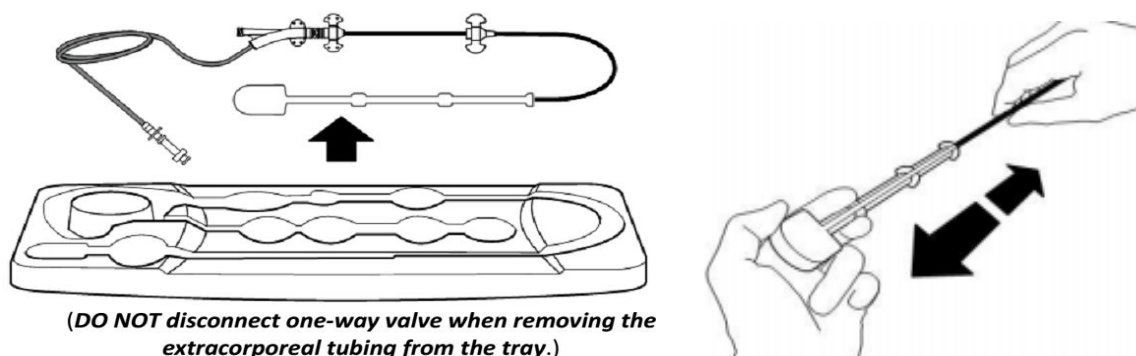
## **STEP BY STEP (STANDARD FLUOROSCOPIC WITH SHEATH)**

1. Connect the IABP to supply line. Check Helium gas status
2. Connect ECG- to the IABP console. (good ECG – must for trigger)

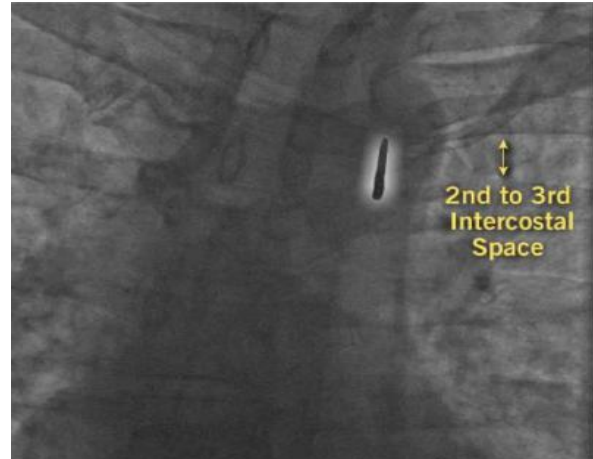
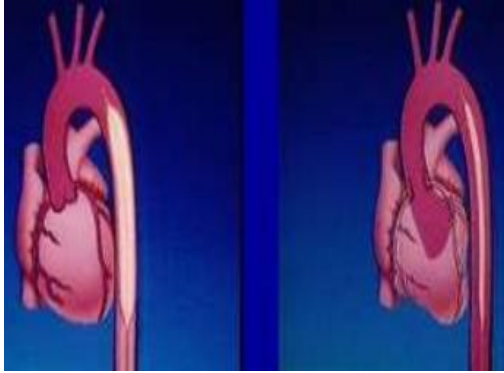
3. Ensure that appropriate size IABP balloon and IABP insertion kit (supplied in separate boxes) is available
4. Femoral access – followed by insertion of the supplied sheath (usually 8 or 9.5 French depending on size)
5. Insert the 0.030 inch supplied J-shaped guide wire to the level of the aortic arch
6. Once access is secured and sheath is on place prepare the balloon
7. The shaft of the balloon catheter contains 2 lumens: one allows for gas exchange from console to balloon; the second is used for catheter delivery over a guidewire and for monitoring of central aortic pressure after installation.
8. Before removing balloon catheter from box, use the supplied 30cc syringe, slowly aspirate at least 30cc.



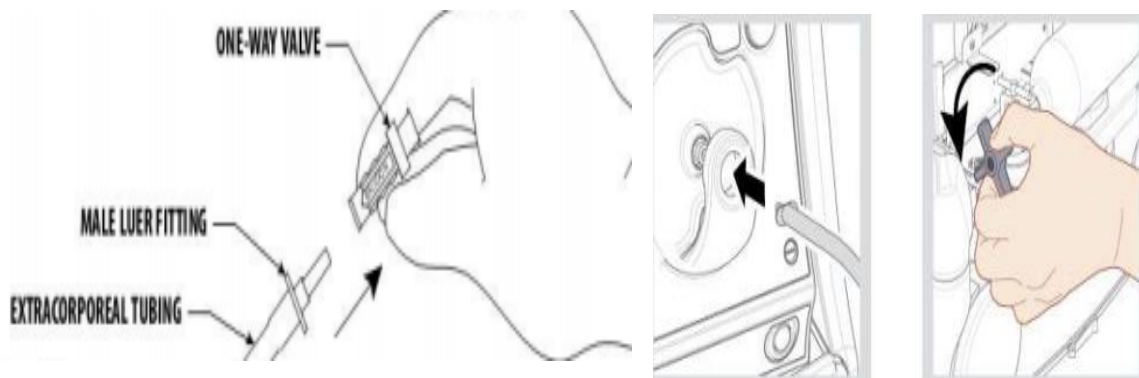
9. Remove the syringe while leaving the one-way valve place.
10. Carefully remove the extracorporeal tubing, Y-fitting and IABP catheter T-handle from the tray – (do not disconnect one-way valve when removing the extracorporeal tubing from the tray)
11. Do not remove the T-handle or packaging stylet until immediately prior to insertion.
12. Maintain a vacuum on the IAB catheter through insertion. Do not remove the one-way valve.
13. IABP central lumen is flushed with saline
14. Remove the IAB catheter from the T-handle by pulling straight out to avoid damaging it.



15. Insert a balloon (remove stylet) only over the guidewire.
16. Advance in small steps of 1 to 2 cm at a time and stop if any resistance.
17. The tip of the IABP catheter should lie 1-2 centimetres distal (below) to the origin of the left subclavian artery
18. This corresponds to 2 and 3 rd intercostals space on fluoro.



19. The proximal end of balloon should be above the renal arteries.
20. After IAB insertion has been completed, remove the one-way valve from the male luer of the extracorporeal tubing.



21. Connect to the console via a long extenderconnector (also supplied) and the system is purged with helium.
22. The central lumen of the catheter is connected to pressure tubing and a pressure transducer to allow for monitoring of central aortic pressure.
23. Heparin should be given as a bolus and continuous infusion to maintain a partial thromboplastin time (PTT) of 60-80 seconds or an activated clotting time (ACT) of 1.5-2.0 times normal.
24. The ECG and pressure tracing should be clear on the IABP console
25. The balloon catheter is secured to the skin by sutures.

Although not ideal IABP catheter may also be inserted sheathlessly and without fluoroscopy. If fluoroscopy is not available, measure the tip of the IAB from

the sterna angle of Louis to the umbilicus and then obliquely to the femoral insertion site for catheter insertion length. X-ray chest must be taken immediately to confirm balloon position.

### **Initial set-up**

1. Once connected properly the console would show ECG and pressure waveforms.
2. Elevate flush bag at least 3' (91.44 cm) above transducer
3. A 3 cc/hour continuous flow through inner lumen is recommended
4. By default the system will be in standby mode. Start pumping by prssing START on the console (automatic mode)

### **Pressing the START key**

- Automatically purges and fills IAB
- Automatically select most appropriate lead and trigger
- Automatically sets inflation and deflation timing

### **Auto operation mode**

- Automatic lead and trigger selection
- Automatic and continuous inflation and deflation timing management – user has ability to fine-tune deflation timing
- Automatic management of irregular rhythms

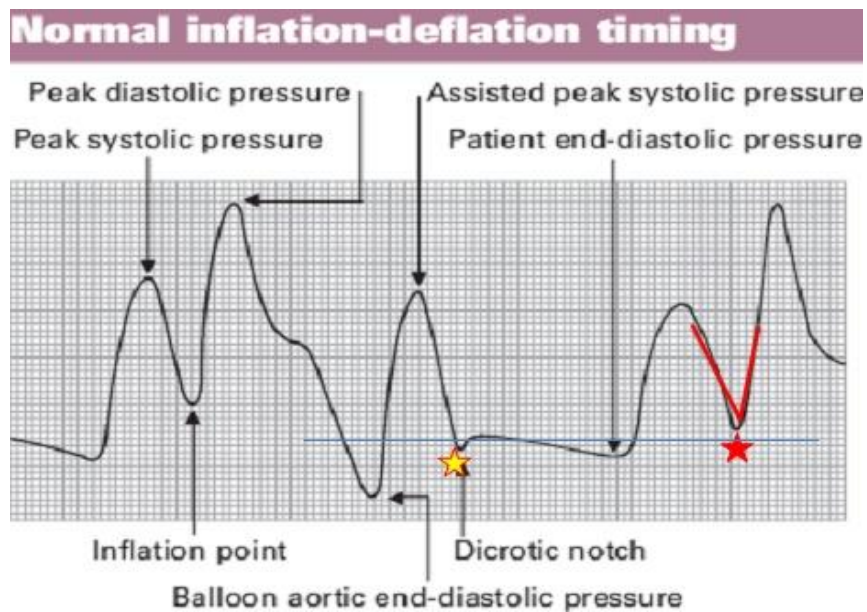
### **Triggering and timing**

- Correct timing of balloon inflation and deflation during the cardiac cycle is vital to ensure optimal effects of counter pulsation whilst minimizing potentially harmful effects related to mistiming.
- Most commonly (and by default) the ECG waveform is used to trigger balloon inflation and deflation.
- The arterial pressure waveform is an alternative technique that may be useful if either the ECG trace is poor or there are cardiac arrhythmias.
- Modern machines allow either method to be easily selected.
- The balloon starts to inflate at the onset of diastole. This corresponds to the middle of T wave on the ECG waveform and the dicrotic notch of the arterial pressure trace.

- As aortic valve closure has occurred balloon inflation causes a sharp upstroke on the arterial pressure waveform followed by a tall peak which represents the assisted diastolic pressure.
- Deflation occurs at the onset of systole immediately before opening of the aortic valve. This corresponds with the peak of the R wave on the ECG trace and the point just before the upstroke of systole on the arterial pressure trace.
- As the balloon deflates, the assisted aortic end-diastolic pressure dips down to create the second deep wave, usually U shaped on the arterial pressure waveform

### **Troubleshoot – timing**

Analyse the wave form periodically to check if IABP is working well. The following points on the waveform are noted.



A: Unassisted End Diastolic pressure

B: Unassisted Systole

C: IAB Inflation

D: Diastolic Augmentation

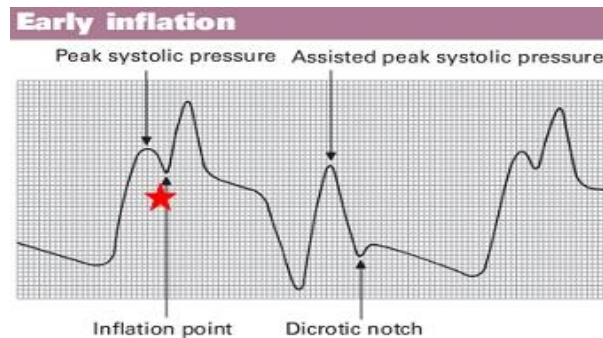
E: Assisted End Diastolic Pressure

F: Assisted Systole

## Timing error – early inflation of IAB (prior to aortic valve closure)

### Waveform characteristics:

- Inflation IAB to dicrotic notch
- Diastolic augmentation encroaches onto systole (may be unable to distinguish)



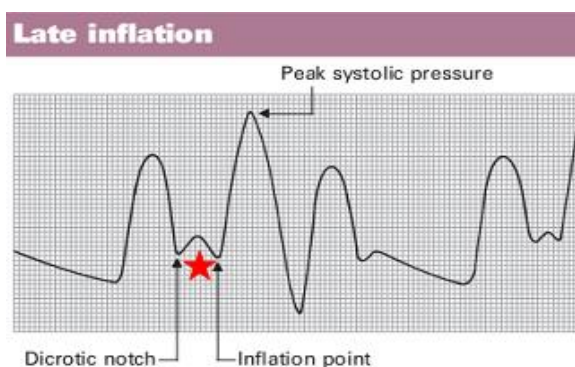
### Physiologic effects:

- Potential premature closure of aortic valve
- Potential increase in LVEDV/LVEDP/PCWP
- Increased left ventricular wall stress or after load
- Aortic regurgitation
- Increased  $MVO_2$  demand

## Timing error – late inflation (inflation of IAB markedly after closure of aortic valve)

### Waveform characteristics:

- Inflation of IAB after dicrotic notch
- Absence of sharp "V"
- Sub-optimal diastolic



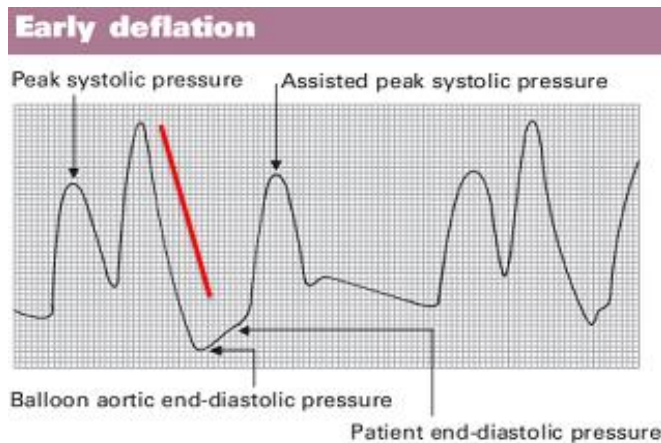
### Physiologic effects:

- Sub-optimal coronary artery perfusion

### Timing error – early deflation (premature deflation of IAB during diastolic phase)

#### Waveform characteristics:

- Deflation of IAB is seen as a sharp drop following diastolic augmentation
- Sub-optimal diastolic augmentation
- Assisted end diastolic pressure may be equal to or less than unassisted end diastolic pressure
- Assisted systolic pressure may rise



### Physiologic effects:

- Sub-optimal coronary perfusion
- Potential for retrograde coronary and carotid blood flow, which may result in angina
- Sub-optimal after load reduction
- Increased  $MVO_2$  demand

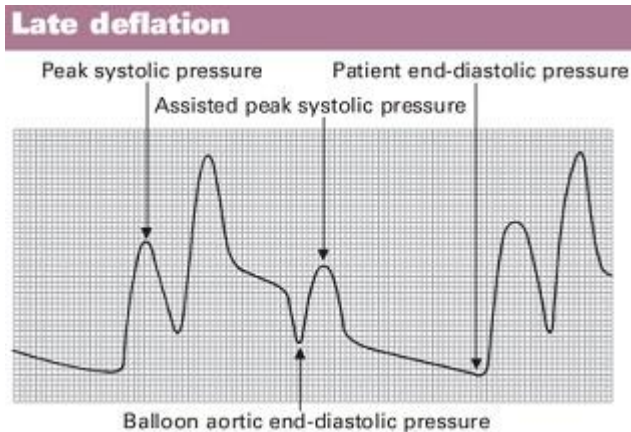
### Timing error – late deflation (deflation of IAB after aortic valve has opened)

#### Waveform characteristics:

- Assisted end diastolic pressure may be equal to or higher than unassisted

## End diastolic pressure

- Rate of rise assisted systole is prolonged
- Diastolic augmentation may appear widened



## Physiologic effect:

- Afterload reduction is essentially absent
- Increased  $MVO_2$  consumption due to left ventricle ejecting against a greater resistance and a prolonged isovolumetric contraction phase
- IAB may impede left ventricular ejection and increase after load

## Precaution during use

1. Patients should be managed in an appropriate area by staff familiar with IABP management.
2. Regularly monitor vital signs and the need for augmentation.
3. Patients should be anticoagulated as per unit protocol unless there is a contraindication.
4. Do not take blood samples from the balloon arterial pressure line.
5. Check for limb pulses at hourly intervals. Presence of limb ischemia should prompt consideration of removal of the device and sheath and urgent vascular surgery review.
6. Perform hourly perfusion assessment of the left upper limb, which may become compromised in the event of proximal migration of the catheter
7. Regularly assess insertion site for oozing, bleeding, swelling and signs of infection.

8. Regularly check haemoglobin (risk of bleeding or haemolysis); platelet count (risk of thrombocytopenia); renal function (risk of acute kidney injury secondary to distal migration of the IABP catheter)
9. The balloon pump must not be left in standby by mode for any longer than 20 minutes in view of high risk device related thrombus formation.
10. Always try to wean off the IABP as early as possible as longer duration is associated with higher incidence of limb complications

## **Complications**

### **1. Limb ischemia**

Limb ischemia requiring IABP removal and that requiring surgical intervention is less than 5%. Related to mechanical obstruction at or above the insertion site. Apparent within a few hours after insertion. Local thrombus may reproduce late ischemia.

### **2. Loss of Limb**

Rare complication, related to prolonged shock, extensive thrombus formation, or cholesterol embolization. Surgical intervention is often ineffective in restoring adequate circulation.

### **3. Arterial Dissection & its complications**

Retrograde dissection, at the time of guidewire advancement. IABP may appear to function normally in the false lumen of the aorta. Severe back pain may be a warning sign.

### **4. Sepsis**

Common when counterpulsation is carried out for longer than 1 week. Prophylactic antibiotics are not given routinely, but they should be administered if there is any compromise in sterile technique.

### **5. Cerebrovascular Accident**

Embolic cerebrovascular accident may occur if the balloon has been placed too proximally or if the central lumen of the balloon has been flushed vigorously to correct thrombus-induced damping of the central arterial pressure.

## **6. Balloon rupture & helium embolization**

Result of equipment malfunction or as a result of heavy calcification of the aorta. Helium is also insoluble in blood, can result in prolonged ischemia or stroke. Ruptured balloon results in thrombus formation within the balloon. Treatment includes hyperbaric oxygen treatment until helium excretion has taken place. Ruptured balloon is usually removed surgically

### **Weaning from IABP**

- Successful weaning from IABP requires the patient to not be in cardiogenic shock and to have an adequate blood pressure whilst on little or no inotropic support.
- Reasonable target values to aim for prior to weaning are a mean arterial pressure of 65 mmHg and, if monitored, a cardiac index of  $e'' 21/ \text{min}/ \text{m}^2$ .
- IABP counterpulsation is usually weaned by reducing the ratio of augmented to non augmented beats.
- This can be done by reducing the augmentation frequency every 1-6 hours, from ratios of 1:1 to 1:2 to 1:3.
- If a ratio of 1:3 is tolerated for 6 hours then the device should be put into standby and removed.
- An alternative weaning method is to decrease the balloon filling volume by 10 ml every 1-6 hours until a filling volume of 20 ml is reached.
- The balloon pump should not be left in situ once switched off as this is associated with a high chance of thrombus formation on the balloon and distal embolization.
- A ratio of 1:3 should also not be used for prolonged periods as this also associated with significant increase in thrombosis risk.

### **Removing the IABP catheter**

7. Consider tapering or discontinuing anticoagulation therapy prior to removal.
8. Stop IABP pumping.
9. Disconnect the IAB catheter from the IAB pump permitting the IAB catheter to vent to atmosphere. Patient blood pressure will collapse the balloon membrane for withdrawal.
10. Remove all securement devices and/or sutures and dressings

11. If an introducer sheath is used: loosen the sheath seal from the hub and withdraw the IAB catheter through the introducer sheath until resistance is met.
12. NEVER attempt to withdraw the balloons membrane through the introducer sheath as a unit
13. Check for adequacy of limb perfusion after hemostasis is achieved.

# **CARDIAC EMERGENCY DRUGS**

<b>DRUG</b>	<b>DOSAGE AND DELIVERY</b>	<b>ACTION AND COMMENTS</b>
Oxygen(O <sub>2</sub> )	2 to 15 L/minute via appropriate device	Maximizes O <sub>2</sub> delivery to cells
<b>Anticoagulants</b>		
Unfractionated heparin (UFH)	50-70 iu/kg IV, followed by small boluses to keep ACT>250 sec or >200sec if a Gp IIb/IIIa inhibitor is given.	Most commonly used thrombin inhibitor Dependant on antithrombin III Stop original clot from expanding and prevent additional clots from forming Small bioavailability
Low molecular weight heparin (LWMH) (Enoxaparin)	1 mg/kg subcutaneously	Combined inhibition of factor IIa and Xa Increased anti-factor Xa activity High bioavailability More consistent anticoagulation
Bivalirudin (Angiomax)	IV bolus of 0.75 mg/kg followed by an infusion of 1.75 mg/kg/ hour.	Direct thrombin inhibitor Does not depend on antithrombin Can inhibit clot bound thrombin Stable anticoagulation level Short acting Dose not cause thrombocytopenia Increased incidence of acute stent thrombosis
<b>Antiplatelet Agents</b>		
Aspirin	160-325 mg tablet	Slows platelet aggregation, reduces further arterial occlusion or reocclusion, and reduces chance of recurrence
<b>II b/IIIa inhibitors</b>		
Tirofiban (Aggrastat)	Acute coronary syndrome 0.4 mcg/kg per min IV for 30 min, then 0.1 mcg/kg per min IV infusion	Antiplatelet drug Tirofiban is indicated to reduce the rate of thrombotic cardiovascular events (combined endpoint of death, myocardial infarction, or refractory ischemia/repeat cardiac procedure) in patients with non-ST elevation acute coronary syndrome (NSTEMI-ACS).

<b>Arrhythmia and Bradycardia</b>		
Atropine sulfate	0.5-1.0 mg IV every 3-5 min as needed	For vasovagal or symptomatic sinus bradycardia Increases the heart rate through anticholinergic effect
<b>Atrial fibrillation or flutter</b>		
Dofetilide	Single infusion of 8mcg/kg over 30 min	For atrial fibrillation and flutter
<b>Supraventricular tachycardia</b>		
Adenosine	6 mg by rapid I.V. push, followed by 10 to 20mL of normal saline solution (NSS) flush; may repeat a 12-mg dose twice, followed by NSS flush	Depresses the sinoatrial and atrioventricular node activity, slowing the heart rate
<b>Ventricular</b>		
Amiodarone	150-mg bolus given I.V. over 10 minutes, followed by continuous I.V. infusion at 1mg/min for 6 hours, then 0.5mg/minute for 18 hours	For ventricular fibrillation
<b>Beta-blockers</b>		
Atenolol, Metoprolol	5 mg IV bolus over 5 minutes; may repeat Atenolol dose once and Metoprolol dose twice	Reduce catecholamins leading to slower heart rate and lower blood pressure
<b>Calcium channel blocker</b>		
Diltiazem	5 to 20 mg by I.V. push over 2 to 5 minutes, followed by I.V. infusion or additional 20 to 25 mg by I.V. push after 15 minutes	Lengthens cardiac cycle, slowing the heart rate

Verapamil	2.5-5.0 mg IV bolus over 2 min. Second dose: 5 mg bolus every 15 min to total dose of 30 mg	Slowing the heart rate
<b>Conscious sedation</b>		
Fentanyl	25-50 mcg intravenously. Repeat as needed every 5 min	Monitor vital sign , oximetry, and state of consciousness as per conscious sedation guidelines
Morphine sulphate	2-4 mg IV (over 1 to 5 min) every 5-30 min	Monitor vital sign , oximetry, and state of consciousness as per conscious sedation guidelines Reduce ventricular preload and cardiac O <sub>2</sub> requirements
<b>Contrast nephropathy</b>		
Hydration	Normal saline 1 ml/kg per hr for 12 hr pre and 12 hr post contrast exposure Alternative normal saline 3 mg/kg over 1 hr preprocedure, then 1 ml/kg per hr 6 hr post-procedure Alternatively sodium bicarbonate (154mEq/L) in D5W	For prevention of contrast induced nephropathy
<b>Diuretic</b>		
Furosemide (Lasix)	IV infusion: 0.5-1.0 mg/kg given over 1 to 2 min If no response, double dose to 2.0 mg/kg, slowly over 1 to 2 min	It is a loop diuretic (water pill) that prevents your body from absorbing too much salt, allowing the salt to instead be passed in your urine.

<b>Inotrope</b>		
Dobutamine (Dobutrex)	IV infusion: Dilute 500 mg (20ml) in 250 ml D5W Usual infusion rate is 2-20 mcg/kg per min	It works by increasing the strength and force of the heartbeat, causing more blood to circulate through the body.
Dopamine	5 to 15 mcg/kg/minute by IV infusion	Stimulates dopamine receptors and increase cardiac output, with increase in minimal oxygen consumption; causes peripheral vasoconstriction
Digoxin	IV infusion: 0.25 mg/ml or 0.1 mg/ml supplied in 1 or 2 ml ampule Loading dose of 10-15 mcg/kg lean body weight –therapeutic effect with minimum toxicity	For rate control in atrial fibrillation and flutter. Maintenance dose is affected by body size and renal function
<b>Pressure agents</b>		
Vasopressine	Dose for cardiac arrest: 40 U IV push *1 Wait for 10 minutes before initiating epinephrine protocol For refractory hypotension: 20 U in 250 ml D5W. Infuse at 0.01-0.10U/min	For cardiac arrest (option to epinephrine) Vasopressin helps prevent loss of water from the body by reducing urine output and helping the kidneys reabsorb water into the body. Vasopressin also raises blood pressure by narrowing blood vessels.
<b>Coronary</b>		
Nitoglycerine	Dilute 200 mcg/ml Administer 100-200 mcg intracoronary	Epicardial vasodilation or treatment of coronary spasm

Adenosine	Dilute 10 mcg/ml For RCA 18-24 mcg through guiding catheter or selectively into distal coronary For LCA 24-36 mcg through guiding catheter or selectively into distal coronary Alternatively, 140-180 mcg /kg per min peripheral intravenous infusion for 3 min	For measurement of fractional flow reserve (FFR)
-----------	--	---

## **COMPLICATIONS IN INTERVENTIONAL PROCEDURES**

### **HEMATOMA**

Bleeding after cardiac catheterization may manifest as a hematoma. Clinically, hematomas present as pain or focal discomfort, discoloration, and bruising, and rarely present as femoral nerve compression with resultant quadriceps weakness. Haemostasis should be achieved with manual pressure or a mechanical compression device before leaving the patient's bedside

### **RETROPERITONEAL HEMATOMA**

A retroperitoneal hematoma is usually associated with arterial puncture above the inguinal ligament. Multiple punctures, and puncture through the posterior wall of the artery, will dramatically increase the risk of bleeding. Since all the bleeding may be internal, the patient often present with unexplained hypotension and tachycardia. While flank pain and bruising may be seen in some patients, an unexplained fall in hematocrit may be the only finding in others.

### **PSEUDOANEURYSM**

A pseudoaneurysm is defined as an arterial wall disruption with resultant extra luminal flow into a chamber contained by adjacent tissue. Arterial endothelium does not comprise the interior of the pseudoaneurysm. The incidence of pseudoaneurysm is between 0.3% to 0.5% of cardiac catheterization. A pseudoaneurysm may manifest as pain, a bruit, a pulsatile mass, an expanding hematoma, and leg weakness. The majority arise from the common femoral artery. Risk factors include multiple arterial punctures, superficial femoral artery puncture, larger sheath size, hypertension, and the use of antithrombotic therapy.

### **ARTERIOVENOUS FISTULA**

Arteriovenous fistulas develop when the needle tract crosses both the femoral artery and vein and is then dilated during sheath insertion. Risk factors include an arterial puncture below the common femoral artery, larger arterial sheath size, older age and prolonged anticoagulation or fibrinolytic therapy. An arteriovenous fistula is clinically characterized by a continuous bruit at the site of catheter insertion. In addition an expanding groin hematoma, decreased or absent lower extremity pulses and a pulsatile mass in the groin may be appreciated. Diagnosis of an AVF confirmed by Doppler ultrasound.

## **CARDIAC TAMPONADE**

Cardiac tamponade may occur after temporary pacemaker placement with an unsuspected perforation of the right ventricle in an anticoagulated patient, or may occur rapidly if there is coronary perforation from guide wire, balloon catheter, or new device manipulation. Tamponade must be identified in patients undergoing coronary angioplasty as an unsuspected cause of hypotension.

## **DEATH**

Death as a complication of diagnostic catheterization has declined progressively over the last 30 years. There has been a progressive reduction in the overall mortality of diagnostic cardiac catheterization; patients with severe left main coronary disease remain at increased risk. Patients with significant left main disease should always begin with careful catheter entry into the left coronary ostium to facilitate early recognition of ostial left main diseases through catheter pressure damping or performance of immediate test.

Patients with cardiogenic shock in the setting of acute myocardial infarction or severe chronic left ventricular dysfunction also have a several fold increased risk of procedural mortality. Interventional procedures tend to carry higher mortality than purely diagnostic catheterizations because they involve the use of more aggressive catheters, super selective cannulation of diseased coronary arteries and brief interruption of coronary or even systemic flow.

## **CEREBROVASCULAR COMPLICATIONS**

Cerebrovascular accidents are uncommon but potentially devastating complications of diagnostic cardiac catheterization. Every invasive cardiologist should be familiar with potential etiologies, preventive strategies, and treatment for catheterization related stroke, and should develop the routine habit of speaking with the patients directly at the end of the procedure. If patient is less alert, has slurred speech, and either visual, sensory, or motor symptoms during or after left heart procedure, there should be a low threshold for performing a screening neurologic exam or obtaining an urgent stroke neurologic consultation.

The risk of stroke is somewhat higher with coronary interventions, as expected based on the use of guiding catheters, multiple equipments exchange in the aortic root, aggressive anticoagulation, and longer procedure times. Although cerebral haemorrhage must always be excluded, the main cause of catheterization related strokes seem to be embolic. So beyond paying careful attention to flushing

and injection technique, there can be no excuse, however for contributory technical malfeasance such as sloppy catheter flushing, introduction of air bubbles during contrast injection.

In addition to aortic root sources, embolic material may also originate in the cardiac chambers, thrombotic coronary arteries, or the surface of cardiac valves. One should thus avoid placing the pigtail catheter fully out to the left ventricular apex in patients with suspected aneurism or recent myocardial infarction, since either condition may be associated with potentially dislodge able mural thrombus.

### **ARRHYTHMIAS**

Various cardiac arrhythmias (tachycardia or bradycardia) or conduction disturbance may occur during the course of diagnostic or therapeutic cardiac catheterization. Most, likely VPCs during catheter entry into the right or left ventricle are devoid of clinical consequence. Others, like asystole or ventricular fibrillation, pose immediate risk. Finally some rhythm disturbances are well tolerated in most patients.

### **VENTRICULAR ARRHYTHMIAS**

Ventricular ectopy or even brief runs of ventricular tachycardia are not uncommon during passage of catheters into the right or left ventricle. Even balloon flotation right heart catheterization may cause such brief runs to ventricular tachycardia or ventricular fibrillation. Ventricular tachycardia and ventricular fibrillation may result from catheter manipulation, the most common is intracoronary injection into the right coronary artery, it can still occur if the contrast injection prolonged or performed with a partially damped catheter pressure.

### **ATRIAL ARRHYTHMIAS**

Atrial extrasystoles are common during catheter advancement from the right atrium to the superior vena cava, or during looping of the catheter in the right atrium to facilitate passage in a patient with enlargement of the right sided heart chambers. These extrasystoles usually subside once the catheter is repositioned, but they may progress to atrial flutter or atrial fibrillation. Atrial flutter or fibrillation are generally benign during catheterization, but may cause clinical sequelae if the ventricular response is rapid or if the atrial kick causes hypotension in a patient with mitral stenosis, hypertrophic cardiomyopathy, or diastolic left ventricular dysfunction.

## **BRADYARRHYTHMIAS**

Transient slowing of the heart rate occurs commonly during coronary angiography, particularly, at the end of a right coronary artery injection performed using a high osmolar ionic contrast agent. Vasovagal reactions, in which bradycardia is associated with hypotension, nausea, yawning, and sweating, should be suspected when bradycardia is more prolonged. Conduction disturbances bundle branch block or complete AV block are an uncommon but potentially serious cause of bradycardia during cardiac catheterization. When complete heart block develops, atropine is rarely helpful in the setting of inadequate junctional escape and hemodynamic deterioration, but should be given anyway, since it has few adverse effects.

## **PERFORATION**

Perforation of the cardiac chambers, coronary arteries, or the intrathoracic great vessels is fortunately a rare event in diagnostic catheterization. Right atrial perforation involved trans-septal catheterization. The right ventricle was the most common site for perforation in the remaining diagnostic procedures, related to the use of stiff catheters. When cardiac perforation does occur, it is usually heralded by bradycardia and hypotension owing to vagal stimulation. In the modern interventional laboratory, however the most common cause of tamponade is perforation or rupture of a coronary artery. Some perforation, particularly those limited to deep injury into the vessel wall with localized perivascular contrast staining, can simply be observed. In contrast, free perforation may lead to the development of frank tamponade within seconds to minute.

Perforation of the great vessels is extremely rare. The aorta is sufficiently elastic to resist perforation, except in the case of weakening by ascending aorta dissection or aneurysm. Aortic puncture may occur, however, during attempted transseptal puncture with too anterior a needle orientation. Ascending aortic dissection can also result from proximal coronary dissection. If the dissection remains localized angiographically, and is confined to the first few centimetres of the aortic root, it can usually be managed medically and will resolve within weeks.

Rupture of the pulmonary artery is also rare, but care must be taken not to use stiff tip guidewires in these thinner walled vessels. Perforation of the branch pulmonary arteries has been reported when balloon floatation catheters are inflated while positioned in a distal branch.

## **INFECTION AND PYROGEN REACTIONS**

Cardiac catheterization is an inherently sterile procedure, infection is extremely unusual. Recommended technique includes shaving and cleaning the catheter introduction site with Providone- iodine, use of a nonporous drape, and adequate operator clothing. When performing a repeat procedure within 2 weeks of an initial diagnostic procedure, the contralateral groin should be used since an increased infection rate has been reported with early reuse of the same groin site. Full sterile precautions are also strongly recommended for the femoral approach when the procedure is prolonged, when the sheath will remain in place for any period, when a stent or permanent pacemaker being implanted, or when a vascular graft is punctured.

## **ALLERGIC AND ANAPHYLACTOID REACTIONS**

Cardiac catheterization may precipitate allergic or anaphylactoid reactions to three materials: (a) local anaesthetic, (b) iodinated contrast agent, or (c) protamine sulphate. True allergies to local anesthetic do occur, but are more common with older ester agents than with newer amide agents. The most common allergic reactions are triggered by iodinated contrast agents, reaction to protamine sulphate, a biologic product derived from salmon eggs, can also occur. Another allergic reaction that should be considered- even though it is rarely seen in the cardiac catheterization laboratory is heparin induced thrombocytopenia.

## **RENAL DYSFUNCTION**

Temporary or permanent renal dysfunction is a serious potential complication of cardiac angiography. The potential mechanism of contrast-induced nephropathy includes vasomotor instability, increased glomerular permeability to protein, direct tubular obstruction. The main defence against contrast induced nephropathy is limitation of total contrast volume. In patients with reduced renal function and especially with diabetes, extra attention must be paid to limiting unnecessary angiographic views and multiple contrast puffs during interventional wire and device placement. Another cause of renal failure following cardiac catheterization is systemic cholesterol embolization.

## **HYPOTENSION**

Reduction in arterial blood pressure is one of the most common problems seen during catheterization. This reduction represents the final common

manifestation of variety of conditions including the following: hypovolemia, owing to inadequate prehydration, blood loss, or excessive contrast –induced diuresis, reduction in cardiac output, owing to ischemia, tamponade, arrhythmia, or valvular regurgitation, inappropriate systemic arteriolar vasodilation, owing to vasovagal, excessive nitrate administration or a vasodilator drugs such as dopamine or dobutamine.

### **VOLUME OVERLOAD**

Patients in the cardiac catheterization laboratory are prone to volume overload owing to the administration of hypertonic contrast agents, myocardial depression or ischemia induced by contrast, poor baseline left ventricular function, as well as their supine position an attempts to volume load patients at risk for contrast induced renal dysfunction.

### **CORONARY DISSECTION**

The most common cause of prolonged ischemia during angioplasty is coronary dissection. Although coronary dissection may be detected by characteristic angiographic imaging, at times, the dissection cannot be differentiated from thrombus formation. Classification of coronary artery dissection followed the national heart blood and lung institute system A-F, where type A is minor radiolucencies within the coronary lumen due to contrast injection with no persistence of dye; type B is a parallel track or double or double lumen impression of radiolucent area during contrast injection with no persistence, type C is extra luminal cap with persistence of contrast after coronary angiography , type D is spiral luminal filling defects in multiple areas of the vessel that persist, and type F is type A-E dissection that lead to impaired flow or abrupt closure.

### **INTRACORONARY THROMBUS**

Presumed intracoronary thrombus is also treated with prolonged balloon inflations and frequently intracoronary thrombolytics. It should be noted , however that routine use of intracoronary thrombolytics has not been found to reduce and may potentially increase, the risk of ischemic events.

### **CORONARY ARTERY EMBOLISM**

Occasionally coronary air embolisms will occur in the performance of procedure catheter exchange, balloon extraction and reinsertion. Air embolism may occur under the following conditions:

- Incomplete aspiration of guiding catheter upon introduction into the circulation
- Balloon leakage or rupture
- Prolonged negative suction of self venting balloon catheters when exposed to room air
- Introduction of balloon catheters into the guide
- Removal of balloon catheters from deeply seated guiding catheter
- Structural failure of catheter
- Injection of air due to bubble in contrast injection line and or syringe
- Vacuum air accumulation on use of tracker exchange system.

### **GUIDE CATHETER OBSTRUCTION**

Ischemia due to guide catheter ostial occlusion is treated by removal of the guide catheter or use of a catheter with side holes. Balloon catheters with relatively larger shaft sizes may create ischemia when they are inserted into relatively smaller arteries. This ischemia persists despite the balloon deflation. The solution is to remove the balloon into the guiding catheter after each inflation.

### **CORONARY SPASM**

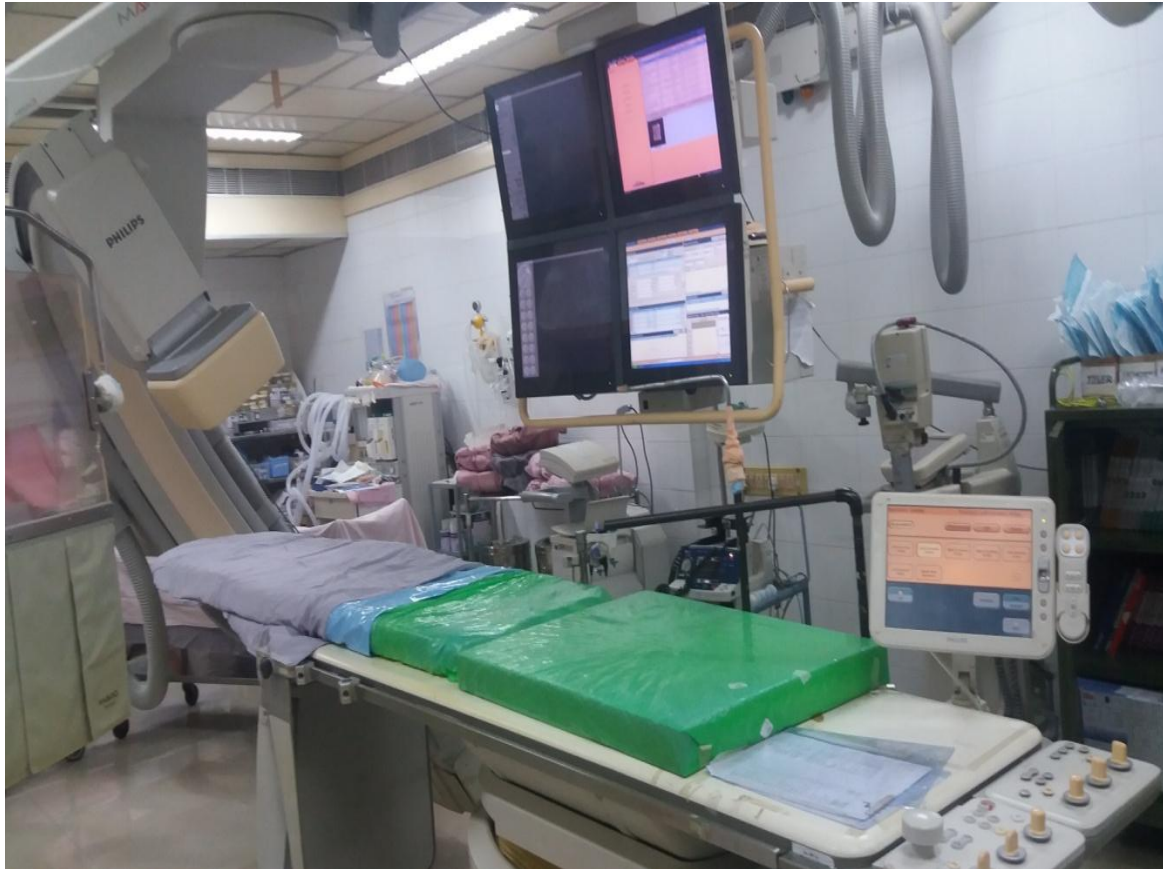Coronary vasospasm occurs frequently during angioplasty, and intracoronary nitroglycerin can readily reverse vasospastic tendencies. Some patients may require continuous intravenous nitroglycerin to remove this potentially complicating factor. Coronary vasospasm should be suspected in every case of reduced flow and excluded by the administration of intracoronary nitroglycerin.

### **CATHETER KINKING**

Catheter rotation during a transradial procedure is much more difficult to perform than via the femoral approach because of the friction generated by the size of the vessel. Catheter advancement around loops and in calcified segments must be monitored (the tip must rotate with the rest of the catheter!) by x-ray and pressure measurement. Indeed, catheter kinking, which can also occur via the transfemoral approach, may have worse consequences. The catheter must not be withdrawn before being straightened up by rotating it in the opposite direction and by inserting a hydrophilic wire which should be advanced in a larger artery.

# **DEPARTMENTAL EQUIPMENTS**

## PHILIPS ALLURA XPER FD 10



The Allura Xper FD10/10 combines exceptional speed and performance of the geometry with superb flat detector image quality. Whether your focus is Interventional Cardiology, Paediatric Cardiology or Electrophysiology (EP), Philips has developed special features and protocols for the Allura Xper FD10/10. Bi-plane viewing power and safety The Allura Xper FD10/10 brings flat detector technology to biplane viewing. This system delivers superb image quality in both the frontal and lateral plane, enabling cardiologists to view them side-by-side. The Allura XperFD10/10 saves valuable time when capturing accurate 3D information while also reducing x-ray dose and contrast medium.

- **DYNAMIC FLAT DETECTOR:** Philips' 14-bit virtually distortion-free dynamic flat detector offers 184 micron pixels for higher resolution and a DQE(O) of 75% that provides better image quality, especially for low dose fluoroscopy. The compact design with a very large field of view of 25 cm (10 in.) is the optimal size for dedicated cardiology and EP applications. It also offers a refresh light

that provides temporal virtually artefact-free imaging by “blinking” the detector, thereby eliminating image glow during dynamic studies.

- **G SHAPED GANTRY:** The compact, motorized, floor-mounted G-arm provides excellent patient accessibility from all sides. The large diameter of the G-arm allows virtually all cardiac Projections, even with obese patients. Two projection scan can be stored and recalled for faster positioning.
- **XPER TABLE:** The Xper table is a dedicated cardiovascular table with a free floating tabletop. This table has very high patient loadability and can make a large longitudinal floating movement.
- **PAN HANDLE:** The PAN handle is a tabletop float control extension, which can be attached to any side of the table.
- **ACQUISITION:** The acquisition page contains information on the current selected patient. The page shows a full overview of all acquired runs and allows you to do QA. The history file of the patient can be reviewed at the touch of a button.
- **ARCHIVE:** Clinical studies can be transferred to an optional Xcelera DICOM Recorder (IDR) or to a PACS, like the Xcelera PACS. The archive process - including multiple destinations, archive formats, and background transfer can be completely automated
- **DSA:** The Digital Subtraction Angiography (DSA) option extends the vascular applicational functionality of the Allura Xper system. DSA features real-time digital subtraction at low frame speeds of 0.5, 1, 2, 3, or 6 frames per second. The DSA programs can be selected via the Xper settings.
- **FLUOROSCOPY:** Three fluoro modes are available at table side and these can be programmed via Xper settings. Each mode can be programmed with different composition of X-ray dose rate, digital processing, and filter settings.
- **X GENERATOR:** X-ray generation consists of the following elements: Xray generator, X-ray tube, collimator (including Spectra Beam, Beam filtration), and dose protection mechanism. The complete dose protection mechanism is part of the Dose Wise program.
- **MONITORS:** The system is delivered standard with four black and white 18-inch LCD monitors in the examination room. One 19-inch LCD color monitor and two 18-inch black and white LCD monitors are standard in the control room.
- **STENT BOOST:** Stent Boost is a simple, quick, and cost-effective tool to enhance visualization of stents in the coronary arteries. It shows the stent in relation to the vessel wall. Stent Boost uses markers on the balloon or stent delivery. Catheter to better visualize objects in the direct environment of the markers<sup>1</sup>.

## **PHILIPS INTEGRIS H 5000 F**

The floor mounted monoplane integris H 5000 F is the dedicated system of cardiac procedures. It brings excellent digital imaging performance to cardiac suit. The larger diameter of the polydiagnost G stand and patient sensing of bodyguard allow high rotation and angulations speeds of up 25 degree per sec. New fully integrated, all digital imaging chain is based on CCD technology optimized for complex cardiovascular applications. It provides high speed, high resolution imaging with true 1024 matrix.

### **X RAY GENERATORS**

Microprocessors controlled 100 kW high frequency converter generator

Voltage range: 40 kV to 150 kV

Max current : 1000mA at 100kV, 800 mA at 125 kV

X ray tube : MRC 0508

Power : 0.5/0.8, 45/85kW

Anode heat storage capacity: 2400kHU anode

Continues heat dissipation : 5300W

TV chain XTV 60, CCD camera with proprietary digital output


Light intensity : 30000 lux

Focusable light field size : 14 – 25 cm

Digital acquisition

Frame speed (frame per second) at 512\*512 image resolution.

## SIEMENS AXIOM ARTIS CATHLAB SPECIFICATIONS



### FEATURES

- Floor-mounted C-arm stand with flexible positioning options and fast programmable movements
- Compact and slim line C-arm design
- Dyna vision rotational angio feasibility
- Catheter table with free-floating tabletop, optionally with tilt and motorized table stepping
- In the examination room: Complete ergonomic system control in the examination room with integrated generator and imaging system control on a color touch-screen interface
- syngo operation in the control room using mouse and keyboard, and color or black and white flat display monitors
- Full-size CCD camera system
- Pulsed fluoroscopy is standard on all basic systems
- Expanded CARE applications for maximum radiation protection

- Full DICOM functionality for patient data acquisition as well as for documentation and archiving
- Integration of Siemens cath lab information and recording system
- Axiom senses hemodynamic system
- High-frequency generator with automatic dose-rate control
- Choice of dual or triple-focus high-performance liquid-bearing or ball bearing **X-ray tube**
- Single joystick for all patient-angle oriented C-arm and I.I. movements

#### **IMAGE PROCESSING:**

- Modes range from single frame to series display with frame rates from 0.5 up to 60 frames/second.
- Pulsed fluoroscopy standard
- Integration with CATHCOR LX cath lab information and recording system.
- Storing for fluoroscopic images also during fluoroscopy.

#### **MONITORS:**

- TWO ceiling suspended: high resolution digital CCD.

#### **GENERATOR:**

- High frequency with integrated, fully automatic dose rate control.
- 100 kW at 100 kV
- SID tracking

#### **TABLE TYPE:**

- Carbon fiber floor-mounted catheter table with free-moving tabletop; no tilt.
- Narrow with recess at head end.

- Rotation +/- 120 degrees.
- Maximum patient weight 100kg.

## **OTHER FEATURES**

- Integration with CATHCOR LX cath lab information and recording system.
- CD recorder.
- DICOM print.
- UPS for imaging system.
- Intercom.

## **BARD EP PRO**

The lab system Pro EP recording System is performance- driven software has deliver increased flexibility for data review and export. Patient review Mode provides significant improvements to work flow management by allowing the physician or nurse the clinical lab system PRO EP recording system as a workstation for case review, study annotation, and report generation.

New CLEARSIGN Amplifier delivers excellent signal quality with unique adaptive noise filtering and up to 160 intracardiac channels. The new report generator seamlessly creates an informative patient record by automatically capturing user- defined study log information into a customizable template. Waveform and fluoroscopy images can also be included to deliver the most complete picture of the patient's diagnosis and treatment. New advanced patient data archiving offers increased archiving confidence with improved status updates and data verification.

The lab system PRO review workstation delivers EP study data. The EP Review Workstations puts the capabilities of the recording system at your finger tips and allows access to your EP study data from any location, in or out of the lab. New CLEARSIGN Amplifier delivers excellent signal quality and intuitive design for improved efficiency and accuracy during your EP procedure.

- Best in class Waveform output and display
- Superior signal clarity
- High resolution 13- bit A/D converter
- Exceptional signal processing
- Unparalleled Noise rejection
- Channel RF energy filters
- Unique adaptive noise filters
- Notch filters at both 50 and 60Hz
- Up to 160 Bipolar IC channels
- Map larger areas in the endocardium
- Flexibility for future technology

EP link interface provides the integration solution for the EP Lab. Now the whole patients care team can access EP study results in the same way that other patient information is available from hospital's control information system (H.I.S).

A seamless bidirectional HL 7 interface, EP link package imports patient demographic, work order, and ADT information prior to EP study initiation and exports EP results at the conclusion of the study. The open architecture design accommodates a variety of software configurations, including commercial and custom designed systems.

## **CS300 IABP WITH INTELLISENSE**

The New CS300 with IntelliSense combines fibre-optic speed with automatic in vivo calibration. The result is faster time to therapy, faster signal acquisition, and faster adaptation to rate and rhythm changes.

### **Faster Time to Therapy**

- Faster inflation and deflation speed
- CS300 has true one-button start-up
- Automatically calibrates the fibre-optic pressure sensor in the patient and recalibrates every 2 hours or sooner should patient or environmental conditions change
- Automatically evaluates and selects the best lead and trigger source

- Automatically sets optimal timing
- Automatically adjusts to changes in patient conditions without clinician intervention

The CS300 Can Be Used With:

- The SENSATION 7Fr. fibre-optic IAB catheter
- Conventional fluid-filled IAB catheters
- Paediatric IAB catheters

Fibre-optic pressure signal transmission to a patient monitor: An electrically isolated, low-level pressure output from the CS300 enables clinicians to send the fibre-optic arterial pressure waveform directly to a patient monitor by simply attaching an appropriate cable.

Unique automatic in vivo calibration: MAQUET has the ONLY fibre-optic IABP and catheter system that automatically calibrates in the patient after insertion and automatically recalibrates in vivo every 2 hours or sooner should patient or environmental conditions change.

## **ST. JUDE ILUMIEN OCT SYSTEM**

ILUMIEN System - Physician Side

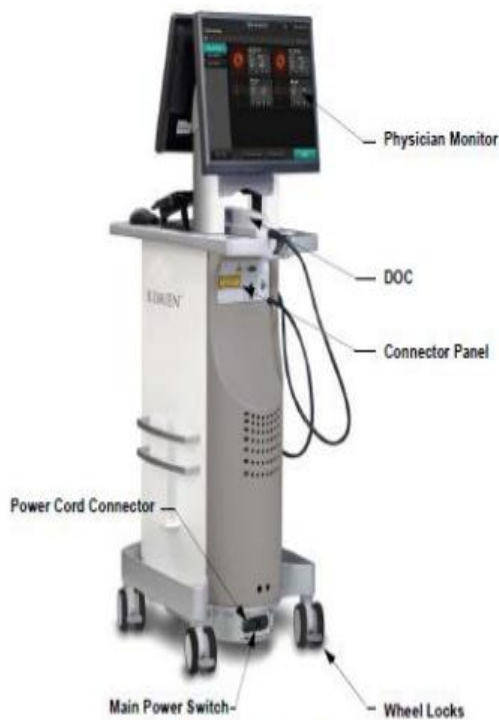

Figure 1-1: ILUMIEN System - Physician Side

ILUMIEN System - Operator Side



The basic principles of OCT consist of a single mode optic fiber that transmits and receives infrared light waves at a bandwidth of 1250-1350 nm which is the ideal spectral range for imaging biologic tissue. The OCT started as a research tool it is graduating to become an important clinical tool particularly to view the edoluminal structure of the blood vessels. The present OCT system that is available in India is from St Jude Medical.

ILUMIEN Therapy Guidance System is intended for the imaging of coronary arteries and is indicated in patients who are candidates for tansluminal interventional procedures. ILUMIEN System will further acquire radio frequency signal outputs from both a distal intracoronary pressure transducer and a proximal aortic pressure transducer to determine the physiological parameter, Fractional Flow Reserve (FFR). The physician may use the FFR parameter, along with knowledge of patient history, medical expertise and clinical judgment to determine if therapeutic intervention is indicated.

## **PRODUCT BENEFITS**

- Combine the functional and anatomical modalities of Fractional Flow Reserve (FFR) and Optical Coherence Tomography (OCT)
- Move between FFR and OCT modalities with one touch
- Wireless FFR setup in one or multiple labs
- Easy on-screen guide simplifies Ilumien FFR and OCT procedures with a new seamless user interface
- The flexibility and cost efficiency of a mobile unit
- Integrated case storage and easy patient ID retrieval
- Ability to perform FFR measurements with optional wireless Wi-Box™, PressureWire Aeries and cables

## **GENERAL PRODUCT INFORMATION**

The compact, mobile console contains all the working elements of the Ilumien Therapy Guidance System, including:

- Ilumien proprietary imaging engine, custom PC software and wireless receivers to perform FFR measurements
- Two monitors (17" and 19") plus remote video output for multiple sightlines
- Keyboard or mouse click control of system and catheter
- 22x CD/DVD±RW dual layer DVD-RAM drive for faster image management
- Large hard drive for ample data storage

- Integrated drive-motor and optical controller (DOC)

## TECHNICAL SPECIFICATION

- **Ilumien:** Size mm/in: 1430 (h) x 471 (w) x 683 (d)/56.3 (h) x 18.5 (w) x 27 (d)
- **Dragonfly** Usable length: 135 cm ,Outer diameter: 2.7 F (distal), Wire lumen: 0.014”
- **PressureWire Aeris:** Operating pressure: -30 to +300mmHg Accuracy:  $\pm 1$  mmHg plus  $\pm 1\%$  of reading (-30 to 50mmHg)  $\pm 3\%$  of reading (50 to 300mmHg)
- **AO pressure via Wi-Box to Ilumien:** Operating pressure: -30 to +300mmHg Accuracy:  $\pm 1$  mmHg or  $\pm 1\%$  of reading whichever greatest
- **AO pressure via Wi-Box to hemodynamic recording system:** Direct galvanic connection Max Pressure shift: <2mmHg
- **Radio specification:** Frequency range: 2.4000-2.4835GHz Type: Frequency hopping spread spectrum (FHSS) Range: 0-4m Delay time: <20ms

## IMAGING PARAMETRES

- Maximum frame rate: 100 fps
- Nominal pullback speed: 20 mm/sec
- # of lines per frame: 500
- Scan diameter: 10 mm
- Axial resolution: 15  $\mu$ m

## IVUS – VOLCANO

Volcano Corporation develops, designed to facilitate endovascular procedures, and enhances the diagnosis of vascular and structural heart disease and guide optimal therapies.

The intravascular ultrasound (IVUS) product line includes ultrasound consoles that can be integrated directly into virtually any modern cath lab single use disposable imaging catheters unique to system. IVUS offerings are used by clinicians to measure the stage and severity of disease present in cardiac and peripheral vessels. IVUS is also used post-stent placement procedures to confirm adequate expansion of the stent and full opposition to the vessel wall. Volcano IVUS offers unique features, including both phased array and rotational IVUS



imaging catheters and advanced functionality options, such as IVUS tissue characterization technology.

### **FEATURES ARE:**

- Automated border rendering: automatically generate borders and measurements in grayscale or VH mode to highlight lumen and vessel boundaries
- Advanced border editing tools: additional border editing tools allow for free draw adjustments or placements of dots to mark desired border location
- Automatic Measurements: automatically calculated key documentation endpoints including MLD, CSA, and plaque burden
- VH IVUS: proprietary plaque composition technology can be seen on cross-section and longitudinal views
- Target assist: quickly identifies IVUS frame with most severe narrowing and automatically displays lesion length
- Rapid Review: cine animation of consecutive static frames for improved image interpretation, newly enhanced to allow concurrent border rendering and measurement during playback
- ChromaFlo: proprietary blood motion technology highlights flow in orange to assist in conforming proper stent apposition and stent CSA
- Digital Archiving & DICOM Service: supports offline archiving to local hard drive, to DVD and to DICOM network via DICOM store. Also supports DICOM work list management
- Expanded settings options

Powerful new settings options allows you to customize your s5 configurations to accelerate and simplify your network.

### **RADI-ANALYZER**

Radi-analyzer enables fast easy and accurate physiological measurements for clinical decision making as well as advanced research. Physiological assessment using Fractional Flow Reserve is a clinically proven and cost effective solution for determining the functional degree and location of stenosis. The pressure wire sensor offers superior handling characteristics and reliable and stable signal performance, providing the physician with more ease of use and decision making opportunities in coronary assessment and fractional flow reserve procedures

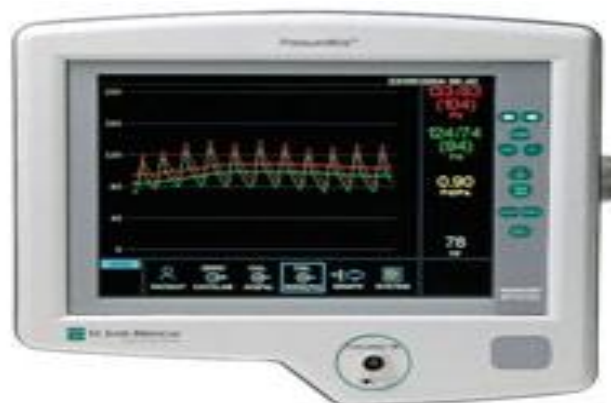## **THE FEATURES OF RADI ANALYZER**

- Real time calculation of myocardial fractional flow reserve (FFR<sub>myo</sub>)
- Automatic equalization of pressure wire sensor and guide catheter pressures
- Simultaneous display of both phasic and mean pressure curves
- Easy to read multifunction display with remote touch pad control
- Mount easily to standard IV pole
- RADI Analyzer thermo option upgrade kit offers the possibility to obtain temperature measurements and CFR measurements.
- Measurement of FFR, temperature and CFR can be made using one single pressure wire sensor
- The CFR measurement is based on the thermodilution principle. The user is guided by step by step through on screen instructions and a highly automated measurement system

## **RADI VIEW**

- Digital transfer and storage of RADI Analyzer- recording
- Review, examine and edit stored recording on local PC or through network
- Export recording in spreadsheet or image format
- Create presentation in Microsoft power point
- Print RADI Analyzer recordings directly from your PC

## **QUANTIEN WIRELESS FFR**



The QUANTIEN integrated FFR solution gives you a wireless patient environment, removing the clutter of cables and clearing the table for what's most important the.

Patient ID is quickly loaded from your hospital scheduling system, and the results are exported back to your archive, all with a minimum of manual interaction.

Place the QUANTIEN main unit anywhere in the lab, freeing up valuable table space and allowing control by either sterile or nonsterile-dressed staff. Regardless of where you chose to place QUANTIEN, its video screen can be displayed on existing lab monitors for convenient viewing right next to your angiography and hemodynamic screens. Integrating QUANTIEN into your cath lab environment is quick and easy — no need to install cables through the floor or ceiling. QUANTIEN lets you go wireless without taking down the lab.

## **SECURE WIRELESS**

Fast, robust and secure wireless communication using advanced radio technology from St. Jude Medical. Well proven in cath labs around the world. The Quantien integrated FFR platform is compatible with Pressure Wire Certus™ and Pressure Wire Aeris from St. Jude Medical.

## **VOLCANO S5 SYSTEM**

- FFR onscreen command facilitates quick transition between modes
- Automatic patient data integration to FFR
- Simple user interface promotes easy workflow
- Uniform FFR controls on s5 simplifies operation
- Green button workflow guides operator
- Bookmark regions of interest for future analysis
- Quickly zoom in on regions of interest with new trend chart feature
- Record and play back cases or save screen shots on systems with available USB drives

## **AUTOMATIC PRESSURE INJECTORS**

The automatic pressure injectors most commonly used today allows for specific volume of contrast to safely be delivered at a precise flow rate.

## **ANGIOMATE ILLUMINA**

- **DIGITAL POWER HEAD DISPLAY:** The LED display automatically “flips” as the power head is rotated ensuring proper orientation for viewing. Indicates programmed protocol and volume remaining in the syringe.

- **FILL CONTROL BAR:** Allows easy, one finger operation. Speed control of ram for Syringe filling, pull-back, or infusion.
- **SYRINGES:** The latex free and transparent syringes provide a crystal clear view of the contrast medium. Compatible with pre-filled syringes.
- **AIR DETECTION DEVICE:** The optional Air Detection and Warning System (ADAWS) detects empty syringes and air bolus.
- **TOUCH SCREEN:** The pressure sensitive touch screen display makes the injection setup direct and easy. Protocol manager to store and recall user defined protocols.
- **MULTIMODALITY:** With just a touch of a button the injector switches between Angio and CT modes.

## **ANGIOMAT 6000**

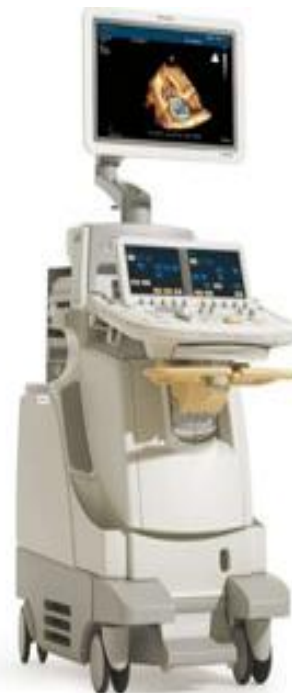- Volume range: 0.1 ml to 9.9 ml in 0.1 ml increment and 1 ml to 150 ml in 1 ml increment
- Flow rate range : 0.01 ml – 40 ml/ sec increment
- Duration range : 0 – 10/255 sec in 0.01 sec increment
- Pressure limit : 127 – 1200 psi in 1 psi increment

## **IE 33 X MATRIX ECHOCARDIOGRAPHY SYSTEM**

Combining unprecedented 2D and 3D image quality in the same transducer and a host of easy-to-use quantification, clinical performance, and information management tools, the new iE33 xMATRIX echo system addresses the clinical needs of managing patients with cardiac disease, including heart failure, valvular disease, and congenital heart disease.

### **X5-1 xMATRIX ARRAY**

The X5-1 transducer helps remove the barriers to 3D imaging, giving clinicians the power to choose 2D, 3D or combination imaging without disrupting workflow. Combining Xmatrix array technology with PureWave crystal technology for consistently excellent image quality, the X5-1 supports 3D, 2D, color flow, M-mode, PW/CW Doppler, Tissue Doppler imaging and contrast-enhanced exams.



- 3,040 elements with microbeamforming
- 1 to 5 MHz extended operating frequency range
- 2D, Live 3D volume, high volume rate (HVR), one-beat, two-beat and four-beat Live volume, color flow, Live 3D color, PW/CW Doppler, M-mode, color M-mode, contrast, Tissue Doppler imaging, Live xPlane imaging
- iRotate – Electronically rotatable scan angle from 0 to 180 degrees
- Adult, contrast LVO, pediatric CHD, cardiology coronary
- Ergonomic design for reduced user fatigue
- Solid state reliability and no complex liquid cooling required
- Philips green label approved transducer
- Dimensions: 9.2 x 3.9 x 2.9 cm (3.6 x1.5 x 1.1 in) LWD

## **LIVE 3D TEE TRANSDUCER**

On the EPIQ 7, iE33 xMATRIX and CX50 xMATRIX systems, the X7-2t transducer combines xMATRIX array and PureWave crystal technologies in a fully functional TEE probe for exceptional Live 3D Echo performance during transesophageal exams and interventional procedures.

- 2D and 3D matrix array
- 7 to 2 MHz extended operating frequency range
- 2D, color flow, PW Doppler, CW Doppler, M-mode, Live xPlane imaging, Live 3D Echo, Live 3D zoom, advanced XRES, triggered full volume, triggered 3D color
- Harmonic imaging
- Dynamic elevational focusing
- Electrocautery suppression
- Electronic rotatable array from 0 to 180 degrees
- TEE applications for patients >30 kg/66 lb

## **2D TEE TRANSDUCER**

On the EPIQ 5, CX50 and Sparq systems, the X7-2t transducer combines xMATRIX and PureWave crystal technologies in a TEE probe for remarkable 2D transesophageal imaging.

- 2D matrix array
- 7 to 2 MHz extended operating frequency range
- 2D, color flow, PW Doppler, CW Doppler, M-mode, advanced XRES
- Harmonic imaging
- Dynamic elevational focusing
- Electrocautery suppression
- Electronic rotatable array from 0 to 180 degrees

- TEE applications for patients >30 kg/66 lb

An optional transducer adapter is available for purchase that enables the CX50 and Sparq X7-2t transducer to be used in both 2D and 3D modes on an iE33 system.

## **HD 15 PURE WAVE ULTRASOUND SYSTEM**

Philips exclusive PureWave crystal technology is clinically proven to improve penetration in difficult-to-image patients. PureWave crystals are the result of a manufacturing technique that creates a near-perfect atomic level arrangement. The uniformity and lack of grain boundaries help transfer energy with up to 85% greater precision and efficiency over conventional materials. Their extended bandwidth covers the frequency range of two transducers, with improved Doppler performance and highly sensitive harmonic imaging. PureWave crystals have virtually perfect uniformity for greater bandwidth and twice the efficiency of conventional ceramic materials. The result is excellent imaging and Doppler performance.

### **SOPHISTICATED TECHNOLOGIES.SIMPLE TO US**

For advanced imaging and greater diagnostic confidence, rapid 3D volume renditions and dynamic 4D displays are presented with incredible clarity and detail resolution. This is a result of the HD15's next generation architecture with new high resolution analog to- digital conversion (A/D) technology and 4X parallel processing, leading to incredible contrast resolution as well as outstanding frame rates and 4D volume rates. For superb image sharpness and uniformity, Microfine EX focusing provides dynamic receive lens tuning with five times more focal points than previous generation systems. For images with less noise and fewer artifacts, SonoCT is true real-time compound imaging that merges up to nine lines of sight to create one amazing image with better clarity of curved and irregular borders. To attain extraordinary clarity and edge definition advanced XRES adaptive image processing uses proprietary algorithms originally developed for Philips MR to display images that are essentially free from noise, without reducing frame rates. To quickly achieve optimal image quality in 2D, color and Doppler exams, Iscan image optimization is a one-button push that automatically adjusts.

### **PHILIPS HD 15 FEATURES**

- New high resolution A/D technology
- 4 times Parallel Processing
- Microfine EX focusing
- SonoCT real-time compound imaging

- Advanced XRES adaptive image processing
- PureWave crystal technology

## **PHILIPS CLEARVUE 350**

The refurbished Philips ClearVue 350 is an entry-level shared service ultrasound machine that replaces the Philips HD6 and HD7 ultrasound machines. It's easy to use, very compact and lightweight, and has excellent image quality considering its size and price range.

The used ClearVue 350 shared service ultrasound machine is lightweight with a small foot print, it has a good price, and is easy to use. The 17" LCD flat screen shows very high resolution and the transducers are lightweight and ergonomically friendly.

Philips did a complete redesign when it replaced the Philips "HD series" with the ClearVue series of ultrasounds. Although it has a limited selection of transducers and features, the image quality of a used ClearVue 350 is excellent and it remains a versatile ultrasound machine with its broadband probes. Its basic design shouldn't sway you from thinking it's a very basic underperforming ultrasound machine. The ClearVue 350 is a very good shared service ultrasound machine.

### ***PHILIPS CLEARVUE 350 FEATURES***

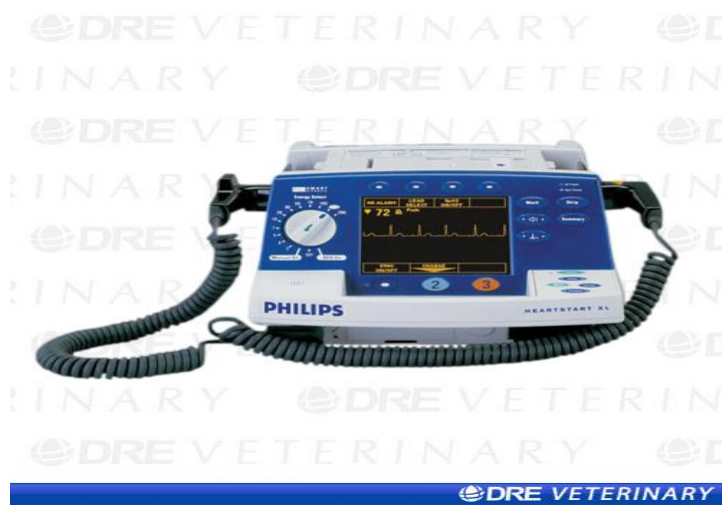- Simplified Interface
- Lightweight transducers
- Tissue Harmonics
- 2D, M-Mode, Anatomical M-Mode
- Trapezoidal Imaging
- PW/Color/Power Angio Doppler
- HPRF PW Doppler
- 3 USB Ports
- internal Hard Drive
- CW Doppler Option
- Duplex, Triplex

## **MORTARA XSCRIBE 5( STRESS EXERCISE TESTING SYSTEM)**

This X scribe cardiac stress exercise system performs and documents four phases of a patient exercise test. These phases consist of pre exercise test, exercise, recovery and final report.

- **Wireless ECG Acquisition and Transmission:** The optional X12+™ digitally transmits diagnostic-quality, 12-lead ECG data providing comfort and freedom of movement for the patient.
- **Advanced VERITAS™ Signal Processing:** Mortara's VERITAS signal processing algorithms provide exceptional accuracy in beat detection and noise rejection resulting in superior identification of events.
- **Comprehensive Presentation of Clinical Data:** In addition to continuous ST trends, the XScribe™ 5 stress exercise testing system presents ST level and slope for all 12 average complexes, an ST Profile, and auto comparison with reference complexes on a 24-inch wide-screen display.
- **Unique Source Consistency Filter :** Mortara's patented Source Consistency Filter reduces noise and baseline artefact while preserving a diagnostic-quality ECG signal.
- **Powerful Beat-By-Beat Review Mode:** Full disclosure review during the exam and post-test allow retrospective addition of events and ECG printing ensures that no critical moment is ever missed.
- **Report Export and Network Options:** Highly customizable final report in non-proprietary PDF, XML, or DICOM format can be manually or automatically exported to any networked destination.
- **HL7 (Health Level 7) and DICOM Bidirectional Interfaces:** Automatically download HIS patient demographics and orders, export status and billing messages, and generate reports utilizing the XScribe 5 worklist.
- **Scalable Solution:** XScribe 5 enables flexible system configurations to satisfy a full range of stress testing needs from standalone to complex. A single system or multiple XScribe 5 workstations can schedule patients, conduct stress exams, review, and generate results within a shared database.

## PHILIPS HEART START XL BIPHASIC DEFIBRILLATOR WITH ECG MONITORING



- Fast charging. Goes from 0 to 360 joules in under 5 seconds
- Battery Indicator. Low battery LED message lets you know when battery is running
- Back up AC power. Can be plugged into a standard AC wall socket.
- True 1-2-3 operation
- Event summary. Documents and stored up to 28 events, plus even stores data after the unit is turned off
- Shock advisory option. Lets you know whether a rhythm is shockable or not and guides you through the process of defibrillation
- Advisory event summary. Included with shock advisory, this features documents and stores up to 50 ECG strips and 200 events in shock advisory mode
- Large CRT display. User friendly messages and monitoring information appear on a bright 5 inch screen
- Leads off indicator, paddle contact indicator
- Uncluttered front panel
- Monitoring, an ECG bedside monitor when a separate unit isn't available
- Annotating recorder, Hands free defibrillation
- Built in pacing option, Integrated pulse oximinator option
- Autogain , adjustable heart rate alarms
- Easy loading thermal array recorder

- Built in pediatric paddles and internal paddles.
- 5 wire ECG option
- Light weight

## **GE MAC 500 PORTABLE ECG MACHINE**

Portable 12 lead electrocardiograph, designed for acquisition, with or without analysis. For those facilities needing minimal ECG requirements.

### **SPECIFICATIONS**

- **Dimensions:** Size: 290 x 80 x 200 (width x height x depth in mm).Weight: 2 kg Including battery
- **Power Supply:** From main or built-in battery lead-acid 12 V, 1.2 A hr
- **Languages:** There are 17 operational languages (German, English, French, Italian, Spanish, Swedish, Norwegian, Danish, Dutch, Czech, Finnish Hungarian, Macedonian, Bulgarian, Polish, Portuguese, and Russian)
- **Recording :**Thermal dot printer process, writing width 80 mm
- **Paper:** Paper width 90 mm
- **Paper speed:** 5-25-50 mm/s
- **Display :**Alphanumeric LCD 2 x 16 characters; Adjustable display contrast Zeroing; Automatic setting in the optimal recording range Anti-Drift- System
- **Electrode check:** Audible indicator and display on LCD; monitoring of individual electrodes Heart rate
- **Display:** Range 30-300 beats/min
- **Heart rate control:** Definable upper and lower limits; alarm when outside defined range
- **Mains operation:** Battery charging from built-in charger Voltage independent mains Operation /universal power supply; nominal input range: 100...240 V, 49...65 Hz

## **MORTARA ELI 250**

The Mortara ELI 250 ECG is durable, practical and flexible, able to monitor and interpret electro cardio graph exams to determine heart rates. It is compact and light weight, the electrocardiograph provides comprehensive functionality with A4 paper. It is easy to use and portable device. Features of Mortara ELI 250 are



- High resolution power display
- Real time preview of real time 12 lead ECG
- Post acquisition review of acquired ECG
- By using the algorithm about the gender, adult and pediatric criteria provides a second opinion for resting ECG
- Bidirectional communication between USB, memory stick, LAN , wireless mortara
- Internal storage up to 60 digital ECG records. Optional expended storage up to digital ECG records
- 1000Hz sampling rate

ELI 250 automatically selects and displays the best 10 seconds of ECG signal form five minute segment of internal full disclosure reducing clinical review time and eliminating the need of repeat ECG

## **AMBULATORY HOLTER MONITORS**

### **SEER MC AMBULATORY DIGITAL ANALYSIS RECORDER**

The SEER MC Recorder provides ambulatory ECG signal, as well as automated analysis of recorded data. Results of the automated analysis intended to assist the physician in the interpretation of the recorded data. Features of the SEER MC ambulatory recorder are

- It can collect and store up to 48 hours
- It have 2 to bipolar channels of the ECG data
- On demand it can acquire 12 lead ECG
- Ambulatory Holter recording provides an opportunity to assess the cardiac function while patient undergoing routine daily activities
- SEER MC have an event button when record ECG, it creates a patient marked event

ECG acquired in the ambulatory environment will include more artifact. SEER MC stored each 10 seconds 12 lead ECG as a sample that makes up a trend; also

acquire these samples so that they can be trended over time. It have an LCD display from which can get pacemaker spike detect display, AM/PM display, Heart beat display, numerical display.

Hard ware's of the SEER MC are the ambulatory recorder, light weight color coded ambulatory cable, 4AA alkaline battery and a removable ECG data card of memory of 64 Mb up to 48 hours



### **SEER MC SETTINGS**

- Paced detect mode off
- AECG gain unity gain(1x)
- AECG high frequency 55 Hz
- AECG low frequency- 0.5 Hz
- Pace pulse frequency response 3.0to 15KHz

### **CUSTO CORE-3**

Custo core -3 is a multi channel Holter ECG recorder providing options for patients diagnosis. The electrodes leads are firmly attach to the device and ergonomically attach to the device. The ECG data are recorded on the MINI SD card which is located in the device. The recorded ECG data are transferred to the PC either wireless via integrated Bluetooth interphase by reading the mini SD card. The ECG data are evaluated in combination with the custo diagnostic software. Product features are:

- Available as 3/6/12 channel recorder
- Modern, ergonomic design
- Housing protect against splash water
- Extremely and light for high wearing comfort

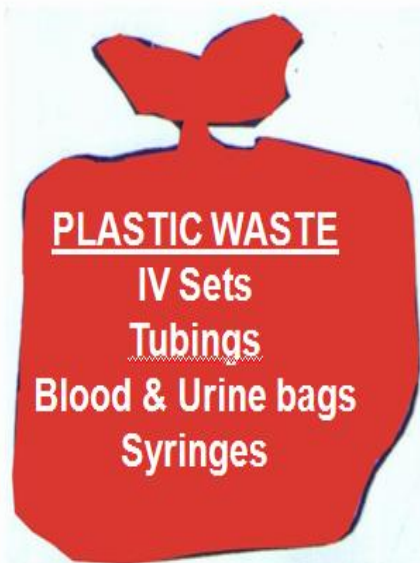- Visualization of the ECG data on the integrated color display
- Display of the device information, runtime of battery, state of recording
- Recording time 24 hours guaranteed
- Network independent operation with only one battery of the size AAA 1.5 v

## CATEGORIES OF BIO MEDICAL WASTE

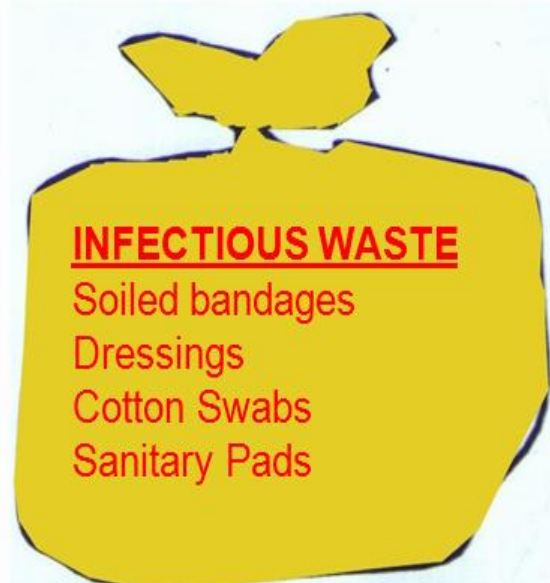<b>OPTION</b>	<b>WASTE CATEGORY</b>	<b>TREATMENT &amp; DISPOSAL</b>
Category No. 1	Human Anatomical Waste	Incineration / deep burial
Category No. 2	Animal Waste	Incineration / deep burial
Category No. 3	Microbiology & Biotechnology Waste	Local autoclaving / microwaving / incineration
Category No. 4	Waste Sharps	Disinfection by chemical treatment / autoclaving / microwaving and mutilation / shredding
Category No. 5	Discarded Medicines and Cytotoxic drugs	Incineration / destruction and drugs disposal in secured landfills
Category No. 6	Solid Waste	Incineration / autoclaving / microwaving
Category No. 7	Solid Waste	Disinfection by chemical treatment / autoclaving / microwaving and mutilation / shredding
Category No. 8	Liquid Waste	Disinfection by chemical treatment and discharge into drains.
Category No. 9	Incineration Ash	Disposal in municipal landfill
Category No. 10	Chemical Waste	Chemical treatment and discharge into drains for liquids and secured land for solids

**COLOUR CODING AND TYPE OF CONTAINER FOR DISPOSAL OF BIOMEDICAL WASTES**

**RED BAG OR CONTAINER**

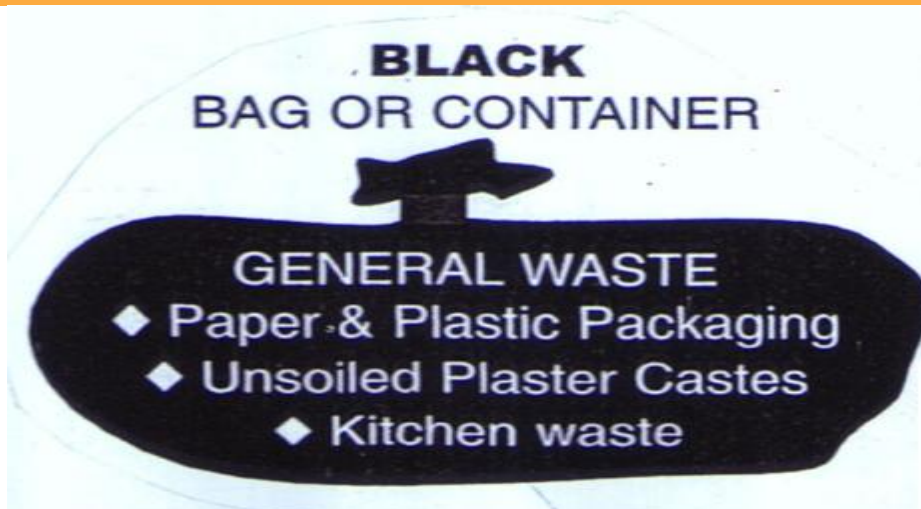

**YELLOW  
BAG OR CONTAINER**



**Needles and Ampoules  
to be put  
in the separate  
puncture proof bin provided**

**BLACK  
BAG OR CONTAINER**



---

# LOGBOOK

## LIST OF ECG PERFORMED

SL NO.	PATIENT NAME	HOSP NO.
1.	YESHODHA A P	373045
2.	SUBAIDHA P A	8901226
3.	USHA KUMARI	327929
4.	SAROJAM	346238
5.	GANESHAN P	388813
6.	SARA BEEVI	388530
7.	SAMUEL J	379714
8.	INDHIRA G	388800
9.	SANTHAMMA	388716
10.	NANDHINI	255972
11.	GOPA KUMAR P R	378891
12.	MOHANDAS	323474
13.	ABDUL SALAM	386753
14.	PRASANNAN K	385379
15.	SURENDRAN V	376571
16.	GEORGE WILSON	388802
17.	CHACKO C T	354611
18.	BINDHU K	335678
19.	SASIKALA N	9510100
20.	ABDUL MAJEED P	384933
21.	BABU B	381062
22.	B/O RANJINI	388815
23.	ELIYAMMA MATHEW	388832
24.	MAHESAN B	388833
25.	HELAN MARY	385006
26.	NARNDHRNATH P K	323020
27.	GIREESAN K	387142
28.	SHAHUL HAMEED A	387616
29.	SARA B	388837
30.	SATHASIVAN NAIR	292628
31.	RAJAGOPAL G	364818
32.	EDISON D	243231
33.	RAJAN N	387956
34.	PRASANTH K	366351
35.	GOVINDHAN T	306365
36.	RAJAN P	265667
37.	BIJU J	380720
38.	THNKAMMA GEORGE	180968
39.	GOPALAKRIHNA PILLAI	388870

40.	SULOCHANA K	368578
41.	SOMANTHAN PILLAI	388881
42.	BALAKRISHNAN	289555
43.	AMBILI KUMAR	233387
44.	ANOOP GEORGE	388875
45.	MADHAVAN	365854
46.	VEENA VIJAYAN	385191
47.	SREELEKSHMI B	385825
48.	VARGHESE C V	388872
49.	B/O ANEESHA M R	385695
50.	CHANDRASHEKHARAN	388884
51.	GOPINATHAN M V	388889
52.	RAJESH KUMAR R	296707
53.	MAJEEDA BEEVI	283219
54.	VARGESE ABHRAHAM	388945
55.	VIJAYARAJAN V	379987
56.	APPU N	374393
57.	JOSEPH A T	388950
58.	SUDHEER S	388960
59.	JESY P JOHN	9004091
60.	MANJULA M	270587
61.	SAHAL P	318661
62.	ABDUL SALAM	388963
63.	ARUN	359704
64.	SADANANDHAN	388952
65.	LIBIN	388985
66.	ANANDHU R	386205
67.	AFNA FATHIMA	389000
68.	LAL P	389001
69.	MANI K	382819
70.	RAJENDRAN S	378445
71.	ANIL KUMAR N	8805432
72.	MUHAMMED P K	383469
73.	OMANA C	244079
74.	ABDUL HAKEEM	388876
75.	B/O JIMINA	386908
76.	ADITHYAN S	389032
77.	SANTHOSH KUMAR	389008
78.	SUGATHAN P	397065
79.	DEEPA P	8702354
80.	HARDHAS N D	319849
81.	INDIRA N PILLAI	383294

82.	JOSEPH VARKEY	388817
83.	THOMAS JOHN	389050
84.	RAJAMMA P N	389007
85.	VNODAN P M	378362
86.	B/O FASEELA	357686
87.	ARSHAD S N	348770
88.	DEVANANDHU D	343990
89.	ATHUL	388031
90.	MOHANAKUMAR S	385462
91.	RAMASWAMY A	389081
92.	PECHIAMMAL	389090
93.	NAZEEMA A	367937
94.	ABDUL RASHEED A	389112
95.	SADASIVAN PILLAI M	388105
96.	SUDHA L	380211
97.	VIJAYAKUMAR C	389118
98.	RENUKA DEVI	267260
99.	SIRIL JOHN	308276
100.	MUHAMMED KHAIS	389095

## LIST OF TMT PERFORMED

SL NO.	PATIENT NAME	HOSP NO
1.	RAJAMMA N	191068
2.	LEELA S	379424
3.	PADMINI	379566
4.	OMANA CHANDRAN	379794
5.	RAJASEKHARAN	284460
6.	SREEKUMAR	322171
7.	AYYAPPAN A	379998
8.	SNEHALATHA	9909438
9.	SURENDRAN NAIR	308609
10.	RENU T R	380145
11.	MOHAMMED SALIM	379533
12.	VASUDEVAN	254719
13.	THANGAMANI C	379909
14.	USHA T N	379776
15.	MOHAMMED SALIM	339743
16.	SHADIYA A	380043
17.	ABDUL RAHIM M	380195
18.	BABY	358100
19.	MATHEW S T	360717
20.	SUDHAKARAN	273042
21.	JOY G	269609
22.	NANUKUTTAN	246615
23.	SADANANTHAN S	301492
24.	STELLUS	378620
25.	KHALID	242729
26.	MASOOD A	342620
27.	ARJUNAN PILLAI	380620
28.	CHANDRASEKHAR	359028
29.	SUSHEELA JOSE	250354
30.	BIJU J	380720
31.	SUMESH KUMAR	380536
32.	MANIYAN PILLAI	379664
33.	SUSHAMMA HAL	309785
34.	CHITHIRAI KANNU	385781
35.	RAPHI D	346053
36.	SANDEEP	380852
37.	ABDUL KAREEM	380230
38.	RAJAKUMARI	382367
39.	SUGATHAN	320228

40.	PRASAD V	374364
41.	PADMANABHAN	315684
42.	JOSHY THOMAS	379908
43.	JAYASREEDEV	382902
44.	ANAS S	381252
45.	PRABHAKARN	382693
46.	SHAJAHAN	382653
47.	PARAMESWARA KURUP	382706
48.	MUNSHIR AHAMMED	9907860
49.	HARIKRISHNAN U	381434
50.	BALASUBRAMANIYAN	368269

## LIST OF HOLTER TEST PERFORMED

SL NO.	PATIENT NAME	HOSP NO.
1.	RAJU R	384171
2.	AKBAR T B	300676
3.	MEBIL SIMON	193672
4.	SREEDHARAN PILLAI	385011
5.	SAVAD S	9306032
6.	JOHN K M	187626
7.	RAJU R	384171
8.	SUMATHY AMMA C	384285
9.	SARA P C	297015
10.	PANKAJAKSHAN K	383469
11.	SANALKUMAR	387602
12.	SANKARAN V	318550
13.	SUMAYYA A	384992
14.	SATHEESH BABU C K	230408
15.	SILPA L S	372622
16.	PARULBEN DHINESHBHAI	384963
17.	AMBUJAM	8705532
18.	INDIRAKUTTY AMMA	385423
19.	ANANDU A S	352264
20.	DHRUVA RANJITH	303810
21.	BINDHU V C	350648
22.	MUHAMMED SUHAIL S	347818
23.	PRATHIBHA P	382311
24.	MAIMUNA P K	385297
25.	KRISHNA KUMAR	367890
26.	GOPALAKRISHNAN D	343217
27.	SOMAN M	385035
28.	SUDHAKARAN N	273042
29.	GOWRI GOPAN S	383769
30.	ANNAMMA MATHEW	384661
31.	ANN MARIYA	304047
32.	INDIRA DEVI V	383593
33.	SATHA DEVAN	372658
34.	SIVA PRAKASAN	377259
35.	MATHAI MATHAI	383699
36.	MIDHUN MS	320895
37.	THOMUS MATHEW	382395
38.	HELEN JOHN	381916
39.	HAMEETHAL BEEVI	382228

40.	ANEESH A	382980
41.	BALAN M	355857
42.	UMAMAHESWARI G	337480
43.	ARYA B	365188
44.	KAVITHA S	382005
45.	SASIKALA DEVI PILLAI	301845
46.	SHAMEEMA K E	383102
47.	BIBIN DEV J S	316243
48.	AMAL SOMARAJAN	382713
49.	ISSAKIAMMAL	336971
50.	ANITHA I	209561

## LIST OF ECHO ASSISTED

SL.NO	PATIENT NAME	HOSP NO.	DIAGNOSIS
1.	FATHIMA DILFA	385056	AS
2.	PRAGATHI VC	393962	VSD
3.	NOUSA HANOON	394308	PDA
4.	AISWARYA DILEEP	394337	ASD, MVP
5.	MUHAMMED BASIM	392827	TRICUSPID ATRESIA
6.	NANDHINY M	255303	DORV, VSD, PS
7.	SIDHARTH K	394423	TGA, VSD, PS
8.	SEHALA FEBI P	394410	AVCD, MR
9.	BHUVANESWARI M	394416	ASD
10.	MANHA	394388	CS TAPVC
11.	SYAM	394408	BAV, AS
12.	SELVA	394468	TOF
13.	SHAJU NG	394460	SV ASD
14.	SIYA M V	394505	LV DYSFUNCTION
15.	LEKSHMI S	390505	SA VSD
16.	DHANJAY SANKAR E S	394541	ASD
17.	B/O SHYJA	39454	OBSTRUCTION OF LV
18.	MANU DEV	377168	COA
19.	B/O SINDHA	351704	TOF
20.	SREENIVASAN V C	394555	EBSTEINS ANOMALY
21.	MOHAMMED SALMAN K	394657	PDA
22.	B/O ANANTHI	394688	DTGA
23.	AHAMMED KASIM	357796	MULTIPPLE ASD
24.	B/O MEHABOoba	396281	TRUNCUS ARTERIOSUS
25.	SANGEETH S H	398224	DOWNSYNDROM, PDA, PAH
26.	PRIYANKA P	9810172	FEOTAL ECHO
27.	BHADRA PRIYA B R	398348	EBSTEIN ANOMALY
28.	MUHAMMED SHAHAD VILLIAN	389884	VSD, COA
29.	MUHAMMED RAYAN A	400701	COMPLETE CAD
30.	MAHESWARI T	331354	HD, SEV MS
31.	ABDUL MAJEED P K	393832	DCM, LV DYSFUNCTION
32.	SIVNKUTTY A K	393832	SEV AS
33.	VINOD KUMAR	393933	HYPERTROPHIC CARDIOMYOPATHY
34.	SIMON	397929	AS
35.	NARAYANAN NAIR	401089	PAH, SEV MR
36.	JAYASREE R	397953	PULMONARY EMBOLISM
37.	MADHUSOODHANAN G	397924	CAD, DEXTROCARDIYA

38.	GOWRIMANIS	398220	DCM
39.	MATHEW P	8907936	BICUSPID AV
40.	SUKUMARAN N	3980282	IVC CLOT
41.	FATHIMAKUNJU A	398269	SEV MS, PAH
42.	RAMLABEEVI A	401474	TAMPONADE
43.	SAKEER HUSSAIN	394020	ASD, RHD
44.	SUBULAKSHMI S	394686	MS, PAH
45.	SNEHA M P	389884	ICR, ASD CLOSURE
46.	AKBER M	398120	RHD, MR, PAH
47.	SAJEEV K N	15094	VSD, RSOV
48.	JAGNNATHA PANICKER C K	400103	DCM
49.	MUTHUMANIYAMMAL M	400508	RHD, AS, MS
50.	ABHINAV PM	398761	COA

## LIST OF TEE ASSISTED

SL NO	PATIENT NAME	HOSP NO.	DIAGNOSIS
1.	VINITHA	387423	ASD
2.	MANIKUMAR	388940	RULE OUT PFO
3.	RAJESWARI I	389037	RHD, MS
4.	DAVID KINGSONA	387166	LA CLOT
5.	SHYAMLAL K	385059	ASD
6.	ANITHA KUMARI S	387981	ASD
7.	MUHAMMED SHABEEB T	378841	PRIOR TO BMV
8.	VINTHA KUMARI K	389023	ASD
9.	MASANAM A	351927	ASD
10.	SIMI S	393032	ASD
11.	SATHIAMMA	388538	SV ASD
12.	SHEELA F	374446	RHD MS
13.	RUBY SACHARIA	383132	RHD, MS
14.	SIBULAL	386263	ASD
15.	RATHAMMA K	386413	RHD, MS
16.	LAIJU K G	393422	ASD
17.	AMITHA M	231823	RHD, MS
18.	MINIMOL P	395781	ASD
19.	JAMEELA BEEVI	397365	MVP, SEV MR
20.	SOBHANA JOHN	303693	RHD, MS

## LIST OF CORONARY ANGIOGRAM ASSISTED

SL NO .	CATH NO	DATE OF PROCEDURE	NAME	HNO	SEX	AGE	CLINICAL DIAGNOSIS	FINAL DIAGNOSIS
1.	64817	22.06.15	UNNIKRI HNAN K K	3983 83	M	65	INFRARENAL AORTIC ANEURYSUM	2VD
2.	64820	22.06.15	SARADHA MMA B	3078 21	F	61	CHB WITH NARROW QRS. S/P PCI	NORMAL CORONARIES
3.	64825	22.06.15	SUDHIKU MAR V	2940 98	M	51	CAD, TMT POSITIVE, PCI TO LCX , POBA TO RCA(2009)	3VD , PLANNED FOR CABG
4.	64834	22.06.15	ROY PHILIP	2350 53	M	60	CAD-OLD IWMI	3VD
5.	64837	23.06.15	AZEEZKUT TY T	2430 41	M	58	CAD, ASMI	3VD, PLANNED CABG
6.	64798	23.06.15	MADHAVA N S	2423 93	M	73	CAD, OLD AWMI	S/O 2VD LAD/RCA WITH BOARDER LINE LMCA AND MINOR LCX LESION
7.	64824	23.06.15	SHAIK K	3972 76	M	65	RHD-CALCIFIC MITRAL AND AORTIC VALVE, FC III	NORMAL CORONARIES, PLANNED FOR DVR
8.	64842	24.06.15	SUKUMAR AN N	3963 13	M	67	CAD	3VD
9.	64843	24.06.15	MANZOOR A	3981 48	M	55	CAD	OSTEOPROXIMA L 99% LAD LESION, PLANNED FOR CABG
10.	64845 6	24.06.15	RADHAKRI SHNAN NAIR R	3985 18	M	60	CAD-ACS	3VD, PLANNED FOR CABG
11.	64847	24.06.15	SULOCHA NA B	3218 77	F	67	CAD-OLD ACS, S/P PCI TO PROXIMAL LAD	PROXIMAL RCA TOTAL, PLANNED FOR PCI TO RCA
12.	64850	24.06.15	MAHADEV AN M	2366 21	M	62	CAD-CSA	MID RCA DISEASE, BORDERLINE

								LCX LESIONS, PLANNED FOR PCI TO RCA
13.	64857	25.06.15	LEELA KUMARI C	3404 33	F	49	RHD, SEVERE CALCIFIC MS, MOD MR	NORMAL CORONARES
14.	64865	25.06.15	RAJAMMA K	3951 68	F	72	CAD, FCII, TMT POSITIVE	PLANNED OR CABG
15.	64869	25.06.15	SEEMANT HANI M	3918 84	F	62	CALCIFIC AV, SEV AS	NORMAL CORONARIES, PLANNED FOR AVR
16.	64871	25.06.15	SOBHANA KUMARI P	3913 83	F	55	ATYPICAL CHEST PAIN	NORMAL CORONARIES
17.	64872	26.06.15	SHYLAJA SATHYAN	3843 96	F	55	CAD-TMT POSITIVE	BORDERLINE RCA DISEASE, FFR TO RCA (0.84)
18.	64874	26.06.15	SHAHUL HAMEED M	3975 65	M	65	CAD-IW STEMI	TVD, PLANNED FOR CABG
19.	64876	26.06.15	ASOKA KUMAR V	3979 58	M	53	CAD-IW STEMI	TVD, PLANNED FOR CABG
20.	64878	26.06.15	OMANA AMMA D	3984 79	F	63	RECURRENT ACS	2VD LAD+MLD OM DISEASE
21.	64888	29.06.15	KUMAR P K	3986 55	M	59	CAD-EVOLVED PWMI, TRIVIAL MR	TVD, PLANNED CABG
22.	64892	29.06.15	ALEYAMM A THOMAS	3971 31	F	62	CAD, EXERTIONAL ANGINA	LAD-MID SIDNIFICANT LESION, FFR TO LAD (0.86)
23.	64893	29.06.15	PUSHPALA THA G	3987 24	F	42	CAD-ACS-ILW STEMI	NORMAL CORONARIES
24.	64895	29.06.15	IDAMMA GEORGE	3960 46	F	65	RHD-SEV MS, MOD MR MOD PAH	NORMAL CORONARIES, PLANNED FOR MVR
25.	64896	29.06.15	MUTHAIY AN T	3935 90	M	57	CAD, TMT POSITIVE	TVD, PLANNED FOR CABG
26.	64901	29.06.15	SUDARSA N A	3904 96	M	50	CAD, RECENT ACS, AWTMI	ULCERATED PLAQUE IN LAD, IVUS/FFR TO LAD WAS PLANNED
27.	64902	29.06.15	K G KURIYAN	3230 76	M	64	CAD, OLD IWMI	TVD

28.	64904	30.09.15	SHAJI B	3917 78	M	37	CAAD, RECENT IWMI, MILD MR	NO FLOW LIMITING LESION
29.	64905	30.09.15	KUMARI THANKAM M	3958 02	F	55	CAD, FCII-III TMT +VE	NORMAL CORONARIES
30.	64910	30.06.15	MURUGES AN G	3963 38	M	48	CAD-RECENT ACS-IWMI	3VD, PLANNED CABG
31.	64911	30.06.15	RAJESH R	3947 04	M	34	CAD-ACUTE IWM, MILD TO MOD MR,	FFR TO LAD(0.82)
32.	65095	22/07/20 15	PECHIAM MAL.S.	3918 61	F	43	LARGE OS ASDL- ->R SHUNT/ MILD PAH/ RA, RV OVERLOAD	NORMAL CORONARIES.
33.	65098	22/07/20 15	KUMAR A.	3967 12	M	37	CALCIFIC SEVERE AS , MODERATE AR , MILD LV DYSFUNCTION	NORMAL CORONARIES
34.	65046	22/07/20 15	SOMENI S.	3943 39	F	59	CAD-OLD IW+LW MI-POST PCI TO LCX (DES), 2010, SEVERE MR- RECURRENT PULMONARY EDEMA-FAIR LV FUNCTION	LAD LESSION PLAN FFR TO LAD
35.	65097	22/07/20 15	RAJU B.	3996 23	M	55	CAD , RECENT AWSTEMI(14/7/ 15) LYSED WITH STK	2VD (LAD + RCA)
36.	65083	22/07/20 15	NASIRUDE EN H.	3977 96	M	46	CAD , RECENT AWMI	S/O 2VD (LAD WITH D1+D2 & RCA) , S/P PCI TO LAD(DES) , POBA TO D1&D2 , FFR TO RCA - 0.92
37.	65109	23/07/20 15	BHARGAV AN KANI K.	3935 12	M	75	SEVERE CALCIFIC AS , MILD AR , MILD TO MODERATE LV SYSTOLIC	PROXIMAL LCX 40-50% LESION

							DYSFUNCTION	
38.	65111	23/07/2015	BALAN P.G.	393747	M	51	ACHD , 22 X 15 MM OS ASD , L TO R , 2:1 , GOOD LV/RV FUNCTION	NORMAL CORONARIES
39.	65110	23/07/2015	KOSHY GEORGE	397645	M	42	RHD , SEVERE MS , MILD MR , MODERATE AR , MILD PAH	NORMAL CORONARIES
40.	65128	24/07/2015	GIRIJA KAVIRAJ	309289	F	65	ATYPICAL CHEST PAIN , FC II	SHOWED MINOR CAD , ECTATIC LAD.
41.	65120	24/07/2015	BHASKARAN NAIR K.	395971	M	72	CAD , UA 11/2014 , CAG(30/4/15)-S/O 3VD , GOOD LV FUNCTION	S/P CAG+IVUS TO LCA(24/7/15) - 3VD , PLANNED FOR URGENT CABG
42.	65122	24/07/2015	AYSHA BEEVI A.	393235	F	60	RHEUMATIC HEART DISEASE/ CALCIFIC MITRAL STENOSIS	NORMAL CORONARIES
43.	65108	24/07/2015	KAMALAM V	364133	F	62	RHD, SEVERE MS, MILD MR ,MOD PAH	NORMAL CORONARIES
44.	65112	24/07/2015	MARY A V.	392562	F	54	CAD AAWMI 08.2013 THROMBOLYSED ,TMT 09/2014 POSITIVE AT LOW WORKLOAD	NORMAL CORNARIES
45.	65139	27/07/2015	RAJA KUMAR SELVIN J.P.	399981	M	47	CAD, NSTEMI EVOLVED AAWMI, TROP T +VE	LAD & RCA LESION
46.	65123	27/07/2015	ABDULLA KUNJU A.	397855	M	72	CAD , AAWSTEMI (??LYSED) , ? OLD IWMI	S/O-2VD (LAD CTO + LPDA) , LV APICAL ANEURYSM
47.	65133	27/07/20	REJIMON	4206	M	49	CAD , ?H/O ACS,	2 VD (

		15					ACHD , S/P TRANS ATL -VSD (DACRON PATCH) CLOSURE + AVR	DIAGONAL + DISTAL RCA)
48.	65136	27/07/20 15	SHAJI P.	3972 97	M	48	CAD , RECENT AWSTEMI	S/O-3VD ( LAD + LCX + RCA)
49.	65124	27/07/20 15	SAJEENDR A BABU K.	3897 20	M	41	CAD , OLD NSTEMI(2004) , OLD IWSTEMI(12/20 14) LYSED WITH STK	ECTATIC CORONARIES
50.	65141	28/07/20 15	ANILA M.	3885 76	F	42	VARIABLE THRESHOLD ANGINA, TMT NEGATIVE	S/O MILD ETATIC CORONARIES, NO SIGNIFICANT STENOSIS
51.	65143	28/07/20 15	PONNAN P	3336 67	M	51	CAD/S/P ABDOMINAL AORTIC ANEURYSM REPAIR WITH AORTOBIFEMOR AL	2VD
52.	65142	28/07/20 15	OBIEDULL AH V	3399 97	M	58	CAD , LMCA+3VD , S/P CABG 4G[LIMA TO LAD,RSVG TO OM2, OM3, PDA]= LAD	S/O NATIVE 3VD + OCCLUDED ALL VENOUS GRAFTS
53.	65140	28/07/20 15	MUHAMM ED HANEEF A R.	3936 85	M	66	RECENT ONSET AOE, TMT STAGE 1 POSITIVE, NO CCF, NO PAH	
54.	65148	28/07/20 15	KRISHNA KUMAR R.	3999 12	M	42	CAD , IWSTEMI	2VD (LAD+RCA)
55.	65156	29/07/20 15	ANIL KUMAR V.	3972 28	M	46	CAD/FC II DOE/TMT POSITIVE AT STAGE I	2VD(LAD AND RCA)
56.	65151	29/07/20	VINAYAN	3989	M	66	ATYPICAL CHEST	MYOCARDIAL

		15		61			PAIN, MID LAD LONG SEGMENT MYOCARDIAL BRIDGING	BRIDGING
57.	65154	29/07/20 15	MUPPUDA THY P.	3826 11	M	67	CAD, AWTMI (16/7/14)- NOT LYSED	DVD- LAD , RCA
58.	65152	29/07/20 15	KRISHNAN .K(RTD STAFF	9306 266	M	65	EXERTIONAL DYSPLNEA UNDER EVALUATION , GOOD LV/RV SYSTOLIC FUNCTION	S/O SVD OF LCX
59.	65170	30/07/20 15	BABY SAROJAM N	3790 37	F	54	AORTOARTERITI S WITH MODERATE TO SEVERE AR, CAD, S/P CABG 2X GRAFTS	PATENT GRAFTS, S/P PCI TO RCA SEVERE CALCIFIC AS/ MILD TO MOD AR/ MODERATE MR/ MODERATE LV DYSFUNCTION/ GLOBAL LV HYPOKINESIA / FCIII/ SR
60.	65171	30/07/20 15	MURUGAT HAL A.	3975 58	F	54	ADMITTED WITH HEART FAILURE	15 S/O OF CO DOMINANT NORMAL CORONARIES PLANNED FOR AVR
61.	65173	30/07/20 15	ABIDA BEEVI E.	3961 44	F	62	DILATED CARDIOMYOPAT HY, MODERATE LV SYSTOLIC DYSFUNCTION	NORMAL CORONARIES
62.	65172	30/07/20 15	INDIRA K	3133 64	F	53	DCM	NORMAL CORONARIES
63.	65159	30/07/20 15	CHANDRA DETHAN V.	3989 25	M	67	CAD/ ACS OLD IWMI / RECURRENT HEMODYNAMIC ALLY	NORMAL CORONARIES

							STABLE VT	
64.	65158	30/07/2015	RADHAKRISHNA PILLAI C.	399680	M	64	CAD , RECENT ONSET ANGINA + DOE , TMT POSITIVE AT STAGE I	SVD LAD/ PTCA TO MID LAD(DES)
65.								
66.	65182	31/07/2015	ASHOKAN C.	321586	M	54	CAD	SVD(LCX)
67.	65174	31/07/2015	SAMSU NISHA J.	399495	F	40	PROBABLE AORTOARTERITIS (INACTIVE) UNSTABLE ANGINA (TROP T NEGATIVE)	LMCA OSTIAL 90%, MILD RCA OSTIAL, LEFT SUBCLAVIAN TOTAL
68.	65181	31/07/2015	ANIL KUMAR .G	394667	M	48	RHD , CALCIFIC SEVERE MS , MILD TO MODERATE MR , SEVERE PAH	TVD/ PLAN MVR +CABG
69.	651789	31/07/2015	RAJENDRA N NAIR M.	391640	M	60	CALCIFIC AORTIC VALVE, SEVERE AS, TRIVIAL AR	MILD CORONARY DISEASE
70.	65192	03/08/2015	SREEKUMAR B.	250313	M	56	CAD/CSA/MINOR CAD(2006)/ NOW FC II AOE/TMT POSITIVE	2VD
71.	65191	03/08/2015	KUNJAMMA K.	392775	F	49	RHD, SEVERE MR, AML FLAIL ? CHORDAL RUPTURE, MODERATE PAH	NORMAL CORONARIES PLANNED FOR MVR
72.	65267	13/08/2015	GEETHA BALASUBRAMONIAN	369232	F	59	DILATED CARDIOMYOPATHY, MOD LV DYSFUNCTION, FC II DOE	NORMAL CORONARIES
73.	65285	14.08.15	FATHIMA BEEVI	257625	F	56	ATYPICAL CHEST PAIN	NORMAL EPICARDIYAL CORONARIES
74.	65277	14.08.15	PADMAVA	3627	F	67	SEV CALSIFIC AS	NORMAL

			THY	12				CORONARIES
75.	65286	14.08.15	HASEENA T	3975 88	F	41	EFFORT ANGINA, TMT+VE	MINOR PLAQUE IN LAD
76.	65295	17.08.15	BALAKRIS HNAN NAIR	3644 23	M	77	CAD, CSA	CALSIFIC CORONARIES WITH LMCA 50% + TVD
77.	65278	17.08.15	RADHAKRI SHNAN ACHARI	3976 54	M	61	CAD, CSA	TVD
78.	65291	17.08.15	GOPALAK RISHNAN V	3957 32	M	56	CAD, NSTEMI	SVD 50% LAD
79.	65294	17.08.15	MADHAVA N NAIR	3469 29	M	65	CAD,OLD AWMI	SVD LAD CTO
80.	65301	17.08.15	POOKUNJ U	3896 69	M	62	CAD,CSA	3VD
81.	65311	18.08.15	SOMAN P	3937 64	M	66	CAD	SVD
82.	65299	18/08/20 15	RAJAN PANICKER M.	1941 95	M	68	ATYPICAL CHEST PAIN/ TMT POSITIVE	NORMAL CORONARIES
83.	65297	18/08/20 15	RETHNAK ARAN C.	4008 43	M	62	CAD/RECENT ACS AWSTEMI	TVD/ PLAN : CABG
84.	65315	18/08/20 15	THANKAM MA C.	3947 52	F	60	CAD RECENT AWMI THROMBOLYZE D WITH STREPTOKINASE	S/O 2VD PLANNED FOR CABG LAD/D1/MAJOR OM
85.	65312	18/08/20 15	NASSARU DEEN E.	3977 56	M	50	CORONARY ARTERY DISEASE, ACYTE IWSTEMI	2VD (LAD AND LCX)
86.	65310	18/08/20 15	SAJEEVAN V.	2612 67	M	48	CAD/OLD IWMI 2006- LYSED	2VD/MILD OSTIAL LAD LESION/OCCLUD ED LCX/PATENT SVG - DISTAL LCX. OCCLUDED LIMA. MOD LV DYSFUNCTION.
87.	65298	18/08/20 15	RAMAJAY AM J.	2377 85	M	72	CAD/OLD IWMI 2000	3VD+SEVERE AS/HTN/DLP/MI

								LD THROMBOCYTO PENIA
88.	65329	19/08/20 15	AYYAPPAN PILLAI T.	3982 71	M	52	MILD RV DILATION, ? RV EMF, GOOD LV FUNCTION	NORMAL CORONARIES, S/O RVEMF
89.	65328	19/08/20 15	RAJA MOHAN K.S	3809 78	M	56	RHD , SEVERE AR , MILD AS, MODERATE MR	NORMAL CORONARIES
90.	65327	19/08/20 15	CHANDRA SEKHAR R.	4010 01	M	49	CALCIFIC SEVERE AORTIC STENOSIS, MODERATE AORTIC REGURGITATIO N	SVD(LAD)/PLAN: CABG+AVR +/MVR/ SMOKER, T2DM, DYSLIPIDEMIA, OVERWEIGHT
91.	65300	19/08/20 15	P.B.K.NAIR	3968 67	M	71	CAD OLD OLD IPWMI, ? RECENT NSTEMI	2VD
92.	65330	19/08/20 15	BINDU B	3806 50	F	39	ACHD, SCIMITAR SYNDROME, RLPV -->IVC	NORMAL CORONARIES
93.	65323	19/08/20 15	ABDUL KALAM A.	3937 41	M	61	CAD , OLD ACS	LMCA + 3VD , PLANNED FPOR EARLY CABG
94.	65423	02/09/20 15	TERRY C.	3988 14	M	41	SEVERE CALCIFIC AORTIC STENOSIS, SEVERE CALCIFIC MITRAL STENOSIS	NORMAL CORONARIES/PL AN: DVR/ PSORIASIS
95.	65429	02/09/20 15	FAIZAL K.	3937 38	M	32	CAD	ECTATIC CORONARIES/P ROBABLY IWMI RELATED PML
96.	65424	02/09/20 15	ABDUL AZEEZ N.	3944 29	M	58	CALCIFIC AORTIC VALVE - ? BICUSPID, MODERATE AS	- NORMAL CORONARIES/PL AN: MEDICAL FOLLOWUP
97.	65439	03/09/20 15	SHANMU GHATHAI	3941 45	F	37	RHD S/P BMV 2008, NOW RE	S/O RIGHT DOMINANT

			M.				SEVERE MS	CORONARIES PLANNED FOR MVR
98.	65438	03/09/20 15	NAGARAJ AN P.N.	3655 54	M	58	RHD/S/P CMV 1981/RE SEVERE MS/MOD MR	NORMAL CORONARIES/F AIR LV FUNCTION
99.	65442	03/09/20 15	ABDUL MAJEED S.	3954 81	M	67	CAD, OLD AWTMI 1992, IWTMI 1999	DISTAL LMCA +TVD/PLAN : URGENT CABG
100.	65457	04/09/20 15	VIMALAM MA PILLAI G	3641 47	F	71	CAD OLD AWMI/IWTMI 2007, FC II AOE	S/O 3VD PLANNED FOR CABG - GRAFTS TO LAD, MAJOR OM, DISTAL RCA/ RPDA/RPLB

## LIST OF CORONARY INTERVENTIONS ASSISTED

SL.NO	CATH NO	DATE OF PROCEDURE	PATIENT NAME	HOSP NO	SEX	AGE	PROCEDURE
1.	64644	01.06.15	IBRAHIM ABDHUL RAHMAN	395047	M	70	PCI TO LAD – D2 BIFURCATION WITH CRUSH TECHNIQUE
2.	64666	03.06.15	PREMNATH	395024	M	59	PCI TO RCA
3.	64683	04.06.15	RAJEEVAN V	395920	M	41	PCI TO LAD AND RAMUS
4.	64676	05.06.15	CHERIYAKOYA B	389131	M	50	PCI TO LCX
5.	64645	05.06.15	RAJKUMAR GEORGE	9607166	M	55	PCI TO RCA
6.	64686	05.06.15	SUSEELA VIMAL	397655	F	62	PRIMARY PCI TO LAD AND RCA
7.	64706	08.06.15	THILAK P K	394588	M	51	PCI TO LAD AND RCA CTO REATTEMPT
8.	64707	08.06.15	THANCKACHAN	393552	M	61	PCI TO LCX
9.	64709	08.06.15	SAJJAD	393776	M	53	PCI TO DISRTAL LAD, PROX LCX AND OM
10.	64708	08.06.15	KHADEEJA	394864	F	75	PCI TO RCA AND LAD
11.	64701	08.06.15	DIVAKARAN AK	351383	M	74	PCI TO LAD
12.	64700	09.06.15	SUNDARARAM L	393587	M	42	PCI TO LCX
13.	64718	09.06.15	SATHYAN M K	395283	M	47	PCI TO LAD AND MAJOR DIAGONAL
14.	64729	10.06.15	MURALEDHARN PILLAI	397579	M	67	PCI TO LAD AND LCX
15.	64697	10.06.15	VIJAYAN K	396730	M	60	PCI TO RCA, FFR TO LAD
16.	64730	11.06.15	ABDHUL HAMEED	397915	M	55	PCI TO LMCA AND LAD
17.	64717	12.06.15	MADHU	396746	M	45	PCI TO LAD, D1
18.	64787	15.06.15	VENUGOPAL B	396811	M	50	PCI TO DISTAL RCA
19.	64768	15.06.15	ANIL KUMAR V	390225	M	46	PCI TO MAJOR OM
20.	64767	15.06.15	RAJAN R	396113	M	49	PCI TO MID LAD CRO
21.	64759	15.06.15	JOSHUAKUTTY	389902	M	65	PCI TO MID

							AND DISTAL LAD
22.	64769	15.06.15	AKBAR T A	254959	M	43	PCI TO LAD
23.	64758	15.06.15	CHOKALINGAM	395470	M	58	PCI PROX AND DISTAL RCA
24.	65014	16.07.15	SATHEESAN S	397945	M	63	PCI TO LAD FFR TO RCA
25.	65054	17.07.15	PANIMAYA RAJ	399318	M	50	PCI TO PROX LAD
26.	65023	17.07.15	CHANDRAN	319986	M	60	PCI TO LAD
27.	65053	17.07.15	THANKAMMA R	399252	F	69	PCI TO LAD
28.	65078	20.07.15	SIDHIK P	392764	M	35	PCI TO LAD CTO
29.	65080	20.07.15	PRABHAKARAN NADAR	389353	M	66	PCI TO LAD
30.	65079	20.07.15	KESHAVN S	397244	M	38	PCI TO RCA
31.	65084	21.07.15	SUDHARI K	399683	F	59	PCI TO RCA
32.	65070.2	24.05.15	BENZILY K M	389879	M	45	PCI TO LAD
33.	65121	24.07.15	NAZARUDHEEN H	397796	M	46	PCI TO LAD POBA TO D1 AND D2, FFR TO RCA
34.	65137	27.5.15	VASUDHEVAN NAIR	388211	M	68	PCI TO RCA
35.	65147	28.07.15	MARIYA ANBIAH	235249	M	65	PCI TO LCX AND OM
36.	65139	29.07.15	RAJAKUMAR SELVAN	399981	M	47	PCI TO LAD AND RCA,POBA TOI DIAGONAL
37.	65153	29.07.15	NIZAR A	400049	M	49	PCI TO RCA
38.	65157	30.07.15	JACKSON PHILIP	391797	M	50	PRIMARY PCI TO RCA AND POBA RPLB
39.	65364	24.08.15	CHRISTHUDAS N	395013	M	66	PCI TO LCX
40.	65354	24.08.15	GEORGE STEPHEN	399215	M	65	PCI TO RCA
41.	65363	24.08.15	SETHULEKSHMI	395727	F	49	PCI TO LAD AND LCX
42.	65374	25.08.15	SATHYBALAN K	393357	M	62	PCI TO PROX LAD
43.	65373	25.08.15	JAYAKUMAR R	401519	M	47	PRIMARY PTCA TO LCX
44.	65367	26.08.15	NAZEEMA N	397236	F	55	PCI TO LAD
45.	65390	26.08.15	DR.RAMESWARA	254031	M	51	PCI TO LAD
46.	65747	05.10.15	SASI B	402252	M	53	PRIMARY PCI TO RCA
47.	65748	05.10.15	RAJENDRAN	397155	M	70	PCI TO LAD

			NAIR				
48.	65796	09.10.15	SADASIVAN NAIR	403708	M	88	PRIMAR PCI TO RCA (BMS)
49.	65746	09.10.15	DEVI K P	397829	F	66	PCI TO RCI
50.	65818	12.10.15	SAIFUDHEEN S	394214	M	37	PCI TO OM

## LIST OF BALLOON MITRAL VALVULOPLASTY ASSISTED

SL NO.	CATH NO	NAME	HOSP NO	SEX	AGE	DIAGNOSIS
1.	63347	RAJESWARI	389037	F	27	RHD, SEVERE MS, MILD MR, MOD TR
2.	63369	REEJA R HENTRY	290098F	F	28	RHD-SEV MS,MILD MR, MOD PAH, ANOMALOUS ORIGIN OF RCA FROM LEFT ORIGIN
3.	63426	JAYAKUMAR.R.	9685	M	44	RHD & SEV CALCIFIED MS, MILD MR, MOD AS, MILD AR, MOD TR, BMV ATTEMPTED
4.	63485	ARUNA.R	9603717	F	26	RHD, MOD-SEVERE MS, MILD MR, MOD PAH, BWV DONE AT 7 MONTHS OF PREGNANCY
5.	63498	CHITHAYEE M.	203053	F	36	RHD, SEV MS, MILD MR, SEV PAH,LAA CLOT
6.	63523	HELEN J	388597	F	27	RHD, SEV MS, MILD AR, SEV PAH, BMV DONE
7.	63528	26 SUMATHI C	389555	F	26	RHD, SEV MS,MOD MR, MILD AR MILD-MOD TR, SEVERE PAH, GOOD RV/LV FUNCTION, 23 WEEKS PREGNANT, BMV DONE
8.	63591	RUBY ZACHARIA M L.	383132	F	44	RHD, SEV MS, MOD AR, TRIVIAL MR, MILD TR, MOD PAH, GOOD LV FUNCTION, SR, NO HF, FC II, BMV DONE
9.	63675	STEPHEN .J	362605	M	49	RHD/SEVERE MS/MILD MR/OLD LA CLOT-RESOLVED/ BMV DONE MILD MS/ MR. FC II/ AF WITH CONTROLLED HR RATE/ NO HEART FAILURE
10.	64741	MAHESWARI T	331354	F	32	RHD SEVERE MS , NO MR, MOD AR, MILD AS, SEV PAH, GOOD LV /RV FUNCTION, FC II,

11.	64761	SHOUKATH ALI.I.	9301353	M	33	RHD - SEVERE MS , MILD - MOD MR, GOOD LV FUNCTION, MOD PAH, AF WITH CVR, NO HC, FC II DOE UNDERWENT BMV
12.	64794	ASHAMOL S.	398226	F	14	RHD SEVERE JUVENILE MS, MILD MR, MILD PAH, FC II, GOOD LV / RV FUNCTION,
13.	64828	ANATHAMMAL G.	397827	F	55	RHD SEVERE MS, TRIVIAL MR, MILD PAH, NO CCF, GLVF, FC II , AF WITH FVR
14.	64827	BINDHU SARAVANAN	393166	F	39	RHD/ SEVERE MS, MILD - MOD MR, SEV PAH, SR, GOOD LV FUNCTION
15.	64826	PADMAKUMARI A.	395098	F	50	RHD SEVERE MS, TRIVIAL MR, MILD PAH, NO CCF, GLVF, FC II
16.	64830	SAKEENA ILLIKKAL	395672	F	39	RHD - SEVERE MS, GOOD LV FUNCTION
17.	64873	MINI.B.L	39584	F	40	RHD S/P CMV SEV- MS, MILD MR, MILD AR, MILD PAH, FC II, AF WITH FVR
18.	64897	THAMARAİKANI B.	395415	F	26	RHD, SEV MS, MILD MR, MILD PAH, GOOD LV /RV FUNCTION, SR, NO HF
19.	64903	SHAJI M.	397725	M	36	RHD – SEV MS, MILD MR, MILD-MODERATE AR, GOOD LV FUNCTION, MILD PAH
20.	64960	SUBADHRA M	384310	F	45	RHD, SEVERE MITRAL STENOSIS, SEV PAH, H/O TIA, H/O LAA CLOT, FC II, BMV DONE

## LIST OF ELECTROPHYSIOLOGICAL PROCEDURES ASSISTED

SL NO.	CATH NO	DATE	NAME	HOSP NO	SEX	AGE	DIAGNOSIS
1.	65640	22/09/2015	ABDUL KARIM U.	402077	M	65	AVNRT
2.	65643	22/09/2015	RAJAGOPALAN ACHARI P.	402253	M	64	LEFT LATERAL PATHWAY
3.	65642	22/09/2015	LIJIMOL P.C.	401373	F	26	AVNRT
4.	65651	23/09/2015	MAYA PRASAD	401170	F	44	AVNRT
5.	65671	28/09/2015	VASUDEVAN P.	402034	M	61	AVNRT
6.	65666	28/09/2015	SIVAGAMI N.	402450	F	41	AVNRT
7.	65688	29/09/2015	RAJEEVAN S.	402671	M	35	AF, AVNRT
8.	65672	29/09/2015	MARYKUTTY JOHN	402477	F	44	AVNRT
9.	65689	30/09/2015	RASHEEDA SAMAD	402070	F	48	AVNRT
10.	65690	30/09/2015	SHAMSUDEEN .A.	402096	M	49	AVNRT
11.	65751	05/10/2015	SHAMLATH BEEVI P.	401214	F	56	LEFT POSTEROLATERAL PATHWAY, AVNRT
12.	65770	06/10/2015	VIVEK O.R.	402134	M	13	AVNRT
13.	65773	06/10/2015	KARTHIKA P.	402285	F	24	AVNRT
14.	65772	06/10/2015	VASUDEVAN N.	283443	M	79	AVNRT
15.	65771	06/10/2015	THOUFEEQ M.	402507	M	15	RIGHT POSTEROLATERAL PATHWAY, AVNRT
16.	65769	07/10/2015	SWAMYDHAS K	366466	M	47	AVNRT
17.	65810	12/10/2015	PREENU SARA VARUGHESE	403442	F	22	AVNRT
18.	65820	13/10/2015	BALAKRISHNAN NAIR P.	403454	M	55	AVNRT
19.	65819	13/10/2015	LATHIKA N.	394882	F	50	AVNRT, AT
20.	65850	15/10/2015	SANESH KUMAR S.	403284	M	32	LEFT LATERAL PATHWAY, TACHY INDUCED

## LIST OF PACEMAKER IMPLANTATION ASSISTED

SL.NO	CAT H NO.	DATE	PATIENT NAME	HOSP NO.	SEX	AGE		DIAGNOSIS
1.	3816	02/06/2015	SOBHANA S	391418	F	56	AAI	CHB
2.	3818	03/06/2015	ABDULLA P.K.	395974	M	38	DR	CHB
3.	3820	09/06/2015	GOPALAKRISHNAN NAIR C.G	186684	M	77	DDDR	CHB
4.	3821	10/06/2015	KAMALANANDAN G.	397774	M	72	VVI	CHB
5.	3822	10/06/2015	UNNI KRISHNAN P.V	320184	M	45	AAIR	SSS
6.	3824	17/06/2015	ALEYAMMA E.J.	386567	F	59	DDD	AVCH, S/P ICR, CHB
7.	3826	19/06/2015	PHILOMINA JOY	397891	F	57	DDDR	SSS
8.	3944	16/10/2015	NASEEMA BEEVI M.	402986	F	53	VVIR	CHB
9.	3826	19/06/2015	PHILOMINA JOY	397891	F	55	DDDR	DR
10.	3830	23/06/2015	LEENA SEBASTIAN	396340	F	48	DR	SYMPTOMATIC SSS
11.	3831	24/06/2015	ABDUL HAMEED M	397915	M	55	VVI	INTERMITTENT CHB
12.	3832	24/06/2015	RETHINA VETRIVEL A.	396319	M	61	VVIR	CHB
13.	3834	29/06/2015	RAJAN K	363971	M	69	VVI	SSS
14.	3931	07/10/2015	ELSY VARKEY	380683	F	55	DR	SSS
15.	3935	08/10/2015	PUSHPAVALLY K	896648	F	55	PG CHANGE	SSS, POST PPI
16.	3938	13/10/2015	SUMA DEVI G	400016	F	44	DDD	SPONTANEOUS AF
17.	3940	14/10/2015	RAVINDRAN N	403812	M	73	DDD	CHB
18.	3942	15/10/2015	SUNIL K N	380295	M	38	DDDR	PRESYNCOPE, POST ILR IMPLANTATION
19.	3943	15/10/2015	JOHN THOMAS	345881	M	58	DDDR	SSS, PAROXYMAL

								AF
20.	3944	16/10/201 5	NASEEMA BEEVI M.	402986	F	53	VVIR	CHB

**LIST OF CARDIAC RESYNCHRONISATION THERAPY/  
IMPLANTABLE CARDIAC DEFIBRILLATOR  
IMPLANTATION PROCEDURE ASSISTED**

SL NO	CAT H NO.	DATE	PATIENT NAME	HOSP NO.	SEX	AGE	PROCEDURE	DIAGNOSIS
1.	3840	06/07/2015	ANILKUMAR P	396965	M	42	CRT	ISCHEMIC, LBBB, LV DYSFUNCTION
2.	3933	08/10/2015	GEETHAKUMARI	400909	F	56	CRT-D	DILATED CARDIOMYOPATHY, LBBB
3.	3936	09/10/2015	SOMAN P R	273424	M	62	CRT-P	CHB
4.	3928	05/10/2015	VARGHESE	9503402	M	74	AICD	CHB
5.	3930	05/10/2015	KRISHNANKUTY	221039	M	54	ICD	UNSTABLE VT
6.	3939	14/10/2015	VELAYUDHAN K	402802	M	62	ICD	ISCHEMIC CARDIOMYOPATHY, RECURRENT VT

## LIST OF CATHETERIZATION ASSISTED

SL NO	CATH NO	DATE OF PROCEDURE	PATIENT NAME	HOSP NO.	SEX	AGE	DIAGNOSIS
1.	63879	03.03.15	SANJAY C	392750	M	13	CHD, SEV MS, MULTIPLE VSD, BAV
2.	63890	04.03.15	SIVENDHU	373573	F	1	CHD, LAGE MALALAINED SA VSD, PDA
3.	63955	11.03.15	NAZEEMA C M	9507096	F	28	CCHD, S/P TOF
4.	63942	11.03.15	JEESHMA K	372690	F	11	SILC, DORV LARGE SP VSD, LARGE OS ASD, INFANTIBULAR PS
5.	64004	17.03.15	LAIJU K G	393422	M	36	ACHD, LARGRE OS ASD
6.	64013	18.03.15	KRISHNAPRIYA	259910	F	10	CCHD, TA, DORV, VSD, PS
7.	64061	24.03.15	DIVYA MOL K B	9100801	F	24	CHD, LARGE MID MUSCULAR VSD, SMALL PDA
8.	64085	25.03.15	PAVITHRA I	389262	F	2	CCHD, TRUNCUS ARTERIOSUS, ASD
9.	64102	26.03.15	ATHIRA S	255142	F	10	CCHD, SA VSD, TA, PDA, MULTIPLE MAPCA
10.	64194	07.04.15	MARIYAM BEEVI	387694	F	15	ACHD, OS ASD, MULTIPLE PV STENOSIS
11.	64549	21.05.15	SANDEEP SOMAN P	379527	M	29	ACHD, SS/LC, SAVSD, PDA
12.	64594	27.05.15	SHAMEERALI CK	351494	M	2	CCHD, LARGE SA VSD, PA, MAPCA
13.	64595	27.05.15	MISRIYA	333490	F	4	ACHD, SS/LC MULTIPLE ASD
14.	64597	28.05.15	SEYADHU SHEBAYEEDEN	390551	M	16	ACHD, SS/LC, LARGE OS ASD
15.	64764	16.06.15	AMRITHA P	8807592	F	27	COMPLEX CCHD, SA/LC, COMMON

							ATRIUM, PA
16.	64975	07.07.1 5	SEETHA R	93010 99	F	33	CHD, OS ASD
17.	64994	09.07.1 5	AFEefa K	38093 9	F	6	ACHD, OS ASD
18.	64988	09.07.1 5	ANILA JOY	29083 2	F	44	ACHD, PFO R TO L
19.	65018	14.07.1 5	SANAM A KHADER	37738 7	F	17	CHD, PARTIAL AVCD, OP ASD
20.	65030	14.07.1 5	SREERUP S	95031 86	M	23	CCHD, PA, HYPOPLASTIC RV

## LIST OF NON – CORONARY INTERVENTIONS ASSISTED

SL NO.	CATH NO	DATE OF PROCEDURE	NAME	HOSP NO	AGE	SEX	DIAGNOSIS
<b>ASD DC</b>							
1.	63452	15.01.15	ANEESH N	303362	M	30	OS ASD
2.	63454	15.01.15	SABU P	388497	M	38	PFO R TO L
3.	63490	20.01.15	SHYLA P K	342139	F	46	17*15MM ASD
4.	63506	21.01.15	MUHAMMED AZHARUDHEEN	384103	M	22	OS ASD
5.	68507	21.01.15	BINDHU B	346529	F	36	11MM OS ASD
6.	63521	22.01.15	RIJI T	389611	F	29	15MM OS ASD
7.	63520	22.01.15	BIYAMIN R A	372874	F	16	35*30 OS ASD
8.	63518	22.01.15	VINEETHA T S	387423	F	22	35*33M OS ASD
9.	63558	28.01.15	AFSILA K T	359802	F	6	MULTIPLE ASD
10.	63561	28.01.15	SNEHA PRIYA	383353	F	26	25 MM OS ASD
11.	63707	12.02.15	SADHIKA SUJITH	372664	F	4	OS ASD
12.	63709	12.02.15	VARUN S	392071	M	31	OS ASD
13.	63708	12.02.15	AJAL PETER	373525	M	22	OS ASD
14.	63746	18.02.15	VINAYAK S	326092	M	6	OS ASD
15.	63756	19.02.15	SUKUMATHI	379064	F	14	OS ASD
16.	65032	15.07.15	AYYAPPAN K	394921	M	49	24*24MM OS ASD
17.	65035	15.07.15	JOHN MINERALAL	9500391	M	31	24*18 MM OS ASD
18.	65034	15.07.	SHAMLIK T	36254	M	9	OS ASD

		15		5			
19.	65040	16.07. 15	SAANISHA	39717 9	F	24	OS ASD
20.	65037	16.07. 15	HEMA J	34781 9	F	4	OS ASD
<b>PDA DC</b>							
1.	64400	06.05. 15	MUHASEENA SHAJAHAN	37475 7	F	11	2.8 MM PDA
2.	64399	06.05. 15	ANASWARA MOHAN	37698 3	F	5	2 MM PDA
3.	64462	13.05. 15	MUHAMMED AFNAN	35846 4	M	3	2 MM PDA
4.	64469	14.05. 15	ASLAH	39628 2	M	0	3 MM PDA
5.	64479	14.05. 15	SHAHANAS S	36831 7	F	2	3.9 MM PDA
6.	64538	21.05. 15	AGNES JOHN	33666 1	M	3	2.5 MM PDA
7.	64550	21.05. 15	GEENA KURIYAN	38238 0	F	12	1.9 MM PDA
8.	64548	21.05. 15	ANJULA SHERIN	35961 9	F	3	2.5 MM PDA
9.	65091	22.07. 15	AADHIL K S	39604 5	M	4	3 MM PDA
10.	65102	23.07. 15	NEHA S SHAJI	36992 7	F	5	2.9 MM PDA
11.	65094	23.07. 15	NAKSHATHARA P	38171 5	F	1	PDA
12.	65114	24.07. 15	DILEEP KUMAR K	39641 6	M	22	LARGE PDA
13.	65161	29.07. 15	IVIN JOBY	38706 4	M	3	PDA
14.	65160	29.07. 15	MANIKANDAN	39967 9	M	0	3 MM PDA
15.	65270	12.08. 15	FATHIMA SAJA	38654 0	F	5	2 MM PDA
<b>BAV</b>							
	64143	01.04. 15	THAKSON	39451 1	M	0	BICUSPID AV, CRITICAL SEV AS
	64852	24.06. 15	B/O SREEJINA	39217 4	F	0	BICUSPID AV, SEVERE AS
<b>BPV</b>							
1.	63880	03.03.	SHIBULAL	38626	M	49	SEVERE

		15		3			VALVULAR PS
2.	64012	18.03. 15	VANARAMAN	31520 5	M	5	SEVERE VALVULAR PS
3.	64211	08.04. 15	BARADHANAN K	39257 5	M	8	SEVERE VALVULAR PS
4.	64301	20.04. 15	SANGEETHA M K	30301 6	F	15	SEVERE CONGENATEL VALVULAR PS
5.	64465	14.05. 15	ANSALAN	37501 7	F	5	SEVERE VALVULAR PS

## SPECIAL PROCEDURES

SL NO.	CATH NO.	PROCEDURE DATE	PATIENT NAME	HOSP NO.	SEX	AGE	DIAGNOSIS	PROCEDURE
1.	63432	14.01.15	VASUDEVA N E R	9709315	M	18	SA VSD	VSD DC
2.	64985	08.07.15	MAHESH KUMAR T	392789	M	21	POST SUBCLAVIAN COA OF AORTA	COA STENTING
3.	64986	08.07.15	SANTHAM MA C	391435	F	60	POST SUBCLVIAN COA OF AORTA	COA STENTING
4.	63338	02.01.15	SIVAN K K	13296	M	49	SEVERE PARAVALVULAR MR, SEV PAH, MOD PARAVALVULAR	PARA VALVULAR MR DC
5.	63969	17.03.15	CHRISTHU DAS	226128	M	58	PARAVALVULAR MR	PARAVALVULAR DC
6.	63627	04.02.15	SAHAD A	375628	M	4	TYPE II ABERNATHY MALFORMATION WITH DIFFUSE B/L PULMONARY AV FISTULA	DC OF ABERNATHY MALFORMATION
7.	63980	13.03.15	NAGARAJA N E	379173	M	59	HYPERTROPHIC CARDIOMYOPATHY, SEV LVOTO, ASH	ALCOHOLIC SEPTAL ABLATION
8.	64819	22.06.15	MARIYA PUSHPAM	398051	F	74	CHRONIC RIGHT PULMONARY THROMBOEMBOLISM WITH H/O DVT	IVC FILTER INSERTION
9.	6359	30.01.1	RADHA K	37801	F	39	ACHD, SV	PERICARI

	4	50	M	6			VSD, POST PERICARDIOTOMY SYNDROME	O CENTESIS DONE
10.	65555	15.09.15	RAMAKRISHNA PILLAI	301155	M	60	MASSIVE PERICARDIAL EFFUSION	PERICARDIO CENTESIS
11.	63750	18.02.15	B/O SUMAYYA	392372	F	0	VALVULAR PA, PDA DEPENDENT PULMONARY CIRCULATION	PDA STENTING
12.	64500	16.05.15	B/O PRABISHA	396649	F	0	CRITICAL PS, PA, HYPOPLASTIC RV	BPV AND PDA STENTING
13.	64806	21.06.15	B/O JAMSHEED A BANU	398388	M	0	DORV, LONG SEGMENT PULMONARY PA, PDA DEPENDENT PULMONARY CIRCULATION	PDA STENTING
14.	65150	28.07.15	SHAHIDA P	389056	F	32	RESTRICTIVE CARDIOMYOPATHY, NON OBSTRUCTIVE HOCM, BIATRIAL ENLARGEMENT INTERATRIAL SEPTUM ANEURISMAL	ENDOMYCARDIAL BIOPSY DONE
15.	64054	21.03.15	SUDHAMONY P V	393761	F	51	CA RECTOSIGMOID ON CHEMOTHERAPY, FRACTURED PICC EMBOLIZATION INTO RV	CATHETER RETRIEVAL FROM RV

## LIST OF BALLOON ATRIAL SEPTOSTOMY PROCEDURES ASSISTED

SL NO	CATH NO	DATE	PATIENT NAME	HOSP NO	SEX	AGE (Y/M)	DIAGNOSIS
1.	65071	20/07/2015	B/O SUMIJA N.	399778	F	2 M	CCHD, DTGA, INTACT IVS, RESTRICTIVE ASD, 2.8 MM PDA, NO PAH, NO LVOTO/RVOTO
2.	65165	29/07/2015	SIBHATULLA A.	400243	M	0	SS, LC, D TGA, 3.0 MM FLAP ASD L--> R, 4 MM SUBPULMONIC VSD R--> L, 2.5 MM PDA WITH BIDIRECTIONAL FLOW, GOOD LV FUNCTION
3.	65163	29/07/2015	B/O PUSHPA P.	397750	F	3 M	CCHD, TRICUSPID ATRESIA, ANEURYSMAL IAS WITH 4 MM ASD, VSD SEV PAH
4.	65250	11/08/2015	B/O ANU	400833	M	0	CCHD, D-TGA WITH INTACT IVS, 3MM ASD L-->R, 4.5 MM PDA L->R
5.	65320	19/08/2015	B/O BUSHRA	401235	M	1 M	CCHD/ D-TGA/ INTACT SEPTUM/ RESTRICTIVE ASD/PDA