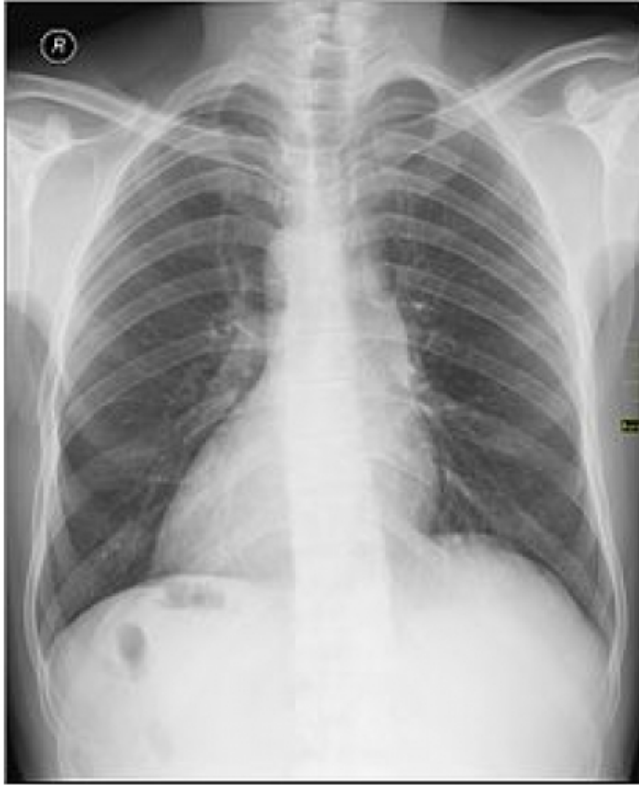



ANATOMY AND MALFORMATIONS IN PATIENT WITH DEXTROCARDIA

Suyash Tripathi

SUYASH TRIPATHI

Anatomy and malformations in
patient with dextrocardia- A
retrospective study

**ANATOMY AND MALFORMATIONS IN PATIENTS WITH DEXTROCARDIA: A
RETROSPECTIVE STUDY**



Submitted for DM Cardiology

By

Dr. Suyash Tripathi

Department of Cardiology

Sree Chitra Tirunal Institute for Medical Sciences & Technology

Thiruvananthapuram – 695011

Jan 2015-Dec 2017

**ANATOMY AND MALFORMATIONS IN PATIENTS WITH DEXTROCARDIA: A
RETROSPECTIVE STUDY**



Submitted by: Dr. Suyash Tripathi

Programme: DM Cardiology

Month & year of submission: October, 2017

INVESTIGATORS

Dr. Suyash Tripathi

Dr. Ajit Kumar V.K., Professor

Dr. Narayanan Namboodiri

CERTIFICATE

This is to certify that the thesis entitled **ANATOMY AND MALFORMATION IN PATIENTS WITH DEXTROCARDIA: A RETROSPECTIVE STUDY** is a bonafide work of Dr. Suyash Tripathi and was conducted in the Department of Cardiology, Sree Chitra Tirunal Institute for Medical Sciences & Technology, Thiruvananthapuram (SCTIMST), under my guidance and supervision.

Dr Ajit Kumar V.K.
Professor and Head
Department of Cardiology
SCTIMST
Thiruvananthapuram

CERTIFICATE

This is to certify that this thesis titled **ANATOMY AND MALFORMATION IN PATIENTS WITH DEXTROCARDIA: A RETROSPECTIVE STUDY** is a bonafide work of Dr.Suyash Tripathi, DM Cardiology resident and has been done under my direct guidance at Sree Chitra Tirunal Institute for Medical Sciences & Technology, Thiruvananthapuram. She has shown keen interest in preparing this project.

Dr Narayanan Namboodiri
Professor
Department of Cardiology
SCTIMST
Thiruvananthapuram

Dr Ajit Kumar V.K.
Professor and Head
Department of Cardiology
SCTIMST
Thiruvananthapuram

DECLARATION FORM

I hereby declare that the project work entitled “Evaluation Of Cardiac Anatomy And Malformation In Patients With Dextrocardia-A Retrospective Study” submitted to department of Cardiology, SCTIMST, Trivandrum is a record of an original work done by me under the guidance of “Dr Ajit Kumar V K, Professor and Head Department of Cardiology, SCTIMST, Trivandrum” and “Dr Narayanan Namboodiri, Professor Department of Cardiology, SCTIMST, Trivandrum”. I also declare that neither me nor my Co-PI have any conflict of interest. This thesis is submitted to SCTIMST in partial fulfilment of rules and regulations of DM Cardiology examination.

Dr Suyash Tripathi

SR Cardiology, SCTIMST

Dated: 7/9/2017

ACKNOWLEDGEMENT

The guidance of Dr. Ajit Kumar V K, Professor and Head of the Department of cardiology, has been invaluable and I am extremely grateful and indebted for his contributions and suggestions, which were of invaluable help during the entire work.

I owe a deep sense of gratitude to Dr. Narayanan Namboodiri for his invaluable advice, encouragement and guidance, without which this work would not have been possible.

The critical remarks, suggestions of Dr. Deepa S Kumar, helped me in achieving a high standard of work.

Last but not the least, I owe a deep sense of gratitude to all my patients without whom this work would not have been possible.

Dr Suyash Tripathi

Senior Resident

Department of Cardiology

SCTIMST

Thirvananthpuram

TABLE OF CONTENTS

Topic	Page number
1. Abbreviations	1-3
2. Abbreviations	4
3. Background and Introduction	5
4. Hypothesis	6
5. Aim of study	6
6. Objective of study	7
7. Review of Literature	8-28
8. Materials and Method	29-35
9. Results	36-70
10. Discussion	71-73
11. Conclusion	74
12. Bibilography	75-76

ABBREVIATIONS

(L)A	Anatomical left atrium
(L)V	Anatomical left ventricle
(R)A	Anatomical Right atrium
(R)V	Anatomical Right ventricle
AF	Atrial Fibrillation
AFL	Atrial flutter
Ant	Anterior
Ao	Aorta
ASD	Atrial Septal Defect
Atr	Atresia
AV	atrio ventricular
AVCD	Atrio-ventricular canal defect
AVV	Atrio-ventricular valve
B/L SVC	Bilateral Superior vena cava
CA	Common atrium
C-AVCD	Complete Atrio-ventricular canal defect
C-AVCD (U)	Unbalanced Complete Atrio-ventricular canal defect
C-AVCD (B)	Balanced Complete Atrio-ventricular canal defect
C-AVCD (U-L)	Unbalanced Complete Atrio-ventricular canal defect with Left ventricular dominance
C-AVCD (U-R)	Unbalanced Complete Atrio-ventricular canal defect with Right ventricular dominance
C-AVCD (U-U)	Unbalanced Complete Atrio-ventricular canal defect with unknown ventricular dominance
C-AVV	Common atrio-ventricular valve
CC-TGA	Congenitally corrected transposition of great arteries
CoA	Coarctation of aorta
CS	Coronary sinus
C-TAPVC	Cardiac Total anomalous pulmonary venous connection
C-TGA	Complete transposition of great arteries
DOLV	Double outlet Left ventricle
DORV	Double outlet Right ventricle
Hypo	Hypoplastic
IC-TAPVC	Infra-cardiac Total anomalous pulmonary venous connection
Inf	Inferior Vena cava
Intr	Interrupted
IVC	Inferior Vena cava
L	Left
LA	left atrium

LAI	Left atrial isomerism (Polysplenia)
L-AVV	Left Atrio-ventricular valve
LCx	Left circumflex artery
LSVC	Left Superior vena cava
LV	Left ventricle
MA	Mitral atresia
Memb	Membrane
mLA	morphologic Left atrium
mLV	morphologic Left Ventricle
mRA	morphologic Right atrium
mRV	morphologic Right ventricle
NRGA	Normally related great arteries
PA	Pulmonary atresia
PAH	Pulmonary arterial hypertension
P-AVCD	Partial atrio-ventricular canal defect
PDA	Patent ductus arteriosus
Post	Posterior
PS	Pulmonary stenosis
R	Right
RA	Right atrium
RAI	Right atrial isomerism (Asplenia)
R-AVV	Right Atrio-ventricular valve
RSVC	Right Superior vena cava
RV	Right ventricle
SA	Situs ambiguus
SA-VSD	Sub-aortic ventricular septal defect
SC-TAPVC	Supra-cardiac Total anomalous pulmonary venous connection
SI	Situs inversus
SS	Situs solitus
Sup	Superior
SV	Single Ventricle
SVC	Superior vena cava
SV-L	Single ventricle of Left ventricular morphology
SV-R	Single Ventricle of Right ventricular morphology
SVT	Supra ventricular tachycardia
SV-U	Single ventricle of undetermined morphology
TA	Tricuspid atresia
TAPVC	Total anomalous pulmonary venous connection
TGA	Transposition of great arteries
UAI	Unidentified atrial isomerism
VA	ventriculo-arterial
VSD	Ventricular Septal Defect

Z-TGA

Zero transposition of great arteries

PLAGIARISM CERTIFICATE

PlagScan Results of plagiarism analysis from 2017-09-30 13:13 UTC

Suyash Tripathi_DM thesis

1.8%



Date: 2017-09-30 13:10 UTC

* All sources 9 | Internet sources 9 |

- | | | | | |
|-------------------------------------|-----|--|------|-----------|
| <input checked="" type="checkbox"/> | [0] | https://www.ncbi.nlm.nih.gov/pmc/articles/PMC4677272/ | 0.6% | 1 matches |
| <input checked="" type="checkbox"/> | [1] | www.internationaljournalofcardiology.com/article/S0167-5273(07)01423-4/pdf | 0.3% | 3 matches |
| <input checked="" type="checkbox"/> | [2] | www.acc.org/~media/Non-Clinical/Files-P...0am Hamm pdf.pdf | 0.3% | 2 matches |
| <input checked="" type="checkbox"/> | [3] | https://rd.springer.com/content/pdf/10.1007/s00270-015-1108-1.pdf | 0.2% | 2 matches |
| <input checked="" type="checkbox"/> | [4] | www.onlinejacc.org/content/38/6/1622 | 0.2% | 2 matches |
| <input checked="" type="checkbox"/> | [5] | https://documentslide.com/documents/coro...ar-k-md-dm-facc.html | 0.1% | 1 matches |
| <input checked="" type="checkbox"/> | [6] | europepmc.org/articles/PMC4145433 | 0.1% | 1 matches |
| <input checked="" type="checkbox"/> | [7] | circ.ahajournals.org/cgi/content/meeting_abstract/124/21_MeetingAbstracts/A11068 | 0.1% | 1 matches |
| <input checked="" type="checkbox"/> | [8] | www.sciencedirect.com/science/article/pii/S0167527308015544 | 0.1% | 1 matches |

28 pages, 5524 words

PlagLevel: selected / overall

12 matches from 9 sources, of which 9 are online sources.

Settings

Data policy: Compare with web sources

Sensitivity: Medium

Bibliography: Consider text

Citation detection: Reduce PlagLevel

Whitelist: --

BACKGROUND

Dextrocardia (from Latin *dexter*, meaning "right," and Greek *kardia*, meaning "heart") is a rare congenital defect in which the apex of the heart is located on the right side of the body. Dextrocardia is a rare condition. In a study by Walmsley et al, retrospective review of 5539 fetal echoes in a tertiary care hospital, incidence was 8.3 in 1000 Walmsley, Hishitani *et al*,¹⁸. Another study by Bohun et al Bohun, Potts *et al*, 2007³, A retrospective review of all diagnoses of dextrocardia due to embryologic development at a tertiary care hospital from 1985 to 2001 was performed. Eighty-one cases were identified (48 ante-natally). The incidence of dextrocardia was estimated to be 1 in 12,019 pregnancies. Twenty-seven cases were situs solitus, 30 situs inversus, and 24 situs ambiguous or isomerism. Cardiac malformations were found in 26 of 27 cases of situs solitus, 7 of 30 cases of situs inversus, and 24 of 24 cases of isomerism. Non-cardiac malformations were identified in 10 of 27 cases of situs solitus, 6 of 30 cases of situs inversus, and 14 of 24 cases of isomerism. There are very few studies which have specifically looked specifically into the incidence of situs in patients with dextrocardia. In the study by Offen et al among the 19 patients with adult congenital heart disease, Situs was solitus in 14 (74%) and inversus in five (26%) Offen, Jackson *et al*, 2016¹². In another study by Garg et al from SGPGI, Lucknow, of total 125 patients with dextrocardia incidence of situs inversus (39.2%) followed by situs solitus (34.4%) and situs ambiguous [26.4% (right isomerism in 18.4% and left isomerism in 8.0%)] Garg, Agarwal *et al*, 2003⁸.

HYPOTHESIS

There is significant difference in the morphologic findings in patients with dextrocardia with different situs.

AIM OF THE STUDY

To evaluate the cardiac anatomy, situs and malformations in patients with Dextrocardia registered in SCTIMST database

To determine the most common situs in patients presenting to a tertiary care centre

OBJECTIVE

1. To determine the most common situs in patients with dextrocardia who are being registered to SCTIMST.
2. To determine the most common diagnosis in patients with dextrocardia
3. To determine the most common diagnosis in patients of different situs with increased and decreased pulmonary blood flow
4. To determine the Looping of ventricles in patients with dextrocardia
5. To determine the cardiac chamber and great artery positions relative to thorax.
6. To compare the structural difference in the hearts of patients with situs solitus and situs inversus with dextrocardia

REVIEW OF LITERATURE

DEFINITIONS

Dextrocardia (from Latin dexter, meaning "right," and Greek kardia, meaning "heart")

DEFINITION-1

- Van Praagh, Van Praagh *et al*, 1964¹⁷ described it as the situation where on plain chest x-ray the heart is predominantly in the right hemithorax irrespective of location of apex.

DEFINITION-2

- Lev, Liberthson *et al*, 1968⁹, Squarcia, Ritter *et al*, 1973¹⁵ described dextrocardia when the Apex or major axis of the heart points to the right due to intrinsic developmental anomaly of heart see Figure 2. In this manuscript we will be following this definition.

Arcilla and Gasul, 1961¹ described dextrocardia when the angle between mid-sagittal axis and longitudinal axis of heart is 30-40° to the right side see Figure 1

Dextroposition (Lev, Liberthson *et al*, 1968⁹)- Cardiac base-apex axis may be oriented similarly as in dextrocardia or still points toward the left, but the heart is shifted to the right due to extra-cardiac pathologic states involving the diaphragm, lung, pleura, or other adjoining tissues see Figure 2.

Dextroversion= Dextrorotation= Pivotal Dextrocardia= Isolated Dextrocardia (Ellis, Fleming *et al*, 1966⁷, Lev, Liberthson *et al*, 1968⁹)- Refers to that type of dextrocardia in which the orientation of the chambers is such as would be obtained were the heart rotated or pivoted to the right along the horizontal plane with the atria as a fulcrum see Figure 2. In this situation patient will have situs solitus with right sided cardiac apex with non-inverted ventricle. In situation where inversion of ventricle is present it is called as *ventricular inversion in situs solitus with dextroversion* (de la Cruz, Espino-Vela *et al*, 1967⁵). Van

Praagh, Van Praagh *et al*, 1964¹⁷ discouraged this term, he argued that in normal fetus with D-looped ventricle, fetal

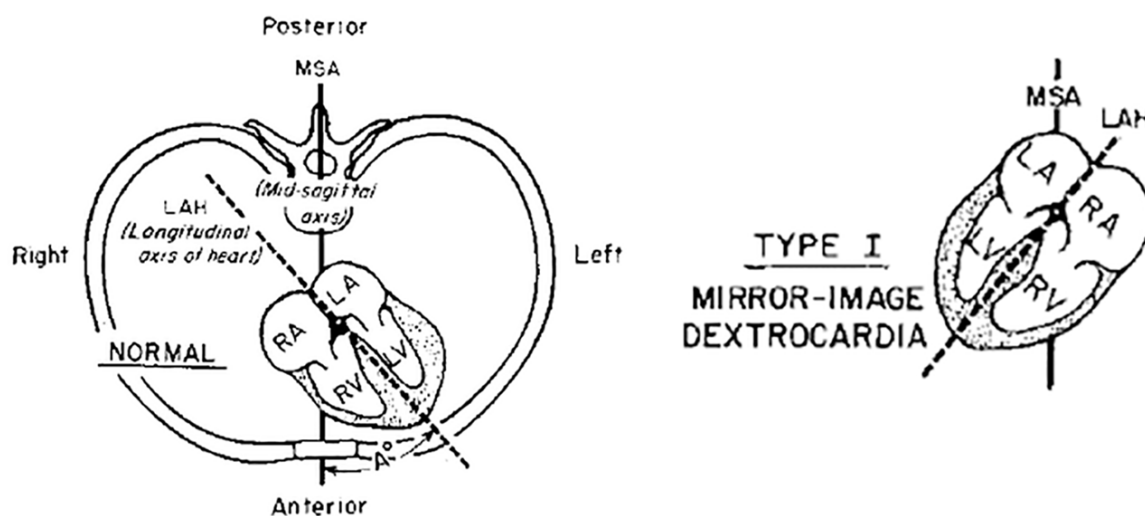


Figure 1 A transverse section of the chest demonstrating the position and chamber arrangement of a normally placed heart. The angle (A°) formed by the longitudinal axis of the heart (LAH) with the midsagittal axis of the chest (MSA) in the horizontal plane indicates the degree of cardiac heterotaxy. The angle (A°) is $30-40^{\circ}$ to the right has been described as dextrocardia. Arcilla and Gasul, 1961¹

heart swings to left side by the end of 2nd month of pregnancy, it is the failure of this rotation causes dextrocardia, hence actually there is no dextro-rotation, Similarly in L-loop ventricle heart is destined to swing to the right side, the term dextroversion in this case erroneously suggest that there is an abnormality.

Dextroversion 2nd definition- Certain authors have expanded the realm of this condition, they have stated that apex of heart is points to right with morphologic left ventricle in anterior position but they can also occur in lung pathology. Rogel, Schwartz *et al*, 1963¹⁴ has presented a case series of 6 patients, in which he tried to differentiate it from dextroposition, which also occurs in lung pathology but in this case, although heart is in right hemithorax, it's apex is pointing to left and morphologic Right ventricle is the anterior most structure in this case.

Mirror-image Dextrocardia (Lev, Liberthson *et al*, 1968⁹)- Applies to the dextrocardia in which the orientation of the cardiac chambers is a mirror-image of that of a normally situated heart or levocardia see Figure 2. In this situation patient will have situs inversus with right sided cardiac apex with non-inverted ventricle. If ventricular inversion is present it is called as ventricular inversion in *situs inversus with mirror image dextrocardia* (de la Cruz, Espino-Vela *et al*, 1967⁵)

Laevoverision (de la Cruz, Espino-Vela *et al*, 1967⁵)-Applies to situs inversus with left sided cardiac apex with without ventricular inversion (i.e. morphologic left ventricle on right side and morphologic right ventricle on left side). When ventricular inversion is present it is called as *ventricular inversion with situs inversus with laevoverision*.

Mixed Dextrocardia (Lev, Liberthson *et al*, 1968⁹)- applies to that type of dextrocardia in which the atria and ventricles do not correspond, that is, the atria are in "pivotal" position, while the ventricles are in "mirror-image", or vice versa see Figure 2

Transposition (Lev, Liberthson *et al*, 1968⁹)- in dextrocardia will pertain to exit of the arterial trunks from the morphologically wrong ventricles, or to an abnormal anteroposterior relationship of these vessels with the aortic orifice situated anterior to that of the pulmonary orifice, or to both. The point of reference of the position of the arterial trunks in dextrocardia with transposition will be the normal position of the arterial trunks in levocardia (normal position of the heart).

Inverted Transposition (Lev, Liberthson *et al*, 1968⁹)- will signify that, in addition to the disturbed anteroposterior position of the arterial trunks, there is abnormal lateral relationship; that is, the aortic orifice lies to the left of the pulmonary orifice.

Zero Transposition (Squarcia, Ritter *et al*, 1973¹⁵)- Refers to the type of transposition in which position of aortic annulus is anterior to pulmonary annulus.

Cardiac Position and Apical Direction

Location in the Chest

Within the thorax, the heart can be described positionally as left-sided (normal), right-sided, or midline. The position of the heart in the mediastinum is affected not only by underlying cardiac malformations but also by abnormalities in adjacent structures. It can be displaced by conditions that distort the shape of the thorax, such as severe scoliosis or an elevated diaphragm, or that alter the size of thoracic structures, such as a hypoplastic lung or diaphragmatic hernia. Rightward displacement of the heart constitutes dextroposition, a leftward shift represents levoposition, and shifts toward the midline are called mesoposition.

Orientation in the Chest

The direction in which the ventricles are aligned defines the base–apex axis of the heart and may be leftward, rightward, or midline. The base–apex axis is independent of cardiac location and displacements. For example, a patient with a hypoplastic right lung could have a right-sided heart, owing to dextroposition, and still exhibit a leftward apex. The base–apex axis is also independent of cardiac sidedness.

Situs solitus (De la Cruz, Anselmi *et al*, 1971⁶)

Characterized by an anatomical right atrium, the greater lobe of the liver, and the supra-hepatic segment of the inferior vena cava being placed on the right, is divided according to the direction of the apex into: (a) normally placed heart, with apex to the left, and (b) dextroversion, with apex to the right.

Situs inversus (De la Cruz, Anselmi *et al*, 1971⁶)

Characterized by an anatomical right atrium, greater lobe of the liver, and the supra-hepatic portion of the inferior vena cava being placed to the left, is divided according to the position

of the apex into: (a) mirror-image dextrocardia, with a right-sided apex and (b) laevoversion, with a left-sided apex.

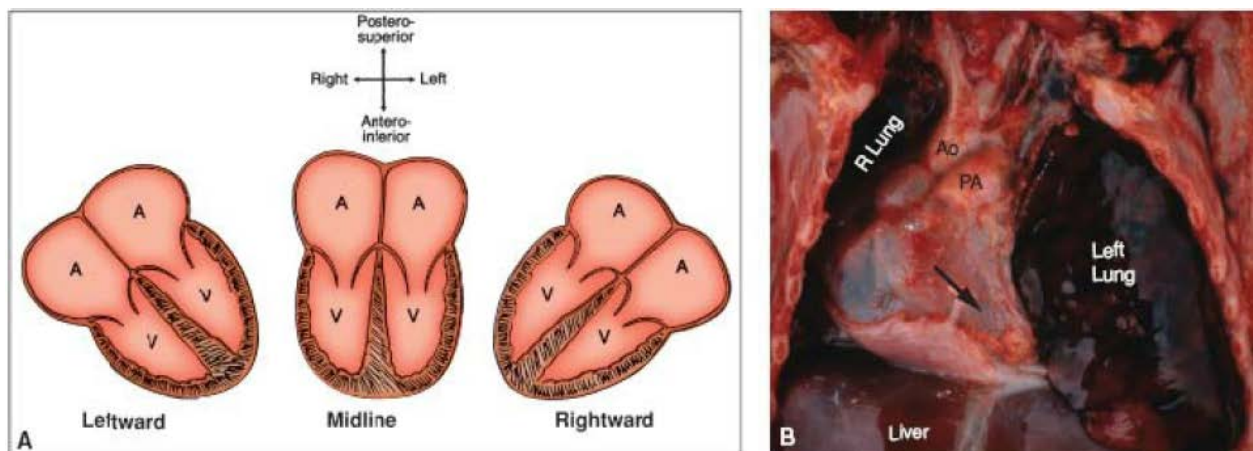


Figure 3 Cardiac base–apex axis. A: The three types are shown schematically and are independent of cardiac position or situs. B: The ventricular apex is leftward (arrow), even though a hypoplastic right lung has caused dextroposition of the entire heart

Visceral Sidedness (Situs)

All major organ systems begin their embryologic development as midline structures with bilateral mirror-image symmetry. However, three organ systems (cardiovascular, respiratory, and digestive) later acquire asymmetry and are thereby characterized by sidedness (situs or handedness), which is genetically determined. Sidedness may be normal, mirror-image, isomeric, or indeterminate. Right isomerism indicates bilateral right-sidedness, whereas left isomerism denotes bilateral left-sidedness.

Cardiac Sidedness (Situs)

Cardiac sidedness is determined by the position of the morphologic right atrium. It is not determined by the direction of the cardiac apex, the positions of the ventricles or great arteries, or the sidedness of non-cardiac viscera. The morphologic right atrium is normally right-sided but is left sided in situs inversus (mirror-image sidedness). Bilateral right atria define right cardiac isomerism, and bilateral left atria constitute left cardiac isomerism

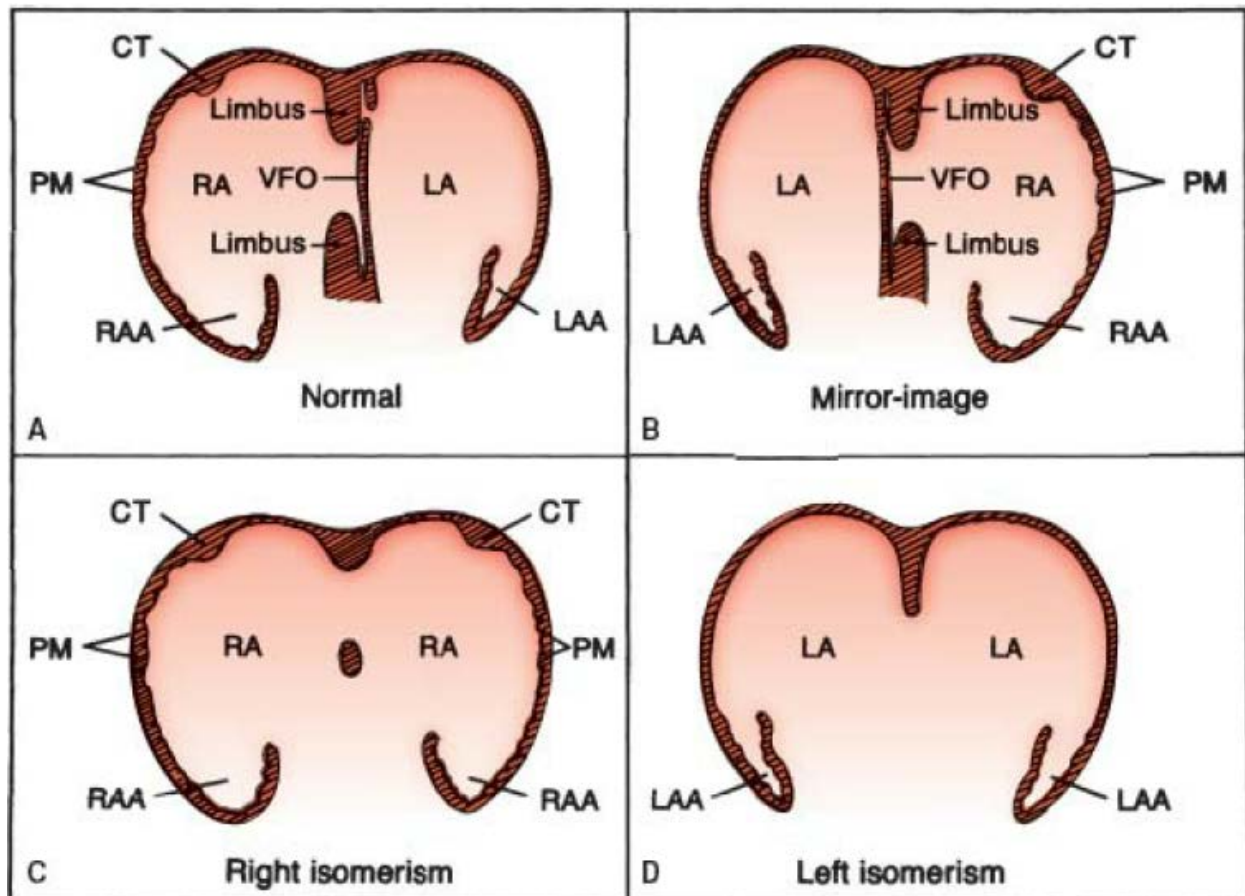


Figure 4 Cardiac situs (sidedness), shown schematically. A: Situs solitus, with right-sided morphologic right atrium. B: Situs inversus, with left-sided morphologic right atrium. C, D: Situs ambiguus, with bilateral morphologic right atria (C) and bilateral morphologic left atria

Pulmonary Sidedness (Situs)

Pulmonary sidedness is determined by the positions of the morphologic right and left lungs. Pulmonary morphology, in turn, is defined by the relationship of the pulmonary arteries to their adjacent bronchi, and not by the number of lobes. The pulmonary artery of a morphologic right lung travels anterior to its upper and intermediate bronchi, whereas that of a morphologic left lung travels superior to its main bronchus and posterior to the upper lobe bronchus.

Normally, the distance from the carina to the origin of the upper lobe bronchus is 1.5 to 2.5 times greater for the morphologic left lung than for the right lung, and this ratio holds true

regardless of the sidedness of the aortic arch (which is determined by the bronchus over which the aorta travels) Van Mierop, Eisen *et al*, 1970¹⁶

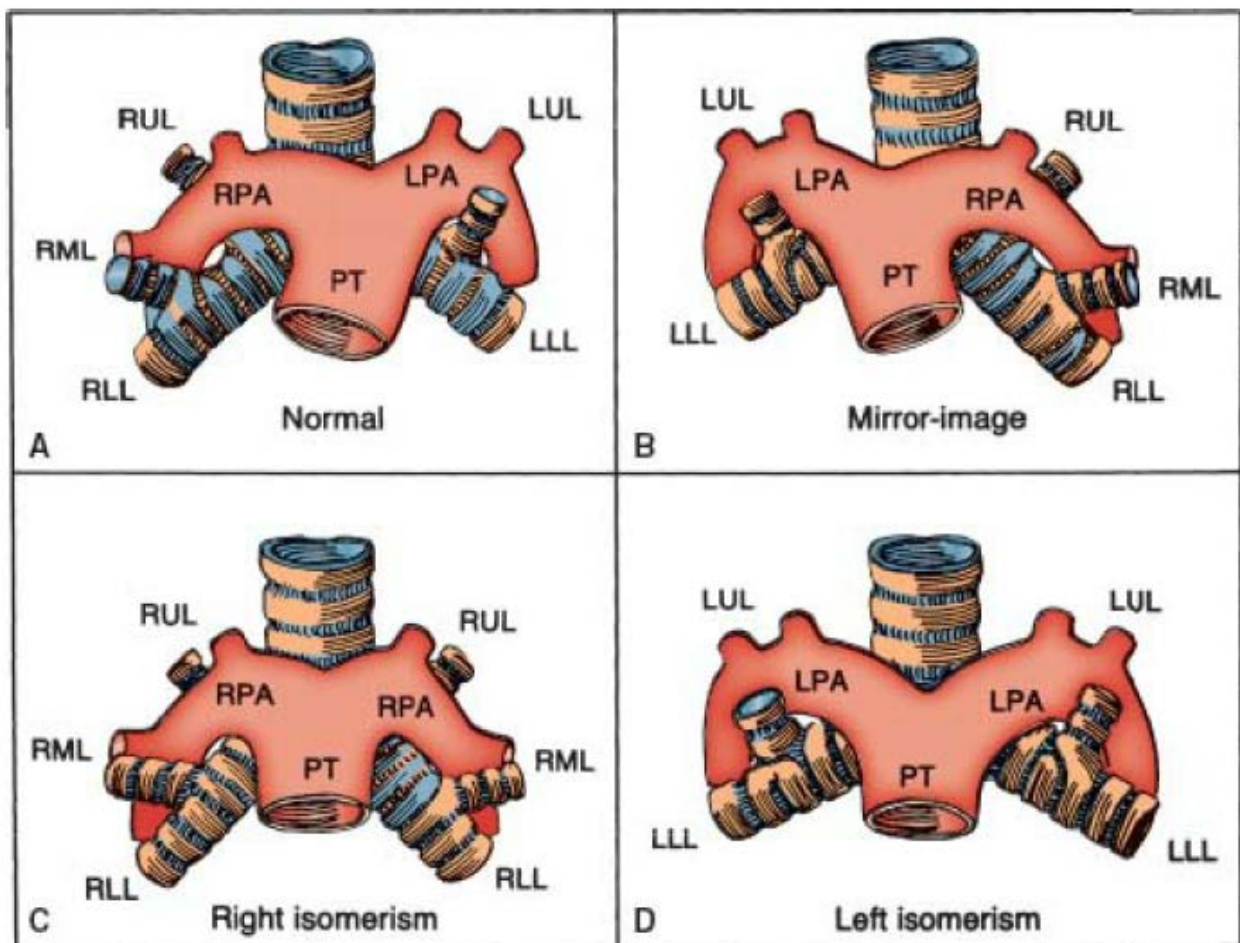


Figure 5 Pulmonary situs (sidedness), shown schematically. A: Situs solitus, with right pulmonary anterior to its upper lobe bronchus and with left pulmonary artery posterior to its upper lobe bronchus. B: Situs inversus, with mirror-image morphology. C, D: Situs ambiguus, with bilateral morphologic right lungs (C) and bilateral morphologic left lungs (D).

Abdominal Sidedness (Situs)

Abdominal sidedness is determined by the location of the liver and stomach, with the spleen and pancreas generally on the same side of the vertebral column as the stomach. The state of the spleen can be evaluated by clinical imaging.

In the asplenia syndrome, the liver is commonly midline with two mirror-image right lobes (right hepatic isomerism). The biliary tree is patent and is usually associated with a single gallbladder. The position of the stomach and pancreas can be left-sided, right-sided, or

midline. Malrotation of the bowel is the rule, such that the cecum and appendix may be located in any of the abdominal quadrants. Finally, the aorta and inferior vena cava travel together on the same side of the vertebral column, a unique feature that can be demonstrated by abdominal imaging.

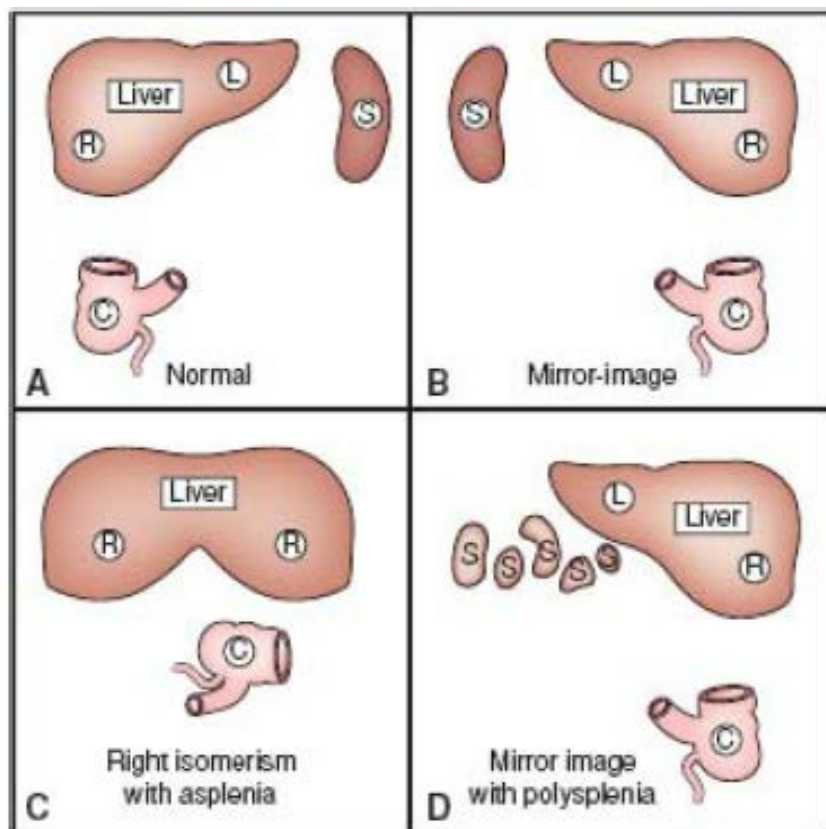


Figure 6 Abdominal situs (sidedness), drawn schematically. A: Situs solitus, with right-sided liver, left-sided spleen (also stomach and pancreas, not shown), and cecum in right lower quadrant. B: Situs inversus, with mirror-image morphology. C: Situs ambiguus with right isomerism shows liver with two right lobes, malrotation of the bowel (indicated by the abnormal position of the cecum), and asplenia. D: Situs ambiguus with left isomerism shows polysplenia; other features are variable.

In the polysplenia syndrome, the sidedness of the abdominal viscera may be indeterminate (ambiguous), mirror-image (inversus), or even normal (solitus). Although the spleens are multiple, they are all located on the same side of the vertebral column as the stomach. The gallbladder is single, but biliary atresia may occur. As a rule, the inferior vena cava fails to join the heart directly and exhibits azygos continuation, with connection to the superior vena cava.

In the article authored by Van Praagh, Van Praagh *et al*, 1964¹⁷ titled Anatomic types of dextrocardia, on the basis of 51 necropsies he has described various types of congenital dextrocardia. He has proposed a classification to determine the relative locations of cardiac chambers on basis of (1) the type of viscerio-atrial situs present, and (2) the type of cardiac loop which coexists. He also hypothesized that on the basis of relative locations of great arteries at semilunar valve positions determine the ventricular loop and the location of ventricle, in patients with transposed aorta position of aortic valve determines the position of right ventricle. The mirror-imagery of inversion is considered to be a biologic illusion. He also stated that, situs solitus of the viscera and situs inversus of the atria never occur together, isolated mirror-image dextrocardia (type II of Reinberg and Mandelstam, 1928¹³ See also *Figure 7*) is non-existent. Transposition was found in 61% cases, of these 10% had double outlet right ventricle.

In the article authored by Arcilla and Gasul, 1961² titled “Congenital dextrocardia”, on the basis of 50 cases studied partly by necropsy and angiocardiography they have classified dextrocardia into 5 types see Figure 13. First category is Mirror Image dextrocardia, Type II is dextroversion with normal position of chambers i.e. Venous chambers are right sided and posterior. Type III is mixed dextrocardia with inverted cardiac chambers, Type IV is congenital dextro-position and Type V is extrinsic dextrocardia (congenital anomaly of chest cage, lung and diaphragm). The chest roentgenologic findings were similar in Type I, II and III with elevated left hemi-diaphragm. In this study they didn't classify the dextrocardia in the background of visceral situs. In patient with patient with type II dextroversion they have described some cases in which left ventricle to left and anterior to right ventricle and aorta also to left and anterior to Pulmonary artery, but they were not classified as transposition, see Error! Reference source not found.

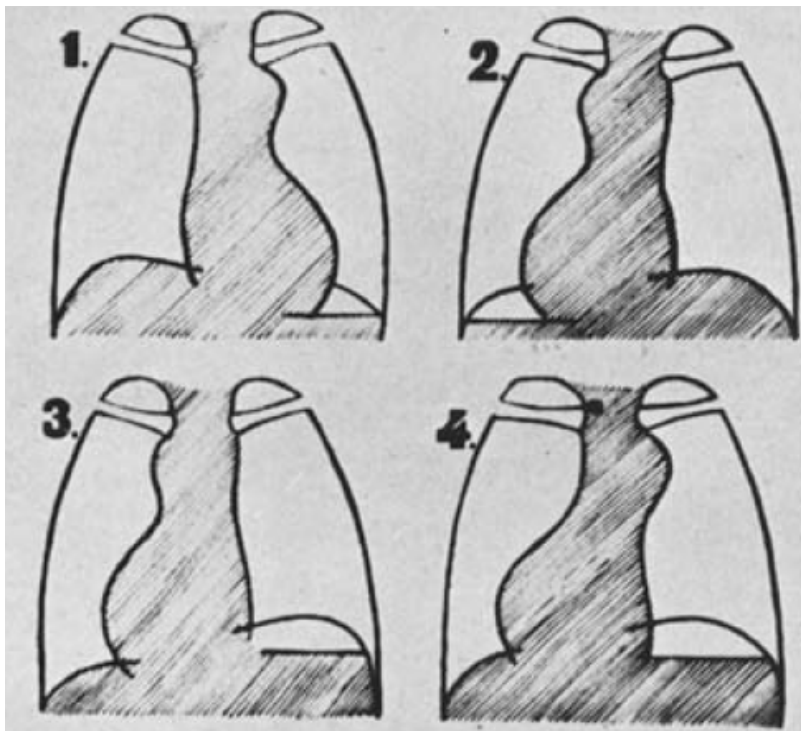


Figure 7 X-ray appearance of the different types of congenital dextrocardia. (1) Normal. (2) Complete inversion of viscera (Type I). Reversed image compared with normal. (3) Congenital isolated dextrocardia with inversion of cavities. Abdominal viscera normally placed (Type II). (4) Isolated dextrocardia, with normal interrelation of cavities and left-sided aortic arch (Type III). Note the position of the diaphragmatic domes. Adapted from Reinberg and Mandelstam, 1928^{1,3}

In the article authored by Lev, Liberthson *et al*, 1968⁹ titled “Pathologic Anatomy of Dextrocardia and its Clinical Implications” on the basis of 41 necropsies they concluded that dextrocardia can be classified as 1)Dextroversion, 2)Mixed dextrocardia with either atrial or ventricular inversion and 3)Mirror image dextrocardia. Mixed dextrocardia is frequently associated with Transposition, VSD and Pulmonary atresia. Dextroversion and Mirror image dextrocardia have no definite association in this series. Besides great vessel orifice position relative to each other position of Anterior Descending (AD) artery may help differentiate between dextroversion and mixed dextrocardia with atria as pivot with AD on left side in former and right side in later. Pulmonary trunk is posterior and left of aorta in dextroversion while it is to right and posterior in mixed dextrocardia and mirror image dextrocardia. In patients with transposed great vessels convexity of ascending aorta is to right in dextroversion

and to left in mixed dextrocardia see Table 1. Transposition was found in 70% cases, of these 12% had double outlet right ventricle.

In the article authored by Squarcia, Ritter *et al*, 1973¹⁵, titled as “Dextrocardia: Angiographic study and classification” on the basis of 60 angiographic studies they concluded that position of septum, chambers, great arteries, their relation at semilunar valve level can be confidently described from angiograms. 75% patient in this series had transpositions. Transposition with double outlet right ventricle occurred in 15% cases in this series. They also stressed to the fact that visceral and atrial situs always match, more so with drainage of inferior vena cava. They also coined the term zero transposition when aorta is anterior to pulmonary artery.

In the article authored by De la Cruz, Anselmi *et al*, 1971⁶ titled “Systematization and embryological and anatomical study of mirror-image dextrocardia, dextroversion, and laevoversion” they have discussed the embryology of heart and explained the term dextroversion and laevoversion. They have explained to diagnose situs on the basis of location of liver, supra-hepatic IVC position. Then they position of the apex to be determined as right or left. In situs solitus if apex is left-Levocardia or apex is rightward-Dextroversion, whereas in situs inversus if apex is rightward- Mirror image dextrocardia or leftward- Laevoversion. Then presence or absence of ventricular inversion to be commented appropriate for situs. Furthermore great artery relationship should be classified as normally related, transposed or truncus. Therefore according to this group if a patient had situs inversus with dextrocardia and corrected transposition and D-Posed right ventricle, it should be classified as *situs inversus, mirror image dextrocardia with ventricular inversion with transposed great arteries*. In this article they also described patients with situs inversus, isolated ventricular inversion and normally related great arteries i.e. pulmonary artery is anterior and right.

In the article authored by Garg, Agarwal *et al*, 2003⁸ titled “Dextrocardia: an analysis of cardiac structures in 125 patients”, they concluded that Of total 125 patients, dextrocardia was most common with situs inversus (39.2%) followed by situs solitus (34.4%) and situs ambiguous [26.4% (right isomerism in 18.4% and left isomerism in 8.0%)]. Mean age was 9.2+/-11.2 years

(range; 3 days to 60 years), 82 males and 43 females. In situs inversus dextrocardia, majority (73.4%) had concordant atrioventricular (AV) connections while discordant AV connections and univentricular atrioventricular connections (UVAVC) were present in 12.2 and 14.3% patients, respectively. Majority of patients with concordant AV connections (72.2%) also had concordant VA (ventriculo-arterial) connections (conotruncal anomalies were commonest). Similarly, majority of patients with discordant AV connections (66.7%) also had discordant VA connections. Commonly (44.9%), these patients presented with decreased pulmonary blood flow (Qp). Total 28.6% patients had normal intra-cardiac anatomy (10.2% presented with rheumatic heart disease). In situs solitus dextrocardia, majority (51.2%) had AV concordance while discordant AV connections and UVAVC were present in 41.9 and 7.0% patients, respectively. In patients with concordant AV connections, majority (77.2%) had VA concordance (majority presented with increased Qp due to pre or post-tricuspid shunts). Similarly, majority of patients with discordant AV connections (88.9%) also had discordant VA connections (88.9% presented with decreased Qp). Only 7.0% patients with situs solitus dextrocardia had normal intra-cardiac anatomy. The striking features of right isomerism were male predominance (male: female ratio 2.2:1), cyanosis with decreased Qp in 86.9%, and high incidence of UVAVC and venous system anomalies (39.1% each). Striking features of left isomerism were biventricular ambiguous AV connections in all except one, presentation with increased Qp in 60.0% and presence of inferior vena caval interruption in 60.0% patients

In the study by Ellis, Fleming *et al*, 1966⁷ titled “ New concepts in dextrocardia: Angiographic considerations” based on study of n=69 patients, done partly by angiography and partly by necropsy they gave an angiographic classification of dextrocardia based on the situs and ventricular looping. Type I situs solitus, Type II- situs inversus and Type III-situs ambiguus. Each of these were further sub-classified according to A-Concordant ventricular loop (i.e. D-Loop for situs solitus and L-Loop for situs inversus); B-discordant ventricular loop (i.e. L-Loop for situs solitus and D- Loop for situs inversus)

In the study by Calcaterra, Anderson *et al*, 1979⁴ titled “Dextrocardia-value of segmental analysis” based on study of n=40 patients, by radiography, angiography and necropsy in few cases they concluded that segmental analysis and descriptive terms are essential to define anatomy of heart. In this study they also concluded that bronchial situs is better marker of atrial situs as compared to location of spleen. They also advocated that instead of defining loops and ventricular inversion it is easier to describe the location of ventricle as anterior/posterior and superior/inferior in relation to the other ventricle.

Position of structures in thorax	Dextroversion	Mixed Dextrocardia	Mirror Image Dextrocardia
Origin of anterior descending artery from aorta	Left	Right	Right
Right Ventricle	Posterior and Right	Anterior and Left	Anterior and Left
Left Ventricle	Anterior and Left	Posterior and Right	Posterior and Right
Aortic annulus position relative to pulmonary annulus	Posterior and Right if no transposition Right and anterior if transposition	Anterior and Left	Anterior and Left
Pulmonary trunk	Passes to left of aorta and dips posteriorly	Passed to Right of aorta and dips posteriorly	Passes to Right of aorta and dips posteriorly
With transposition convexity of ascending aorta	Right	Left	

Table 1 Summary of finding from Lev, Liberthson et al, 1968⁹, Note in patients with mixed dextrocardia in this series all patients had ventricular inversion with atria as situs, there was no case with atrial inversion and ventricle as pivot

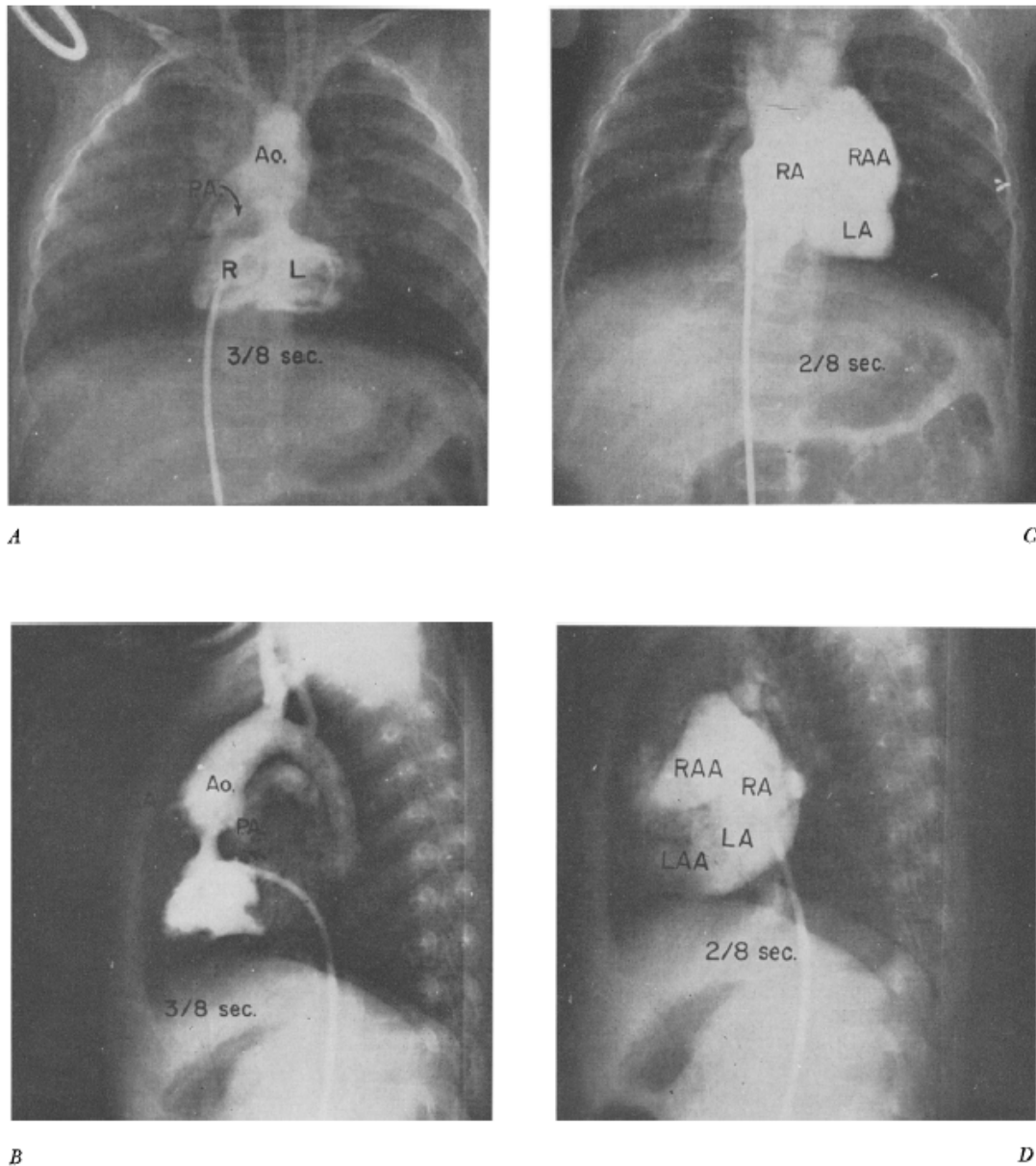


Figure 8 Incomplete dextroversion (Type IIb) with a large ventricular septal defect, atrial septal defect, overriding aorta, pulmonary infundibular stenosis, and juxtaposed atrial appendages. A, Anteroposterior view. Selective injection of contrast substance into the right ventricle with immediate opacification of the right (RV) and left (LV) ventricles and no identifiable septum. Small pulmonary artery (PA) arises from the right ventricle through an infundibular stenosis (see arrow). The aorta is at the midline and originates mostly from the left ventricle. B, Lateral view of same showing the anterior and superior location of the aorta compared to the pulmonary artery. Arrow points to infundibular stenosis. C, Anteroposterior view. Selective injection of contrast substance into the right atrium with immediate filling of the right (RA) and left (LA) atria. Note abnormal location of right atrial appendage (RAA) on the left side and above the left atrial appendage (LAA). D, Lateral view demonstrating the abnormal position of the atrial appendages. The 2 atria are situated well behind the still unopacified ventricular chambers. Arcilla and Gasul, 1961¹

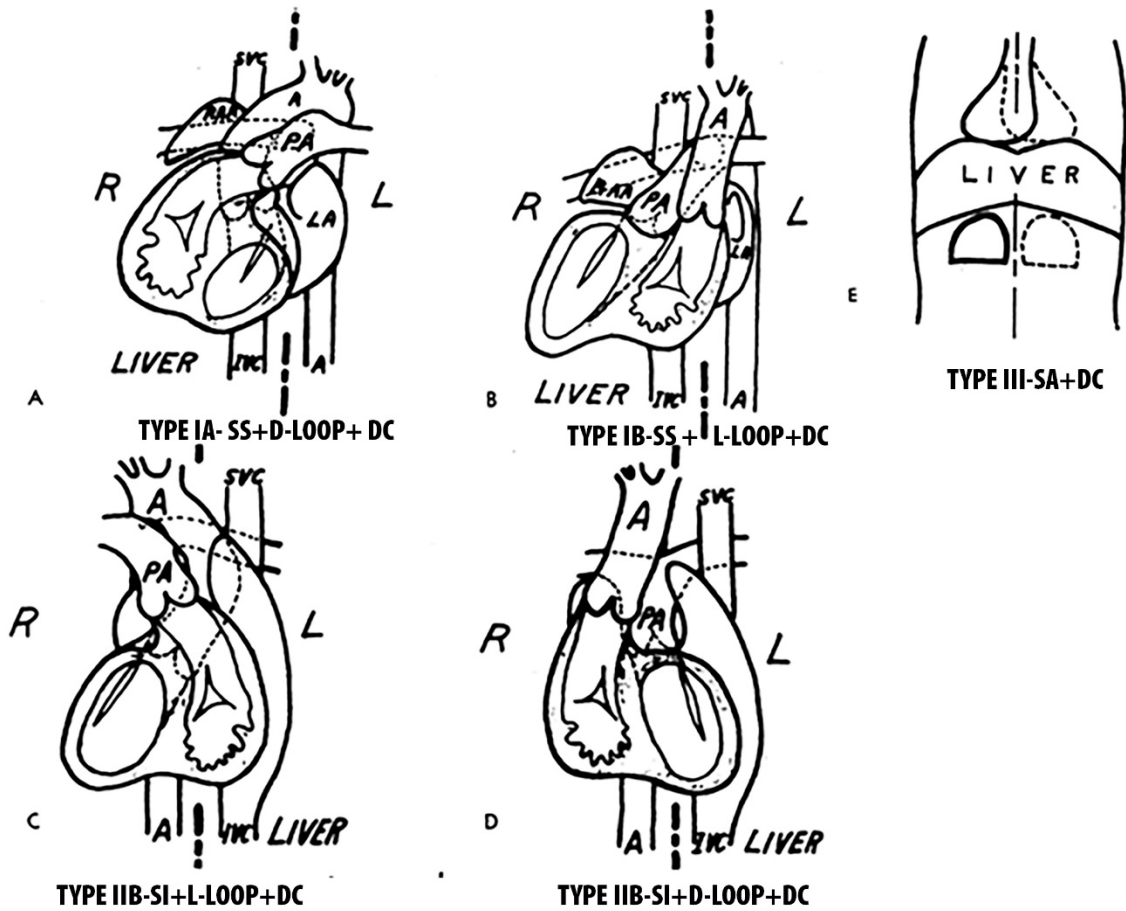


Figure 9 by Ellis, Fleming et al, 1966 – Figure A Type IA Situs solitus (SS) + D-loop of ventricles+ Dextrocardia (DC); Figure B Type IB Situs solitus (SS) + L-loop of ventricles+ Dextrocardia (DC); Figure C Type IIA Situs inversus (SI) + L-loop of ventricles+ Dextrocardia (DC) Classification of dextrocardia); Figure D Type IIB Situs inversus (SI) +D-loop of ventricles + Dextrocardia (DC); Figure E Type III Situs ambiguus (SA) + Dextrocardia (DC)

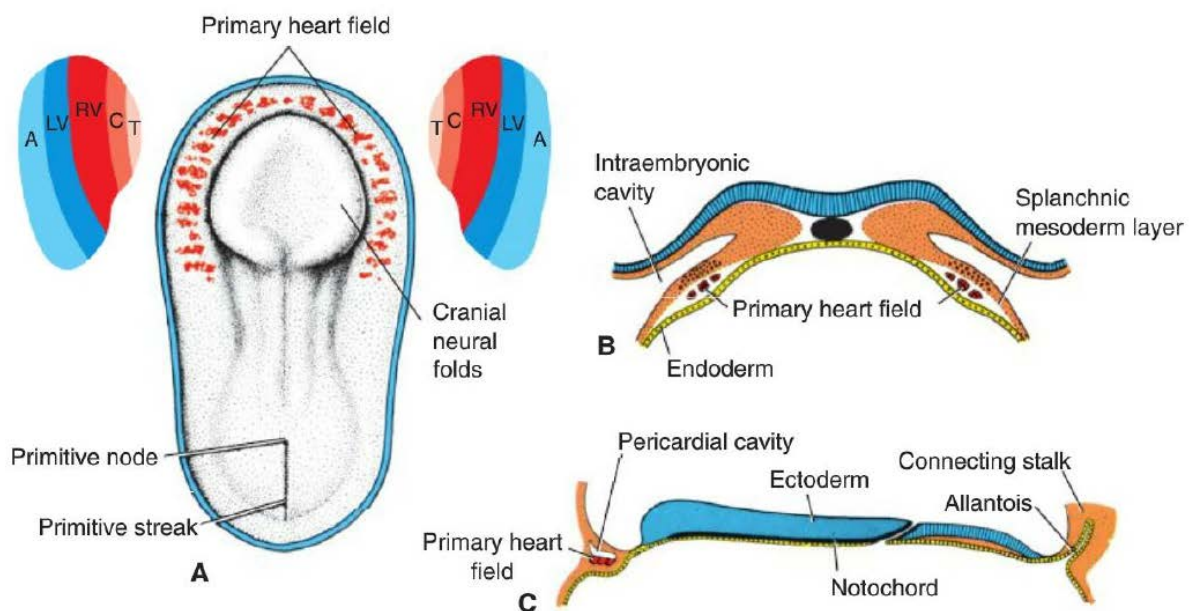
Embryology of Dextrocardia

Following are the events listed in sequential order

- Progenitor Heart cells: middle of third week (Day 16)- epiblast (cranial end of primitive streak)
- Primary Heart field (Day 18)-splanchnic layer of lateral plate mesoderm (horse shoe shaped cluster)-atria, left ventricle, and part of the right ventricle.
- Secondary Heart Field-splanchnic mesoderm ventral to the pharynx-remainder of the right ventricle and outflow tract (conus cordis and truncus arteriosus) and atria at caudal end of heart including sinus venosus
- Laterality of embryo also occurs during this period-Day 16 i.e. the right half exhibits right developmental potentialities and the left half exhibits left developmental potentialities. See Figure 12. Genetics of left sided laterality genes has been extensively studied and PITX2 gene has been found to be the master gene for laterality of left sided structures, right sided laterality genes are not yet clearly elucidated.
- Rotation of cardiac apex: In the early stages of fetal life with situs solitus and formation of a D-bulboventricular loop, the apex of the heart is in the right hemithorax. At the end of the 9th week of fetal life, the apex of the heart migrates from the right thorax to the left Ellis, Fleming *et al*, 1966⁷, Licata, 1954¹⁰. If it is L-bulboventricular loop, apex is initially in left hemithorax in early fetal life and subsequently it migrates to right hemithorax, due to this reason patients with L-transposition of great arteries are more likely to have dextrocardia.
- Rotation of apex of the heart has also been documented by fetal echocardiogram in the study done by McBrien, Howley *et al*, 2013¹¹. They did serial fetal echocardiogram of pregnant females between 8th week of pregnancy to 15th week of pregnancy and documented an fetal cardiac axis (defined as the angle between midline of the chest

(from the middle of the anterior chest wall to the center of the vertebral body) and the plane of the interventricular septum) shift to left in these patients from $25.5 \pm 11.5^\circ$ to $40.4 \pm 9.2^\circ$ by 12th week of pregnancy and then remains stable thereafter.

- In general, regardless of atrial situs, all D-bulbo-ventricular loops should end development with the heart in the left hemithorax (levocardia), and all L-bulbo-ventricular loops should become dextrocardia. Failure of this shift of the ventricular apex can result in dextrocardia with situs solitus (termed “dextroversion”) or levocardia with situs inversus (termed “laevoversion”)



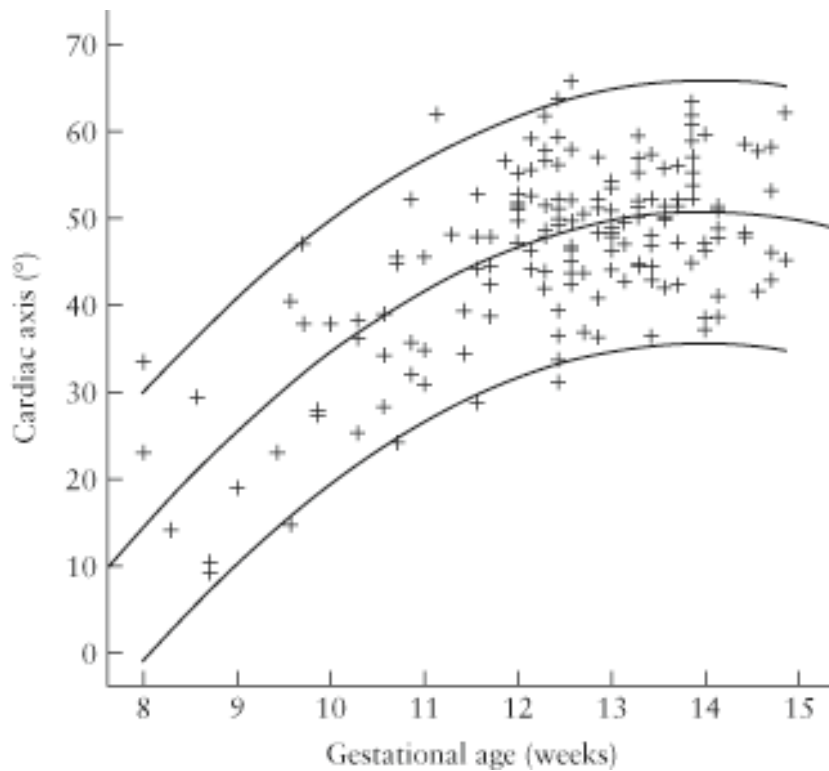


Figure 10 Scatterplot demonstrating fetal cardiac axis measurements according to gestational age. Quadratic line of best fit (R^2 quadratic = 0.482) and 95% range are indicated. McBrien, Howley et al, 2013¹¹

Sequence of Events in Looping

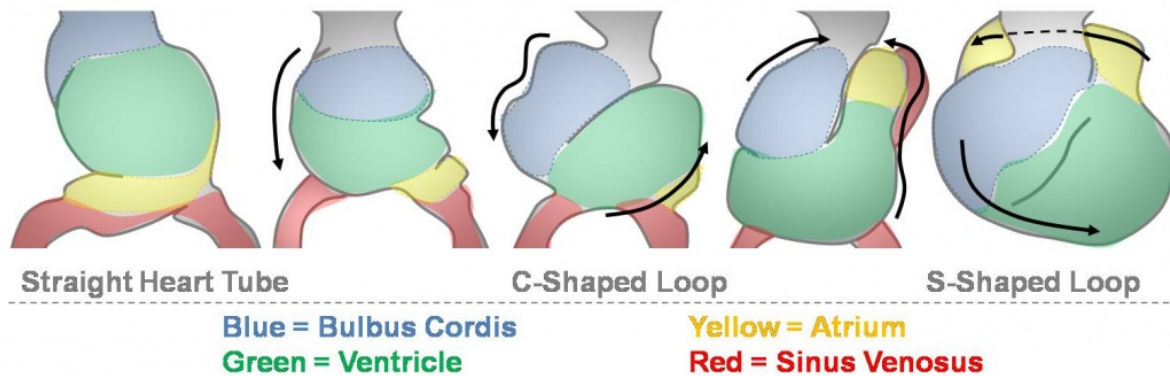


Figure 11 In situs solitus, during the 8th week of gestation, the cardiac apex is directed to the right and during the 8th week it is progressively displaced until it reaches its normal left-sided position for this situs (Licata, 1954).

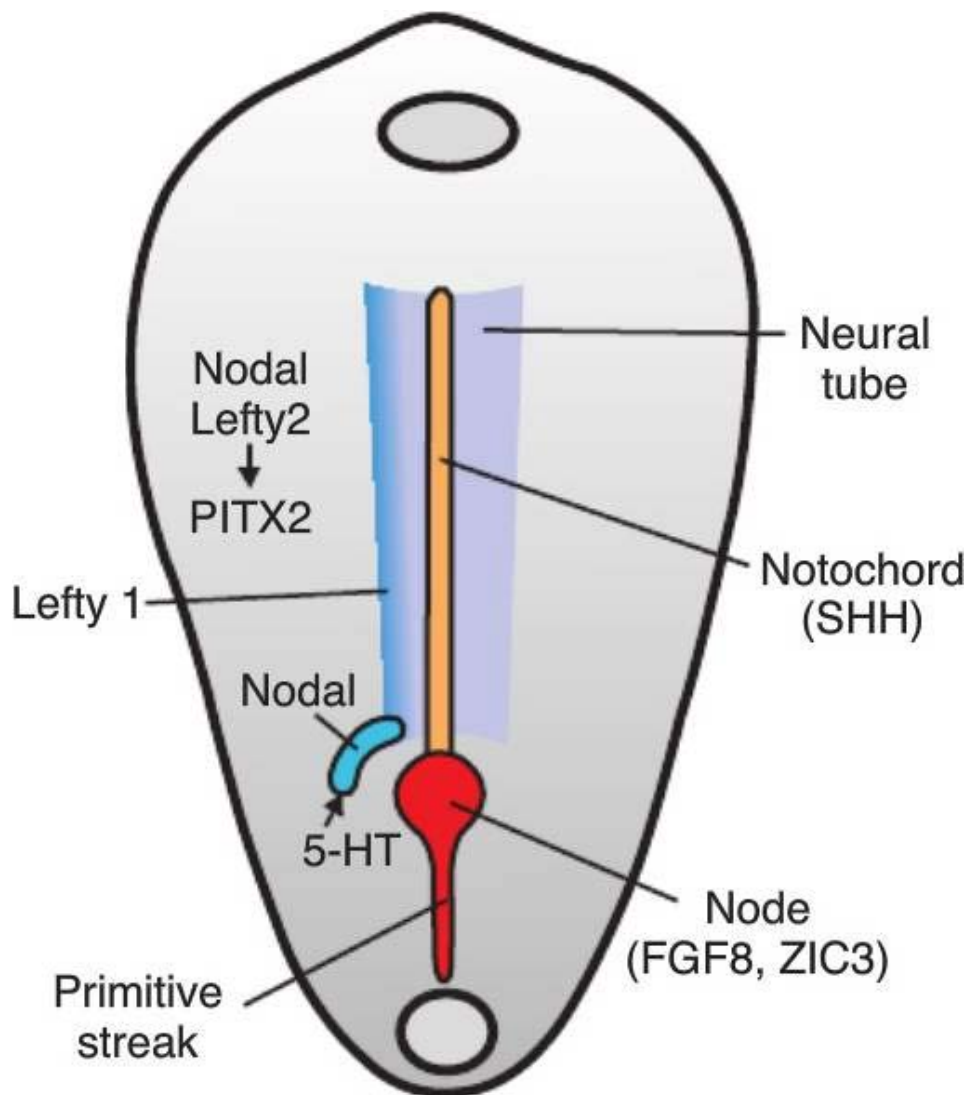


Figure 12 Dorsal view of a drawing of a 16-day embryo showing the laterality pathway. The path way is expressed in lateral plate mesoderm on the left side and involves a number of signaling molecules, including serotonin (5-HT), which result in signaling of the transcription factor MAD3, which restricts Nodal expression to the left where this gene initiates expression of the transcription factor PITX2, the master gene for left sidedness. This pathway specifies the left side of the body and also programs heart cells in the primary and SHFs. The right side is specified as well, but genes responsible for this patterning have not been completely determined. Disruption of the pathway on the left results in laterality abnormalities, including many heart defects; SSRI HAVE BEEN IMPLICATED IN EPIDEMIOLOGIC STUDIES

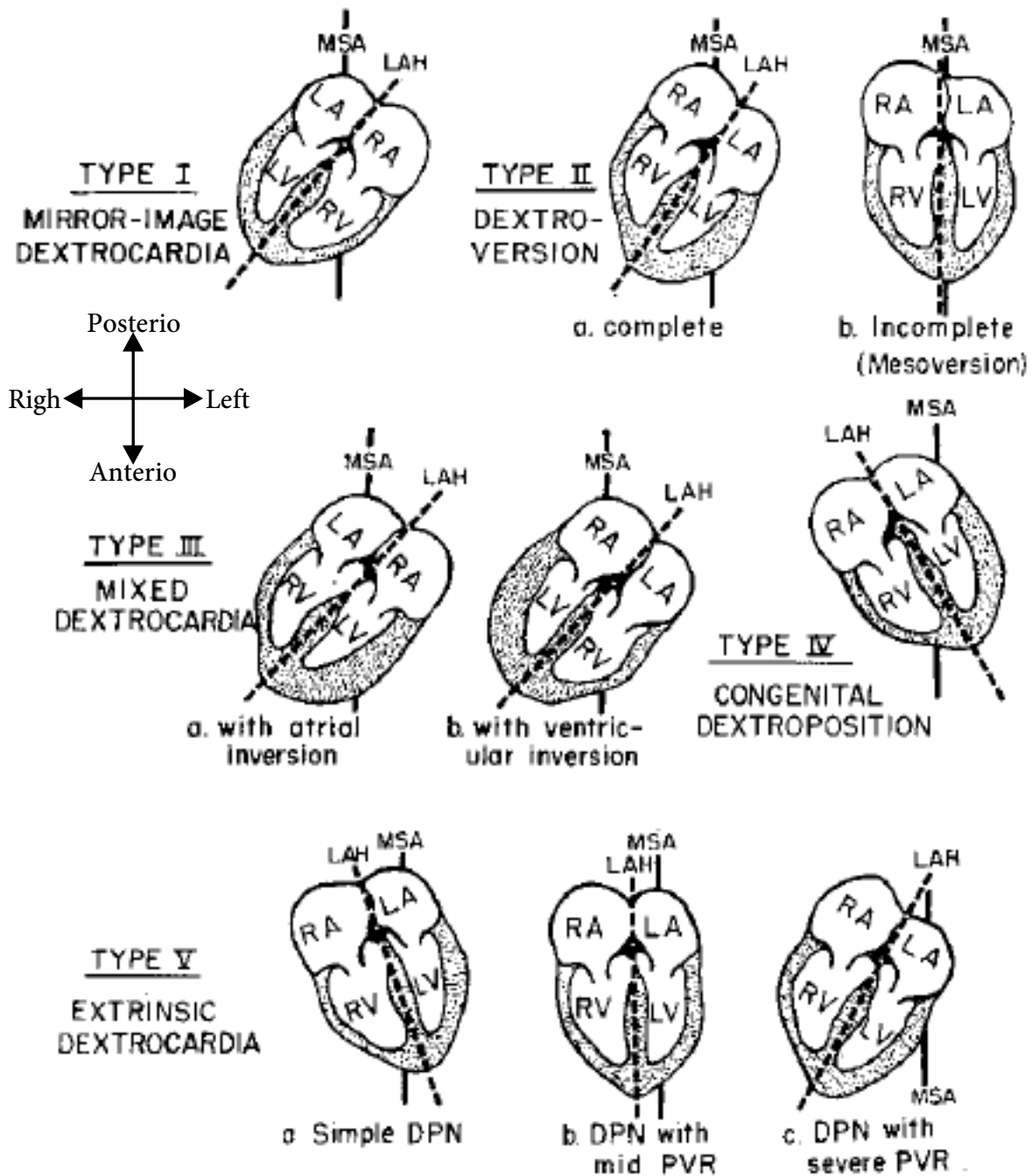


Figure 13 Classification of diagram and position of the heart and arrangement of its chambers in the various types of dextrocardia. The angle (A°) formed by the longitudinal axis of the heart (LAH) with- the midsagittal axis of the chest (MSA) in the horizontal plane indicates the degree of cardiac heterotaxy: A transverse section of the chest demonstrating the position and chamber arrangement of a normally placed heart is presented for comparison. DPN=dextro-position; PVR=pivotal rotation. Adapted from Arcilla and Gasul, 1961¹

MATERIALS AND METHODS

- Retrospective cross sectional study
- Duration-20yrs
- Total of 1322 records were scanned by using the search term Dextrocardia, 746.8D, 745.1DGA, DC, DX
- 3 patient were excluded because no data was not available
- N=390

Patients of dextrocardia will be searched from SCTIMST database of our out-patient and inpatient records over last 20 years. Patients in whom appropriate investigations for diagnosis of situs were present will be included in the study. Standard criteria for diagnosis of situs will be used as detailed in review of literature.

Detailed segmental analysis for cardiac anatomy and associated malformations will be done using previously suggested and well accepted terms and definitions. Cardiac situs will be confirmed by chest X ray, USG, catheterization, CMRI/CT and during surgery.

Atrio-ventricular cushion defect and atrio-ventricular valve atresia, if present with transposed aorta will be classified as SV of LV/RV morphology depending on the unbalance.

Definitions

Although detailed description of terms will be discussed in review of literature, here in this section we will be discussing certain terms which we have used practically in this study.

Dextrocardia: It is defined as condition when the base to apex axis of heart is pointing to the right side as seen from echocardiogram. Van Praagh, Van Praagh *et al*, 1964¹⁷ Definition is not be used in this study (which refers to the right sided position of heart, in right hemithorax as seen on chest X-ray), because it will include various extra-cardiac lung pathologies, kindly refer to Review of Literature for further discussion. The angle between mid-sagittal axis and longitudinal axis of heart (as defined by Arcilla and Gasul, 1961¹) will also not be measured in this study because sufficient data is not available in this regard due to the retrospective nature of this study.

Transposition of great arteries (TGA)- Refers to the condition in which antero-posterior relation of great arteries is changed, i.e. aortic annulus is anterior to pulmonary annulus irrespective of situs. When aortic annulus is right and anterior it will be called as D-TGA (D-Posed), when it is left and anterior it will be termed as L-TGA (L-Posed), lastly when it is just anterior to pulmonary annulus it will be called as Z-TGA (Zero-Posed). (Squarcia, Ritter *et al*, 1973¹⁵)

It is important to note that TGA will refer only to anatomic position of aortic annulus in relation to pulmonary annulus, it will not be considered synonymous as physiological complete or corrected TGA because, both D-transposition or L-transposition may or may not be complete relative to the position of ventricular septum (Van Praagh, Van Praagh *et al*, 1964¹⁷).

Situs solitus (De la Cruz, Anselmi *et al*, 1971⁶) Characterized by an anatomical right atrium, the greater lobe of the liver, and the supra-hepatic segment of the inferior vena cava being placed on the right. Position of gastric fundus bubble to left side on Chest X-ray will also be considered among the diagnostic criterion.

Situs inversus (De la Cruz, Anselmi *et al*, 1971⁶) Characterized by an anatomical right atrium, greater lobe of the liver, and the supra-hepatic portion of the inferior vena cava being placed to the left. Position of gastric fundus bubble to the right side will also be considered among the diagnostic criterion.

Situs Ambiguus when above definition is not fulfilled i.e. atrio-visceral discordance is present it is called as situs ambiguus. Further classification into asplenia (Right atrial isomerism-RAI) or polysplenia (Left atrial isomerism) will considered in those patients only in whom

appropriate Ultra-sonogram of abdomen, catheterization, MRI/CT or surgical finding will be present. Otherwise it will be classified as unidentified atrial isomerism (UAI).

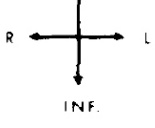
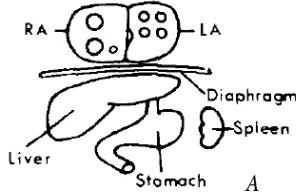
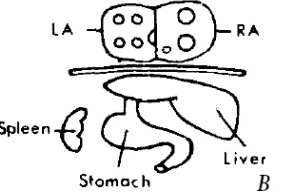
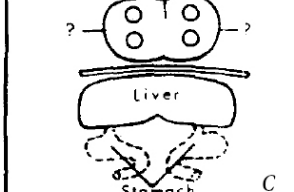
TYPE	SOLITUS	INVERSUS	ASPLENIA
SUP  ANTERIOR VIEW	(ORDINARY, ie., NORMAL)  Liver Stomach Spleen A	(MIRROR IMAGE of SOLITUS)  Liver Stomach Spleen B	(UNCERTAIN SITUS)  Liver Stomach C

Figure 14 showing viscerο-atrial situs: A-Situs solitus, B-Situs inversus, C-Situs ambiguus Van Praagh, Van Praagh et al, 1964¹⁷

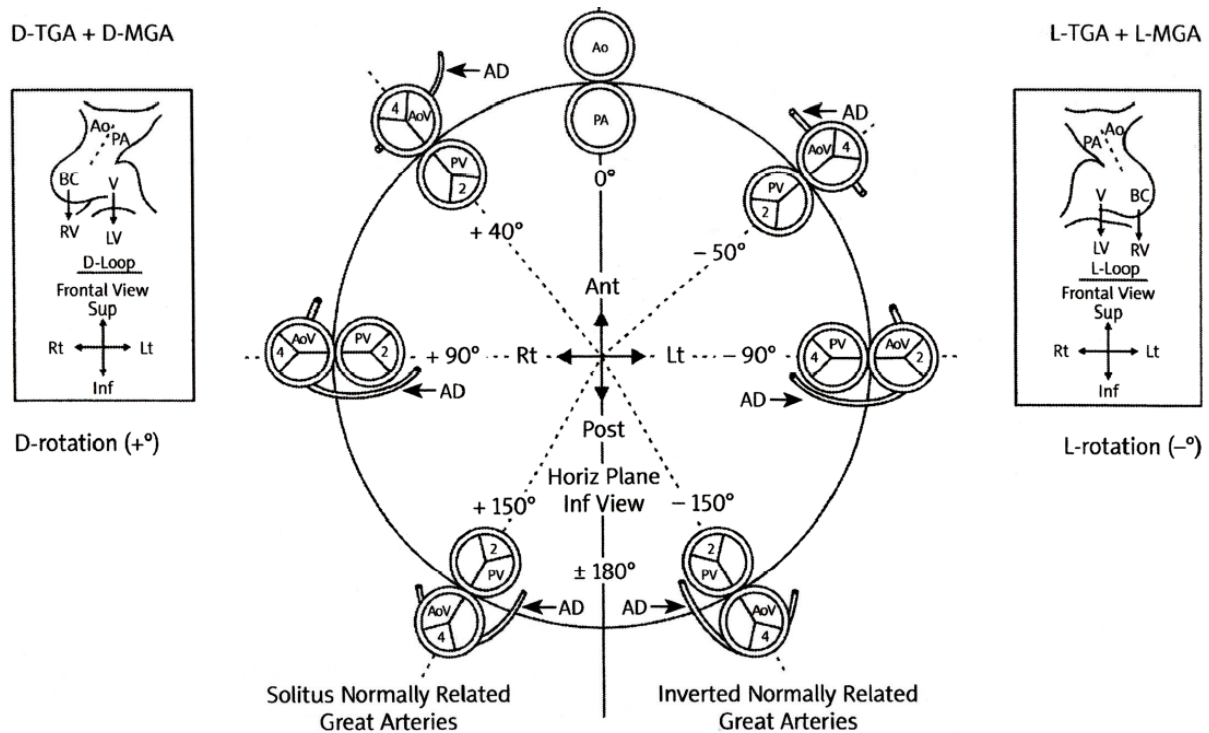


Figure 15 showing various position of aortic annulus in relation to pulmonary annulus.

Segmental Analysis (Calcaterra, Anderson et al, 1979⁴)- Refers to systematic analysis by echo and other relevant investigations. It starts from identification of situs, location of aorta and inferior vena cava in abdomen, venous drainage to atrium, atrial morphology, type of atrio-

ventricular valve (AVV) (i.e. two valves, common valve, or single valve atresia), atrio-ventricular connection (concordant, discordant, univentricular common AVV, univentricular single AVV atresia), ventriculo-arterial connection (concordant, discordant, double outlet right ventricle, double outlet left ventricle, single outlet pulmonary atresia), Position of aortic annulus in relation to pulmonary annulus (anterior, right anterior, left and anterior, right side by side, left side by side, posterior, right and posterior, left and posterior)

Data collection

All the data collection will be done by the principal investigator

Patients of dextrocardia will be searched from SCTIMST database of our out-patient and inpatient records over last 10 years. Patients in whom appropriate investigations for diagnosis of situs were present will be included in the study. Standard criteria for diagnosis of situs will be used. Detailed segmental analysis for cardiac anatomy and associated malformations will be done using previously suggested and well accepted terms and definitions. Cardiac situs will be confirmed by chest X ray, USG, catheterization, CMRI/CT and during surgery.

Following parameters (Nominal Data) will be noted from the database

1. Age of the patient
2. Sex of the patient.
3. Situs of the patient: Solitus/Inversus/Ambiguous
4. Pulmonary venous drainage: normal/abnormal
5. Systemic venous drainage: normal/abnormal
6. Atrio ventricular concordance: Concordant/Non-concordant
7. Ventriculo-arterial concordance: Concordant/Non-concordant
8. Great artery relationship: Normal/D-TGA/L-TGA/DORV
9. Right Ventricular outflow obstruction: Yes/No
10. Left Ventricular outflow obstruction: Yes/No
11. Arch of aorta: Left/Right
12. Superior Vena Cava: Right/Left/Bilateral
13. Atrial Septal Defect: Yes/No
14. Ventricular Septal Defect: Yes/No
15. Patent Ductus Arteriosus: Yes/No

16. Pulmonary Blood flow: Yes/No

17. Complete Diagnosis

Statistical Analysis

All analysis will be done by principal investigator using IBM SPSS v23.0.

Descriptive analysis will be done.

All the variables in this study are categorical variable except age.

Chi square and Kruskal wallis test will be used to analyze categorical variables. Using this data we will generate the proportion of situs in patients with dextrocardia.

Data will be analyzed as dextrocardia ungrouped and then it will be analyzed as dextrocardia grouped according to situs. Situs ambiguus will further be analyzed as Right atrial isomerism, Left atrial isomerism or unidentified atrial isomerism.

Missing data will also be shown wherever relevant.

A comparison of morphological findings of situs inversus and dextrocardia will be done.



श्री चित्रा तिरुनाल आयुर्विज्ञान और प्रौद्योगिकी संस्थान, त्रिवेन्द्रम
तिरुवनन्तपुरम - ६९५०११, केरल, इंडिया
SREE CHITRA TIRUNAL INSTITUTE FOR MEDICAL SCIENCES AND TECHNOLOGY, TRIVANDRUM
Thiruvananthapuram - 695 011, Kerala, India
(An Institute of National Importance under Govt. of India)

Grams : Chitramet, Phone : +91-471-2443152, Fax : +91-471-2550728 / 2446433, E-mail : sct@sctimst.ac.in, Website : www.sctimst.ac.in

Institutional Ethics Committee (IEC Regn No. ECR/189/Inst/KL/2013)

SCT/IEC/1060/JUNE-2017

15.09.2017

Dr. Suyash Tripathi
Resident
Department of Cardiology
SCTIMST, Thiruvananthapuram

Dear Dr. Suyash Tripathi,

The Institutional Ethics Committee reviewed and discussed your application to conduct the study entitled "EVALUATION OF CARDIAC ANATOMY AND MALFORMATION IN PATIENTS WITH DEXTROCARDIA-A RETROSPECTIVE STUDY (IEC/1060)" on 17th June, 2017.

The following documents were reviewed:

Original submission

1. Covering Letter addressed to the Chairman, IEC, SCTIMST dated 25.05.2017 with checklist
2. TAC Approval Letter
3. IEC Application Form
4. Project Proposal
5. Protocol
6. Declaration form
7. CV of Principal Investigator and Co-Principal Investigators

Revised submission

1. Covering Letter addressed to the Chairman, IEC, SCTIMST dated 14.09.2017 with checklist
2. TAC Approval Letter
3. IEC Application Form
4. Project Proposal
5. Protocol
6. Declaration form
7. Copy of IEC Recommendations Letter dated 06.07.2017
8. CV of Principal Investigator and Co-Principal Investigators

Page 1 of 2

The following members of the Ethics Committee were present at the meeting held on 17th June, 2017 at G. Parthasarathi Board Room, AMCHSS, SCTIMST

SL. No.	Member Name	Highest Degree	Gender	Scientific /Non Scientific	Affiliation with Institution(s)
1.	Dr. R V G Menon	M Tech, PhD	Male	Lay Person (Chairman)	No
2.	Dr. Lekha Pandit	MD. DM Neurology, PhD (Bioscience)	Female	Clinician	No
3.	Dr. Kala Kesavan. P	MBBS, MD	Female	Basic Medical Scientist	No
4.	Dr. Rema M. N	MD	Female	Basic Medical Scientist	No
5.	Dr. S S Giri Sankar	LL.M. Ph.D.	Male	Legal Expert	No
6.	Dr. Aneesh V Pillai	BA. LLB (Hons.), LLM, Ph. D, SET (Law)	Male	Legal Expert	No
7.	Mr. Satheesh Chandran	MSW, PGDPM	Male	Lay person/ NGO/ Social Scientist	No
8.	Smt. Sathi Nair	MA (English Literature)	Female	Lay Person	No
9.	Dr. P. Manickam	BSMS, MSc (Epid), PhD	Male	Health Science Expert/ Social Scientist	No
10.	Dr. Christina George	MD Psychiatry	Female	Clinician	No
11.	Dr. V. Raman Kutty	M D, M Phil, M P H	Male	Health Sciences Expert/Clinician	Yes
12.	Dr. K R S Krishnan	M.E., Ph.D.	Male	Medical Technology	Yes
13.	Dr. Hari Krishna Varma PR	Ph.D(Materials Science)	Male	Medical Technology	Yes
14.	Dr. Hari Krishnan S	MD, DM (Cardiology) DNB (Cardiology)	Male	Clinician	Yes
15.	Dr. Mala Ramanathan	PhD	Female	Social Scientist (Member Secretary)	Yes

IEC Decision


The IEC approved the conduct of the study in the present form.

Remarks:

The Institutional Ethics Committee expects to be informed about the progress of the study, any SAE occurring in the course of the study, any changes in the protocol and patient information/informed consent and asks to be provided a copy of the final report.

There was no member of the study team who participated in voting / decision making process. The ethics committee is organized and operated according to the requirements of Good Clinical Practice and the requirements of the Indian Council of Medical Research (ICMR).

Sincerely,



Mala Ramanathan
Member Secretary, IEC

RESULTS

Results will be analyzed as total group of dextrocardia and they will be further analyzed by splitting the data according to situs.

- 43.6 % were females
- Mean age 8.3 ± 15.3 yrs (Minimum 1 day to maximum of 72yr)
- Median age 0.98 yrs
- Mode is 7.01yrs

Total n=378 patients were in the study, of them 43.1% were in situs solitus, 38.1% were in situs inversus, 18.8% were in situs ambiguus (see [Table 2](#))

Situs	Total (n=378)
Situs Solitus	163 (43.1%)
Situs Inversus	144 (38.1%)
Situs Ambiguus	71 (18.8%)

Table 2 Distribution of situs in patients with dextrocardia

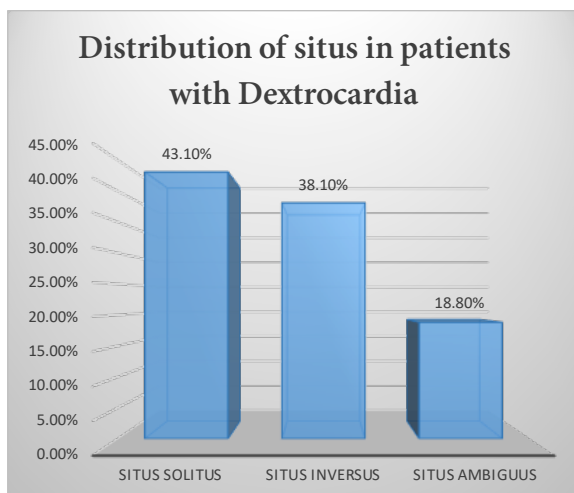


Figure 16 Showing percentage distribution of situs among patients with dextrocardia

Morphological characteristics	Situs			Total n=378
	Situs Solitus n=163	Situs Inversus n=144	Situs Ambiguus n=71	
Pulmonary Blood Flow				
Normal / Increased	53 (32.5%)	67 (46.5%)	19 (26.8%)	139 (36.8%)
Decreased	110 (67.5%)	77 (53.5%)	52 (73.2%)	239 (63.2%)
Pulmonary Outflow Obstruction				
Present	110 (67.5%)	77 (53.5%)	52 (73.2%)	239 (63.2%)
Aortic Annulus Position in relation to Pulmonary annulus				
Aorta Anterior	9 (5.5%)	6 (4.2%)	9 (12.7%)	24 (6.3%)
Aorta Right and Anterior	20 (12.3%)	24 (16.7%)	16 (22.5%)	60 (15.9%)
Aorta Left and Anterior	79 (48.5%)	35 (24.3%)	21 (29.6%)	135 (35.7%)
Aorta to Right	3 (1.8%)	7 (4.9%)	1 (1.4%)	11 (2.9%)
Aorta to Left	8 (4.9%)	6 (4.2%)	5 (7.0%)	19 (5.0%)
Aorta Posterior	1 (0.6%)	0 (0.0%)	0 (0.0%)	1 (0.3%)
Aorta Right and Posterior	31 (19.0%)	2 (1.4%)	1(1.4%)	34 (9.0%)
Aorta Left and Posterior	4 (2.5%)	60 (41.7%)	8 (11.3%)	72 (19.0%)
Missing	8 (4.9%)	4 (2.8%)	10 (14.1%)	22 (5.8%)
Pulmonary Venous Drainage				
Abnormal	5 (3.1%)	12 (8.3%)	31 (43.7%)	48 (12.7%)
Systemic Venous Drainage				
Abnormal	5 (3.1%)	14 (9.7%)	34 (47.9%)	53 (14.0%)
Mode of Atrio-Ventricular connection				
Two Atrioventricular Valve	120 (73.6%)	107 (74.3%)	25 (35.2%)	252 (66.7%)
Common Atrioventricular Valve	20 (12.3%)	21 (14.6%)	41 (57.7%)	82 (21.7%)
Single Atrioventricular Valve	23 (14.1%)	16 (11.1%)	5 (7.0%)	44 (11.6%)
Atrio-ventricular Connection				
Concordant	62 (38.0%)	96 (66.7%)	23 (32.4%)	181 (47.9%)
Discordant	55 (33.7%)	15 (10.4%)	3 (4.2%)	73 (19.3%)
Univentricular Double Inlet	21 (12.9%)	16 (11.1%)	41 (57.7%)	78 (20.6%)
Univentricular Single valve Atresia	24 (14.7%)	17 (11.8%)	4 (5.6%)	45 (11.9%)

Continued to next page.....

Missing	1 (0.6%)	0 (0.0%)	0 (0.0%)	1 (0.3%)
Ventriculoarterial Connection				
Concordance	44 (27.0%)	65 (45.1%)	25 (35.2%)	134 (35.4%)
Discordance	49 (30.1%)	25 (17.4%)	11 (15.5%)	85 (22.5%)
Double Outlet Right Ventricle	37 (22.7%)	31 (21.5%)	21 (29.6%)	89 (23.5%)
Double Outlet Left Ventricle	14 (8.6%)	9 (6.3%)	4 (5.6%)	27 (7.1%)
Single Outlet Pulmonary Atresia	19 (11.7%)	14 (9.7%)	10 (14.1%)	43 (11.4%)
Aortic Outflow Obstruction				
Present	2 (1.2%)	6 (4.2%)	2 (2.8%)	10 (2.6%)
Arch				
Left	123 (75.5%)	44 (30.6%)	30 (42.3%)	197 (52.1%)
Right	20 (12.3%)	80 (55.6%)	29 (40.8%)	129 (34.1%)
Missing	20 (12.3%)	20 (13.9%)	12 (16.9%)	52 (13.8%)
Superior Vena Cava				
Right sided	71 (43.6%)	27 (18.8%)	9 (12.7%)	107 (28.3%)
Left sided	13 (8.0%)	45 (31.3%)	18 (25.4%)	76 (20.1%)
Bilateral	39 (23.9%)	29 (20.1%)	40 (56.3%)	108 (28.6%)
Missing	40 (24.5%)	43 (29.9%)	4 (5.6%)	87 (23.0%)
Atrial Septal Defect				
Present	87 (53.4%)	67 (46.5%)	66 (93.0%)	220 (58.2%)
Missing	2 (1.2%)	1 (0.7%)	0 (0.0%)	3 (0.8%)
Ventricular Septal Defect				
Present	127 (77.9%)	101 (70.1%)	62 (87.3%)	290 (76.7%)
Patent Ductus Arteriosus				
Present	44 (27.0%)	27 (18.8%)	22 (31.0%)	93 (24.6%)
Missing	1 (0.6%)	0 (0.0%)	0 (0.0%)	1 (0.3%)

Table 3 Table showing morphologic characteristics of patient with dextrocardia as a whole group and divided into each situs

Table 3 shows the morphological characteristics of patients with dextrocardia. Overall 63.2% patients had decreased pulmonary blood flow if grouped according to situs these figures were 67.5%, 53.5% and 73.2% in situs solitus, inversus and ambiguus respectively.

Pulmonary venous drainage abnormality was seen in overall 12.7% of the patients, these figures were 3.1%, 8.3% and 43.7% in situs solitus, inversus and ambiguus respectively. Similarly systemic venous drainage was 47.9% in situs ambiguus.

Common atrioventricular valve was seen in 21.7% of patients with dextrocardia these figures were 12.3%, 14.6% and 57.7% in situs solitus, inversus and ambiguus respectively, suggesting high possibility of atrioventricular canal defect in situs ambiguus. They are very less in situs solitus and inversus.

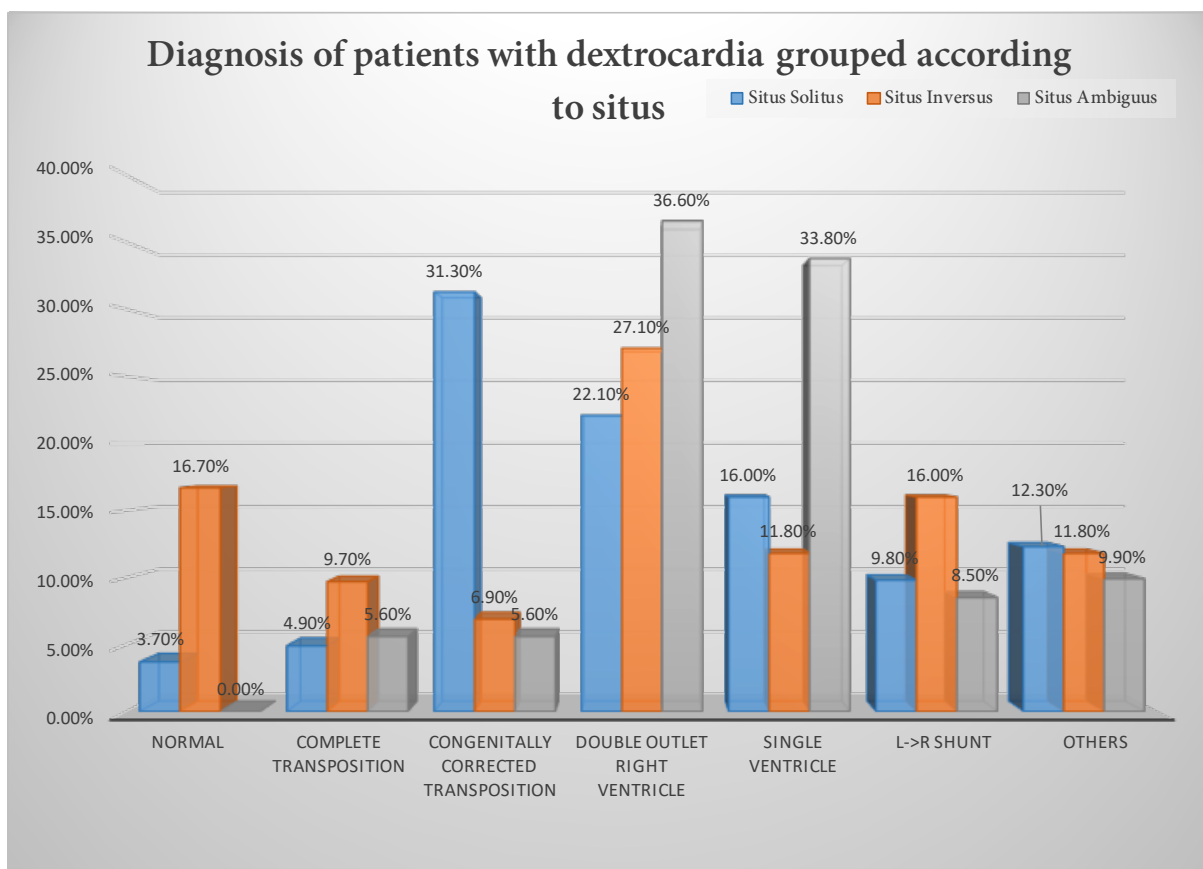


Figure 17 Diagnosis of patients grouped according to situs. Others include criss-cross heart, Truncus arteriosus, Single atrio-ventricular valve atresia, Common atrio-ventricular defect see Table 8, Table 10 and Table 12 for further details.

Figure 17 shows most common diagnosis in patients with SS is CC-TGA followed by DORV, while in SI, most common diagnosis is DORV, followed by structurally normal heart and Left to right shunt. In patients with SA, DORV is most common diagnosis.

Morphological Characteristics	Situs		p-value	χ^2	df
	Situs solitus n=163	Situs Inversus n=144			
Diagnosis					
Normal	6 (3.7%)	24 (16.7%)	<0.01	10.8	1
Complete Transposition of great arteries	8 (4.9%)	14 (9.7%)	0.20	1.64	1
Congenitally corrected transposed great arteries	51 (31.3%)	10 (6.9%)	<0.01	22.6	1
Double outlet Right ventricle	36 (22.1%)	39 (27.1%)	0.73	0.12	1
Atrio-ventricular cushion defect with NRGAs	4 (2.5%)	4 (2.8%)	-	-	-
Atrio-ventricular valve defect with NRGAs	2 (1.2%)	2 (1.4%)	-	-	-
Single Ventricle	26 (16%)	17 (11.8%)	0.17	1.9	
Left→Right shunt (ASD/VSD/PDA)	16 (9.8%)	23 (16%)	0.26	1.3	
Tetralogy of Fallot (VSD+PS/PA) with NRGAs	10 (6.1%)	10 (6.9%)	1.00	0.00	
Others	4 (2.5%)	1 (0.7%)	-	-	-
Looping of ventricles					
D-Loop	65 (39.9%)	25 (17.4%)	<0.01	17.8	1
L-Loop	91 (55.8%)	105 (72.9%)	0.31	1.00	1
x-Loop	1 (0.6%)	11 (7.6%)	-	-	-
Missing	6 (3.7%)	3 (2.1%)	-	-	-
Pulmonary Blood Flow					
Normal / Increased	53 (32.5%)	67 (46.5%)	0.20	1.63	1
Decreased	110 (67.5%)	77 (53.5%)	0.02	5.82	1
Pulmonary Outflow Obstruction					
Present	110 (67.5%)	77 (53.5%)	0.02	5.82	1
Aortic Annulus Position in relation to Pulmonary annulus					
Aorta Anterior	9 (5.5%)	6 (4.2%)	0.44	0.60	1
Aorta Right and Anterior	20 (12.3%)	24 (16.7%)	0.55	0.37	1
Aorta Left and Anterior	79 (48.5%)	35 (24.3%)	<0.01	16.9	1
Aorta to Right	3 (1.8%)	7 (4.9%)	0.21	1.60	1

Continued to next page.....

Aorta to Left	8 (4.9%)	6 (4.2%)	0.59	0.29	1
Aorta Posterior	1 (0.6%)	0 (0.0%)	-	-	-
Aorta Right and Posterior	31 (19.0%)	2 (1.4%)	<0.01	25.5	1
Aorta Left and Posterior	4 (2.5%)	60 (41.7%)	<0.01	49.0	1
Missing	8 (4.9%)	4 (2.8%)	0.25	1.33	1
Pulmonary Venous Drainage					
Abnormal	5 (3.1%)	12 (8.3%)	0.09	2.88	1
Systemic Venous Drainage					
Abnormal	5 (3.1%)	14 (9.7%)	0.04	4.26	1
Mode of Atrio-Ventricular connection					
Two Atrioventricular Valve	120 (73.6%)	107 (74.3%)	0.39	0.71	1
Common Atrioventricular Valve	20 (12.3%)	21 (14.6%)	0.71	0.14	1
Single Atrioventricular Valve	23 (14.1%)	16 (11.1%)	0.27	1.19	1
Atrio-ventricular Connection					
Concordant	62 (38.0%)	96 (66.7%)	<0.01	7.31	1
Discordant	55 (33.7%)	15 (10.4%)	<0.01	22.9	1
Univentricular Double Inlet	21 (12.9%)	16 (11.1%)	0.41	0.68	1
Univentricular Single valve Atresia	24 (14.7%)	17 (11.8%)	0.27	1.19	1
Ventriculo-arterial Connection					
Concordance	44 (27.0%)	65 (45.1%)	0.04	4.05	1
Discordance	49 (30.1%)	25 (17.4%)	<0.01	7.78	1
Double Outlet Right Ventricle	37 (22.7%)	31 (21.5%)	0.47	0.53	1
Double Outlet Left Ventricle	14 (8.6%)	9 (6.3%)	0.29	1.09	1
Single Outlet Pulmonary Atresia	19 (11.7%)	14 (9.7%)	0.38	0.76	1
Aortic Outflow Obstruction					
Present	2 (1.2%)	6 (4.2%)	0.16	2.00	1
Arch sidedness					
Left	123 (75.5%)	44 (30.6%)	<0.01	37.4	1
Right	20 (12.3%)	80 (55.6%)	<0.01	36.0	1
Missing	20 (12.3%)	20 (13.9%)	1.0	0	1

Continued on next page.....

Superior Vena Cava					
Right sided	71 (43.6%)	27 (18.8%)	<0.01	19.8	1
Left sided	13 (8.0%)	45 (31.3%)	<0.01	17.7	1
Bilateral	39 (23.9%)	29 (20.1%)	0.23	1.47	1
Missing	40 (24.5%)	43 (29.9%)	0.74	0.11	1
Atrial Septal Defect					
Present	87 (53.4%)	67 (46.5%)	0.11	2.59	1
Missing	2 (1.2%)	1 (0.7%)	-	-	-
Ventricular Septal Defect					
Present	127 (77.9%)	101 (70.1%)	0.09	2.97	1
Patent Ductus Arteriosus					
Present	44 (27.0%)	27 (18.8%)	0.04	4.07	1
Missing	1 (0.6%)	0 (0.0%)	-	-	-

Table 4 showing comparison of morphological characteristics of patients with situs solitus versus situs inversus. All the percentage are column percent. However it is important to note that all the comparisons are based on row. The test of significance done is chi square test where ever applicable. In Superior vena cava and arch sidedness row large number of data are missing, but they not significantly different in both the groups hence the significant findings are likely to be correct. NPGA-Normally related great arteries.

Table 4 is showing statistical comparison of morphological characteristics of patient with situs solitus and situs inversus. Normal patients were more common in situs inversus while discordant looping i.e. congenitally corrected transposition is more common in situs inversus. D-looping is more common in situs solitus while there is no significant difference in L-loop in both the group. Pulmonary blood flow pattern was significantly more decreased in situs solitus as compared to situs inversus while normal/Increased pulmonary blood flow was similar in both the groups. Left -anterior and Right -posterior aortic annulus position is significantly more common in situs solitus as compared to situs inversus (48.5% vs 24.3% and 19% vs 1.4%) respectively. Whereas Left –posterior aortic position was significantly more common in situs inversus as compared to situs solitus (41.7% vs 2.5% respectively for each situs). Pulmonary venous drainage abnormality was similar in both the group while systemic venous drainage abnormality was more common in situs inversus (3.1% for solitus vs 9.7% for inversus).

Concordant atiro-ventricular connection is significantly more common in situs inversus (66.7%) as compared to situs solitus (38%). While discordant atrio-ventricular connection was more common in situs solitus (33.7%) as compared to situs inversus (10.4%). Similar to atrio-ventricular connection, concordant ventriculo-arterial connection was significantly more common in situs inversus (45.1%) as compared to situs solitus (27%). Whereas discordant ventriculo-arterial connection was significantly more common in situs solitus (30.1%) as compared to situs inversus (17.4%). Left sided arch is significantly more common in situs solitus (75.5%) as compared to situs inversus (30.6%). Whereas Right sided arch is significantly more common in situs inversus (55.6%) as compared to situs solitus (12.3%). It is important to that missing data is not significantly different in either category. Right sided Superior vena cava was significantly more common in situs solitus (43.6%) as compared to situs inversus (18.8%). Left sided superior vena cava is significantly more common in situs inversus (31.3%) as compared to situs solitus (8.0%). Again in this category also missing data is not significantly different in either category. Atrial septal defect and ventricular septal defect was similar in either group, while patent ductus arteriosus was significantly more common in situs solitus (27%) as compared to situs inversus (18.8%).

Situs	D-Loop (n=90)	L-Loop (n=196)	p-value	χ^2
Situs Solitus (n=163)	65 (39.9%)	91 (55.8%)	<0.01	144.8
Situs Inversus (n=144)	25 (17.4%)	105 (72.9%)	<0.01	183.2
Total	90 (23.8%)	196 (51.8%)		

Table 5 Showing the Looping of ventricles in patients with situs solitus and situs inversus. Percentage are row percent. It shows that L-Loop is more likely to occur in both situs solitus with dextrocardia and situs inversus with dextrocardia. It is also noteworthy that D-looping is still significantly more common in situs solitus with dextrocardia as compared to situs inversus with dextrocardia (see Table 4)

Table 5 shows that in patients with situs solitus L-looping (55.8%) was more common than D-looping (39.9%), but it is also important to note that if we compare in D-loops, situs solitus had more D-loops as compared to situs inversus (see Table 4). Also as expected, in situs inversus L-looping (72.9%) was significantly more than D-looping (17.4%).

Diagnosis in patients with dextrocardia (Ungrouped)	Pulmonary Blood Flow		
	Normal / Increased	Decreased	Total
	N=139	N=239	N=378
Normal	30 (21.6%)	0	30 (7.9%)
Complete Transposition	6 (4.3%)	20 (8.4%)	26 (6.9%)
Congenitally corrected transposition	17 (12.2%)	48 (20.1%)	65 (17.2%)
Double outlet Right ventricle	20 (14.4%)	81 (33.9%)	101 (26.7%)
Atrioventricular Canal Defects with NRGAs	8 (5.8%)	5 (2.1%)	13 (3.4%)
Atrio-ventricular valve atresia with NRGAs	1 (0.7%)	3 (1.3%)	4 (1.2%)
Single ventricle	10 (7.2%)	57 (23.8%)	67(17.7%)
Truncus arteriosus	1 (0.7%)	0 (0.0%)	1 (0.3%)
Left → Right Shunt (ASD/VSD/PDA)	45 (32.4%)	0 (0.0%)	45 (11.9%)
Tetralogy of Fallot	0 (0.0%)	22(9.2%)	22 (5.8%)
Others	1 (0.7%)	3 (1.3%)	4 (1.1%)

Table 6 Table showing diagnosis of patients with dextrocardia according to pulmonary blood flow. Note all the percentage are column percent. ASD-atrial septal defect, VSD-Ventricular septal defect, PDA-Patent ductus arteriosus, NRGAs- Normally related great arteries

Table 6 shows the diagnosis of patients with dextrocardia (Ungrouped). Overall of the total (n=378), decreased pulmonary blood flow was seen in 63.2 % (n=239) patients. 7.9% had no congenital heart abnormality. Complete transposition of great arteries was seen in 6.9% patients, congenitally corrected transpositions are seen in 17.2% patients. Double outlet right ventricle was seen in 26.7% and single ventricle was seen in 17.7% of the patients. Left to right shunt was seen 11.9% of the patients while tetralogy of fallot was seen in 5.8% of the patients.

Table 7 shows aortic annulus position in relation to pulmonary annulus in various patients with double outlet right ventricle divided according to situs. In situs solitus it can occur in all positions except left posterior position with majority of them occurring in left anterior (54.1%) and right anterior (27.0%) positions. In situs inversus it occurs in all positions with majority of them occurring in left anterior (45.2%).

Situs	Aortic annulus position relative to pulmonary annulus in patients with Double outlet Right ventricle								Missin g	Tot al
	Ant	R Ant	L Ant	Right	Left	R Post	L Post			
Solitus	1(2.7%)	10(27.0%)	20(54.1%)	2(5.4%)	1(2.7%)	1(2.7%)	0	2(5.4%)	37	
Inversus	2(6.5%)	3(9.7%)	14(45.2%)	3(9.7%)	4(12.9%)	1(3.2%)	2(6.5%)	2(6.5%)	31	
Ambiguous	1(4.8%)	8(38.1%)	7(33.3%)	0	3(14.3%)	0	1(4.8%)	1(4.8%)	21	
Total	4(4.5%)	21(23.6%)	41(46.1%)	5(5.6%)	8(9.0%)	2(2.2%)	3(3.4%)	5(5.6%)	89	

Table 7 Showing aortic annulus position in relation to pulmonary annulus in patients with double outlet Right ventricle grouped according to situs. Ant-anterior, Post-Posterior, R-Right, L-left.

Results in patient with situs solitus and dextrocardia

Diagnosis in patients with dextrocardia and situs solitus	Pulmonary Blood Flow		
	Normal /Increased n=53	Decreased n=110	Total n=163
Normal	6 (11.3%)	0 (0.0%)	6 (3.7%)
Complete Transposition	3 (5.7%)	5 (4.5%)	8 (4.9%)
Congenitally corrected transposition	12 (22.6%)	39 (35.5%)	51 (31.3%)
Double outlet Right ventricle	10 (18.9%)	26 (23.6%)	36 (22.1%)
Atrio-ventricular Canal Defects with NRGAs	2 (3.8%)	2(1.8%)	4 (2.5%)
Atrio-ventricular valve atresia with NRGAs	1 (1.9%)	1(0.9%)	2 (1.2%)
Single ventricle	2 (3.8%)	24 (21.8%)	26 (16.0%)
Left→Right Shunt (ASD/VSD/PDA)	16 (30.2%)	0 (0.0%)	16(9.8%)
Tetralogy of Fallot	0 (0.0%)	10 (9.1%)	10 (6.1%)
Others	1 (1.9%)¶	3 (2.7%)§	4 (2.5%)

Table 8 Table showing Diagnosis of patient with situs solitus and dextrocardia grouped according to pulmonary blood flow. Note all the percentage are column percent. ASD-atrial septal defect, VSD-Ventricular septal defect, PDA-Patent ductus arteriosus, NRGAs- Normally related great arteries Others-§-3 patients with criss-cross ventricles with PS, of which 2 had VSD, ¶1 patient with truncus arteriosus

Table 8 shows the diagnosis of patients with dextrocardia with situs solitus. There were total of n=163 patients in this group of which 67.5% had reduced pulmonary blood flow. Only 3.7%

of the patients had hearts without congenital defect. Most of the patients in this group had serious congenital heart defects. 4.9% had complete transposition, 31.3% had congenitally corrected transposition, 22.1% had double outlet right ventricle, Single ventricle was seen in 16.0%, whereas tetralogy of fallot was seen in 6.1% only. Left to right shunt was seen in 9.8% of the patients. Overall in patients with situs solitus 20 patients had atrioventricular cushion defects with various diagnosis like DORV, C-TGA, CC-TGA, SV, whereas 23 patients had single atrio-ventricular valve atresia of which 16 had L-posed aorta and 5 had D-Posed aorta.

Mode of atrio-ventricular connection in situs solitus	Aortic position				Total
	D-Posed	L-Posed	Z-Posed	Missing+NRGA	
Two Atrioventricular Valve	15 (12.5%)	62 (51.7%)	7 (5.8%)	36 (30.0%)	120
Common Atrioventricular Valve	5 (25.0%)	10 (50.0%)	1 (5.0%)	4 (20.0%)	20
Single Atrioventricular Valve	3 (13.0%)	15 (65.2%)	1 (4.3%)	4 (17.4%)	23
Total	23 (14.1%)	87 (53.4%)	9 (5.5%)	44 (27.0%)	163

Table 9 Patients with situs solitus and dextrocardia showing position of aorta and mode of atrio-ventricular valve connection. All the percentage values are row percent. Patients with Single atrioventricular valve atresia were more likely to have L-Posed Aorta (p-value<0.01).

Table 9 shows that patients with common atrio-ventricular valve and single atrio-ventricular valve atresia are more likely to have L-posed aorta as compared to D-Posed aorta

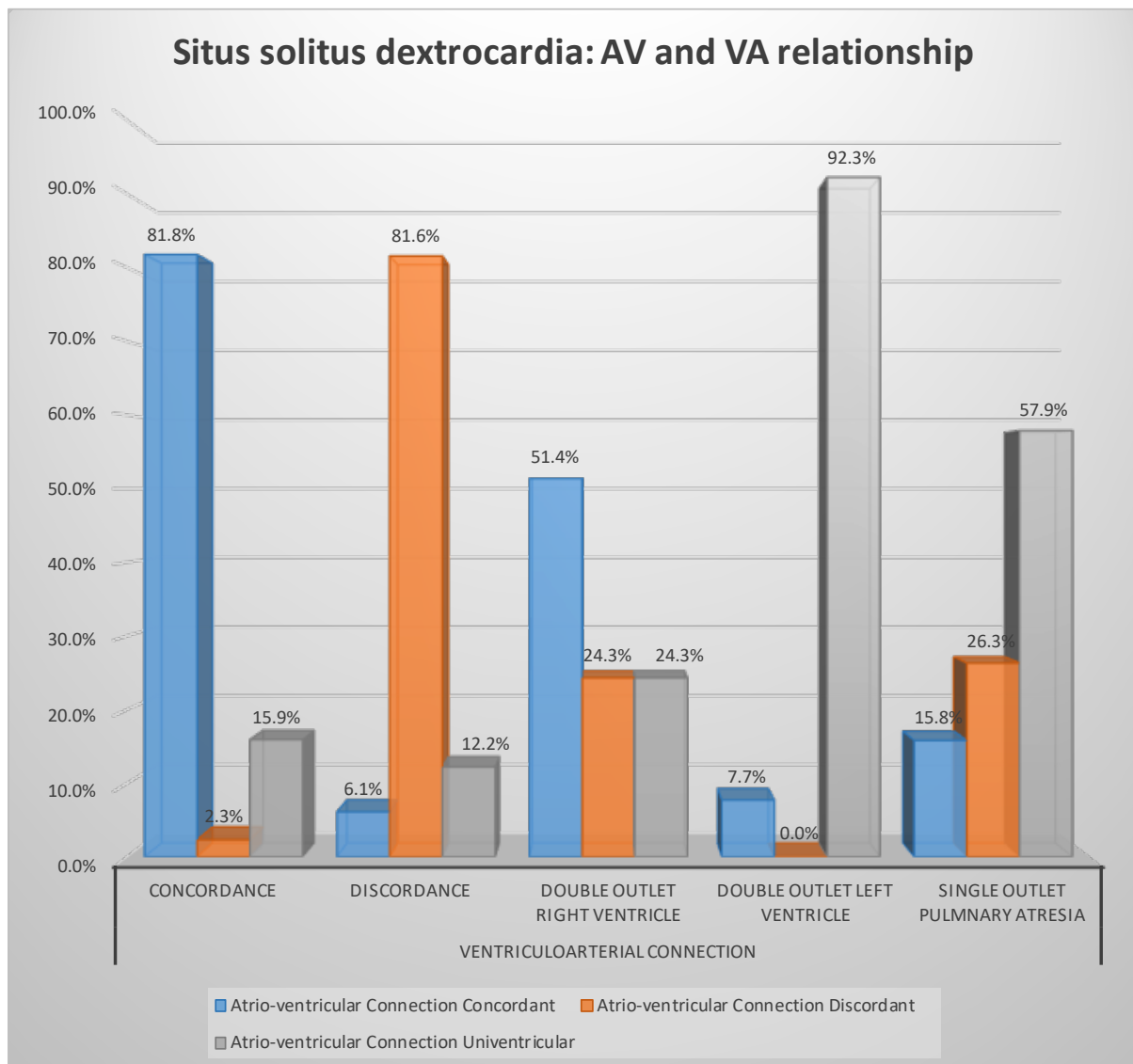


Figure 18 In patients with situs solitus and dextrocardia, showing relationship in atrioventricular (AV) connection and ventricular-arterial (VA) connection. Note univentricular atrio-ventricular connection includes both common atrioventricular valve and single atrio-ventricular valve atresia.

Figure 18 shows atrio-ventricular (AV) and ventricular-arterial (VA) connection in patients with situs solitus. It shows that concordant AV connection will more likely to have VA concordance. While discordant AV connection will more likely to have VA discordance. DORV is likely to have univentricular connection.

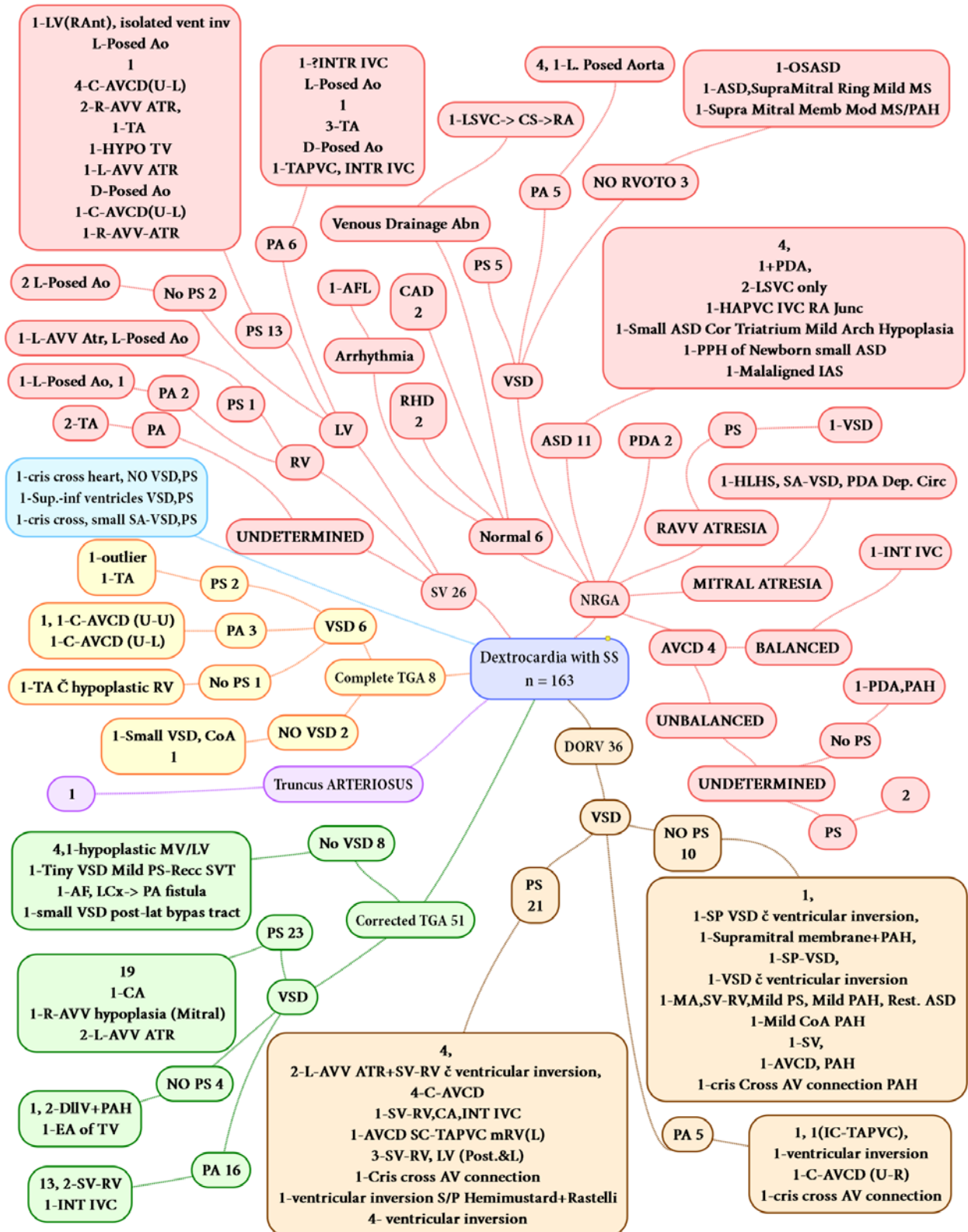

Figure 19 Flow chart showing the diagnosis of various patients with situs solitus and dextrocardia. AF-Atrial Fibrillation, Ant- anterior, ASD-Atrial septal defect, ATR-Atresia, AVCD-Atrio-ventricular cushion defect, AV-Atrioventricular, AVV-Atrio-ventricular valve,

CA- Common atrium, CAD-Coronary artery disease, C-AVCD- Complete AVCD, CoA-Coarctation of aorta, CS- Coronary sinus, DILV-double inlet left ventricle, DORV-double outlet right ventricle, HAPVC-Hemi-anomalous pulmonary venous connection, INT. IVC- Interrupted Inferior vena cava, L-Left, LV-Left ventricle, MA-Mitral atresia, PA-Pulmonary Atresia, PAH-Pulmonary arterial hypertension, PAPVC-Partially anomalous pulmonary venous connection, PDA-Patent ductus arteriosus, Post- Posterior, PPH-Primary pulmonary hypertension, PS-Pulmonary Stenosis, R- Right, SP-Sub-pulmonic, RHD- Rheumatic heart disease, RV-Right ventricle, SS-Situs Solitus, SV-Single ventricle, SVC-Superior vena cava, TA tricuspid atresia, TAPVC-Totally anomalous pulmonary venous connection, TGA-Transposition Of Great Arteries, VSD- Ventricular septal defect.

Diagnosis in patients with Dextrocardia and Situs Solitus (n = 163)

- Normally related great arteries
 - Atrio-ventricular canal defect 4
 - Balanced
 - 1-Interrupted IVC
 - Unbalanced
 - Undetermined
 - PS 2
 - No PS : 1-PDA,PAH
 - Right Atrio-ventricular valve Atresia
 - PS
 - 1-VSD
 - Ventricular septal defect
 - PS 5
 - PA 5
 - 4, 1-L. Posed Aorta
 - NO RVOTO 3
 - 1-OSASD
 - 1-ASD,Supra-Mitral Ring Mild MS
 - 1-Supra Mitral Membrane Mod MS/PAH
 - Atrial septal defect 11
 - 4,
 - 1+PDA,
 - 2-LSVC only
 - 1-HAPVC IVC RA Junction
 - 1-Small ASD Cor Triatrium Mild Arch Hypoplasia
 - 1-PPH of Newborn small ASD
 - 1-Malaligned Interatrial septum
 - Mitral Atresia

- 1-HLHS, SA-VSD, PDA Dependent Circulation
- Patent ductus arteriosus 2
- Normal 6
 - Rheumatic heart disease 2
 - Coronary artery disease 2
 - Arrhythmia 1(Atrial flutter)
 - Venous Drainage Abnormality
 - 1-LSVC-> CS->RA
- Double outlet Right ventricle 36
 - Ventricular septal defect
 - NO PS 10
 - 1,
 - 1-SP VSD č ventricular inversion,
 - 1-Supramitral membrane +PAH,
 - 1-SP-VSD,
 - 1-VSD č ventricular inversion
 - 1-MA,SV-RV,Mild PS, Mild PAH, Restrictive ASD
 - 1-Mild Coarctation PAH
 - 1-Single ventricle,
 - 1-AVCD, PAH
 - 1-cris Cross AV connection PAH
 - PS 21
 - 4,
 - 2-L-AVV ATR+SV-RV č ventricular inversion,
 - 4-C-AVCD
 - 1-SV-RV,CA,Interrupted IVC
 - 1-AVCD SC-TAPVC mRV(L)
 - 3-SV-RV, LV (Post.&L)
 - 1-Cris cross AV connection
 - 1-ventricular inversion S/P Hemimustard+Rastelli
 - 4- ventricular inversion
 - PA 5
 - 1, 1(IC-TAPVC),
 - 1-ventricular inversion
 - 1-C-AVCD (U-R)
 - 1-cris cross AV connection
- Complete Transposition of great arteries 8
 - Ventricular septal defect 6
 - PS 2
 - 1-outlier
 - 1-Tricuspid atresia
 - No PS 1

- 1-Tricuspid atresia Ć hypoplastic RV
 - PA 3
 - 1, 1-C-AVCD (U-U)
 - 1-C-AVCD (U-L)
 - No Ventricular septal defect 2
 - 1-Small VSD, Coarctation of aorta
1
- Corrected Transposition of great arteries 51
 - Ventricular septal defect
 - PS 23
 - 19
 - 1-CA
 - 1-R-AVV hypoplasia (Mitral)
 - 2-L-AVV Atresia
 - NO PS 4
 - 1, 2-DIIV+PAH
 - 1-Ebstein's anomaly of Tricuspid valve
 - PA 16
 - 13, 2-SV-RV
 - 1-Intrrrupted IVC
 - No Ventricular septal defect 8
 - 4,1-hypoplastic MV/LV
 - 1-Tiny VSD Mild PS-Recurrent Supraventricular Tachycardia
 - 1-AF, LCx-> PA fistula
 - 1-small VSD postero-lateral bypass tract
- Truncus Arteriosus 1
- 1-cris cross heart, NO VSD, PS
- 1-Superior-inferior ventricles VSD, PS
- 1-cris cross heart, small SA-VSD, PS
- Single ventricle 26
 - Left ventricular morphology 21
 - PS 13
 - 1-LV(RAnt), isolated ventricular inversion
 - L-Posed Aorta
 - 1
 - 4-C-AVCD(U-L)
 - 2-R-AVV Atresia
 - 1-Tricuspid valve
 - 1-Hypoplastic Tricuspid valve
 - 1-L-AVV Atresia

D-Posed Aorta

1-C-AVCD(U-L)

1-R-AVV-Atresia

- PA 6
 - 1-?Interrupted IVC

L-Posed Aorta

1

3-Tricuspid atresia

D-Posed Aorta

1-TAPVC, Interrupted IVC

- No PS 2
 - L-Posed Aorta
- Right ventricular morphology 3
 - PA 2
 - L-Posed Aorta, 1
 - PS 1
 - L-Posed Aorta, 1-L-AVV Atresia,
- Undetermined morphology 2
 - PA
 - 2-Tricuspid Atresia

SITUS INVERSUS AND DEXTROCARDIA

Diagnosis of patient with Situs Inversus and dextrocardia	Pulmonary Blood Flow		
	Normal/ Increased	Decreased	Total
	n=67	n=77	n=144
Normal	24 (35.8%)	0 (0.0%)	24 (16.7%)
Complete Transposition	3 (4.5%)	11 (14.3%)	14 (9.7%)
Congenitally corrected transposition	5 (7.5%)	5 (6.5%)	10 (6.9%)
Double outlet Right ventricle	6 (9.0%)	33 (42.9%)	39 (27.1%)
Atrio-ventricular Canal Defects with NRGAs	2 (3.0%)	2 (2.6%)	4 (2.8%)
Atrio-ventricular valve atresia with NRGAs	0 (0.0%)	2 (2.6%)	2 (1.4%)
Single ventricle	3 (4.5%)	14 (18.2%)	17 (11.8%)
Left→Right shunts (ASD/VSD/PDA)	23 (34.3%)	0 (0.0%)	23 (16.0%)
Tetralogy of Fallot	0 (0.0%)	10 (13.0%)	10 (6.9%)
OTHERS	1 (1.5%)	0 (0.0%)	1 (0.7%)

Table 10 showing diagnosis of patients with dextrocardia and situs inversus, grouped according to pulmonary blood flow. Note all the percentage are column percent. ASD-atrial septal defect, VSD-Ventricular septal defect, PDA-Patent ductus arteriosus, NRGAs- Normally related great arteries

Table 10 shows the diagnosis of patients with dextrocardia and situs inversus. There is total of n=144 patients in this group in which 53.4% had reduced pulmonary blood flow this number is significantly less than in patients with situs solitus dextrocardia (see Table 4). Most common diagnosis in this group was double outlet right ventricle (27.1%) followed by normal patients with no congenital heart defect in (16.7%), closely followed by Left to right shunt was present in (16%). 9.7% had complete transposition of great arteries, 6.9% had congenitally corrected transposition of great arteries, Single ventricle was present in 11.8% of the patients and tetralogy of fallot in 6.9%.

Table 11 shows that common atrio-ventricular valve and single atrioventricular valve were more likely to have L-posed aorta as compared to D-posed aorta (p<0.01)

Mode of atrioventricular connection in situs inversus	Aortic Position				Total
	D- Posed	L- Posed	Z- Posed	Missing+ NRGAs	
Two Atrioventricular Valve	21 (19.6%)	24 (22.4%)	3 (2.8%)	29 (55.1%)	107
Common Atrioventricular Valve	4(19.0%)	11 (52.4%)	2 (9.5%)	4 (19.0%)	21
Single Atrioventricular Valve	6 (7.5%)	6 (37.5%)	1 (6.3%)	3 (18.8%)	16
Total	31 (21.5%)	41 (28.5%)	6 (4.2%)	66 (45.8%)	144

Table 11 Patients with situs inversus and dextrocardia showing position of aorta and mode of atrio-ventricular valve connection. All the percentage values are row percent. Patients with Common atrio-ventricular canal defect were more likely to have L-Posed Aorta (p-value<0.01).

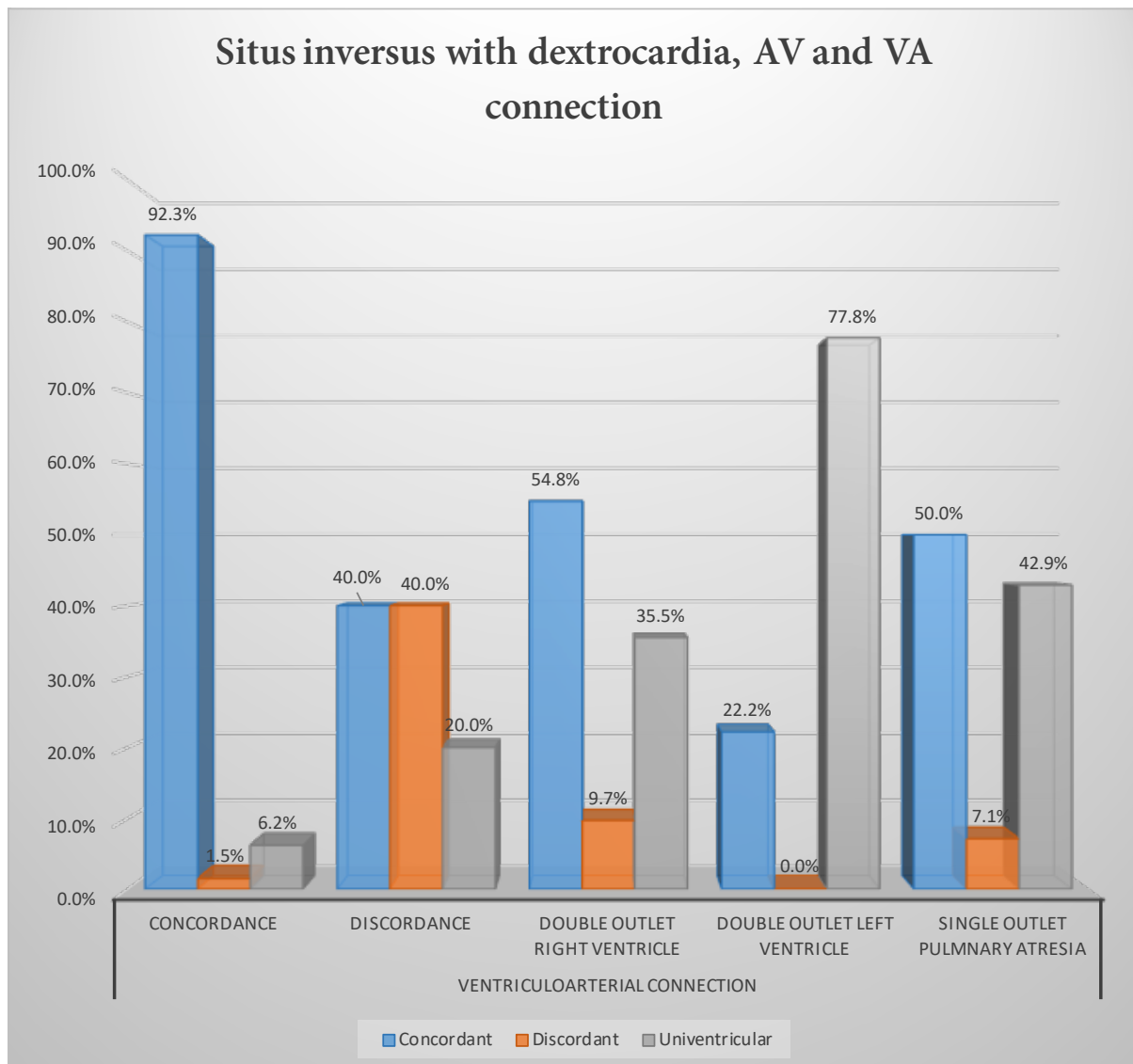


Figure 20 showing atrio-ventricular (AV) connection vs ventriculo-arterial (VA) connection in patients with situs inversus and dextrocardia. Note that univentricular AV connection includes both common atrio-ventricular valve and single atrio-ventricular valve atresia.

Figure 20 shows relationship of atrio-ventricular (AV) vs ventriculo-arterial (VA) connection in patients with situs inversus and dextrocardia. It shows that in patient with AV concordance are more likely to have VA concordance while those with AV discordance are more likely to have VA discordance.

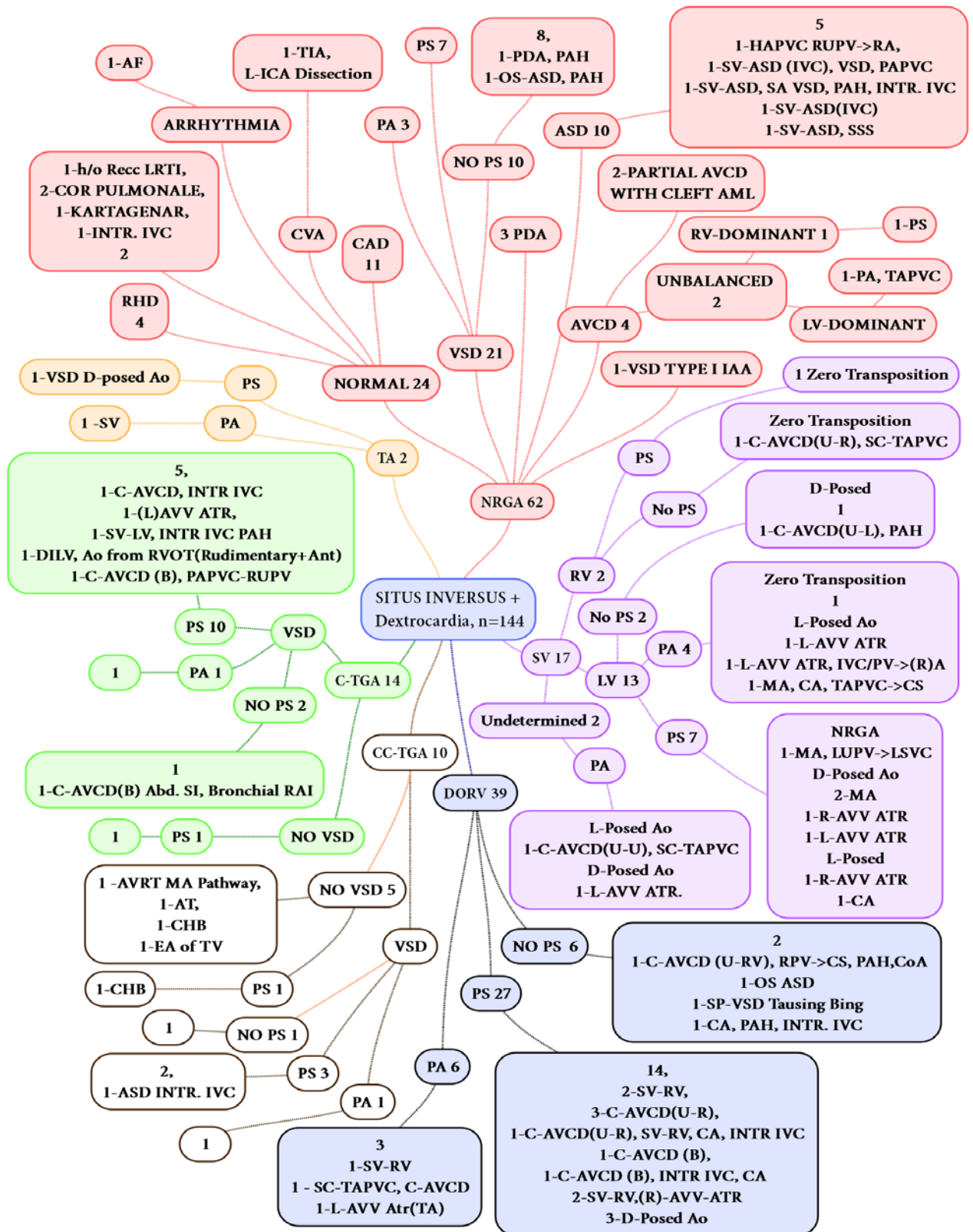


Figure 21 Flow chart showing the diagnosis of various patients with situs inversus and dextrocardia. AF-Atrial Fibrillation, Ant- anterior, ASD-Atrial septal defect, ATR-Atresia, AVCD-Atrio-ventricular cushion defect, AV-Atrioventricular, AVV-Atrio-ventricular valve,

CA- Common atrium, CAD-Coronary artery disease, C-AVCD- Complete AVCD, CoA-Coarctation of aorta, CS- Coronary sinus, DILV-double inlet left ventricle, DORV-double outlet right ventricle, GV-Great vessels, HAPVC-Hemi-anomalous pulmonary venous connection, INT. IVC- Interrupted Inferior vena cava, L-Left, LV-Left ventricle, MA-Mitral atresia, PA-Pulmonary Atresia, PAH- Pulmonary arterial hypertension, PAPVC-Partially anomalous pulmonary venous connection, PDA-Patent ductus arteriosus, Post- Posterior, PPH-Primary pulmonary hypertension, PS- Pulmonary Stenosis, R- Right, SP-Sub-pulmonic, RHD-Rheumatic heart disease, RPV-Right pulmonary vein, RV-Right ventricle, SS-Situs Solitus, SC-TAPVC-Supracardiac Totally anomalous pulmonary venous connection, SV-Single ventricle, SVC-Superior vena cava, TA tricuspid atresia, TAPVC-Totally anomalous pulmonary venous connection, TGA-Transposition Of Great Arteries, VSD- Ventricular septal defect.

Situs Inversus + Dextrocardia, n=144

- Normally related great arteries 62
 - Atrio-ventricular canal defect 4
 - Unbalanced 2
 - Right Ventricle-Dominant 1
 - 1-PS
 - Left Ventricle-Dominant 1
 - 1-PA, TAPVC
 - Partial Atrio-ventricular canal defect with cleft AML -2
 - Ventricular septal defect 21
 - PS 7
 - PA 3
 - No PS 10
 - 8,
1-PDA, PAH
 - 1-OS-ASD, PAH
 - Normal 24
 - 1-h/o Recurrent LRTI,
 - 2-Cor Pulmonale,
 - 1-Kartagenar Syndrome,
 - 1-Inturrupted IVC
 - 2
 - Rheumatic heart disease 4
 - Coronary artery disease 11
 - Arrhythmia 1(Atrial Fibrillation)
 - Cerebrovascular accident 1 (Left-Internal Carotid Artery Dissection)
 - Patent ductus arteriosus 3

- Type I Interrupted aortic arch with VSD -1
- Atrial septal defect 10
 - 5
 - 1-HAPVC RUPV->RA,
 - 1-SV-ASD (IVC), VSD, PAPVC
 - 1-SV-ASD, SA VSD, PAH, Interrupted IVC
 - 1-SV-ASD(IVC)
 - 1-SV-ASD, SSS
- Double outlet Right ventricle 39
 - PS 27
 - 14,
 - 2-SV-RV,
 - 3-C-AVCD(U-R),
 - 1-C-AVCD(U-R), SV-RV, CA, Interrupted IVC
 - 1-C-AVCD (B),
 - 1-C-AVCD (B), Interrupted IVC, CA
 - 2-SV-RV,(R)-AVV-Atresia
 - 3-D-Posed Aorta
 - PA 6
 - 3
 - 1-SV-RV
 - 1 - SC-TAPVC, C-AVCD
 - 1-L-AVV Atresia(TA)
 - NO PS 6
 - 2
 - 1-C-AVCD (U-RV), RPV->CS, PAH, Coarctation of aorta
 - 1-OS ASD
 - 1-SP-VSD Tausing Bing
 - 1-CA, PAH, Interrupted IVC
- Congenitally corrected transposition of great arteries 10
 - Ventricular septal defect
 - PS 3
 - 2,
 - 1-ASD Interrupted IVC
 - NO PS 1
 - 1
 - PA 2
 - No Ventricular septal defect 5
 - 1 -AVRT MA Pathway,
 - 1-AT,
 - 1-CHB
 - 1-EA of TV

- PS 1
 - 1-CHB
- Complete transposition of great arteries 14
 - Ventricular septal defect
 - PS 10
 - 5,
1-C-AVCD, Interrupted IVC
1-(L)AVV Atresia,
1-SV-LV, Interrupted IVC, PAH
1-DILV, Aorta from RVOT(Rudimentary +Anterior)
1-C-AVCD (B), PAPVC-RUPV
 - NO PS 2
 - 1
1-C-AVCD(B) Abdominal SI, Bronchial RAI
 - PA 1
 - 1
 - NO Ventricular septal defect
 - PS 1
 - 1
- Tricuspid atresia 2
 - PS
 - 1-VSD D-posed Aorta
 - PA
 - 1 -Single Ventricle
- Single ventricle 17
 - Left ventricular morphology 13
 - PS 7
 - Normally Related great arteries
1-MA, LUPV->LSVC
D-Posed Aorta
2-MA
1-R-AVV ATR
1-L-AVV ATR
L-Posed Aorta
1-R-AVV ATR
1-CA
 - PA 4
 - Zero Transposition
1
L-Posed Aorta
1-L-AVV ATR

- 1-L-AVV ATR, IVC/PV->(R)A
- 1-MA, CA, TAPVC->CS
- No PS 2
 - D-Posed Aorta
1
1-C-AVCD(U-L), PAH
- Right ventricular morphology 2
 - PS
 - Zero Transposition of Aorta -1
 - No PS
 - Zero Transposition of aorta 1-C-AVCD(U-R), SC-TAPVC
- Undetermined morphology 2
 - PA
 - L-Posed Aorta
1-C-AVCD(U-U), SC-TAPVC
 - D-Posed Aorta
1-L-AVV Atresia

SITUS AMBIGUUS AND DEXTROCARDIA (N=71)

Diagnosis in patients with situs ambiguus and dextrocardia	Pulmonary Blood Flow		
	Normal/ increased n=19	Decreased n=52	Total n=71
Complete Transposition	0 (0.0%)	4 (7.7%)	4 (5.6%)
Congenitally corrected transposition	0 (0.0%)	4 (7.7%)	4 (5.6%)
Double outlet Right ventricle	4 (21.1%)	22 (42.3%)	26 (36.6%)
Atrio-ventricular Canal Defects with NRGAs	4 (21.1%)	1 (1.9%)	5 (7.0%)
Single ventricle	5 (26.3%)	19 (36.5%)	24 (33.8%)
Left→Right shunt (ASD/VSD/PDA)	6 (31.6%)	0 (0.0%)	6 (8.5%)
Tetralogy of Fallot	0 (0.0%)	2 (3.8%)	2 (2.8%)

Table 12 showing diagnosis of patient with Situs Ambiguus and dextrocardia, grouped according to pulmonary blood flow. Note all the percentage are column percent. ASD-atrial septal defect, VSD-Ventricular septal defect, PDA-Patent ductus arteriosus, NRGAs- Normally related great arteries

Table 12 shows diagnosis of patient with situs ambiguus and dextrocardia. There are total of n=71 patients in this group of which 73.2% had lesions with reduced pulmonary blood flow. Most common diagnosis in this group was double outlet right ventricle (36.6%), second most common in this group was Single ventricle (33.8%). Complete transposition of great arteries was seen in 5.6% and congenitally corrected transposition was also seen in 5.6% patients.

Table 13 shows position of aorta and mode of atrio-ventricular connection in situs ambiguus patients. It shows that common atrio-ventricular valves and single atrio-ventricular valves are more likely to have L-Posed aorta as compared to D-posed aorta.

Mode of atrioventricular connection in situs ambiguus	Aortic Position				Missing + NRGAs	Total
	D- Posed	D- Posed	D- Posed	D- Posed		
Two Atrioventricular Valve	6 (24.0%)	6 (24.0%)	3 (12.0%)	10 (40.0%)	25	
Common Atrioventricular Valve	10 (24.4%)	17 (41.5%)	5 (12.2%)	9 (22.0%)	41	
Single Atrioventricular Valve	1 (20.0%)	3 (60.0%)	1 (20.0%)	0	5	
Total	17 (23.9%)	26 (36.6%)	9 (12.7%)	19 (26.8%)	71	

Table 13 Patients with situs ambiguus and dextrocardia showing position of aorta and mode of atrio-ventricular valve connection. All the percentage values are row percent.

Table 14 shows the diagnosis of patients on the basis of type of situs ambiguus. There are total of n=71 patients with situs ambiguus, of which most common was right atrial isomerism (43.7%). Among the right atrial isomerism most common diagnosis was double outlet right ventricle (45.1%), whereas among left atrial isomerism left to right shunt lesions were most common (42.1%).

Diagnosis			RAI	LAI	UAI	TOTAL	
DORV	NO PS		1 (1.4%)	1 (1.4%)	2 (2.8%)	4 (5.6%)	
		PS	11 (15.4%)	3 (4.2%)	3 (4.2%)	17 (23.9%)	
		PA	2 (2.8%)	1 (1.4%)	2 (2.8%)	5 (7.0%)	
CC-TGA	VSD	PS	1 (1.4%)	0	1 (1.4%)	2 (2.8%)	
		PA	2 (2.8%)	0	0	2 (2.8%)	
C-TGA	VSD	PS	1 (1.4%)	0	0	1 (1.4%)	
		PA	2 (2.8%)	1 (1.4%)	0	3 (4.2%)	
SV	LV	NO PS	1 (1.4%)	0	0	1 (1.4%)	
		PS	2 (2.8%)	1 (1.4%)	1 (1.4%)	4 (5.6%)	
		PA	1 (1.4%)	0	2 (2.8%)	3 (4.2%)	
	UNDETER	NO PS	PS	1 (1.4%)	0	1 (1.4%)	2 (2.8%)
			PS	0	1 (1.4%)	1 (1.4%)	2 (2.8%)
			PA	2 (2.8%)	0	0	2 (2.8%)
	RV	NO PS	PS	1 (1.4%)	1 (1.4%)	0	2 (2.8%)
			PS	1 (1.4%)	2 (2.8%)	1 (1.4%)	4 (5.6%)
			PA	2 (2.8%)	0	2 (2.8%)	4 (5.6%)
NRGA	VSD	NO PS	0	1 (1.4%)	0	1 (1.4%)	
		PS	0	1 (1.4%)	0	1 (1.4%)	
		PA	0	0	1 (1.4%)	1 (1.4%)	
	ASD		0	2 (2.8%)	3 (4.2%)	5 (7.0%)	
		AVCD	PARTIAL	0	4 (5.6%)	0	4 (5.6%)
			COMP	0	0	1 (1.4%)	1 (1.4%)
TOTAL			31 (43.7%)	19 (26.8%)	21 (29.6%)	71	

Table 14 Diagnosis of patients with type of situs ambiguus and dextrocardia. All the percentages are obtained by dividing each number with 71 (Total number of patients with situs ambiguus). DORV- Double outlet right ventricle, TGA- transposition of great arteries, C-TGA- complete TGA, CC-TGA- congenitally corrected TGA, SV- single ventricle, SV-LV SV of left ventricular morphology, SV-RV- SV of right ventricular morphology, SV-Undeter- SV of undetermined morphology, NRGA-normally related great arteries, VSD-ventricular septal defect, ASD-atrial septal defect, AVCD-atrioventricular canal defect, AVCD-COMP-complete AVCD, PS-pulmonary stenosis, PA- pulmonary atresia, RAI-right atrial isomerism, LAI-left atrial isomerism, UAI-Unidentified atrial isomerism

Table 14 shows that Right atrial isomerism is more common than Left atrial isomerism, 43.7% vs 26.8% ($p < 0.01$). Among the patients with Right atrial isomerism Double outlet Right ventricle is the most common diagnosis (45.2%). Whereas among patients with Left atrial isomerism DORV and single ventricle have a tie at 26.3% (see also Figure 23).

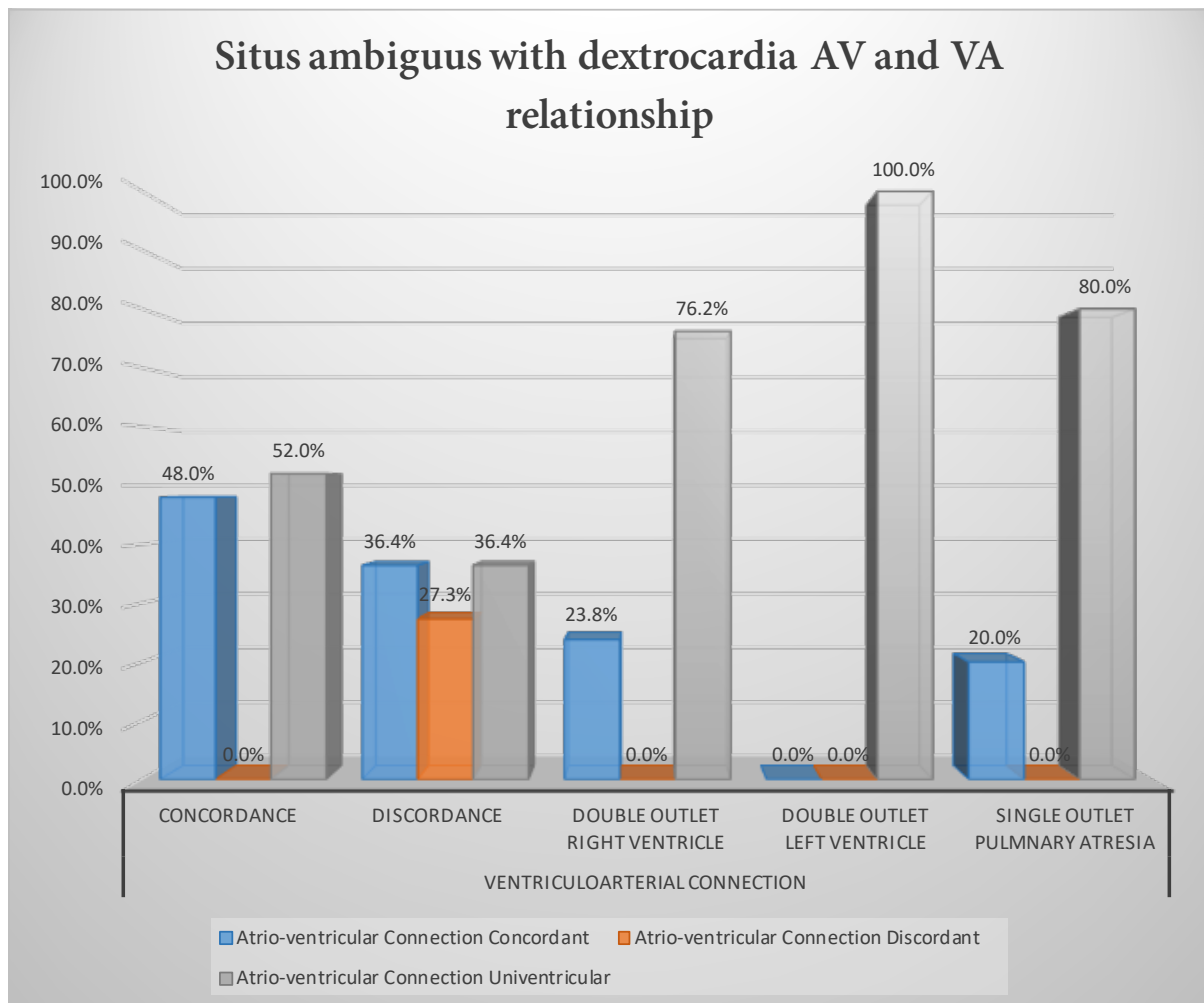


Figure 22 showing atrio-ventricular vs ventriculo-arterial relation in patients with situs ambiguus and dextrocardia. Note that univentricular AV connection includes both common atrio-ventricular valve and single atrio-ventricular valve atresia

Figure 22 shows the atrio-ventricular connection (AVC) vs ventriculo-arterial connection (VAC) in patients with situs ambiguus grouped according to type of atrial isomerism. It shows that patients with Right atrial isomerism with concordant VAC are more likely to have concordant AVC as compared to Left atrial isomerism, 48% vs 0% respectively. While in patients with discordant AVC are both the type are isomerism have similar incidence of discordant AVC.

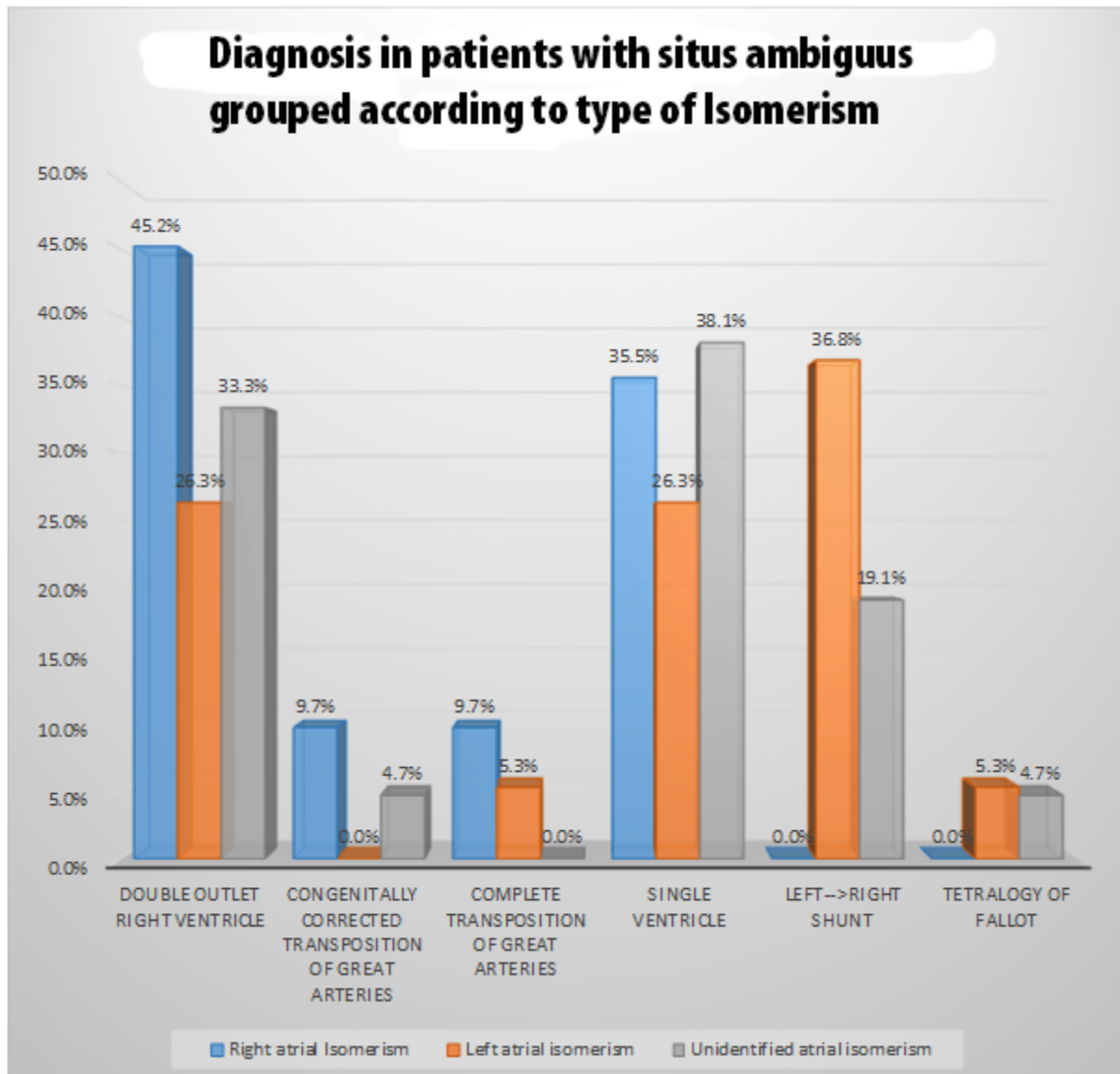


Figure 23 Diagnosis of patients with situs ambiguus grouped according to type of isomerism. Note that Left → Right shunt includes atrial septal defect (including primum atrio-ventricular defect), Ventricular septal defects.

Figure 23 shows the diagnosis of patients with situs ambiguus divided according to type of atrial isomerism. It shows that left to right shunt lesions are more likely to be common in Left atrial isomerism than in right atrial isomerism 36.8% vs 0% respectively.

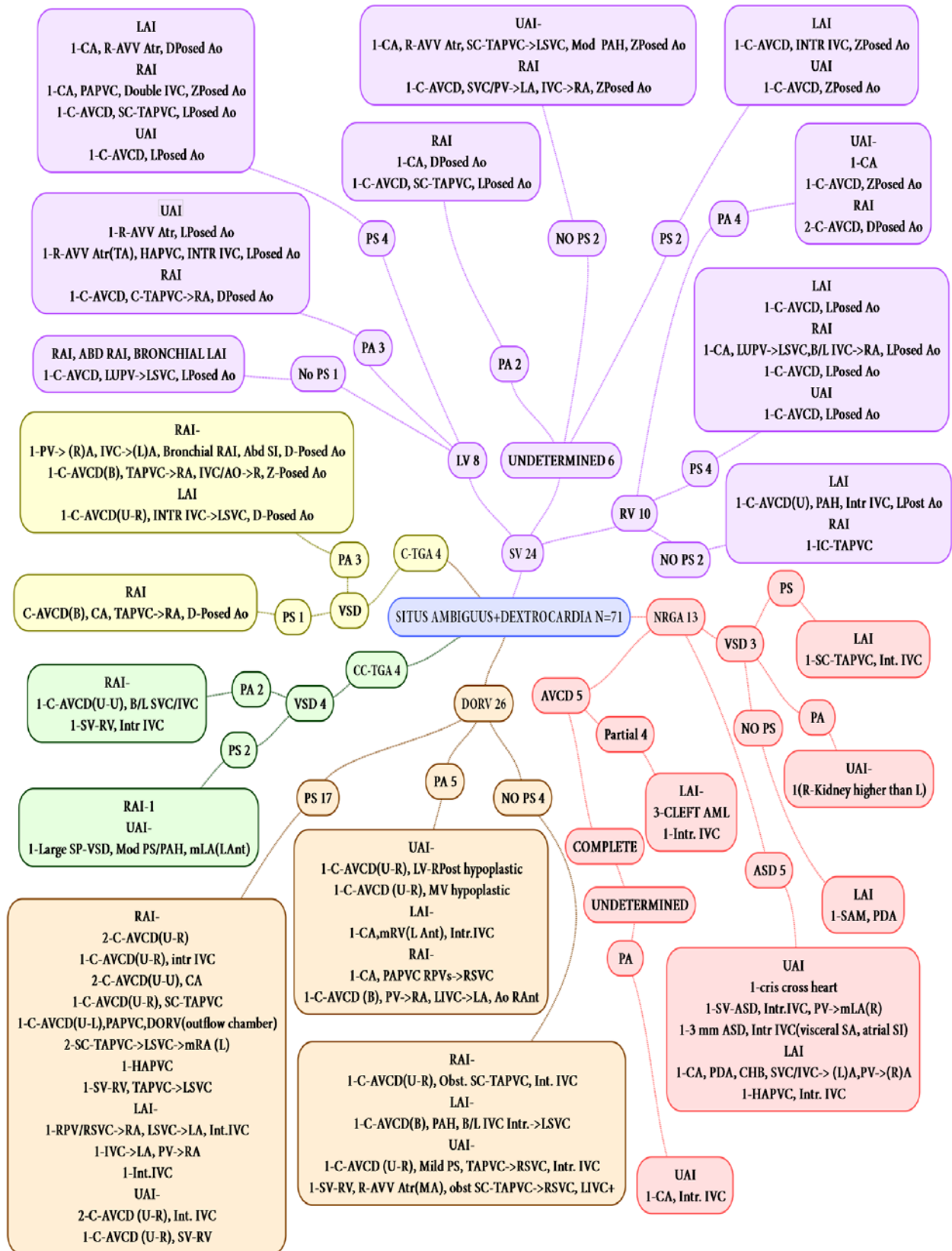


Figure 24 Flow chart showing the diagnosis of various patients with situs ambiguus and dextrocardia. AF-Atrial Fibrillation, Ant- anterior, ASD-Atrial septal defect, ATR-Atresia,

AVCD-Atrio-ventricular cushion defect, AV-Atrioventricular, AVV-Atrio-ventricular valve, CA- Common atrium, CAD-Coronary artery disease, C-AVCD- Complete AVCD, CoA-Coarctation of aorta, CS- Coronary sinus, DILV-double inlet left ventricle, DORV-double outlet right ventricle, GV-Great vessels, HAPVC-Hemi-anomalous pulmonary venous connection, INT. IVC- Interrupted Inferior vena cava, L-Left, LAI-Left atrial isomerism, LV-Left ventricle, MA-Mitral atresia, PA-Pulmonary Atresia, PAH- Pulmonary arterial hypertension, PAPVC-Partially anomalous pulmonary venous connection, PDA-Patent ductus arteriosus, Post-Posterior, PPH-Primary pulmonary hypertension, PS- Pulmonary Stenosis, R- Right, SP-Subpulmonic, RAI- Right atrial isomerism, RHD- Rheumatic heart disease, RPV-Right pulmonary vein, RV-Right ventricle, SS-Situs Solitus, SC-TAPVC-Supracardiac Totally anomalous pulmonary venous connection SV-Single ventricle, SVC-Superior vena cava, TA tricuspid atresia, TAPVC-Totally anomalous pulmonary venous connection, TGA-Transposition Of Great Arteries, UAI-Undetermined atrial isomerism, VSD- Ventricular septal defect.

Diagnosis of patients with Situs Ambiguus and Dextrocardia (n=71)

- Normally Related Great arteries 13
 - Ventricular Septal Defect 3
 - PS
 - Left atrial Isomerism
1-SC-TAPVC, Int. IVC
 - NO PS
 - Left atrial Isomerism
1-SAM, PDA
 - PA
 - Unidentified atrial Isomerism-
1(R-Kidney higher than L)
 - Atrial septal defect 5
 - Unidentified atrial Isomerism
1-cris cross heart
1-Single Ventricle-ASD, Interrupted. IVC, PV->mLA(R)
1-3 mm ASD, Interrupted IVC(visceral SA, atrial SI)
Left atrial Isomerism
1-CA, PDA, CHB, SVC/IVC-> (L)A,PV->(R)A
1-HAPVC, Interrupted. IVC
 - Atrio-ventricular cushion defects 5
 - Partial 4
 - Left atrial Isomerism-
3-CLEFT AML
1-Inturrupted. IVC

- Complete
 - Undetermined
 - PA
 - Unidentified atrial Isomerism
1-CA, Interrupted. IVC
 - Double Outlet Right Ventricle 26
 - PS 17
 - Right atrial Isomerism-
2-C-AVCD(U-R)
1-C-AVCD(U-R), Interrupted IVC
2-C-AVCD(U-U), CA
1-C-AVCD(U-R), SC-TAPVC
1-C-AVCD(U-L),PAPVC, Double Outlet Right Ventricle(outflow chamber)
2-SC-TAPVC->LSVC->mRA (L)
1-HAPVC
1-Single Ventricle-Right Ventricular morphology, TAPVC->LSVC
 - Left atrial Isomerism-
1-RPV/RSVC->RA, LSVC->LA, Interrupted IVC
1-IVC->LA, PV->RA
1-Int.IVC
 - Unidentified atrial Isomerism-
2-C-AVCD (U-R), Int. IVC
1-C-AVCD (U-R), Single Ventricle-Right Ventricular morphology
 - PA 5
 - Unidentified atrial Isomerism-
1-C-AVCD(U-R), Left Ventricular morphology-RPost hypoplastic
1-C-AVCD (U-R), MV hypoplastic
 - Left atrial Isomerism-
1-CA,mRV(L Ant), Interrupted IVC
 - Right atrial Isomerism-
1-CA, PAPVC RPVs->RSVC
1-C-AVCD (B), PV->RA, LIVC->LA, Aorta RAnt
 - NO PS 4
 - Right atrial Isomerism-
1-C-AVCD(U-R), Obstructive SC-TAPVC, Int. IVC
 - Left atrial Isomerism-
1-C-AVCD(B), PAH, B/L IVC Interrupted.->LSVC
 - Unidentified atrial Isomerism-
1-C-AVCD (U-R), Mild PS, TAPVC->RSVC, Interrupted. IVC
1-Single Ventricle-Right Ventricular morphology, R-AVV Atresia(MA), obstructed SC-TAPVC->RSVC, LIVC+

- Complete Transposition of great arteries 4
 - Ventricular Septal Defect
 - PA 3
 - Right atrial Isomerism-
1-PV-> (R)A, IVC->(L)A, Bronchial Right atrial Isomerism, Abdominal SI, D-Posed Aorta
1-C-AVCD(B), TAPVC->RA, IVC/AO->R, Z-Posed Aorta
 - Left atrial Isomerism
1-C-AVCD(U-R), Interrupted IVC->LSVC, D-Posed Aorta
 - PS 1
 - Right atrial Isomerism
C-AVCD(B), CA, TAPVC->RA, D-Posed Aorta
- Congenitally corrected Transposition of great arteries 4
 - Ventricular Septal Defect 4
 - PA 2
 - Right atrial Isomerism-
1-C-AVCD(U-U), B/L SVC/IVC
1-Single Ventricle-Right Ventricular morphology, Interrupted IVC
 - PS 2
 - Right atrial Isomerism-1
Unidentified atrial Isomerism-
1-Large SP-Ventricular Septal Defect, Mod PS/PAH, mLA(LAnt)
- Single Ventricle 24
 - Left Ventricular morphology 8
 - PS 4
 - Left atrial Isomerism
1-CA, R-AVV Atresia, D-Posed Aorta
 - Right atrial Isomerism
1-CA, PAPVC, Double IVC, Z-Posed Aorta
1-C-AVCD, SC-TAPVC, L-Posed Aorta
 - Unidentified atrial Isomerism
1-C-AVCD, L-Posed Aorta
 - PA 3
 - Unidentified atrial Isomerism
1-R-AVV Atresia, L-Posed Aorta
1-R-AVV Atresia (TA), HAPVC, INTURRUPTED IVC, L-Posed Aorta
 - Right atrial Isomerism
1-C-AVCD, C-TAPVC->RA, D-Posed Aorta
 - No PS 1
 - Right atrial Isomerism, Abdominal RAI, Bronchial RAI
1-C-AVCD, LUPV->LSVC, L-Posed Aorta

- Right Ventricular morphology 10
 - PA 4
 - Unidentified atrial Isomerism-
1-CA
1-C-AVCD, Z Posed Aorta
Right atrial Isomerism
2-C-AVCD, D-Posed Aorta
 - PS 4
 - Left atrial Isomerism
1-C-AVCD, L-Posed Aorta
Right atrial Isomerism
1-CA, LUPV->LSVC,B/L IVC->RA, L-Posed Aorta
1-C-AVCD, L-Posed Aorta
Unidentified atrial Isomerism
1-C-AVCD, L-Posed Aorta
 - NO PS 2
 - Left atrial Isomerism
1-C-AVCD(U), PAH, Interrupted IVC, L-Post Aorta
Right atrial Isomerism
1-IC-TAPVC
- Undetermined ventricular morphology 6
 - NO PS 2
 - Unidentified atrial Isomerism-
1-CA, R-AVV Atresia, SC-TAPVC->LSVC, Mod PAH, Z-Posed Aorta
Right atrial Isomerism
1-C-AVCD, SVC/PV->LA, IVC->RA, Z-Posed Aorta
 - PA 2
 - Right atrial Isomerism
1-CA, D-Posed Aorta
1-C-AVCD, SC-TAPVC, L-Posed Aorta
 - PS 2
 - Left atrial Isomerism
1-C-AVCD, INTURRUPTED IVC, Z-Posed Aorta
Unidentified atrial Isomerism
1-C-AVCD, Z-Posed Aorta

DISCUSSION

This study is by far, to the best of our knowledge is the largest retrospective (cases upto last 20yrs) study on dextrocardia with with n=378 patients with mean age of 8.3 ± 15.3 yrs with 43.9% of patients were females. The study by Garg, Agarwal *et al*, 2003⁸ had 125 patients with mean age of 9.2yrs with 34.4% females in their study population.

In the current study 43.3 % were in situs solitus, 38% were in situs inversus 18.7% in situs ambiguus (43.5% had right isomerism and 25.2% had left isomerism and 30.2% had unidentified atrial isomerism) whereas in study by Garg, Agarwal *et al*, 2003⁸ these numbers were 34.4%, 39.2% and 26.4% (18.4% had right isomerism and 8% had left isomerism) for situs solitus, inversus and ambiguus respectively see Table 15, this difference is probably because patients in Garg, Agarwal *et al*, 2003⁸ study were older and with less complex congenital heart disease. Studies done by other authors have higher percentage of situs solitus because they were mostly necropsy studies implying that these patients had more complex congenital heart disease.

Situs	Current study	Arcilla and Gasul, 1961 ¹	Van Praagh <i>et al</i> , 1964 ¹⁷	Ellis, Fleming <i>et al</i> 1966 ⁷	Lev, Liberthson <i>et al</i> , 1968 ⁹	Squarcia, Ritter <i>et al</i> , 1973 ¹⁵	Calcaterra, Anderson <i>et al</i> , 1979 ⁴	Garg, Agarwal <i>et al</i> , 2003 ⁸
Solitus	43.1%	56.7%	47.3%	61%	36.6%	73%	48%	34.4%
Inversus	38.1%	33.3%	25%	11.9%	12.2%	18.3%	33%	39.2%
Ambiguus	18.8%	10%	27.14%	10.2%	51.2%	8.4%	18%	26.4%
Total	378	30	48	59	41	60	33	125

Table 15 showing incidence of situs in studies performed by various authors and the current study

In our study majority of the cases of dextrocardia were 51.8% in L-Loop (vs 23.8% cases of D-Loop). Furthermore whether in situs solitus or situs inversus L-Loop is significantly more common than D-Loop 55.8%vs 39.9% and 72.9%vs 17.4% respectively for solitus and inversus (see Table 5). It is also noteworthy that D-Loop is significantly more common in situs solitus than situs inversus see Table 4. This finding is similar to other studies, Van Praagh, Van Praagh *et al*, 1964¹⁷ study there were twice as many L-loops as D-loops (34/17 cases). These findings are supported by the fact that L-looping is destined to have dextrocardia since the heart rotates to right by the end of second month of gestation Licata, 1954¹⁰.

Discordant cardiac loops were seen in 116 cases, 91(55.8%) of all solitus (n=163) patients had L-loop, whereas 25(17.4%) of all inversus (n=144) patients had D-loop, see Table 5. Similar findings were seen in Van Praagh, Van Praagh *et al*, 1964¹⁷ series, 18 cases had discordant loop, 15 (65.2%) solitus individuals had L-loop while 3 (25%) inversus individual had D-loop. Although from physiologic standpoint much fewer number of patients had congenitally corrected transposition of great arteries (6.9% in situs inversus and 31.3% in situs solitus see Table 11 and Table 8 respectively).

Situs Inversus and Dextrocardia

In our study there were total 144 cases of situs inversus with dextrocardia, of which 53.4% had reduced pulmonary blood flow. On segmental analysis AV connection was concordant in majority (66.7%) while discordant AV connection and univentricular connections were 10.4% and 22.9% respectively these findings are similar to Calcaterra, Anderson *et al*, 1979⁴, Garg, Agarwal *et al*, 2003⁸, Squarcia, Ritter *et al*, 1973¹⁵. Structurally normal heart was found in 16.5% patients in our group similar number was found in Garg, Agarwal *et al*, 2003⁸ (30%). Among the discordant atrioventricular connection 40% patients had discordant ventriculoarterial discordance, interestingly around 10% patients had Double outlet right ventricle which is a

very rare finding. Around 16% of the patients had left right shunt some of which have undergone percutaneous device closure. Among the individuals with mirror image dextrocardia with structurally normal heart almost 50% patients had coronary artery disease and 15% had rheumatic heart disease. 1 patient had interrupted IVC and no other cardiac abnormality.

Situs Solitus and dextrocardia (n=163)

These patients are more likely to have serious cardiac abnormality. In our study only 3.7% had structurally normal heart and 6.1% had left to right shunt while 67.5% patients had reduced pulmonary blood flow. In the study by Garg, Agarwal *et al*, 2003⁸, 7% patients had structurally normal heart. Studies authored by Calcaterra, Anderson *et al*, 1979⁴, Van Praagh, Van Praagh *et al*, 1964¹⁷ structurally normal heart in situs solitus was not described probably due to the nature of these studies many of which were necropsy studies. In our study 38% had concordant AV connection and 34% had discordant AV connection while univentricular AV connection was seen in 27%. AV-VA discordance was seen in 31.3% patients. 81% of patients with discordant VA connection, also had AV discordance. Similarly 81% of patients with concordant VA connection, also had AV discordance see Figure 18.

Situs Ambiguus and dextrocardia (n=71)

In our study 43.4% patients had right atrial isomerism, 26.8% had left atrial isomerism and 29.6% had unidentified atrial isomerism. 73.2% patients had reduced pulmonary blood flow majority of them had cyanosis. DORV and single ventricle are the 2 most common diagnosis. 32.4% had concordant AV connection 53.2% had univentricular connection. Similar findings were also present in previous studies.

CONCLUSION

- Patient with dextrocardia who are seeking medical advice at a tertiary care centre are more likely to have situs solitus followed by situs inversus.
- Double outlet right ventricle (DORV) \pm PS/PA followed by congenitally corrected transposition (CC-TGA) \pm PS/PA and single ventricle \pm PS/PA is the most common diagnosis in patients with dextrocardia (ungrouped).
- CC-TGA \pm PS/PA followed by DORV \pm PS/PA is the most common diagnosis in situs solitus
- DORV \pm PS/PA is the most common diagnosis followed by left to right shunt lesion (ASD/VSD/PDA) and structurally normal heart in patients with situs inversus.
- DORV \pm PS/PA followed by single ventricle \pm PS/PA is the most common diagnosis in patients with situs ambiguus.
- Patients with situs solitus are more likely to have complicated cardiac lesions as compared to situs inversus.
- Nearly one fifth of the patient with situs inversus had structurally normal heart.
- Aortic annulus position is significantly more in left and anterior to pulmonary annulus in situs solitus signifying high propensity for L-looping.
- Aortic annulus position is significantly more in left and posterior to pulmonary annulus in situs inversus signifying normal relation of great arteries
- Congenitally corrected TGA (i.e. D-Looped ventricle) in situs inversus is very rare
- Left arch and Right sided SVC is significantly more common in situs solitus and Right arch and Left SVC is more common in situs inversus
- Bilateral SVC is more common in situs ambiguus
- Patients with situs solitus have more complex lesions compared to situs inversus hence more chances of referral to our tertiary care centre.(Referral bias)

BIBLIOGRAPHY

1. Arcilla RA, Gasul BM. Congenital dextrocardia Part 1. *The Journal of Pediatrics*. 1961;58(1):39-58.
2. Arcilla RA, Gasul BM. Congenital dextrocardia Part 2. *The Journal of Pediatrics*. 1961;58(2):251-62.
3. Bohun CM, Potts JE, Casey BM, Sandor GGS. A Population-Based Study of Cardiac Malformations and Outcomes Associated With Dextrocardia. *The American Journal of Cardiology*. 2007;100(2):305-9.
4. Calcaterra G, Anderson RH, Lau KC, Shinebourne EA. Dextrocardia--value of segmental analysis in its categorisation. *British Heart Journal*. 1979;42(5):497-507.
5. de la Cruz MV, Espino-Vela J, Attie F, Muñoz C L. An embryologic theory for ventricular inversions and their classification. *American Heart Journal*. 1967;73(6):777-93.
6. De la Cruz MV, Anselmi G, Munos-Castellanos L, Nadal-Ginard B, Munoz-Armas S. Systematization and embryological and anatomical study of mirror-image dextrocardias, dextroversions, and laevoversions. *British Heart Journal*. 1971;33(6):841-53.
7. Ellis K, Fleming RJ, Griffiths SP, Jameson AG. NEW CONCEPTS IN DEXTROCARDIA. *American Journal of Roentgenology*. 1966;97(2):295-313.
8. Garg N, Agarwal BL, Modi N, Radhakrishnan S, Sinha N. Dextrocardia: an analysis of cardiac structures in 125 patients. *International Journal of Cardiology*. 2003;88(2-3):143-55.
9. Lev M, Liberthson RR, ECKNER FAO, ARCILLA RA. Pathologic Anatomy of Dextrocardia and Its Clinical Implications. *Circulation*. 1968;37(6):979-99.
10. Licata RH. The human embryonic heart in the ninth week. *American Journal of Anatomy*. 1954;94(1):73-125.
11. McBrien A, Howley L, Yamamoto Y, Hutchinson D, Hirose A, Sekar P, et al. Changes in fetal cardiac axis between 8 and 15 weeks' gestation. *Ultrasound in Obstetrics & Gynecology*. 2013;42(6):653-8.
12. Offen S, Jackson D, Canniffe C, Choudhary P, Celermajer DS. Dextrocardia in Adults with Congenital Heart Disease. *Heart, Lung and Circulation*. 2016;25(4):352-7.
13. Reinberg SA, Mandelstam ME. On the Various Types of Dextrocardia and Their Diagnostics. *Radiology*. 1928;11(3):240-9.
14. Rogel S, Schwartz A, Rakower J. The Differentiation of Dextroversion from Dextroposition of the Heart and Their Relation to Pulmonary Abnormalities. *Diseases of the Chest*. 1963;44(2):186-92.

15. Squarcia U, Ritter DG, Kincaid OW. Dextrocardia: Angiocardiographic study and classification. *American Journal of Cardiology*. 1973;32(7):965-77.
16. Van Mierop LHS, Eisen S, Schiebler GL. The radiographic appearance of the tracheobronchial tree as an indicator of visceral situs. *The American Journal of Cardiology*. 1970;26(4):432-5.
17. Van Praagh R, Van Praagh S, Vlad P, Keith JD. Anatomic types of congenital dextrocardia. *The American Journal of Cardiology*. 1964;13(4):510-31.
18. Walmsley R, Hishitani T, Sandor GGS, Lim K, Duncan W, Tessier F, et al. Diagnosis and outcome of dextrocardia diagnosed in the fetus. *American Journal of Cardiology*. 94(1):141-3.