

**BEDSIDE CHEST ULTRASOUND IN POST OPERATIVE PAEDIATRIC
CARDIAC SURGERY PATIENTS: COMPARISON WITH BEDSIDE
CHEST RADIOGRAPHY**

*Thesis submitted for the partial fulfillment for the requirement of the Degree of DM
(Cardiothoracic and Vascular Anaesthesia)*



BY

DR. DON JOSE PALAMATTAM

DM CARDIOTHORACIC AND VASCULAR ANAESTHESIA RESIDENT

2017 – 2019

**DIVISION OF CARDIOTHORACIC AND VASCULAR
ANAESTHESIOLOGY, DEPARTMENT OF ANAESTHESIOLOGY,
SREE CHITRA TIRUNAL INSTITUTE FOR MEDICAL SCIENCES AND
TECHNOLOGY, TRIVANDRUM KERALA, INDIA – 695011**

DECLARATION

I hereby declare that this thesis entitled, “**BEDSIDE CHEST ULTRASOUND IN POST OPERATIVE PAEDIATRIC CARDIAC SURGERY PATIENTS: COMPARISON WITH BEDSIDE CHEST RADIOGRAPHY**” has been prepared by me under the capable supervision and guidance of **Dr. Rupa Sreedhar**, Senior Professor, Department of Cardiothoracic and Vascular Anaesthesiology, **Dr. Shrinivas Gadhinglajkar**, Professor, Department of Cardiothoracic and Vascular Anaesthesiology **Dr. Prashanta Kumar Dash**, Professor, Department of Cardiothoracic and Vascular Anaesthesiology, **Dr. Subin Sukesan**, Associate Professor, Department of Cardiothoracic and Vascular Anaesthesiology , **Dr. Baiju S Dharan**, Professor and Head, Department of Cardiothoracic and Vascular Surgery, **Dr. Santhosh Kumar K**, Associate Professor, Department of Imaging Sciences and Interventional Radiology, Sree Chitra Tirunal Institute for Medical Sciences & Technology, Thiruvananthapuram, Kerala.

Date:

Place: Thiruvananthapuram

Dr. Don Jose Palamattam,

DM Cardiothoracic and Vascular
Anesthesiology Resident,
Division of Cardiothoracic and
Vascular Anaesthesiology
Department of Anaesthesiology,
SCTIMST, Thiruvananthapuram.

CERTIFICATE

This is to certify that the thesis entitled “**BEDSIDE CHEST ULTRASOUND IN POST OPERATIVE PAEDIATRIC CARDIAC SURGERY PATIENTS: COMPARISON WITH BEDSIDE CHEST RADIOGRAPHY**” is the bonafide work of *Dr. DON JOSE PALAMATTAM*, Senior Resident, conducted in the Division of Cardiothoracic and Vascular Anaesthesiology, Department of Anaesthesiology, at Sree Chitra Tirunal Institute for Medical Sciences & Technology, Thiruvananthapuram under our supervision and guidance. He has shown keen interest in preparing this project.

(GUIDE)

Dr. Rupa Sreedhar

Senior Professor,
Department of Cardiothoracic and
Vascular Anesthesiology,
SCTIMST, Thiruvananthapuram,
India.

(CO-GUIDE)

Dr. Prashanta Kumar Dash

Professor,
Department of Cardiothoracic and
Vascular Anesthesiology,
SCTIMST, Thiruvananthapuram,
India.

(CO-GUIDE)

Dr. Baiju S Dharan

Professor and Head,
Department of Cardiothoracic and
Vascular Surgery,
SCTIMST, Thiruvananthapuram,
India.

(CO-GUIDE)

Dr. Shrinivas Gadhinglajkar

Professor,
Department of Cardiothoracic and
Vascular Anesthesiology,
SCTIMST, Thiruvananthapuram,
India.

(CO-GUIDE)

Dr. Subin Sukesan

Associate Professor,
Department of Cardiothoracic and
Vascular Anesthesiology,
SCTIMST, Thiruvananthapuram,
India.

(CO-GUIDE)

Dr. Santhosh Kumar K

Associate Professor,
Department of Imaging Sciences
and Interventional Radiology,
SCTIMST, Thiruvananthapuram,
India.

CERTIFICATE

This is to certify that the thesis entitled “**BEDSIDE CHEST ULTRASOUND IN POST OPERATIVE PAEDIATRIC CARDIAC SURGERY PATIENTS: COMPARISON WITH BEDSIDE CHEST RADIOGRAPHY**” has been prepared by *Dr. DON JOSE PALAMATTAM*, DM Cardiothoracic and Vascular Anaesthesiology Resident, Division of Cardiothoracic and Vascular Anaesthesiology, Department of Anaesthesiology, at Sree Chitra Tirunal Institute for Medical Sciences & Technology, Thiruvananthapuram. He has shown keen interest in preparing this project.

Date:

Place: Thiruvananthapuram

Prof. Dr.Thomas Koshy,

Senior Professor and Head,
Division of Cardiothoracic and
Vascular Anaesthesiology,
Department of Anaesthesiology,
SCTIMST, Thiruvananthapuram,
India.

ACKNOWLEDGEMENT

*I take this opportunity to express my deep sense of gratitude and thanks to all those who have been instrumental in the successful completion of this work. I am deeply indebted to my esteemed teacher and guide, **Prof. Dr. Rupa Sreedhar**, Senior Professor, Department of Cardiothoracic and Vascular Anesthesiology, Sree Chitra Tirunal Institute for Medical Sciences and Technology, for her unremitting encouragement, avid support and invaluable guidance throughout the course of my study.*

*I would also like to express my deep gratitude and regards to my co-guide, **Prof Dr. Shrinivas Gadhinglajkar**, Department of Cardiothoracic and Vascular Anesthesiology, Sree Chitra Tirunal Institute for Medical Sciences and Technology. Without his guidance, support and personal involvement, the work could never have been completed.*

*I express my sincere thanks to my co-guides **Prof. Dr. Prashanta Kumar Dash** , **Dr. Subin Sukesan** Associate Professor, Department of Cardiothoracic and Vascular Anesthesiology, Sree Chitra Tirunal Institute for Medical Sciences and Technology, for their constant support and guide throughout the conduct of study.*

*I am indebted to my co-guides, **Prof. Dr Baiju S Dharan**, Professor and Head, Department of Cardiothoracic and Vascular Surgery and **Dr. Santhosh Kumar K**, Associate Professor, Department of Imaging Sciences and Interventional Radiology, Sree Chitra Tirunal Institute for Medical Sciences and Technology, for their insights and assistance in conduct of the study.*

*All my teachers, **Prof. Dr. Thomas Koshy**, Senior Professor & Head, **Prof. Dr. Suneel P.R.**, **Prof. Dr. Unnikrishnan K.P.** and **Dr. Saravana Babu**, Assistant Professor, Department of Cardiothoracic and Vascular Anesthesiology, Sree Chitra Tirunal Institute for Medical Sciences and Technology have been extremely helpful during the conduct of the study and have given their invaluable opinion and constructive criticism.*

*My sincere thanks to my fellow surgical colleagues, **Dr. Kiran, Dr. Manfred JXA Fernando and Dr. Sri Raman** for their patience and help with interpreting and reporting Chest X-ray as a part of the study.*

*I am thankful to my fellow residents for their unconditional support throughout the study. **Dr. Santhosh, Dr. Ankur, Dr. Kiran and Dr. Nayana** deserve special mention. I am thankful to all my seniors and juniors who gave valuable suggestion during course of the study.*

I express my gratitude to nursing staff in Paediatric post operative cardiothoracic and vascular intensive care unit (CHICU) for their support to conduct the study in a successful manner.

I would like to take this opportunity to show my gratitude to all my patients who volunteered to be part of this study.

Last but not least, I thank the Almighty and express my heartiest gratitude to my parents, my wife, son and my in-laws who have been a constant source of motivation and encouragement.

Date:

*Place: **Thiruvananthapuram***

Dr. Don Jose Palamattam

ABBREVIATIONS

CXR : Chest X-ray

CUS : Chest ultrasound

US : Ultrasound

CT: Computed Tomography

ACR : American college of Radiology

AP : Antero-posterior

EVLW : Extra vascular lung water

PE: Pericardial effusion

PI : Principle investigator

PACS : Picture archiving and communication system

ETT : Endotracheal tube

PPV : Positive Predictive Value

NPV : Negative Predictive Value

TTE : Transthoracic Ecocardiography

ICU : Intensive care unit

ACHD : Acyanotic congenital heart disease

CCHD : Cyanotic congenital heart disease

POD : Post operative day

BLUE: Bedside Lung Ultrasound in Emergency

RUSH: Rapid Ultrasound in SHock

CONTENTS

<u>Sl. no.</u>	<u>TOPIC</u>	<u>Page No.</u>
1.	INTRODUCTION	1 - 3
2.	REVIEW OF LITREATURE	4 -16
3.	AIM OF THE STUDY	17
4.	MATERIAL AND METHODS	18 - 30
5.	SATISTICAL ANALYSIS	31
6.	OBSERVATIONS	32 - 51
7.	DISCUSSION	52 - 56
8.	LIMITATIONS	57 - 58
9.	CONCLUSION	59 - 60
10.	REFERENCES	61 - 75
11.	APPENDICES	
	INFORMED CONSENT FORM	76 - 85
	INFORMED ASSENT FORM	86 - 90
	OBSERVATION CHART	91 - 93
	TAC APPROVAL LETTER	94 - 95
	IEC APPROVAL LETTER	96 - 97
	PLAGIARISM CHECK	
	MASTER CHART	

INTRODUCTION

Traditionally, chest imaging in post operative cardiac surgical patients, is performed using bedside chest radiography (CXR). It is considered as standard of care to evaluate intra-thoracic structures including heart, lung, mediastinum and their abnormalities. CXR also evaluates position of chest tubes, mediastinal tubes, central venous lines, pulmonary artery catheters, endotracheal tubes and enteral feeding tube [1].

Respiratory complication is one of the major causes of morbidity and death in cardiac post operative patients in adult and pediatric population. Whenever there is a suspicion of intra thoracic pathology, including improper position of tubes and catheters, the need for repeated bedside CXR and thus subsequent unavoidable radiation exposure is inevitable. Other factors leading to the need for repetition of bedside CXR are suboptimal X-ray films, improper positioning of patient and poor correlation with CT scan [2].

Each bed side CXR exposes a patient to 0.02 milli-sieverts of radiation [3]. Though it looks invariably small, repeated CXRs exposes patient to increasing amounts of radiation. Paediatric age group especially neonates , have greater areas of exposure, due to small body surface area and are thus sensitive to hazardous effects of ionizing radiation. The threat of developing immune dysfunction, cataract, cognitive decline and malignancy in later part of life is a possibility [4]. Therefore, effort should be made to minimize radiation exposure whenever possible [5].

Chest ultrasound (CUS) is a fast, repeatable and radiation free methodology.

It is simple to use and requires a limited period of training [6]. It allows for bedside detection of primary pulmonary pathologies [7] such as pleural effusion, pneumothorax, lung atelectasis, or secondary pulmonary pathologies due to cardiac causes (interstitial pulmonary oedema, basal atelectasis) and conditions such as diaphragmatic palsy, subcutaneous emphysema, pericardial effusion, cardiac tamponade and endobronchial intubation [8]. Examination can be done alone or in combination with echocardiography and intravascular volume assessment, thus reducing cost and time.

Diaphragmatic dysfunction, due to phrenic nerve injury, is a complication in postoperative cardiac surgery patients, with an incidence between 0.3% - 20% [9]. Most phrenic nerve injuries are due to transient neuroapraxia of the nerve, secondary to traction, local application of cold solutions, or accidental injury [10]. Rarely, it is caused by direct transection of the phrenic nerve. Diaphragmatic dysfunction impedes normal lung expansion during inspiration [9] and weaning from mechanical ventilation becomes difficult. It is associated with prolonged ventilatory support, intensive care stay, increased risk of nosocomial infections, and an overall morbidity and death [11].

Chest fluoroscopy is the gold standard for diagnosis of diaphragmatic dysfunction. But it is associated with shifting of critically ill children to radiology suite and exposure to higher ionizing radiation. Other modalities include phrenic nerve conduction studies and CUS. CUS being a rapid and easily available technique at the bedside, allows for early diagnosis of abnormal diaphragmatic motion [12].

The use of CUS in the post operative adult cardiac patients is gaining popularity [6]. However, there is little data available concerning the use of CUS in the post operative cardiac pediatric and neonatal populations [13]. To address the above issue, we intend to study the degree of agreement between CUS and CXR; to compare the diagnostic performance of bedside chest ultrasound (CUS) with bedside chest radiography (CXR), for the detection of abnormalities of thorax including abnormal diaphragmatic motion, in postoperative pediatric cardiac surgical patients. We also intend to compare the therapeutic interventions done on basis of CUS and CXR derived information in the postoperative setting.

REVIEW OF LITERATURE

Pulmonary complications in post operative congenital cardiac patients, represents a significant cause of morbidity, and mortality [14]. Cardiopulmonary bypass and surgery, induces inflammatory response and is responsible for postoperative pulmonary dysfunction [15]. This inflammatory response is more relevant in children, where other factors contributing to pulmonary dysfunction may coexist, such as pulmonary hypertension and diaphragmatic palsy [16]. This leads to prolonged mechanical ventilation, hospital stay and repeated examinations leading to high costs [17]. Pulmonary dysfunction may be due to primary pulmonary pathology (pleural effusion, pneumothorax, atelectasis, pneumonia) or secondary due to cardiac causes (interstitial edema, systolic or diastolic dysfunction, basal atelectasis) and conditions such as diaphragmatic palsy and subcutaneous emphysema [14, 17].

Although CT chest is the gold standard for thoracic imaging, it is expensive and cannot be performed on a routine basis, as transportation of critically ill patients to the radiology suite is cumbersome and radiation exposure carries a considerable risk [18]. Conventionally, chest imaging in post operative cardiac patients is performed using bedside CXR. It is the standard of care to evaluate intra-thoracic structures including heart, lung, mediastinum and their abnormalities [1, 19]. CXR also evaluates the position of chest tubes, mediastinal tubes, central venous lines, pulmonary artery catheters, endotracheal tubes and enteral feeding tube [1].

The American College of Radiology (ACR) recommends routine daily chest radiographs for mechanically ventilated patients and use of additional CXRs if necessary

[20]. Routine CXRs theoretically has the advantage of discovering and treating potentially life-threatening situations that might otherwise be missed. Additional CXRs are needed when there is a suspicion of intra thoracic pathologies or after placement of an endotracheal tube, central venous catheter, Swan-Ganz catheter, life supporting intervention, or change in clinical condition of patients [21]. Another factor leading to the need for repetition of bedside CXR are suboptimal X-ray films, improper positioning of patient and poor correlation with CT scan. In spite of carefully controlled exposure conditions, more than 30% of the X-ray films are considered suboptimal [2].

Excessive repetition of X-Ray examinations has been criticized [22]. According to Picano E et al, each CXR exposes a patient to 0.02 milli-sieverts of radiation [3]. The Commission of European Communities (ECs) has recommended a maximum dose of 80 μ Gy for chest radiographs in neonates [23]. Paediatric age group especially neonates, are sensitive to the deleterious effects of radiation due to small body surface area. The risk of developing radiation induced complications including malignancy & genetic damage in later part of life is a possibility [4]. Restrictive CXR strategy must be the norm and must be used only when clinical situation demands it.

Sonography is based on the principle that, ultrasound waves are reflected by an interface between media with different acoustic impedances [24]. For many years, the lung was believed to be unsuitable for examination by ultrasound [25]. In normally aerated lungs, when the ultrasound waves meet air, no image is visible due to the absence of the acoustic mismatch. The beam stops when it reaches the lung or any gas filled

structure [26]. In adults, the bones of the thoracic cage limit the use of lung ultrasound as the attenuating effect of bone is greater than other tissues [24]. Waves reaching bone are completely reflected back to the transducer. The chests of infant and children have unossified costal cartilages and sternum which provide suitable acoustic window [27].

Ultrasonography of lung is based on the production of artifacts. An ultrasound artifact is the incorrect interpretation of the returning signal by the ultrasound machine [28]. It is now recognized that ultrasonography is highly sensitive to variations in the pulmonary content of fluid and balance between air and fluid [26]. In 1989, Francois Jardin made chest ultrasound an integral part of care in critically ill patients. It was only in 2009 that the American College of Chest Physicians and La Société de Réanimation de Langue Française in France jointly proposed chest ultrasound as a standard of care for critically ill patients [29].

Recent studies have shown that the sensitivity and specificity of the chest ultrasonogram is comparable to a CT scan of the chest [30, 31]. Since a decade, point-of-care ultrasonography (POCUS) is used for adult patients to detect pulmonary, pleural and diaphragmatic pathologies. It can now safely be extrapolated to the paediatric group for the diagnosis of intra thoracic pathologies.

BLUE PROTOCOL

Lichenstein et al suggested the BLUE (Bedside Lung Ultrasound in Emergency)

protocol in adults, to study the lung systematically by ultrasonography. A total of 9 profiles were described and it aids to arrive at a reasonable respiratory diagnosis [32].

NORMAL LUNG

On ultrasonography, normal pleura is seen as a smooth echogenic line (parietal pleura), with a hypo-echoic line (visceral pleura) below it. Characteristic of normal findings includes lung sliding, A-line and comet-tail artefacts [33]. Lung sliding is the rhythmic movement of the visceral pleura relative to the fixed parietal pleura, which is separated by a thin layer of intra-pleural fluid [34]. A-lines are a result of reverberation artefacts which appear as bright white, hyper echoic, semi-circular repeating horizontal lines which are found deep to the pleural line generated by air within the lungs. They are separated by regular intervals, the distances of which being equal that between the skin and the pleural line. They do not move with respiration [35]. Comet-tail artefacts are formed by the reverberation echoes, arising due to the irregularity of the lung surface which move with respiration. They have a sensitivity of 100% and a specificity of 60% for normal lung [34].

PLEURAL EFFUSION

Lichtenstein D et al [36] reported that portable CUS has a higher accuracy in detecting pleural effusion in comparison with bedside CXR (93% vs. 47%). Keeping CT thorax as a gold standard, Xirouchaki N et al [31] showed that CXR had a sensitivity of 65%, specificity of 81% and diagnostic accuracy of 69% whereas CUS had a sensitivity

of 100%, specificity of 100% and a diagnostic accuracy of 100% in detection of pleural effusion. In a meta-analysis done by Yousefifard M et al [37], it was found that the sensitivity and specificity of CUS in detection of pleural effusion was 94% (p<0.001) and 98% (p<0.001) respectively, as compared to 51% (p<0.001) and 91% (p<0.001) respectively for CXR.

Blunting of the costo-phrenic angle in adults, takes place when there is a minimum of 150-200 ml of fluid [38]. In lateral chest radiographs, as little of 50 ml can be picked up. However, with CUS, as little as 20 ml can be detected [39]. Balik et al [40], suggested a simple formula to calculate the volume of pleural effusion in adult patients. Volume of pleural effusion V (ml) =20 × sep (mm), where sep is the maximum separation of visceral and parietal pleura by effusion in transverse section of thorax by ultrasound.

Ultrasound in an effusion shows a dark anechoic space above the diaphragm with absence of the mirror artifact. The parietal pleural line is fixed whereas the visceral pleural line, along with lung moves with each respiratory cycle. This is seen as sinusoidal waveform on M mode and is the sonographic sign of pleural effusion [32].

In case of a transudative effusion, it is usually anechoic and homogenous because the fluid contains no ultrasound reflectors. An exudative is characterised by complex, echogenic, septate effusions with particles within the fluid. Homogeneous echogenic effusions are usually hemorrhagic effusions or empyema [41].

PNEUMOTHORAX

Kirkpatrick AW et al [42] reported that in trauma patients, keeping CT as the gold standard, CUS had higher sensitivity than CXR (48.8 % vs. 20.9%) and a similar specificity (99.6% vs. 98.7%) for the detection of pneumothorax. Ball CG [43] reported that up to 76% of occult pneumothoraxes were missed by initial antero-posterior (AP) CXR study of trauma patients.

Keeping CT as the gold standard, Lichtenstein DA [44] showed that in ICU setting ultrasound has a sensitivity of 95.3% and specificity of 91.1% in picking up a pneumothorax. Balesa J [45] showed that the sensitivity and specificity of chest ultrasound were 89% and 88.5% respectively for the detection of pneumothorax when compared with CT thorax. In a study for pneumothorax detection after lung biopsy, Sartori S et al [46] showed that ultrasonography has 100% sensitivity, specificity, positive predictive value (PPV) and negative predictive (NPV) value when compared to CXR, which had 87.5% sensitivity, 100% specificity, 100% PPV, and 99.6% NPV.

A meta – analysis carried out by Ding W et al [47] which included 20 articles, showed that the pooled sensitivity and specificity were 0.88 and 0.99 for chest ultrasonography and 0.52 and 1.00 respectively for CXR for the detection of pneumothorax. There was no significant difference in the sensitivity and specificity when the ultrasonogram was carried out by a clinician other than a radiologist. Meta analysis conducted by S. Alrajab et al [48] also showed similar results. A systematic review by Azad et al [49] suggested the addition of lung ultrasonography to diagnose pneumothorax

in critical care settings.

The cardinal feature of a normal lung is the presence of lung sliding. B-lines are discrete, reverberation artefacts that arise from the visceral pleura and are seen in normal lung. They extend to the bottom of the screen and move with lung sliding [50]. In M-mode, a normal lung will show two different appearances – stationary linear repeating lines closer to the pleural line, with an irregular choppy appearance deeper to the pleural line signifying lung. This is known as the seashore sign [51].

The hallmark signs of a pneumothorax are absence of lung sliding, absence of B-lines, absence of lung pulse and presence of the lung point [52]. The M-mode is also used to confirm the presence of a pneumothorax. M-mode shows only linear repeating lines, with the absence of the irregular choppy appearance of the lung. This is known as the stratosphere or barcode sign [53].

The lung point sign is specific for detection of a pneumothorax. It is seen in an incomplete pneumothorax when the air between the layers of pleura abuts the normal pleura. Therefore, in the same field, there will be absence of lung sliding in one area with normal lung sliding and comet tail artefacts in the other. The presence of lung point has a specificity of 100% to detect a pneumothorax. However, the sensitivity is only 66% [54]. In a supine patient, location of lung point at mid axillary line indicates 15% lung collapse (small pneumothorax) and lateral progression of lung point in serial lung ultrasound indicates increasing pneumothorax volume [55].

CONSOLIDATION

Consolidation is a pulmonary pathology which converts aerated lung to a tissue like echo texture. Pagano A et al [56] showed that the sensitivity and specificity of ultrasonogram was much higher than CXR (98.5% vs. 73.5%) and (64.9% vs. 59.5%) in detection of consolidation. Keeping CT as a gold standard Liu X et al [57] found that the sensitivity, specificity, and accuracy for ultrasonography and CXR for diagnosing consolidation were 94.6% versus 77.7% ($p < 0.001$), 98.5% versus 94.0% ($p = 0.940$) and 96.1% versus 83.8% ($p < 0.001$) respectively. Keeping CT as a gold standard, a study by Nazerian P [58] showed similar results in detection of consolidation by ultrasound. In a meta-analysis done by Chavez MA [59] from 10 articles concluded that for ultrasound pooled sensitivity and specificity were 94% and 96% respectively in detection of consolidation.

A consolidated lung exhibits a liver like echo texture on ultrasound. Air and fluid bronchograms can be seen within consolidated lung. Air bronchograms are dynamic and echogenic foci that fluctuate with the respiratory cycle. Fluid bronchograms on the other hand are seen as anechoic tubular structures which represent fluid filled airways [60].

Alveolar consolidations have dynamic bronchograms which signifies pneumonia, in contrast to atelectasis which has static bronchograms. This finding on ultrasound was found to have a specificity of 94%, sensitivity of 61% and a PPV of 97% [61]. CUS also useful to follow up lung recruitment by using positive end expiratory pressure in consolidated lung [62]

ALVEOLAR INTERSTITIAL EDEMA

A condition which arises due to leakage of fluid into the pulmonary interstitium and alveolar spaces resulting in impaired gas exchange [63].

Agricola E et al [28] conducted a study on the accuracy of ultrasonogram to diagnose pulmonary edema and compared it with CXR, wedge pressure and extravascular lung water (EVLW). They found significant positive linear correlations between ultrasonogram and wedge pressure. Zhou S et al [64] reported that ultrasonogram showed a sensitivity of 80.60%, specificity of 77.60%, PPV of 65.80% and NPV of 88.20% in the diagnosis of pulmonary edema as compared to CXR which showed a sensitivity of 74.20%, specificity of 69.00%, PPV of 56.10% and NPV of 83.30% in the diagnosis of pulmonary edema. In a meta- analysis of 7 articles for pulmonary edema, by Al Deeb M et al [65], showed chest ultrasound having sensitivity of 94.1% and specificity of 92.4% for detection of pulmonary edema.

Sonographic signs of interstitial fluid are seen as B-lines on lung ultrasound. These are vertical hyper echoic artifacts formed secondary to reflection of the waves at the interlobular septa. Lichtenstein D [66] described B lines by seven criteria to distinguish from other artifacts such as Z-lines and E-lines. B lines 1) always arises from the pleural line, 2) moves with lung sliding 3) is long and reaches edge of the screen 4) has a comet tail artifact 5) is well defined and laser like 6) obliterates A-lines 7) is hyper echoic like the pleural line. Z-lines are shorter artifacts that are seen at the pleural interface and do not reach the edge of the screen. E-lines are very similar to B-lines but arise above the pleural line indicating subcutaneous emphysema.[35]

Ultrasound is useful for the diagnosis of pulmonary edema with a sensitivity and specificity of 97% and 95%, respectively [66]. The presence of three or more B –lines in each of two or more lung regions bilaterally indicates interstitial syndrome [35]. Other findings that contribute to a diagnosis of pulmonary edema is the presence of pleural effusion, distension of inferior vena cava and poor cardiac contractility.

Increased B- lines can be due to diffuse parenchymal disease or interstitial edema. In interstitial edema, B-lines are homogenous (regularly spaced). In diffuse parenchymal lung disease, B-lines are non homogenous (irregularly spaced) and associated with pleural line abnormality and sub pleural pathology [52].

Lung rocket is used to describe three or more B-lines between two ribs. They correlate with interstitial syndrome with 100% accuracy when compared to CT [66]. Number of B–lines correlate with volume of extra vascular lung water (EVLW). B-lines are decreased when EVLW is removed by hemodialysis [67].

DIAPHRAGMATIC DYSFUNCTION

The diaphragm is the main muscle of inspiration and is responsible for 75% of normal breathing effort in pediatric age group [68]. Diaphragm dysfunction indicates either paresis or paralysis. Diaphragmatic dysfunction, due to phrenic nerve injury, in paediatric cardiac surgery patients, has an incidence between 0.3% - 20% [9]. Most phrenic nerve injuries are due to transient neuroapraxia of the nerve, secondary to traction, local application of cold solutions, or accidental injury [10]. Rarely, it is caused

by direct transection of the phrenic nerve. Unilateral diaphragm dysfunction compromises pulmonary function by about 25% [68]. Diaphragmatic dysfunction impedes weaning from mechanical ventilation and is associated with prolonged ventilatory support and ICU stay [12].

Diagnosis of diaphragmatic dysfunction is based on a high index of suspicion. Paralysis may be suspected by an elevated hemidiaphragm on CXR. Its confirmation requires dynamic assessment of diaphragm mobility. Different imaging modalities [22], including ultrasound, electromyography, nuclear magnetic resonance or video-fluoroscopy can be used for study of diaphragm mobility, of which chest fluoroscopy is considered to be the gold standard [69]. Chest ultrasound being readily available at bedside, allows for early diagnosis of abnormal diaphragmatic motion [12].

Noh K Dong [70] reported that in asymptomatic adults, ultrasonography and fluoroscopy was equally effective in detecting diaphragmatic movements. A study by Taggu A [71], predicted successful extubation in adult patients, by using bedside ultrasound measurement of diaphragm thickness, just before extubation. They concluded that ultrasound can be used as a tool for assessment for weaning failure from mechanical ventilation. Kim WY et.al [72], reported that vertical excursion of diaphragm less than 1.0 cm, using ultrasound caused failed weaning and prolonged ventilation in adult patients. Sarwal et al [73] using ultrasound reported that diaphragmatic excursion of less than 1.4 cms for right hemidiaphragm and less than 1.2cm for left hemidiaphragm caused weaning failure in adult patients

Epelman et al [74] studied post operative cardiac patients aged from 3 days to 17 years and proposed a protocol for the evaluation of diaphragmatic mobility by ultrasound. Initially both hemidiaphragms were imaged by placing the transducer in an oblique transverse subxiphoid plane in the midline and in each subcostal region where both hemidiaphragms are imaged separately in the coronal plane. The movement of each hemidiaphragm is evaluated using M-mode. In assisted mechanical ventilated patients, the ventilator should be temporarily disconnected for a correct evaluation of diaphragmatic motion.

Urvoas et al. [75] using ultrasound classified diaphragm mobility in children as: normal, paresis (decreased or weakness), or paralysis (absent motion or paradoxical motion). Normal motion is defined as mobility towards the transducer in inspiration; the excursion of diaphragm is >4 mm and the difference of excursion between the hemidiaphragms is $<50\%$. Decreased motion is defined as excursion of diaphragm ≤ 4 mm and the difference of amplitude between the hemidiaphragms is $>50\%$. Absent motion is defined as trace showing a flat line. Paradoxical motion is defined as diaphragmatic motion away from the transducer during inspiration.

ENDOBRONCHIAL INTUBATION

Inadvertent endobronchial intubation can be as high as 30% for pediatric population and 7% for the neonatal population [76]. Unrecognized endobronchial intubation increases the risk of hypoxia and barotrauma [77]. Chun R et al [78] confirmed with ultrasound that successful intubation with an ETT has occurred using either the

sliding lung sign or by diaphragmatic motion along the lateral chest wall. Sim SS et al [79] reported that, during emergency intubation, using ultrasound, absence of lung sliding in one hemi thorax diagnosed endobronchial intubation of opposite bronchus with a PPV of 94.7% and an accuracy of 88.7%. They concluded that ultrasound had a considerable time and advantage over chest X-ray in emergency settings. Hsieh KS [80] reported that paradoxical motion of diaphragm on one side served as a secondary sign of endobronchial intubation using chest ultrasound.

PERICARDIAL EFFUSION

The incidence of Pericardial Effusion (PE) was reported to be 10%–13.6% after congenital cardiac surgeries [81]. PE causes hemodynamic compromise and contributes to postoperative morbidity and mortality. PE commonly occurs more after Fontan and Ross procedure [81]. Ultrasound can quickly rule out pericardial effusion or can aid in pericardiocentesis in presence of cardiac tamponade in post operative period. Erkut O et al [6] compared the diagnostic efficacy of ultrasound and CXR for pericardial effusion in 60 neonates after cardiac surgery. They concluded that ultrasound was better than X-ray for the diagnosis of pericardial effusion. Only 16% of the cases with PE could be diagnosed by CXR.

AIM OF THE STUDY

AIMS AND OBJECTIVES

Primary Objectives

- 1) To study the degree of agreement between bedside chest ultrasound (CUS) and bedside chest radiography (CXR) in post operative paediatric cardiac surgical patients.
- 2) To compare the diagnostic performance of bedside chest ultrasound (CUS) with bedside chest radiography (CXR) in form of sensitivity, specificity, positive predictive value (PPV) and negative predictive value (NPV) for the detection of various pathologies of the lung such as pneumothorax, pleural effusion, interstitial syndrome, atelectasis, consolidation and other abnormalities in thorax including pericardial effusion and abnormal diaphragmatic motion.

Secondary Objectives

- 1) To compare the interventions done on basis of CUS and CXR derived information including endotracheal tube & central venous catheter repositioning, chest tube placement for pleural effusion and pneumothorax, lung recruitment for atelectasis, pericardial drainage for pericardial effusion, need for intravenous fluid or diuretic administration in the postoperative setting.

MATERIAL AND METHODS

Study Design:

Prospective, observational study.

Setting:

SCTIMST, a tertiary referral center and university level hospital, annually performing 700 paediatric cardiac surgeries.

Approval from Institutional Ethics Committee:

Our study was approved by the Technical Advisory Committee (TAC) and Institutional Ethics Committee (IEC) of SCTIMST. TAC registration number was SCT-/S/2018/740 & IEC registration number was SCT/IEC/1223/JUNE-2018.

Participants:

Children who got admitted in post operative Pediatric Cardio-Thoracic Intensive Care Unit after surgery from May 2018 to June 2019.

Informed consent:

Informed written consent was obtained from the patient's parents/relatives. Patient parents/ relatives were educated about the study protocol. An informed assent was also obtained from participants above 12 yrs of age

Study groups:

Chest ultrasound (CUS) and chest x ray (CXR) was studied and compared in same group of patients.

Sample size:

Based on previous study by Ariza et al [82], considering an agreement between chest X-ray and chest ultrasound for pneumothorax (Kappa value $k=0.7$) and for a power of 90% , confidence interval of 95% and alpha error of 0.05, a minimum of 147 patients were required to be studied. We included a sample size of 160 patients in our study. Statistical analysis was done with SPSS software, IBM, version 25.

Inclusion criteria:

1. Children who undergo elective cardiothoracic and vascular surgery.
2. Age group: 1 month to 18 yrs

Exclusion criteria: Patients with:

1. Open sternum.
2. Hemodynamic instability
3. Emergency surgery
4. Refusal of consent

STUDY PROTOCOL

On the day before surgery, patient's parents/relatives were educated about the study and informed consent/assent was obtained.

Soon after shifting the patient to pediatric cardio thoracic ICU following surgery, bed side CXR was done, followed by CUS examination by the principal investigator (PI). CXR was interpreted by the surgical colleague in the ICU. The PI was blinded to the

findings of CXR and the surgeon was blinded to the findings of CUS. A provisional diagnosis was made and the intervention required was decided after each modality of diagnosis. The entire procedure was repeated next day morning. The findings and intervention planned after CUS and CXR was compared and analyzed statistically. The data was kept by the PI. The patient details were kept confidential.

BEDSIDE CHEST X-RAY (CXR) PROTOCOL

With the patient in semi-recumbent position, an antero-posterior CXR is taken using portable X –ray machine (SIEMENS, multimobil, Goa, India). For optimal imaging, technical factors recommended by the ACR were followed [83]. The source to image distance (SID) was adjusted above 40 inches. The CXR images were archived in Picture Archiving and Communication System (PACS). The image was interpreted by the surgical colleague who was blinded to the diagnosis made using CUS.

The recommendation of Nomenclature Committee of Fleischner Society was used for the diagnosis of pleural effusion, pneumothorax, consolidation, atelectasis, interstitial edema, mediastinal widening [84]. Diaphragmatic weakness was indicated by abnormal elevation of hemi-diaphragm in relation to that of the opposite side. Position of endotracheal tube (ETT) tip above the carina was considered as normal. Position of the ETT tip in any bronchus was considered endobronchial intubation. Mediastinal widening was indicated by increased cardio-thoracic ratio in comparison to that of the previous CXR. Report of CXR was recorded in a proforma.

CHEST ULTRASOUND PROTOCOL

Chest Ultrasound was done with the patient in semi recumbent position. We used a linear probe with frequency range of 6-12MHz (Esaote Mylab one, Genova, Italy) for studying pleura and lung (**Fig.1**) and a convex probe with a frequency of 3-8 MHz (Philips, IE33 S8-3, Bothwel , USA) (**Fig.2**) for studying pericardial effusion.



Figure 1 - Esaote my lab one linear probe (6-12 MHz)



Figure 2- Philips, IE33 S8-3 probe (3-8 MHz)

Each hemithorax was divided into 6 sections using 3 longitudinal lines (parasternal, anterior axillary and posterior axillary) and 2 axial lines, one above the diaphragm and another one just above the nipples. Thus each hemithorax is divided into 3 areas: anterior area between sternum and anterior axillary line, lateral area between anterior and posterior axillary line and posterior area between the posterior axillary line and the spine. Each hemithorax was studied by placing the probe perpendicular to the ribs. The examination sequence in each hemithorax was followed as: (1) anterior, (2) lateral and (3) posterior regions starting from the diaphragm and moving toward the apex [85] (**Fig.3**). For insonating posterior thorax, the patient was rolled over to semi-lateral decubitus position.

In both mechanically ventilated and spontaneously breathing patients, diaphragmatic excursion was studied in anterior subcostal region and mid axillary region. In the anterior subcostal region, the diaphragm was studied by placing the transducer probe perpendicular to the chest wall, with the probe marker directed to 12 O'clock. In the mid-axillary area the probe was positioned in the eighth or ninth intercostals space and the marker directed to 12 O'clock. (68). Transthoracic ECHO was done to look for any pericardial effusion.

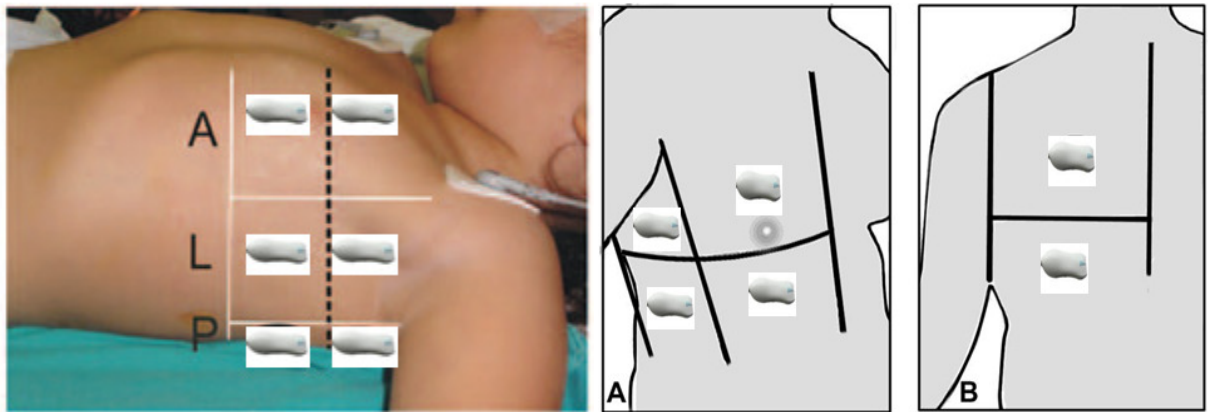


Figure 3--- Division of each hemithorax into 6 regions and position of US probe

Each region was examined for the bat sign (**Fig.4**), lung sliding, A lines (**Fig.5**), Sea shore sign (**Fig.6**), B-lines, sinusoidal sign, quad sign, bar code sign, lung point, tissue like echo texture of lungs, lung pulse and dynamic or static air bronchogram.

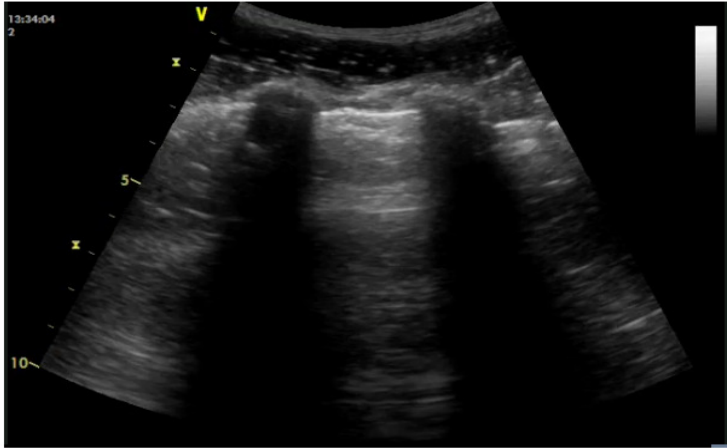


Figure 4 -BAT SIGN of normal lung

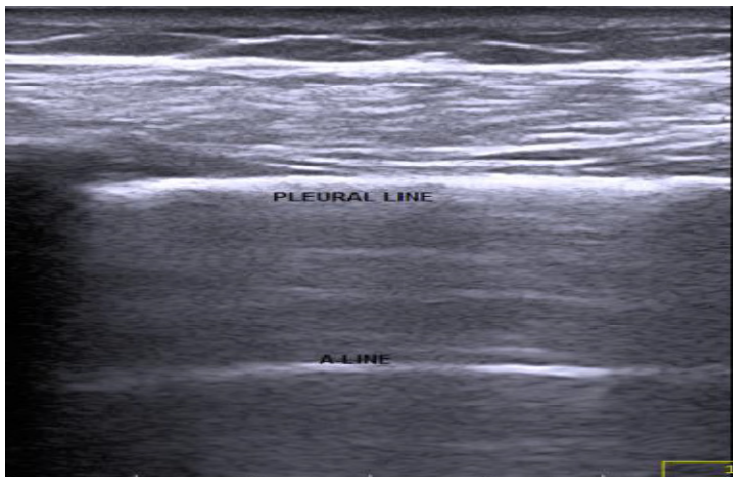


Figure 5 –Pleural line and A line of normal lung

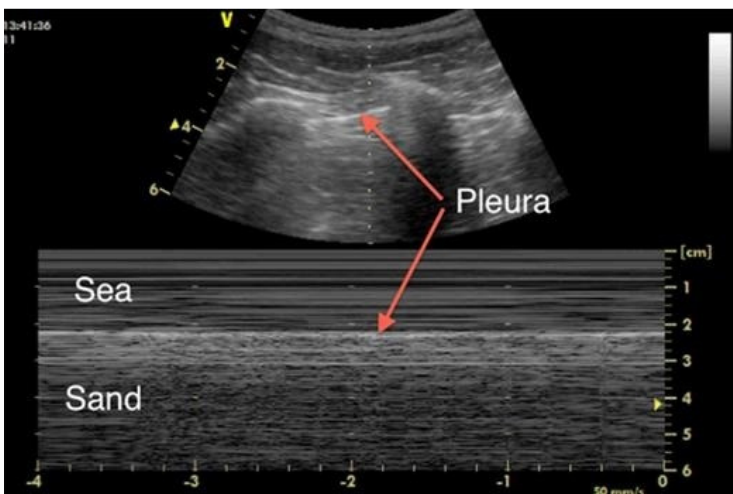


Figure 6 – M mode of normal lung sliding showing sea shore sign

The following chest pathologies were diagnosed as per international evidence based recommendation for point of care lung ultrasound [52].

PNEUMOTHORAX

Pneumothorax was diagnosed based on presence of:

- 1) Absent Lung sliding sign
- 2) Absent B-line
- 3) Presence of Lung point (**Fig.8**)
- 4) Presence of Barcode sign in M-mode (**Fig.7**)

Lung point may or may not be seen in pneumothorax. There will be absence of lung sliding in one area with normal lung sliding in other area. Lung point is sensitive for a small pneumothorax. In large pneumothorax lung point may be absent.

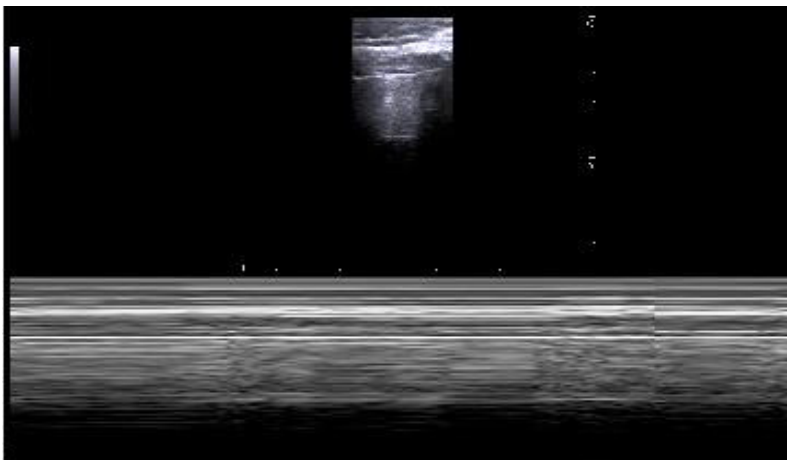


Figure 7 - M-mode showing barcode sign of pneumothorax

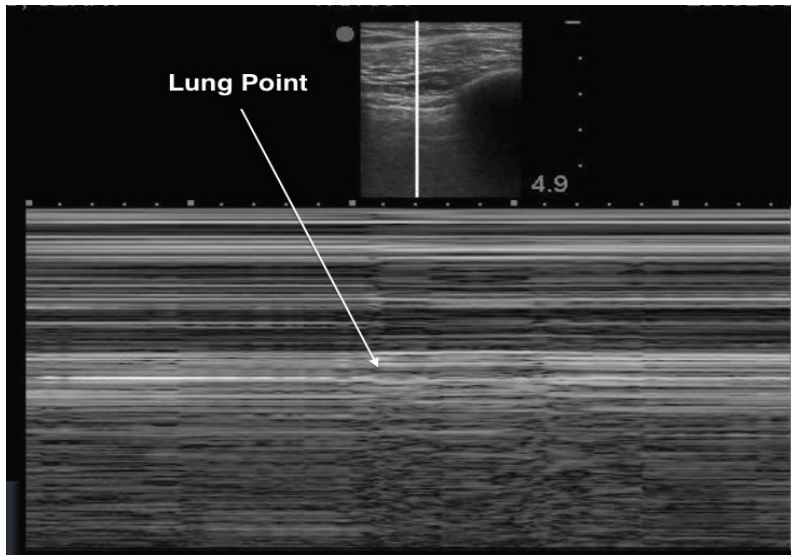


Figure 8 - M-mode in Pneumothorax showing Lung point

PLEURAL EFFUSION

Pleural effusion is detected as anechoic space between parietal and visceral pleura, due to presence of fluid. With rib shadow on either side, along with the anechoic space forms the quad sign of pleural effusion (**Fig. 9 & 10**). The respiratory movement of visceral pleura in the free pleural fluid produces sinusoidal sign. (**Fig. 11**)

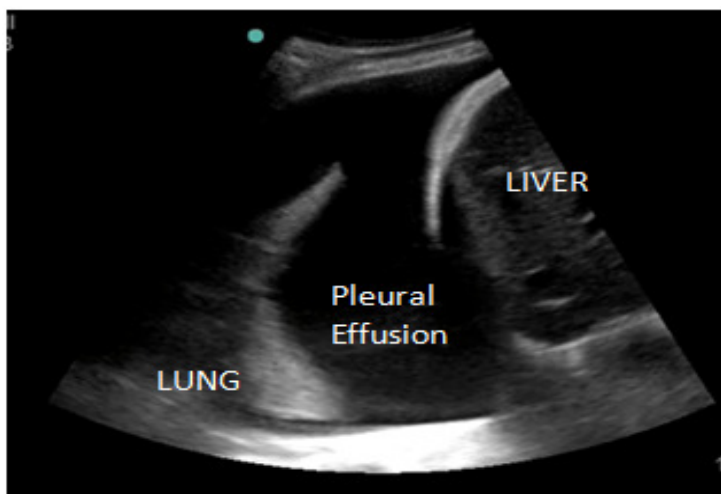


Figure 9 - Right Pleural effusion

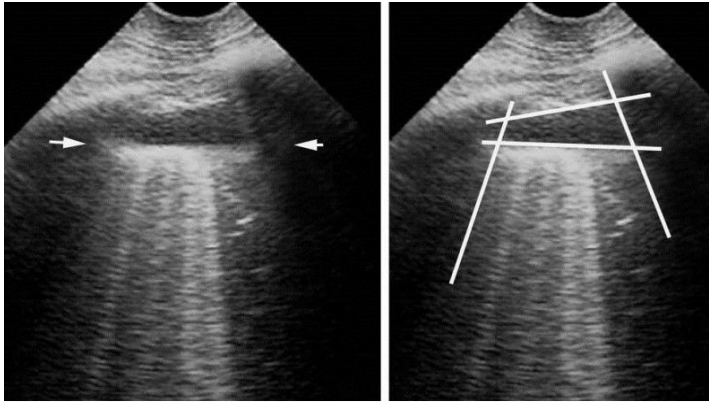


Figure 10 – Quad sign of minimal pleural effusion

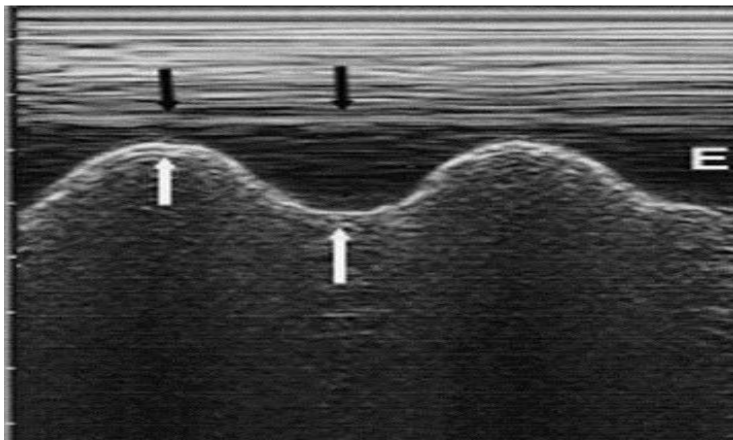
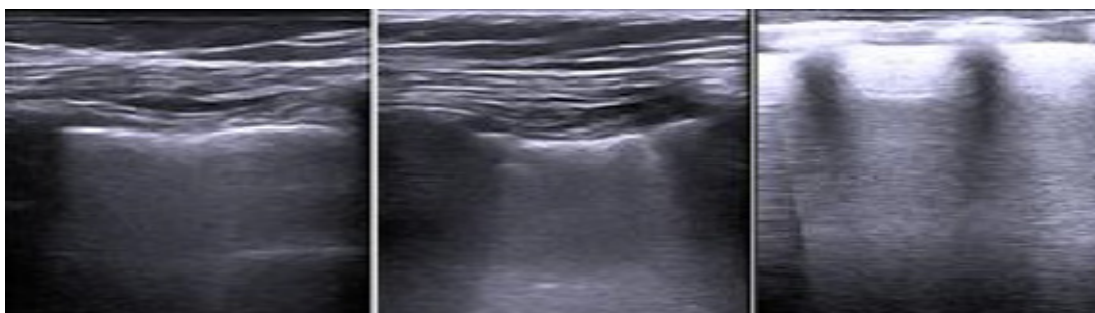


Figure 11 – Sinusoid sign of pleural effusion

INTERSTITIAL EDEMA

Interstitial edema (**Fig.12**) was diagnosed by the presence of more than 3 B-lines in each lung region with at least two lung regions positive in each hemi-thorax. Therapeutic intervention (diuretics) was done when interstitial edema was diagnosed in patients.



(a)

(b)

(c)

Figure 12- Increasing number of B-lines associated with increasing extra vascular lung water. (a) Single B line (b) interstitial edema (c) pulmonary edema

LUNG CONSOLIDATION/ATELECTASIS

Consolidation / atelectasis of lung was diagnosed by the presence of shred sign (**Fig. 13**) or tissue like echo-texture (**Fig.14**). Dynamic air bronchogram is used to differentiate consolidation from atelectasis. It consists of air filled hyper-echoic bronchioles moving centrifugally with respiration and is seen in consolidation (pneumonia). In atelectasis, dynamic air bronchogram sign is absent (static air bronchogram). Lung recruitment manoeuvres were used if atelectasis was diagnosed.

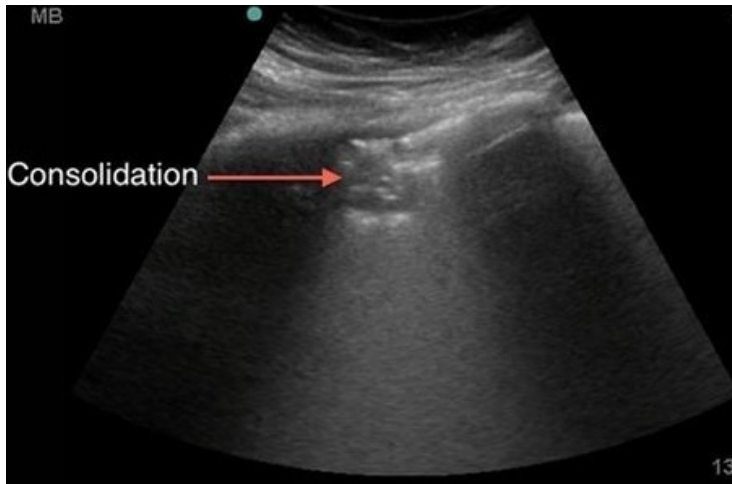


Figure 13 – Shred sign of lung consolidation

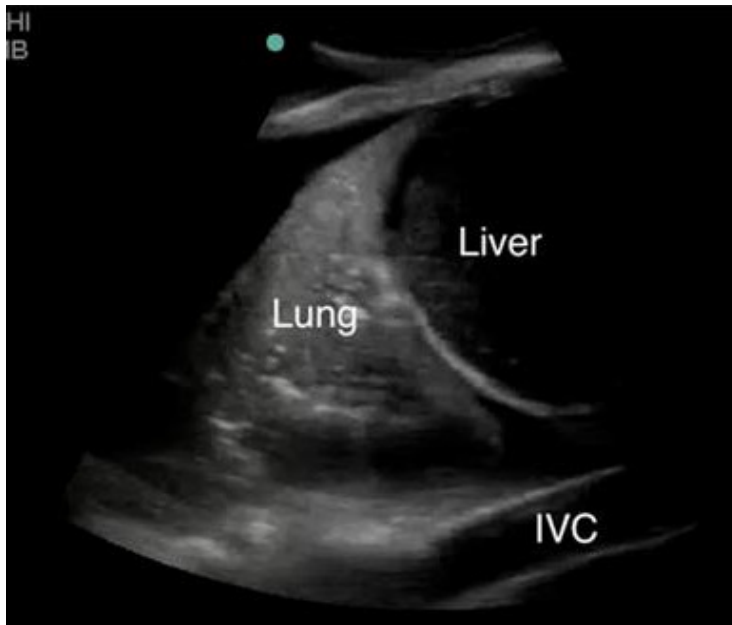


Figure 14 – Tissue like sign of lung consolidation

LUNG ULTRASOUND-GUIDED RECRUITMENT MANEUVER

Recruitment maneuver was performed after ultrasound examination detected atelectasis [86]. Under ultrasound guidance, in pressure controlled ventilation, 5-cm H₂O stepwise increase in pressure was applied from baseline pressures, until no atelectatic

lung areas were visible on the ultrasound. Each level of positive airway pressure was applied for 5 sec. The maximum airway pressure was limited to 40 cm H₂O. After completion of recruitment maneuver, the pre-recruitment ventilator setting was established.

PERICARDIAL EFFUSION

Transthoracic echocardiogram (TTE) was used to rule out pericardial effusion in post operative period. Multiple TTE views were used for grading the degree of pericardial effusion when present. TTE was also used to know the contractility and volume status of heart.

ENDOBRONCHIAL INTUBATION

Absence of lung sliding with the presence of lung pulse on M mode in one hemithorax (**Fig.15**), in mechanically ventilated patients was considered as endobronchial intubation of the opposite side bronchus. Paradoxical or absent movement of hemidiaphragm on same side was taken as a secondary sign of endobronchial intubation. Atelectasis of one lung is also seen when there is an endobronchial intubation of opposite side bronchus.

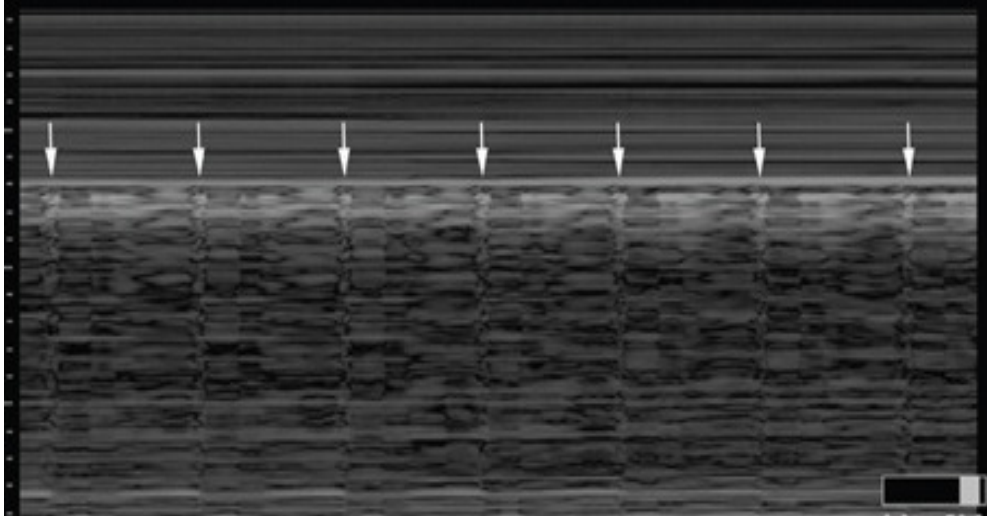


Figure 15 – Lung pulse sign on M mode

DIAPHRAGM WEAKNESS/PALSY

In a spontaneously breathing intubated patient, muscular diaphragm was insonated, by anterior subcostal and mid axillary line approach. The longitudinal excursion of diaphragm was noted on both sides. Excursion of < 4mm for both hemi diaphragms and difference in the amplitude of movement between both hemi-diaphragms of >50% was considered to result in weaning failure [75].

STATISTICAL ANALYSIS

Statistical analysis was done using SPSS software (IBM, SPSS Statistics, version 25). Agreement between CXR and CUS in detecting pathological findings was done using Kappa statistics [87]. Diagnostic performance of bedside chest ultrasound was compared with bedside chest radiography (CXR) using sensitivity, specificity, positive predictive value (PPV) and negative predictive value (NPV) [88]. P value was derived using McNemar test for paired data. P value < 0.05 was considered as statistically significant.

<i>Kappa value</i>	<i>Degree of Agreement</i>
0	Less chance for agreement
0.01 – 0.20	Slight agreement
0.21 – 0.40	Fair agreement
0.41 – 0.60	Moderate agreement
0.61 – 0.80	Substantial agreement
0.81 – 0.99	Almost perfect agreement

OBSERVATIONS

A total of 160 congenital heart disease patients, who underwent open heart surgery, had been studied. The data was collected, tabulated, analyzed and the following observations were made.

Demographic Data of Study Population

Sex Distribution:

Among the study population of 160 patients (N), 92 were males (57%) and 68 (43%) were females. (Fig.16)

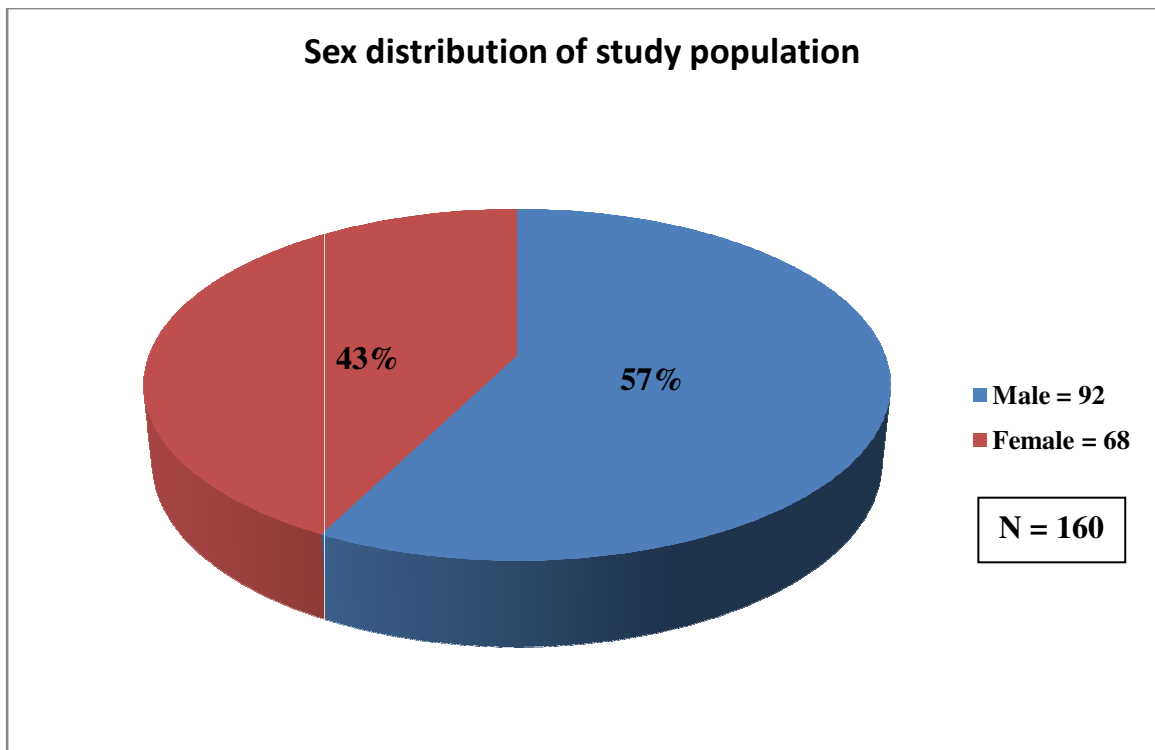


Figure 16 - Sex distribution of study population

AGE DISTRIBUTION OF STUDY POPULATION

Age group (days-d/ months-m/ years-yrs)	Number of patients n (%)
1m - 5m 29d	8 (5%)
6m - 11m 29d	19 (11.8%)
1yr - 5yrs 11m 29d	70 (43.75%)
6yrs - 10yrs 11m 29d	33 (20.6%)
11 yrs - 15yrs 11m 29d	24 (15%)
16 yrs - 18 yrs	6 (3%)

Table 1 - Age distribution of study population

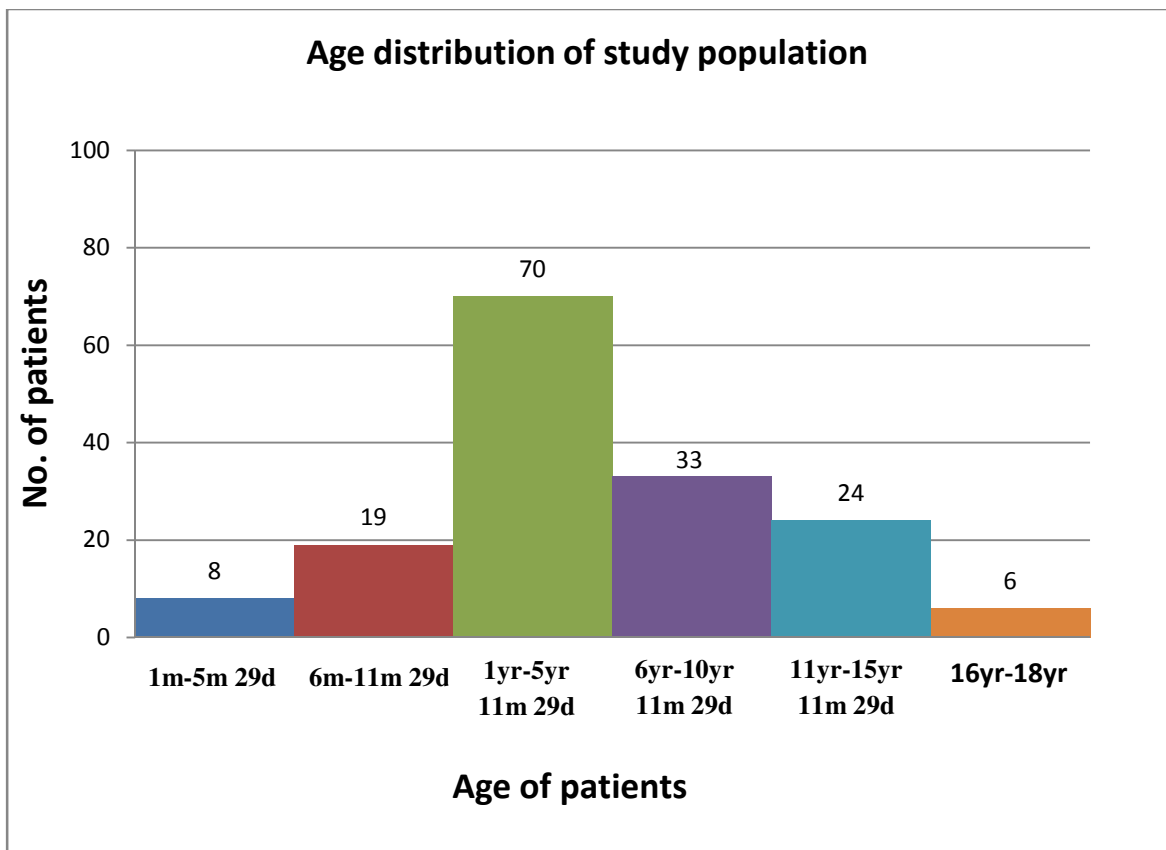


Figure 17 - Age distribution of study population

SURGICAL DETAILS OF STUDY POPULATION

Surgery	Number of patients n(%)
ASD closure	30 (18.75%)
Wardens repair	10 (6.25%)
VSD closure	34 (21.25%)
PDA interruption	1 (0.6%)
CoA repair	2 (1.2%)
TOF repair	29 (18.1%)
Fontan repair	5 (3.1%)
PA banding	1 (0.6%)
Bi-directional Glenn	15 (9.3%)
AVSD repair	6 (3.7%)
ASO	1 (0.6%)
Ebsteins repair	1(0.6%)
DORV repair	6 (3.7%)
ICR others	11 (6.8%)
Others	8 (5%)

Table 2 - Surgical details of study population

Among the study population of 160 patients, number of patients diagnosed as Acyanotic congenital heart disease (ACHD) was 85 (53.1%) as opposed to Cyanotic congenital heart disease (CCHD) of 75 (46.8%) [Fig.18].

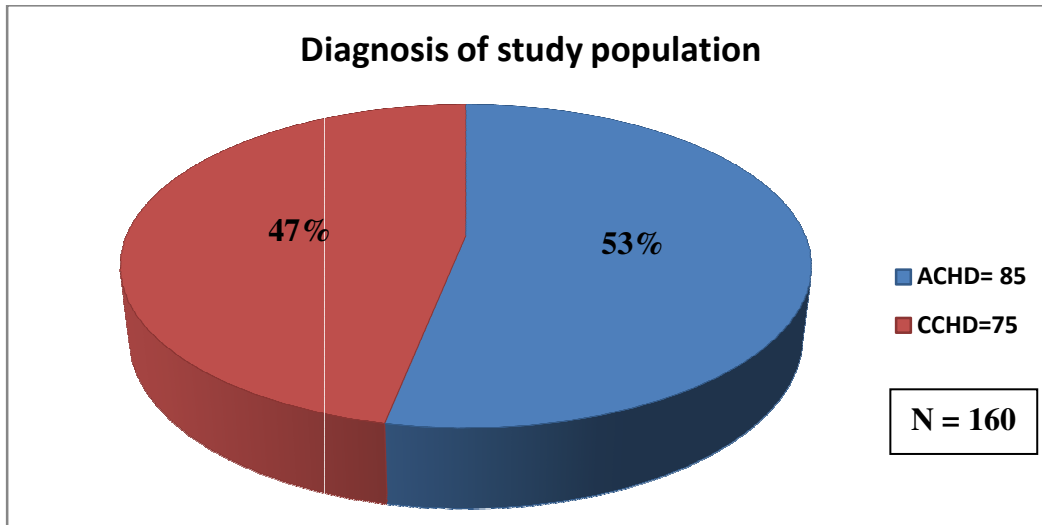


Figure 18 - Diagnosis of study population as ACHD and CCHD

ACHD included Ostium Secundum Atrial Septal Defect (OS-ASD) closure, Wardens repair for Sinous Venosus Atrial Septal Defect (SV-ASD), Ventricular Septal Defect (VSD) closure, Patent Ductus Arteriosus (PDA) interruption, Coarctation of Aorta (CoA) repair, Pulmonary Artery (PA) Banding for multiple VSD and Others which included Anomalous Left Main Coronary Artery arising from Pulmonary Artery (ALCAPA) repair (1), Mitral valve (MV) repair (2), Aorto Pulmonary (AP) window repair (1), Right ventricle outflow tract obstruction (RVOTO) resection (1), Vascular ring division (1), Ross-Kono procedure (1).

CCHD included Tetralogy of Fallot (TOF) repair, Fontan repair, Bi-directional Glenn (BDG), Atrio-ventricular septal defect (AVSD) repair, Arterial switch operation (ASO), Double outlet right ventricle (DORV) repair, Ebsteins repair and Others which included root translocation (1), Redo Intra cardiac repair (ICR) with Pulmonary valve

replacement (PVR) (1), ICR for Pulmonary atresia with ventricular septal defect (PA-VSD) (6), redo ICR (3), Kawashima operation (1).

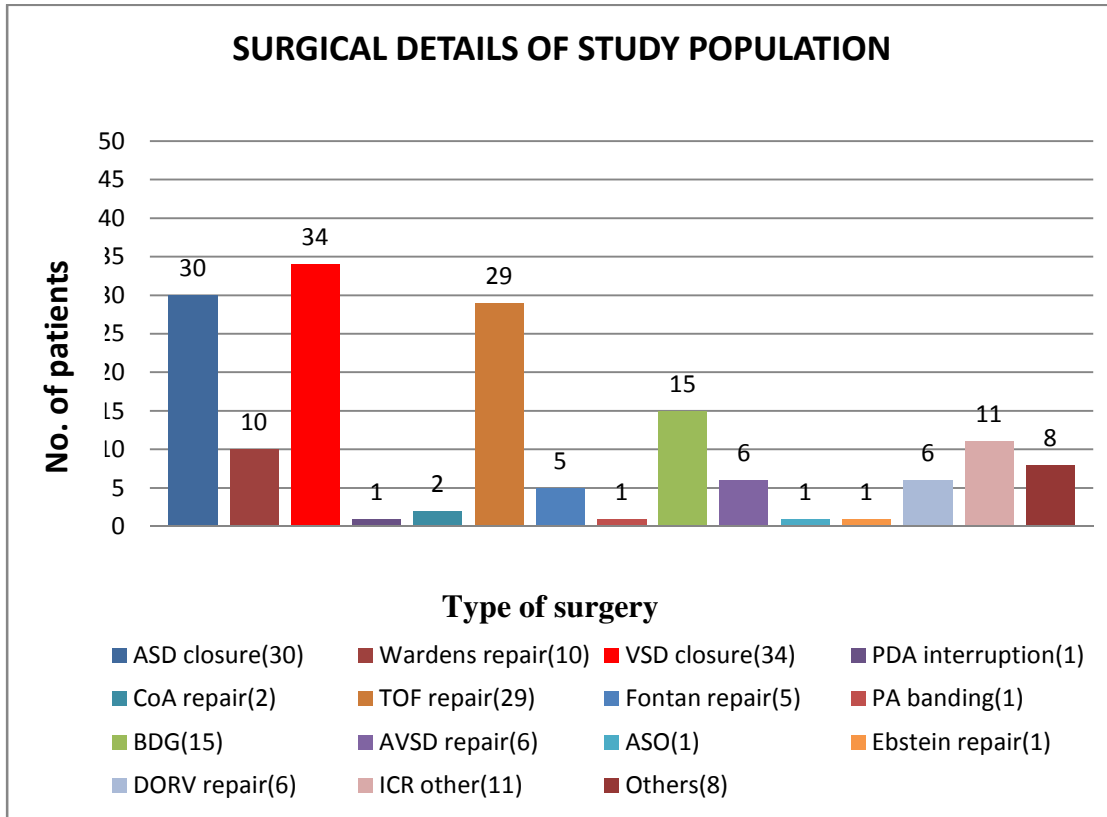


Figure 19 - Surgical details of study population

Among 320 CXR studies, 223 (69.6%) were normal. Surgeon detected abnormalities in 97 (30.3%) CXR studies. Among the CUS studies 192 (60%) revealed no abnormalities and 128 (40%) studies showed abnormal findings. CUS and CXR findings agreed on 189 (58.1%) studies as normal. 94 (29.3%) studies of both modalities agreed on same abnormal findings. 34 studies diagnosed as abnormal by CUS was reported normal by CXR, while 3 studies diagnosed as abnormal by CXR was reported normal by CUS.

**Table 3- COMPARISION OF NORMAL AND ABNORMAL STUDIES
DIAGNOSED BY CUS AND CXR**

		CHEST X RAY		Total no. of Study (n)
		Abnormal (n) (+)	Normal (n) (-)	
CHEST ULTRA- SOUND	Abnormal (n) (+)	94	34	128
	Normal (n) (-)	3	189	192
Total no. of Study(n)		97	223	320

n= number of studies

Kappa statistical analysis showed a substantial agreement with Kappa coefficient K= 0.749 (p value < 0.0001). Sensitivity of CUS was 96.9%, specificity 84.75%, PPV 73.4%

and NPV of 98.43%.

Table 4 - PERCENTAGE AND TOTAL NUMBER OF STUDIES IN EACH SUBGROUP DIVIDED ACCORDING TO THE DIAGNOSIS OF CUS AND CXR

FINDINGS IN CXR AND CUS	NUMBER OF STUDIES
NORMAL CXR AND CUS	189 (59.06%)
ABNORMAL CXR AND CUS	94 (29.3%)
NORMAL CXR AND ABNORMAL CUS	34 (10.6%)
ABNORMAL CXR AND NORMAL CUS	3 (0.93%)

We analysed the agreement between CUS and CXR; sensitivity, specificity, PPV & NPV of CUS in immediate postoperative period and post operative period day one.

IMMEDIATE POST OPERATIVE PERIOD

**Table 5 - COMPARISON OF NORMAL AND ABNORMAL STUDIES
DIAGNOSED BY CXR AND CUS IN IMMEDIATE POSTOPERATIVE PERIOD**

		CHEST X RAY		Total no. of Study (n)
		Abnormal (n) (+)	Normal (n) (-)	
CHEST ULTRA- SOUND	Abnormal (n) (+)	52	16	68
	Normal (n) (-)	1	91	92
Total no. of Study(n)		53	107	160

n= number of studies

Kappa statistical analysis showed a substantial agreement with Kappa coefficient $k = 0.7762$ ($p=0.0007$). Sensitivity of CUS was 98.11%, specificity 85.04%, PPV 76.47% and NPV of 98.91 %.

POST OPERATIVE DAY 1

**Table 6 - COMPARISON OF NORMAL AND ABNORMAL STUDIES
DIAGNOSED BY CUS AND CXR ON POST OPERATIVE DAY ONE**

		CHEST X RAY		Total no. of Study (n)
		Abnormal (n) (+)	Normal (n) (-)	
CHEST ULTRA- SOUND	Abnormal (n) (+)	41	17	58
	Normal (n) (-)	3	99	102
Total no. of Study(n)		44	116	160

n= number of studies

Kappa statistical analysis showed a substantial agreement with Kappa coefficient $k=0.7147$ ($p=0.0037$). Sensitivity of CUS was 93.18%, specificity 85.34%, PPV 70.68% and NPV 97.05 %.

ATELECTASIS

In a total of 37 studies, lung atelectasis was diagnosed by either CUS or CXR or by both. In 25 studies, lung atelectasis was diagnosed by both CUS and CXR.. In 1 studies CXR modality diagnosed atelectasis which was not agreed upon by CUS. In another 11 studies, atelectasis was diagnosed by CUS modality, but this was not agreed by findings in CXR. 283 studies showed no atelectasis by both modalities of diagnosis.

Table 7-COMPARISION OF PRESENCE OR ABSENCE OF ATELECTASIS AS DIAGNOSED BY CUS AND CXR

		CHEST X RAY		Total no. of Study (n)
		Abnormal (n) (+)	Normal (n) (-)	
CHEST ULTRA-SOUND	Abnormal (n) (+)	25	11	36
	Normal (n) (-)	1	283	284
Total no. of Study(n)		26	294	320

n= number of studies

Kappa statistical analysis showed a substantial agreement with Kappa coefficient $k=0.7863$ ($p=0.0094$). Sensitivity of CUS was 96.15%, specificity 96.2%, PPV 69.4% and NPV 99.6%.

PLEURAL EFFUSION

In 24 studies, pleural effusion was diagnosed by either CUS or CXR or by both. In 6 studies, pleural effusion was diagnosed by both CUS and CXR. None of the CXR modality diagnosed pleural effusion which was not agreed upon by CUS. In another 18 studies, pleural effusion was diagnosed by CUS modality, but this was not agreed by findings in CXR. 296 studies showed no pleural effusion by both modalities of diagnosis

Table 8 - COMPARISION OF PRESENCE OR ABSENCE OF PLEURAL EFFUSION AS DIAGNOSED BY CXR AND CUS

		CHEST X RAY		Total no. of Study (n)
		Abnormal (n) (+)	Normal (n) (-)	
CHEST ULTRA-SOUND	Abnormal (n) (+)	6	18	24
	Normal (n) (-)	0	296	296
Total no. of Study(n)		6	314	320

n= number of studies

Kappa statistical analysis showed a fair agreement with Kappa coefficient $k= 0.3814$ ($p<0.0001$). Sensitivity of CUS was 100%, specificity 94.2%, PPV 25% and NPV of 100%

INTERSTITIAL EDEMA

In 98 studies, interstitial edema was diagnosed by either CUS or CXR or by both. In 66 studies, interstitial edema was diagnosed by both CUS and CXR. In 1 study CXR modality diagnosed interstitial edema which was not agreed upon by CUS. In another 31 studies, interstitial edema was diagnosed by CUS modality, but this was not agreed by findings in CXR. 222 studies showed no interstitial edema by both modalities of diagnosis.

Table 9 - COMPARISION OF PRESENCE OR ABSENCE OF INTERSTITIAL EDEMA AS DIAGNOSED BY CUS AND CXR

		CHEST X RAY		Total no. of Study (n)
		Abnormal (n) (+)	Normal (n) (-)	
CHEST ULTRA-SOUND	Abnormal (n) (+)	66	31	97
	Normal (n) (-)	1	222	223
Total no. of Study(n)		67	253	320

n= number of studies

Kappa statistical analysis showed a substantial agreement with Kappa coefficient $k=0.7406$ ($p<0.0001$). Sensitivity of CUS was 98.5%, specificity 87.7%, PPV 68.04% and NPV 99.55%.

PNEUMOTHORAX

In a total of 4 studies, pneumothorax was diagnosed by either CUS or CXR or by both. In 3 studies, pneumothorax was diagnosed by both CUS and CXR.. None of CXR study diagnosed pneumothorax which was not agreed upon by CUS. In 1 study, pneumothorax was diagnosed by CUS modality, but this was not agreed by findings in CXR. 316 studies showed normal study by both modalities of diagnosis.

Table 10 - COMPARISION OF PRESENCE OR ABSENCE OF PNEUMOTHORAX AS DIAGNOSED BY CUS AND CXR

		CHEST X RAY		Total no. of Study (n)
		Abnormal (n) (+)	Normal (n) (-)	
CHEST ULTRA-SOUND	Abnormal (n) (+)	3	1	4
	Normal (n) (-)	0	316	316
Total no. of Study(n)		3	317	320

n = number of studies

Kappa statistical analysis showed almost perfect agreement with Kappa coefficient $k=0.8556$ ($p= 1.0$). Sensitivity of CUS was 100%, specificity 99.68%, PPV 75% and NPV 100%.

DIAPHRAGMATIC WEAKNESS OR PALSY

In a total of 4 studies, diaphragmatic weakness in form of elevated diaphragm or sluggish movement of diaphragm was diagnosed by either CUS or CXR or by both. In 2 studies, diaphragmatic weakness was diagnosed by both CUS and CXR. In 2 studies CXR modality diagnosed diaphragmatic weakness which was not agreed upon by CUS. 316 studies showed normal study by both modalities of diagnosis.

Table 11 - COMPARISON OF PRESENCE OR ABSENCE OF DIAPHRAGMATIC WEAKNESS OR PALSY AS DIAGNOSED BY CUS AND CXR

		CHEST X RAY		Total no. of Study (n)
		Abnormal (n) (+)	Normal (n) (-)	
CHEST ULTRA-SOUND	Abnormal (n) (+)	2	0	2
	Normal (n) (-)	2	316	318
Total no. of Study(n)		4	316	320

n= number of studies

Kappa statistical analysis showed substantial agreement with Kappa coefficient $k=0.6639$ ($p= 0.4795$). Sensitivity of CUS was 50%, specificity 100%, PPV 100% and NPV 99.37%.

ENDOBONCHIAL INTUBATION

Right endobronchial intubation was diagnosed by both modalities in a single immediate post operative study. CXR showed left lung collapse and presence of endotracheal tube in the right bronchus. CUS showed absence of diaphragmatic movements on left side and tissue like echogenicity of the collapsed left lung. Endotracheal tube was later pulled out by 1cms.

PERICARDIAL EFFUSION

No significant pericardial effusion was noted in any patient by both modalities.

INTERVENTIONS USING CUS AND CXR

In a total of 83 studies, interventions were done on the basis of CUS or CXR or both. Intervention in the form of recruitment for atelectasis, diuretics for interstitial edema, low suction through intercostal drain for pneumothorax or intercostal drain placement for pneumothorax and intercostal drain placement for pleural effusion were compared. Out of the 83 interventions done, 65 were agreed upon by both CUS and CXR. 17 interventions were done on the basis of CUS. Only 1 intervention was done on basis of CXR alone. In the remaining 237 studies no intervention was required.

Table 12 - COMPARISION OF INTERVENTIONS AS DIAGNOSED BY CUS AND CXR

		CHEST X RAY		Total no. of Study (n)
		Intervention (n) (+)	No Intervention (n) (-)	
CHEST ULTRA-SOUND	Intervention (n) (+)	65	17	82
	No Intervention (n) (-)	1	237	238
Total no. of Study(n)		66	254	320

n= number of studies

Kappa statistical analysis showed almost perfect agreement with Kappa coefficient $k=0.842$ ($p= 0.0001$)

LUNG RECRUITMENT USING CUS AND CXR

Out of 37 studies diagnosed as collapse/atelectasis by CUS or CXR or both, only 32 studies underwent lung recruitment intervention. A total of 25 studies were agreed by both CUS and CXR for lung recruitment. Only 6 recruitment interventions were done on basis of CUS and 1 study on basis of CXR. Remaining 5 studies didn't require intervention.

Table 13- COMPARISION OF LUNG RECRUITMENT FOR ATELECTASIS AS DIAGNOSED BY CUS AND CXR

		CHEST X RAY		Total no. of Atelectasis Study (n)
		Lung Recruitment (n) (+)	No Recruitment (n) (-)	
CHEST ULTRA-SOUND	Lung Recruitment (n) (+)	25	6	31
	No Recruitment (n) (-)	1	5	6
Total no. of Atelectasis Study(n)		26	11	37

n= number of studies

Kappa statistical analysis showed moderate agreement with Kappa coefficient $k= 0.478$
($p= 0.1306$)

DIURETIC THERAPY USING CUS AND CXR

Out of 98 studies diagnosed as interstitial edema by CUS or CXR or both, only 57 studies underwent diuretic therapy intervention. A total of 46 studies were agreed by both CUS and CXR for diuretic therapy. Diuretic therapy was given on basis of CUS alone in 11 studies. No intervention was done on basis of CXR alone. In the remaining 41 studies, no interventions were done.

Table 14- COMPARISION OF DIURETIC THERAPY FOR INTERSTITIAL EDEMA AS DIAGNOSED BY CUS AND CXR

		CHEST X RAY		Total no. of Interstitial Edema Study (n)
		Diuretic Therapy (n) (+)	No Diuretic Therapy (n) (-)	
CHEST ULTRA-SOUND	Diuretic Therapy (n) (+)	46	11	57
	No Diuretic Therapy (n) (-)	0	41	41
Total no. of Interstitial Edema Study (n)		46	52	98

n= number of studies

Kappa statistical analysis showed substantial agreement with Kappa coefficient $k= 0.777$

($p= 0.0026$)

INTERVENTION FOR PNEUMOTHORAX USING CUS AND CXR

Pneumothorax was diagnosed in 4 studies by CUS or CXR or both. 3 studies were agreed upon by both CUS and CXR as having pneumothorax and low suction intervention was given. In these 3 studies, patients had intercostal drain in situ. In the remaining one study intercostal drain was placed for right sided pneumothorax.

Table 15- COMPARISION OF LOW SUCTION THERAPY PNEUMOTHORAX AS DIAGNOSED BY CUS AND CXR

		CHEST X RAY		Total no. of Pneumothorax Study (n)
		Suction (n) (+)	No Suction (n) (-)	
CHEST ULTRA-SOUND	Suction (n) (+)	3	0	3
	No Suction (n) (-)	0	1	1
Total no. of Pneumothorax Study (n)		3	1	4

n= number of studies

Kappa statistical analysis showed perfect agreement with Kappa coefficient $k = 1.0$

INTERVENTION FOR PLEURAL EFFUSION USING CUS AND CXR

Out of the total 24 studies diagnosed as pleural effusion by CXR or CUS or both, only 1 study had moderate to severe pleural effusion as agreed by both CUS and CXR for which intercostal drain was placed.

OTHER INTERVENTION FOR USING CUS AND CXR

Only one study was diagnosed to have right endobronchial intubation and was agreed by both CUS and CXR for which ET tube was pulled out by 1cms.

The need for repositioning the central venous catheter did not arise, as all central venous catheters were placed under ultrasound guidance in paediatric patients as per Institute protocols.

DISCUSSION

Post operative respiratory dysfunction leads to significant morbidity and mortality. Although CT thorax is the gold standard for the diagnosis of intra-thoracic pathologies, bed side CXR is taken as standard reference of care [1] as post operative cardiac surgical patients with inotropic supports and chest drains cannot be shifted out of ICU to the radiology suite. As more number of CXR's become necessary; more radiation exposure is inevitable. Portable ultrasound (USG) machines are available in most of the intensive care units. Although literature is available supporting its role in diagnostic and therapeutic procedures [89] CUS is underutilized in intensive care units. The noninvasive nature of ultrasound, lack of radiation exposure and quick accessibility makes CUS a feasible imaging modality for perioperative care.

Many studies are available on comparison of CUS with bedside CXR in the adult intensive care units. Scanty studies are available for the post operative paediatric cardiac surgical patients. Therefore we carried out a prospective observational study to compare the degree of agreeability and diagnostic performance of CUS with reference to CXR. Interventions were done according to the combined decision of surgical ICU colleague and the principle investigator. We hypothesized that CUS can be used as an alternative to CXR for the purpose of diagnosis of intrathoracic pathologies and monitoring in post operative cardiac surgical patients.

In our study, among 320 CXR and CUS studies of 160 patients, 30.3 % of CXR showed abnormalities, while 40% of CUS studies showed abnormalities. 59.06% of CUS studies and corresponding CXRs were normal. Among 128 CUS studies with

pathological diagnoses, 94 studies (73.43%) had the same diagnosis as the corresponding CXRs. Among normal 192 CUS studies, 189 studies (98.43%) had normal CXR findings. Kappa statistics (degree of agreement) between CXR and CUS in post operative patients showed substantial agreement $k=0.749$ ($p<0.0001$). CUS showed a sensitivity of 96.9%, specificity 84.75%, PPV 73.4% and NPV 98.43% as compared to CXR. Therefore, CUS can be used as an effective alternative for CXRs, thereby reducing radiation exposure.

A total of 83(63.35%) interventions were done, out of the 131 abnormal studies detected using CXR or CUS or both. Only 66 studies were agreed for intervention by both CXR and CUS; $k=0.842$, ($p= 0.0001$). 17 studies were intervened on basis of CUS findings alone.

We also analyzed the degree of agreement between CXR and CUS in the immediate postoperative period. Kappa coefficient was 0.7762 ($P= 0.0007$), indicating substantial agreement. On the post operative day one, there was substantial agreement between CXR and CUS findings, and Kappa coefficient was $k=0.7147$ ($p= 0.0037$).

For the diagnosis of pleural effusion, CUS showed a fair agreement with CXR $k=0.3814$, ($p<0.0001$). CUS showed a sensitivity of 100%, specificity 94.2%, PPV 25% and NPV 100% as compared to CXR. Only 5 studies were diagnosed as minimal pleural effusion by CXR. Minimal pleural effusions which needed no intervention were diagnosed by CUS in 23 studies. 18 studies of effusion were missed by CXR, probably because in a supine CXR, only pleural effusion of more than 150 ml can be detected [90].

Also, bedside CXR has poor accuracy for differentiating mild pleural effusion from parenchymal disease such as atelectasis [91]. Only 1 study was in agreement by both CUS and CXR for intervention in form of intercostal drain.

Diagnosis of atelectasis by CXR and CUS showed substantial agreement $k=0.7863$, ($p < 0.0094$). CUS showed a sensitivity of 96.15%, specificity 96.2%, PPV 69.4% and NPV 99.6% as compared to CXR. Both CUS and CXR showed atelectasis in 37 studies. Lung recruitment was done in 32 studies, of which 25 studies were agreed on by both CXR and CUS. Lung recruitment was done in 6 studies on the basis of CUS alone. Thus CUS is superior to CXR for recruitment of lung in patients with atelectasis.

For the diagnosis of Interstitial edema, CUS and CXR showed substantial agreement $k=0.7406$; $p < 0.0001$. CUS showed a sensitivity of 98.5%, specificity 87.7%, PPV 68.04% and NPV 99.55% as compared to CXR. Out of the total 98 studies diagnosed as interstitial edema by CUS or CXR or both, only 57 studies received diuretics in the immediate or post operative day one. Out of 57 studies only 46 studies were agreed upon by both CUS and CXR. Diuretics were given in 11 studies on basis on CUS alone.

For the diagnosis of pneumothorax, there was almost perfect agreement $k=0.8556$, ($p = 1.000$), between the two modalities. CUS showed a sensitivity of 100%, specificity 99.68%, PPV 75% and NPV 100% as compared to CXR. Out of the total 4 pneumothorax diagnosed, only 3 were agreed upon by both modalities. In 3 patients low suction was

given as they had intercostal tube in situ. Only in one study, intercostal drain was placed for treating pneumothorax in immediate post operative period.

The degree of agreement between CUS and CXR cannot be commented upon for endobronchial intubation as it was detected only in a single study. Endobronchial intubation can be ruled out by CUS, but the exact position of endotracheal tube tip in relationship to vertebrae can be detected by only CXR.

Bedside CXR shows a static image of diaphragm either in expiration or inspiration, while CUS can be used to see the range movement of diaphragm during inspiration and expiration over many respiratory cycles in spontaneously breathing patients. In our study, 4 studies by CXR or CUS or both revealed diaphragmatic weakness. In 2 studies, CXR diagnosed diaphragmatic weakness in form of elevated diaphragm which was not agreed upon by CUS. Thus, the agreement between CUS and CXR for detecting abnormal diaphragmatic function was substantial $k=0.6639$; ($p=0.4795$). CUS showed a sensitivity of 50%, specificity 100%, PPV 100% and NPV 99.37% as compared to CXR.

In our study, neither CXR nor CUS revealed significant pericardial effusion in any patient. This is due to the presence of mediastinal drain in situ in all post operative patients. Mediastinal drain prevents the accumulation of blood in the opened pericardial cavity.

To summarize, there was a good degree of agreeability between CUS and CXR for the detection of various intra thoracic pathologies. Overall Kappa value of 0.749 shows substantial agreement between the two modalities. Overall sensitivity and specificity of CUS as compared to CXR was 96.9% and 84.75% respectively. For pleural effusion only moderate degree of agreeability of $k = 0.3814$ was seen. This is because; presence of a small pleural effusion is not easily identified by chest x-ray. For pneumothorax there was perfect agreement between two modalities with $k = 0.8556$. For atelectasis there was substantial agreement between the two modalities with $k = 0.7863$. For interstitial edema there was substantial agreement between the two modalities with $k = 0.7406$. For detection of abnormal diaphragmatic function there was substantial agreement $k = 0.6639$ between both modalities. Thus CUS can be an effective alternative to CXR in the immediate postoperative period and in the follow up period (post operative day one).

LIMITATIONS

The following are the limitations of our study using CUS

- 1) Bedside CXR was used as reference standard for comparison with CUS. Thoracic computed tomography (CT) is the gold standard for chest imaging, but it cannot be performed routinely in postoperative patients.
- 2) Sensitivity, specificity, positive predictive value and negative predictive values of CUS were compared with CXR and not Thoracic CT (gold standard).
- 3) The number of endobronchial intubations and pericardial effusion were small to draw a meaningful comparison between the two modalities.
- 4) Restricted field for CUS study in post-operative patients due to presence of dressings and drains.
- 5) Position of drains, endotracheal tube tip, nasogastric tube tip couldn't be studied by CUS probe that we used.
- 6) Our study only included patients in POD-0 and morning of POD-1. Most of the pneumothorax developed in the POD-2 or POD-3 after chest drain removal and it was not studied.
- 7) Some of the studies were conducted in the late immediate post operative period and not in the early immediate post operative period, when the patient was transferred out

of operation theatre to ICU. We acknowledge that findings such as small pneumothorax which could be detected easily by CUS and not by CXR in early immediate post operative were missed.

8) We did not include hemodynamically unstable patients and patients with open sternum. Perhaps a study on this subset of patients can rule out the cardiac or respiratory cause for unstable hemodynamics using the BLUE or RUSH protocol.

CONCLUSIONS

- 1) Minimal and mild pleural effusion could be detected with CUS, but not by CXR. In 7.5% of the total studies diagnosed as pleural effusion, all the studies (7.5%) were diagnosed by CUS. Only 1.8% of studies were diagnosed as pleural effusion by CXR.

- 2) In 30.6% of total studies diagnosed as interstitial edema by both CUS and CXR, 30.3% of studies were diagnosed as interstitial edema by CUS. Only 20.9% of the studies were diagnosed as interstitial edema by CXR. Serial CUS studies were used for studying the clearance of interstitial edema in response to interventions (diuretics). It would be prudent to avoid taking serial CXRs to detect clearance of interstitial edema, lest patients get undesirable radiation exposure.

- 3) We found that both CUS and CXR are equally effective for the detection of lung atelectasis. In 11.5% of total studies, atelectasis was diagnosed by both CUS and CXR, of which 11.25% & 8.1% of the studies were diagnosed as atelectasis by CUS and CXR respectively. Recruitment of atelectatic lung could be monitored by subsequent CUS studies. Subjecting patients to repeated CXR for this purpose would have been undesirable.

- 4) We found that both CUS and CXR are equally effective for the detection of pneumothorax. Only 1.2% of the total studies were diagnosed by both CUS and CXR as pneumothorax, of which CUS detected all (1.2%) the pneumothorax and CXR 0.93% of pneumothorax.

5) CXR was effective for the detection of diaphragmatic weakness in form of elevated diaphragm (1.2% of total studies) as compared to CUS in form of sluggish movement (0.625% of total studies).

Thus, we found that CUS is superior to CXR for diagnosis of pneumothorax, pleural effusion, atelectasis and interstitial edema. CUS was also found to be superior to CXR for assessing response to therapy in patients having interstitial edema and atelectasis. We conclude that chest ultrasound detected more intrathoracic pathologies than CXR and thus can be a better alternative to bedside chest X-ray as a diagnostic and monitoring tool in post operative pediatric cardiac surgical patients. It can be repeated easily whenever the clinical condition of the patient changes and avoids radiation exposure to both patient and staff.

REFERENCES

- 1) Amorosa JK, Bramwit MP, Mohammed TL, Reddy GP, Brown K, Dyer DS et al. ACR appropriateness criteria routine chest radiographs in intensive care unit patients. *J Am Coll Radiol* 2013;10(3):170-74
- 2) Henschke CI, Yankelevitz DF, Wand A, Davis SD, Shiau M. Accuracy and efficacy of chest radiography in the intensive care unit. *Radiol Clin North America* 1996;34:21–31
- 3) Picano E. Education and debate. Sustainability of medical imaging. *BMJ* 2004; 328:578–80
- 4) González A B, Darby S. Risk of cancer from diagnostic X-rays: estimates for the UK and 14 other countries. *Lancet* 2004;363(9406):345–51
- 5) Gargani L. Lung ultrasound: a new tool for the cardiologist. *Cardiovasc Ultrasound*. 2011; 9:6.
- 6) Erkut O, Ibrahim CT, Okan Y, Yakup E, Alper G .The Efficacy of Thoracic Ultrasonography in Postoperative Newborn Patients after Cardiac Surgery. *Braz J Cardiovasc Surg* 2017; 32(4): 283-87
- 7) Yu CJ, Yang PC, Chang DB, Luh KT. Diagnostic and therapeutic use of chest sonography: value in critically ill patients. *Am J Roentgenol* 1992;159(4): 695-701.

- 8) Weaver B, Lyon M, Blaivas M. Confirmation of endotracheal tube placement after intubation using the ultrasound sliding lung sign. *Acad Emerg Med* 2006;13(3):239-44
- 9) Qureshi A: Diaphragm paralysis. *Semin Respir Crit Care Med* 2009;30(3): 315–20
- 10) Aguirre VJ, Sinha P, Zimmet A, Lee GA, Kwa L, Rosenfeldt F. Phrenic nerve injury during cardiac surgery: Mechanisms, management and prevention. *Heart Lung Circ* 2013; 22(11): 895–902.
- 11) Zhang YB, Wang X, Li SJ, Yang KM, Sheng XD, Yan J. Postoperative diaphragmatic paralysis after cardiac surgery in children: Incidence, diagnosis and surgical management. *Chin Med J* 2013; 126: 4083–87
- 12) Srinivasan S, Cornell TT: Bedside ultrasound in pediatric critical care: A review. *Pediatr Crit Care Med* 2011; 12(6): 667–74
- 13) Riu B, Ruiz J, Mari A, Silva S. Chest ultrasonography in pediatric critical care practice. *Ann Fr Anesth Reanim.* 2013; 32(12):e219-23.
- 14) Ng CSH, Wan S, Yim APC, Arifi AA. Pulmonary dysfunction after cardiac surgery. *Chest* 2002; 121(4):1269-77.

- 15) Apostolakis E, Filos KS, Koletsis E, Dougenis D. Lung dysfunction following cardiopulmonary bypass. *J Card Surg* 2010; 25(1):47–55.
- 16) Chowdhury UK, Airan B, Sharma R, Bhan A, Kothari SS, Saxena A et al. Univentricular repair in children under 2 years of age: early and midterm results. *Heart Lung Circ* 2001;10(1):3-13.
- 17) Weissman C. Pulmonary complications after cardiac surgery. *Semin Cardiothorac Vasc Anesth* 2004;8(3) :185–211.
- 18) Bouhemad B, Zhang M, Lu Q, Rouby JJ. Clinical review: Bedside lung ultrasound in critical care practice. *Crit Care* 2007;11(1):205.
- 19) Rubinowitz AN, Siegel MD, Tocino I. Thoracic imaging in the ICU. *Crit Care Clin* 23(3) : 539–73
- 20) Expert Panel on Thoracic Imaging of the American College of Radiology: Routine Chest Radiograph Appropriateness Criteria. 2008 [http://www.acr.org/SecondaryMainMenuCategories/quality_safety/app_criteria/pdf/ExpertPanelonThoracicImaging.aspx]

- 21) Suh RD, Genshaft SJ, Kirsch J, Kanne JP, Chung JH, Donnelly EF et al. ACR Appropriateness Criteria® Intensive Care Unit Patients. *J Thorac Imaging* 2015; 30(6):W63-5.
- 22) Cantinotti M, Giordano R, Volpicelli G, Kutty S, Murzi B, Assanta N, et al. Lung ultrasound in adult and paediatric cardiac surgery: Is it time for routine use? *Interact Cardiovasc Thorac Surg* 2016; 22(2):208–15
- 23) Armpilia C, Fife IA, Croasdale PL. Radiation dose quantities and risk in neonates in a special care baby unit. *Br J Radiol* 2002;75: 590-95
- 24) Moore CL, Copel JA. Point-of-care Ultrasonography. *N Engl J Med* 2011; 364(8): 749-757
- 25) Fuhlbrigge AL, Choi AMK. Diagnostic Procedures in Respiratory Disease. In: Kasper D, Fauci A, Hauser S, Longo D, Jameson JL, Loscalzo J, editors. *Harrison's Principles of Internal Medicine* [Internet]. 19th ed. New York, NY: McGraw-Hill Education; 2015.
- 26) Lichtenstein DA. Lung ultrasound in the Critically Ill. *Neth J Crit Care* 2012;16(2):43-51

- 27) Feldman MK, Katyal S, Blackwood MS. US Artifacts. *RadioGraphics*. 2009;29:1179-89.
- 28) Agricola E, Bova T, Oppizzi M, Marino G, Zangrillo A, Margonato A, et al. "Ultrasound comet-tail images": a marker of pulmonary edema: a comparative study with wedge pressure and extravascular lung water. *Chest* 2005; 127(5):1690-95.
- 29) Mayo PH, Beaulieu Y, Doelken P, Feller-Kopman D, Harrod C, Kaplan A, et al. American College of Chest Physicians/La Société de Réanimation de Langue Française statement on competence in critical care ultrasonography. *Chest* 2009;135(4):1050–60
- 30) Bhagra A, Tierney DM, Sekiguchi H, Soni NJ. Point-of-Care Ultrasonography for Primary Care Physicians and General Internists. *Mayo Clin Proc*. 2016;91(12):1811–27.
- 31) Xirouchaki N, Magkanas E, Vaporidi K, Kondili E, Plataki M, Patrianakos A et al. Lung ultrasound in critically ill patients: Comparison with bedside chest radiography. *Intensive Care Med* 2011; 37(9):1488–93
- 32) Lichtenstein DA. BLUE-Protocol and FALLS-Protocol. *Chest* 2015;147(6): 1659–70.
- 33) Lichtenstein D, Mezière G, Biderman P, Gepner A. The comet-tail artifact: an ultrasound sign ruling out pneumothorax. *Intensive Care Med* 1999;25(4): 383–8.

- 34) Lobo V, Weingrow D, Perera P, Williams SR, Gharahbaghian L. Thoracic ultrasonography. *Crit Care Clin* 2014; 30(1):93–117.
- 35) Lichtenstein DA, Mezière GA, Lagoueyte J-F, Biderman P, Goldstein I, Gepner A. A-lines and B-lines: lung ultrasound as a bedside tool for predicting pulmonary artery occlusion pressure in the critically ill. *Chest* 2009;136(4):1014–20.
- 36) Lichtenstein D, Goldstein I, Mourgeon E, Cluzel P, Grenier P, Rouby JJ. Comparative diagnostic performances of auscultation, chest radiography, and lung ultrasonography in acute respiratory distress syndrome. *Anesthesiology* 2004;100(1): 9–15.
- 37) Yousefifard M, Baikpour M, Ghelichkhani P, Asady H, Shahsavari NK, Moghadas JA, et al. Screening Performance Characteristic of Ultrasonography and Radiography in Detection of Pleural Effusion; a Meta-Analysis. *Emergency* 2016; 4(1):1–10
- 38) Blackmore CC, Black WC, Dallas RV, Crow HC. Pleural fluid volume estimation: a chest radiograph prediction rule. *Acad Radiol.* 1996 Feb;3(2):103–9.
- 39) Kocijancic I. Diagnostic imaging of small amounts of pleural fluid: pleural effusion vs. physiologic pleural fluid. *Coll Antropol.* 2007 Dec;31(4):1195–9

- 40) Balik M, Plasil P, Waldauf P, Pazout J, Fric M, Otahal M et al. Ultrasound estimation of volume of pleural fluid in mechanically ventilated patients. *Intensive Care Med* 2006 ;32(2):318.
- 41) Prina E, Torres A, Carvalho CR. Lung ultrasound in the evaluation of pleural effusion. *J Bras Pneumol* 2014;40(1):1–5.
- 42) Kirkpatrick AW, Sirois M, Laupland KB, Liu D, Rowan K, Ball CG, et al. Hand-held thoracic sonography for detecting post-traumatic pneumothoraces: the Extended Focused Assessment with Sonography for Trauma (EFAST). *J Trauma* 2004;57(2):288–95.
- 43) Ball CG, Ranson K, Dente CJ, Feliciano DV, Laupland KB, Dyer D, et al. Clinical predictors of occult pneumothoraces in severely injured blunt polytrauma patients: A prospective observational study. *Injury* 2009;40(1):44–7.
- 44) Lichtenstein DA, Menu Y. A bedside ultrasound sign ruling out pneumothorax in the critically ill. Lung sliding. *Chest* 1995;108(5):1345–8.
- 45) Balesa J, Rathi V, Kumar S, Tandon A. Chest Sonography in the Diagnosis of Pneumothorax. *Indian J Chest Dis Allied Sci* 2015;57(1):7–11.

- 46) Sartori S, Tombesi P, Trevisani L, Nielsen I, Tassinari D, Abbasciano V. Accuracy of transthoracic sonography in detection of pneumothorax after sonographically guided lung biopsy: Prospective comparison with chest radiography. *Am J Roentgenol* 2007;188:37-41
- 47) Ding W, Shen Y, Yang J, He X, Zhang M. Diagnosis of pneumothorax by radiography and ultrasonography: a meta-analysis. *Chest* 2011;140(4):859–66.
- 48) Alrajab S, Youssef AM, Akkus NI, Caldito G. Pleural ultrasonography versus chest radiography for the diagnosis of pneumothorax: review of the literature and meta-analysis. *Crit Care* 2013;17(5):R208.
- 49) Azad A, Juma SA, Bhatti JA, Dankoff J. Validity of ultrasonography to diagnosing pneumothorax: a critical appraisal of two meta-analyses. *CJEM* 2015;17(2):199–201.
- 50) De Luca C, Valentino M, Rimondi MR, Branchini M, Baleni MC, Barozzi L. Use of chest sonography in acute-care radiology. *J Ultrasound* 2008;11(4):125–34.
- 51) Johnson A. Emergency department diagnosis of pneumothorax using goal-directed ultrasound. *Acad Emerg Med* 2009;16(12):1379–80.

- 52) Volpicelli G, Elbarbary M, Blaivas M, Lichtenstein DA, Mathis G, Kirkpatrick AW et al. International evidence-based recommendations for point-of-care lung ultrasound. In: Intensive Care Medicine 2012; 38:577-91.
- 53) Chen SW, Zhang MY, Liu J. Application of Lung Ultrasonography in the Diagnosis of Childhood Lung Diseases. Chin Med J (Engl)2015;128(19):2672–8.
- 54) Lichtenstein DA, Mezière G, Biderman P, Gepner A. The “lung point”: an ultrasound sign specific to pneumothorax. Intensive Care Med. 2000;26(10):1434–40.
- 55) Volpicelli G, Boero E, Sverzellati N, Cardinale L, Busso M, Boccuzzi F et al. Semi-quantification of pneumothorax volume by lung ultrasound. Intensive Care Med 2014; 40:1460–67.
- 56) Pagano A, Numis FG, Visone G, Pirozzi C, Masarone M, Olibet M, et al. Lung ultrasound for diagnosis of pneumonia in emergency department. Intern Emerg Med 2015;10(7):851–4.
- 57) Liu X, Lian R, Tao Y, Gu C, Zhang G. Lung ultrasonography: an effective way to diagnose community-acquired pneumonia. Emerg Med J 2015; 32(6):433–8.

- 58) Nazerian P, Volpicelli G, Vanni S, Gigli C, Betti L, Bartolucci M, et al. Accuracy of lung ultrasound for the diagnosis of consolidations when compared to chest computed tomography. *Am J Emerg Med* 2015;33(5):620–5
- 59) Chavez MA, Shams N, Ellington LE, Naithani N, Gilman RH, Steinhoff MC, et al. Lung ultrasound for the diagnosis of pneumonia in adults: a systematic review and meta-analysis. *Respir Res* 2014 23;15:50.
- 60) Rizk AM, Zidan MA, Emara DM, Abd El-Hady MA, Wahbi MO. Chest ultrasound in the assessment of patients in ICU: How can it help? *Egypt J Radiol Nucl Med* 2017;48(1): 313–22.
- 61) Lichtenstein D, Mezière G, Seitz J. The dynamic air bronchogram. A lung ultrasound sign of alveolar consolidation ruling out atelectasis. *Chest* 2009;135(6): 1421–5.
- 62) Bouhemad B, Brisson H, Le-Guen M, Arbelot C, Lu Q, Rouby JJ. Bedside ultrasound assessment of positive end-expiratory pressure-induced lung recruitment. *Am J Respir Crit Care Med* 2011; 183(3):341-7.
- 63) Wongwaisayawan S, Suwannanon R, Sawatmongkorngul S, Kaewlai R. Emergency Thoracic US: The Essentials. *Radiographics* 2016;36(3):640–59

- 64) Zhou S, Zha Y, Wang C, Wu J, Liu W, Liu B. The clinical value of bedside lung ultrasound in the diagnosis of chronic obstructive pulmonary disease and cardiac pulmonary edema. *Chin Crit Care Med* 2014;26(8):558–62
- 65) Al Deeb M, Barbic S, Featherstone R, Dankoff J, Barbic D. Point-of-care ultrasonography for the diagnosis of acute cardiogenic pulmonary edema in patients presenting with acute dyspnea: a systematic review and meta-analysis. *Acad Emerg Med* 2014;21(8):843–52.
- 66) Lichtenstein D, Mézière G, Biderman P, Gepner A, Barré O. The comet-tail artifact. An ultrasound sign of alveolar-interstitial syndrome. *Am J Respir Crit Care Med* 1997;156(5):1640–6.
- 67) Trezzi M, Torzillo D, Ceriani E, Costantino G, Caruso S, Damavandi PT et al. Lung ultrasonography for the assessment of rapid extravascular water variation: Evidence from hemodialysis patients. *Intern Emerg Med*. 2013; 8(5):409-415.
- 68) Hamadah HK, Kabbani MS, Elbarbary M, Hijazi O, Shaath G, Ismail S, et al. Ultrasound for diaphragmatic dysfunction in postoperative cardiac children. *Cardiol Young* 2017;27:452-58
- 69) Sanchez TJ, Munoz R, Landsittel D, Shiderly D, Yoshida M, Komarlu R et al. Diagnosis of abnormal diaphragm motion after cardiothoracic surgery: ultrasound

performed by a cardiac intensivist vs. fluoroscopy. *Congenit Heart Dis* 2010;5(6): 565–72.

70) Noh DK, Lee JJ, You JH. Diaphragm breathing movement measurement using ultrasound and radiographic imaging: A concurrent validity. *Biomed Mater Eng* 2014;24(1):947-52

71) Taggu A: Bedside Measurement of Diaphragm Thickness Sonographically Just Before Extubation Is a Predictor of Extubation Outcome *Chest* 2015;148: 326A.

72) Kim WY, Suh HJ, Hong SB, Koh Y, Lim CM. Diaphragm dysfunction assessed by ultrasonography: Influence on weaning from mechanical ventilation. *Crit Care Med.* 2011;39(12):2627-30.

73) Sarwal A, Walker FO, Cartwright MS. Neuromuscular ultrasound for evaluation of the diaphragm. *Muscle Nerve* 2013 ; 47(3):319-29.

74) Epelman M, Navarro OM, Daneman A, Miller SF. M-mode sonography of diaphragmatic motion: description of technique and experience in 278 pediatric patients. *Pediatr Radiol* 2005;35(7): 661–7.

75) Urvoas E, Pariente D, Fausser C, Lipsich J, Taleb R, Devictor D. Diaphragmatic paralysis in children: diagnosis by TM-mode ultrasound. *Pediatr Radiol* 1994;24:564–8

- 76) Kerrey BT, Rinderknecht AS, Geis GL, Nigrovic LE, Mittiga MR. Rapid sequence intubation for pediatric emergency patients: higher frequency of failed attempts and adverse effects found by video review. *Ann Emerg Med* 2012;60(3):251–9.
- 77) Rivera R, Tibballs J. Complications of endotracheal intubation and mechanical ventilation in infants and children. *Crit Care Med* 1992; 20:193–199.
- 78) Chun R, Kirkpatrick AW, Sirois M, Sargasyn AE, Melton S, Hamilton DR et al. Where's the tube? Evaluation of hand-held ultrasound in confirming endotracheal tube placement. *Prehosp Disaster Med* 2004;19(4):366–69.
- 79) Sim SS, Lien WC, Chou HC, Chong KM, Liu SH, Wang CH et al. Ultrasonographic lung sliding sign in confirming proper endotracheal intubation during emergency intubation. *Resuscitation* 2012;83(3):307-12.
- 80) Hsieh KS, Lee C-L, Lin C-C, Huang T-C, Weng K-P, Lu W-H. Secondary confirmation of endotracheal tube position by ultrasound image. *Crit Care Med*. 2004; 32(9 Suppl) : S374-77.
- 81) Cheung EW, Ho SA, Tang KK, Chau AK, Chiu CS, Cheung YF. Pericardial effusion after open heart surgery for congenital heart disease. *Heart* 2003;89(7):780–83

- 82) Ariza J, Manuel J, María J, Ramón B. Comparative study of transthoracic ultrasound and chest X-ray in the postoperative period of thoracic surgery. *Int Surg J.* 2017;4(9): 2925-31.
- 83) ACR–SPR–STR practice parameter for the performance of portable (mobile unit) chest radiography. Revised 2017 (Resolution 3). <https://www.acr.org/-/media/ACR/Files/Practice-Parameters/Port-Chest-Rad.pdf>
- 84) Tuddenham WJ. Glossary of Terms for Thoracic Radiology: Recommendations of the Nomenclature Committee of the Fleischner Society. *Am J Roentgenol* 1984; 143(3): 509-17
- 85) Cattarossi L. Lung ultrasound: its role in neonatology and pediatrics. *Early Hum Dev* 2013;89(Suppl. 1):S17–19.
- 86) Song IK, Kim EH, Lee JH, Ro S, Kim HS, Kim JT. Effects of an alveolar recruitment manoeuvre guided by lung ultrasound on anaesthesia-induced atelectasis in infants: A randomised, controlled trial. *Anaesthesia* 2017; 72:214–22
- 87) Landis RJ, Koch GG. The Measurement of Observer Agreement for Categorical Data. *Biometrics* 1977;33: 159-174.
- 88) Alonzo TA, Pepe MS. Using a combination of reference tests to assess the accuracy of a new diagnostic test. *Statist Med* 1999; 18: 2987-3003

- 89) Nicolaou S, Talsky A, Khashoggi K, Venu V. Ultrasound-guided interventional radiology in critical care. *Crit Care Med* 2007;35(5):S186-97
- 90) Woodring JH. Recognition of pleural effusion on supine radiographs: How much fluid is required? *Am J Roentgenol.* 1984; 142(1):59-64.
- 91) Kitazono MT, Lau CT, Parada AN, Renjen P, Miller WT. Differentiation of Pleural Effusions From Parenchymal Opacities: Accuracy of Bedside Chest Radiography. *Am J of Roentgen.* 2010; 194: 407-412.

APPENDICES

INFORMED CONSENT FORM

Title of the study:

BEDSIDE CHEST ULTRASOUND IN POST OPERATIVE PAEDIATRIC CARDIAC SURGERY PATIENTS:
COMPARISON WITH BEDSIDE CHEST RADIOGRAPHY

Study number:

Your child is being requested to participate in a study to compare the diagnostic performance of bedside chest ultrasound and bedside chest radiography and interventions if required. We will include 160 patients from this hospital in this study.

What is chest ultrasound?

Your child's chest will be scanned with ultrasound by placing a probe with jelly over chest (anterior, axillary and posterior areas) and images can be seen on the monitor. All findings will be recorded and appropriate management will be done. This examination is free of pain and radiation.

Why Chest X-ray done post operatively?

Chest X-ray is routinely performed in post operative cardiac surgical patients to ensure proper expansion of lung; rule out air and fluid accumulation in lung, fluid collection around heart; confirm proper positioning of tube in trachea, tubes in chest cavity and central venous line tip above heart.

Why are we doing the study?

Chest ultrasound is totally free of radiation and recently proved to be good in diagnosing lung abnormalities. We designed this study to compare the clinical utility of Chest ultrasound and Chest X ray in post operative paediatric cardiac surgical patients.

How is Lung ultrasound and Chest X-ray compared?

After surgery your child will be shifted to Post operative Intensive care unit where routine Chest X-ray will be taken. The doctor in charge of ICU will interpret the image. Soon afterwards we will do a chest ultrasound for your child and findings from both the modalities will be recorded, analyzed and interpreted.

Is chest ultrasound safe?

Chest ultrasound uses ultrasonic waves, which is proved scientifically to have no health

hazards even after multiple exposures.

Can you withdraw from this study after it starts?

Your child's participation in this study is entirely voluntary and you are free to decide to withdraw permission to participate in this study. If you do so, this will not affect your child's routine treatment at this hospital in any way.

What will happen if you develop any study related injury?

We do not expect any injury to happen to your child, but if your child does develop any side effects or problems due to the study, these will be treated at no cost to you.

Will you have to pay for the study?

No.

Will your personal details be kept confidential?

The results of this study will be published as thesis or in a medical journal. But your child will not be identified by name or inpatient number in any publication or presentation of results. Your child's medical notes will only be reviewed by people associated with the study.

If you have any further questions, please ask

- Dr. Don Jose Palamattam. Senior Resident, Cardiac Anaesthesia Phone number: 9440377506
- Dr. Mala Ramanathan, Member Secretary, IEC, SCTIMST. Phone number - 0471-2524234. **Email: iec.mem.sec@sctimst.ac.in**

DECLARATION

I, _____, Father / Mother / Uncle /Aunty /Grandparent/ Guardian/
Relative (Please tick) of _____ [**Participant’s name: Date of
Birth / Age (in years)**] declare that I have read the patient information sheet provided to
me regarding the study “Bedside Chest Ultrasound in Post Operative Paediatric Cardiac Surgery
Patients: Comparison with Bedside Chest Radiography.”

- I have clarified doubts that I had. []
- I also understand that my child’s participation in this study is entirely voluntary and that he/she
is free to withdraw from participation at any time without affecting the usual treatment or legal
rights []
- I also understand that that my child will have to undergo Chest X –ray as routinely done in post
operative Intensive care unit and also Chest ultrasound as soon as Chest X-ray is taken. Chest
ultrasound will be done whenever Chest X-ray is taken till my child’s stay in ICU. []
- I understand that the study staff and institutional ethics committee members will not need my
permission to look at the health records of my child even if I withdraw them from the trial. I
agree to this access []
- I understand that my my child’s identity will not be revealed to third parties or published []
- I voluntarily agree to my child’s participation in this study []
- I have received a copy of this signed consent form []

Name:

Signature:

Date:

Relation to participant :

Name of witness:

Study Independent Contact Person-----Dr. Mala Ramnathan, Professor, AMCHSS &
IEC Member Secretary , SCTIMST (0471-2446234) . . **Email:**
iec.mem.sec@sctimst.ac.in

Declaration by Person Obtaining Consent

I attest that the requirements for informed consent for the medical research project described in this form have been satisfied. I have discussed the research project with the participant's parents/guardian and explained to him/her in non-technical terms all of the information contained in this informed consent form, including any risks and adverse reactions that may reasonably be expected to occur. I further certify that I encouraged the participant's parents/guardian to ask questions and that all questions asked were answered.

Signature:

Date:

Dr. Don Jose Palamattam ,
Senior Resident, CVTA,
SCTIMST.
(Ph No: 9440377506)

കാര്യവിവരണപത്രം

പഠന ശീർഷകം

ഹൃദയശസ്ത്രക്രിയ വേണ്ടിവരുന്ന കുട്ടികളായ രോഗികളെ, കുട്ടികളുടെ കാർഡിയോതൊറാസിക് തീവ്യപരിചരണവിഭാഗത്തിൽവെച്ച് ശസ്ത്രക്രിയയ്ക്കു ശേഷം കിടക്കയ്ക്കുകിൽവെച്ച് നടത്തുന്ന നെഞ്ചിന്റെ അൾട്രാസൗണ്ടിന്റെയും നെഞ്ചിന്റെ റേഡിയോഗ്രാഫിയുടെയും താരതമ്യം.

പഠന നമ്പർ

സാധാരണയായി ചെയ്യുന്ന നെഞ്ചിന്റെ എക്സ്റേ പരിശോധനയിലൂടെ നിർണ്ണയിക്കുകയും ചികിത്സാപരമായി ഇടപെടലിനുനിർദ്ദേശിക്കുകയും ചെയ്യുന്നതും, കിടക്കക്കരുകിൽ വെച്ച് ചെയ്യുന്ന അൾട്രാസൗണ്ടിലൂടെ നിർണ്ണയിക്കുകയും ചികിത്സാപരമായ ഇടപെടലിനുനിർദ്ദേശിക്കുകയും ചെയ്യുന്നതും താരതമ്യം ചെയ്യാനുദ്ദേശിച്ചുള്ള ഒരു പഠനത്തിൽ താങ്കളുടെ കുട്ടിയെ പങ്കെടുപ്പിക്കണമെന്ന് അഭ്യർത്ഥിക്കുന്നു. ഈ ആശുപത്രിയിൽനിന്നു 160 പേരെ പങ്കെടുപ്പിക്കാമെന്ന് ഞങ്ങൾ പ്രതീക്ഷിക്കുന്നു.

എന്താണ് നെഞ്ചിലെ അൾട്രാസൗണ്ട്?

താങ്കളുടെ കുട്ടിയുടെ നെഞ്ചിൽ ജല്ലി പുരട്ടിയ ഒരു നിരീക്ഷണ ഉപകരണം (പ്രോബ്) വെച്ച് നെഞ്ചിന്റെ മുൻഭാഗം, വശങ്ങൾ, പിൻഭാഗം എന്നിവയുടെ അൾട്രാസൗണ്ട് ചിത്രീകരണം നടത്തും, ചിത്രങ്ങൾ മോണിറ്ററിൽ കാണാനാകും. എല്ലാ കണ്ടെത്തലുകളും രേഖപ്പെടുത്തുകയും വേണ്ടുന്ന നടപടികൾ കൈക്കൊള്ളുകയും ചെയ്യും. ഈ പരിശോധന വേദനയില്ലാത്തതും റേഡിയേഷനില്ലാത്തതുമാണ്.

ശസ്ത്രക്രിയയ്ക്കു ശേഷം എന്തിനാണ് നെഞ്ചിലെ എക്സ്റേ ചെയ്യുന്നത്?

ശസ്ത്രക്രിയയ്ക്കുശേഷം നെഞ്ചിലെ എക്സ്റേ പതിവായി ചെയ്യുന്നത് - നെഞ്ചിനകത്ത് വായു, ദ്രാവകങ്ങൾ എന്നിവയില്ല എന്നും, ശ്വാസകോശം വേണ്ടുംവിധം വികസിക്കുന്നു എന്നും, ഹൃദയത്തിനു ചുറ്റും ദ്രാവകങ്ങളുടെ ശേഖരണമില്ല എന്നും, ശ്വാസനാളത്തിലെ കുഴൽ, നെഞ്ചിനുള്ളിലെ കുഴലുകൾ, എന്നിവ ശരിയായ നിലയിലാണോയെന്നും കേന്ദ്ര വീനസ്കുഴലിനറ്റം ഹൃദയത്തിന് മുകളിലാണോ എന്നും ഉറപ്പാക്കാൻ വേണ്ടിയാണ്.

ഞങ്ങളെതിന് ഈ പഠനം നടത്തുന്നു?

ശ്വാസകോശരോഗങ്ങൾ നിർണ്ണയിക്കുന്നതിന് നെഞ്ചിലെ എക്സ്റേയേക്കാൾ നല്ലത് റേഡിയേഷൻ

നിൽനിന്നും മുക്തമായ, നെഞ്ചിലെ അശ്വദ്രാസൗണ്ടാണെന്ന് സമീപകാലത്ത് തെളിയിക്കപ്പെട്ടിട്ടുണ്ട്. ഹൃദയശസ്ത്രക്രിയ വേണ്ടിവരുന്ന, കുട്ടികളുടെ ശസ്ത്രക്രിയയ്ക്കു ശേഷം കിടക്കയ്ക്കുകിൽവെച്ച് നടത്തുന്ന നെഞ്ചിന്റെ അശ്വദ്രാസൗണ്ടിന്റെയും നെഞ്ചിന്റെ റേഡിയോഗ്രാഫിയുടെയും താരതമ്യം ചെയ്യാനാണ് ഈ പഠനം നടത്തുന്നത്.

എങ്ങിനെയാണ് ശ്വാസകോശ അശ്വദ്രാസൗണ്ടും നെഞ്ചിലെ എക്സ്റേയും താരതമ്യം ചെയ്യുന്നത്?

ശസ്ത്രക്രിയയ്ക്കു ശേഷം താങ്കളുടെ കുട്ടിയെ ശസ്ത്രക്രിയാനന്തര തീവ്രപരിചരണ വിഭാഗത്തിലേക്ക് മാറ്റി പതിവായുള്ള നെഞ്ചിലെ എക്സ്റേ എടുക്കുകയും തീവ്രപരിചരണ വിഭാഗത്തിലുള്ള ഡോക്ടർ ചിത്രം പരിശോധിക്കുകയും ചെയ്യും. അതു കഴിഞ്ഞാലുടൻ ഞങ്ങൾ നെഞ്ചിലെ അശ്വദ്രാസൗണ്ട് താങ്കളുടെ കുട്ടിയിൽ നടത്തുകയും രണ്ട് രീതിയിലുമുള്ള കണ്ടെത്തലുകൾ രേഖപ്പെടുത്തുകയും വിവരങ്ങൾ വിശകലനം ചെയ്യുകയും വ്യാഖ്യാനിക്കുകയും ചെയ്യും.

നെഞ്ചിലെ അശ്വദ്രാസൗണ്ട് സുരക്ഷിതമാണോ?

നെഞ്ചിലെ അശ്വദ്രാസൗണ്ടിൽ ശബ്ദാതീത തരങ്കങ്ങളുപയോഗിക്കുന്നത് ഒന്നിലേറെ പ്രാവശ്യമുപയോഗിച്ചാലും ആരോഗ്യത്തിന് ഹാനികരമല്ലെന്ന് ശാസ്ത്രീയമായി തെളിഞ്ഞിട്ടുണ്ട്.

പഠനമാരംഭിച്ച ശേഷം താങ്കൾക്ക് പിൻമാറാമോ?

താങ്കളുടെ കുട്ടിയുടെ പഠനത്തിലുള്ള പങ്കാളിത്തം തികച്ചും സ്വമേധയായാണ്, പഠനത്തിലെ പങ്കാളിത്തത്തിൽ നിന്നും പിൻമാറാൻ തീരുമാനമെടുക്കാൻ താങ്കൾക്ക് സ്വാതന്ത്ര്യമുണ്ട്. താങ്കളങ്ങനെ ചെയ്താലും താങ്കളുടെ കുട്ടിയുടെ ഈ ആശുപത്രിയിലെ പതിവ് ചികിത്സയെ ഒരുവിധത്തിലും ബാധിക്കില്ല.

പഠനാനുബന്ധിയായ അപകടമുണ്ടായാൽ എന്ത് സംഭവിക്കും?

പഠനവുമായി ബന്ധപ്പെട്ട് താങ്കളുടെ കുട്ടിക്ക് പരുക്കുകളെന്തെങ്കിലുമുണ്ടാകുമെന്ന് ഞങ്ങൾ പ്രതീക്ഷിക്കുന്നില്ല. പക്ഷേ താങ്കളുടെ കുട്ടിക്ക് എന്തെങ്കിലും പാർശ്വഫലങ്ങളോ പ്രശ്നങ്ങളോ പഠനത്തിനിടയിലുണ്ടായാൽ അവ താങ്കൾക്ക് ചിലവൊന്നുമുണ്ടാകാതെ ചികിത്സിക്കപ്പെടും.

പഠനത്തിനായി താങ്കൾ പണം ചിലവാക്കണോ?

വേണ്ട

താങ്കളുടെ വ്യക്തിവിവരങ്ങൾ രഹസ്യമായിരിക്കുമോ?

പഠനഫലങ്ങൾ പ്രബന്ധമായോ ഒരു വൈദ്യശാസ്ത്ര ജേർണലിലോ പ്രസിദ്ധീകരിക്കുമെങ്കിലും താങ്കളെ വ്യക്തിപരമായി തിരിച്ചറിയാനിടയാക്കുന്നതൊന്നും പ്രസിദ്ധീകരണത്തിലോ, പഠനഫലങ്ങളുടെ പ്രദർശനത്തിലോ ഉണ്ടാവില്ല. താങ്കളുടെ കുട്ടിയുടെ മെഡിക്കൽ വിവരങ്ങൾ പഠനവുമായി ബന്ധപ്പെട്ടയാളുകൾ മാത്രം പരിശോധിച്ചേക്കാം.

താങ്കൾക്ക് കൂടുതൽ എന്തെങ്കിലും ചോദ്യങ്ങൾ ഉണ്ടെങ്കിൽ ദയവായി ഞങ്ങളോട് ചോദിക്കുക

ഡോ. ഡോൺ ജോസ് പാലമറ്റം, സീനിയർ റസിഡന്റ് (പ്രധാന ഗവേഷകൻ), ഡിപ്പാർട്ട്മെന്റ് ഓഫ് കാർഡിയോതൊറാസിക് ആന്റ് വാസ്കുലാർ അനസ്തേഷ്യ (ഫോൺ: **9440377506**).

ഡോ. രൂപ ശ്രീധർ, പ്രൊഫസർ ആന്റ് ഹെഡ്, ഡിപ്പാർട്ട്മെന്റ് ഓഫ് കാർഡിയോതൊറാസിക് ആന്റ് വാസ്കുലാർ അനസ്തേഷ്യ

ഇൻസ്റ്റിറ്റ്യൂഷണൽ എത്തിക്സ് കമ്മിറ്റി അംഗവുമായി ബന്ധപ്പെടുന്നതിന് സ്ഥാപനത്തിലെ നൈതീക കമ്മിറ്റി മെമ്പർ സെക്രട്ടറി

ഡോ. മാല രാമനാഥനെ ബന്ധപ്പെടാം. ഫോൺ: 0471-2524234, Email: iec.mem.sec@sctimst.ac.in

കാര്യബോധത്തോടെയുള്ള സമ്മതപത്രം

ഞാൻ(അച്ഛൻ/അമ്മ/ അമ്മാവൻ/അമ്മായി/ അപ്പുപ്പൻ/അമ്മമ്മ/രക്ഷകർത്താവ്/ബന്ധു)..... (പങ്കെടുക്കുന്ന കുട്ടിയുടെ പേര്/ജനനതീയതി/വയസ്സ്(വർഷത്തിൽ) എനിക്കു തന്ന പഠനവുമായി ബന്ധപ്പെട്ട രോഗിക്കുള്ള കാര്യ വിവരണപത്രം വായിച്ചു എന്ന് പ്രസ്താവിക്കുന്നു

പഠന ശീർഷകം

ഹൃദയശസ്ത്രക്രിയ വേണ്ടിവരുന്ന കുട്ടികളായ രോഗികളെ, കുട്ടികളുടെ കാർഡിയോ തൊറാസിക് തീവ്രപരിചരണവിഭാഗത്തിൽവെച്ച് ശസ്ത്രക്രിയക്കു ശേഷം കിടക്കയ്ക്കരു കിടവെച്ച് നടത്തുന്ന നെഞ്ചിന്റെ അൾട്രാസൗണ്ടിന്റെയും നെഞ്ചിന്റെ റേഡിയോഗ്രഫിയുടെയും താരതമ്യം.

(കോളങ്ങൾ അടയാളപ്പെടുത്തുക).

- എന്റെ എല്ലാ സംശയങ്ങളും പരിഹരിച്ചു. []
- എന്റെ കുട്ടിയുടെ ഈ പഠനത്തിലുള്ള പങ്കാളിത്തം പൂർണ്ണമായും സ്വമേധയായാണെന്നും അനുവാദം കുട്ടിക്ക് ഏതുസമയത്തും ചികിത്സയെയോ നിയമപരമായ അവകാശങ്ങളെയോ ബാധിക്കാതെ പിൻവലിക്കാൻ അവകാശമുണ്ടെന്നും ഞാൻ മനസ്സിലാക്കുന്നു. []
- എന്റെ കുട്ടിക്ക് ശസ്ത്രക്രിയക്കുശേഷം തീവ്രപരിചരണവിഭാഗത്തിൽവെച്ച് പതിവായി നടത്തുന്ന നെഞ്ചിലെ എക്സ്റേയും ഉടനതന്നെ നെഞ്ചിലെ അൾട്രാസൗണ്ട് ചിത്രീകരണവും ചെയ്യുമെന്നും ഞാൻ മനസ്സിലാക്കുന്നു. എന്റെ കുട്ടി തീവ്രപരിചരണവിഭാഗത്തിൽ ഉണ്ടായിരിക്കുന്നിടത്തോളം എപ്പോഴൊക്കെ നെഞ്ചിലെ എക്സ്റേ എടുക്കുമോ അപ്പോഴൊക്കെ നെഞ്ചിലെ അൾട്രാസൗണ്ടും ചെയ്യും.[]
- എന്റെ കുട്ടി ഈ പഠനത്തിൽ നിന്നും പിൻമാറിയാലും പഠനം നടത്തുന്നവർക്കും സ്ഥാപനത്തിലെ നൈതിക കമ്മിറ്റി അംഗങ്ങൾക്കും എന്റെ കുട്ടിയുടെ ആരോഗ്യരേഖകൾ പരിശോധിക്കുന്നതിന് എന്റെ അനുവാദം ആവശ്യമില്ലെന്ന് ഞാൻ മനസ്സിലാക്കുന്നു. അതിനോട് ഞാൻ യോജിക്കുന്നു.[]

- എന്റെ കുട്ടിയെ തിരിച്ചറിയാനുതകുന്ന വിവരങ്ങൾ ഒന്നും മറ്റുള്ളവർക്കു നൽകുകയോ പ്രസിദ്ധീകരിക്കുകയോ ചെയ്തില്ലെന്ന് ഞാൻ മനസ്സിലാക്കുന്നു. []
- എന്റെ കുട്ടിയെ സ്വമേധയാ പഠനത്തിൽ പങ്കെടുപ്പിക്കാൻ സമ്മതിക്കുന്നു []
- എനിക്ക് പഠനത്തെപ്പറ്റിയോ പങ്കാളിയുടെ അവകാശങ്ങളെപ്പറ്റിയോ കൂടുതൽ അറിയണമെങ്കിൽ പ്രധാനഗവേഷകനെ ബന്ധപ്പെടാനുള്ള നമ്പർ നൽകിയിട്ടുണ്ട്. []
- സമ്മതപത്രത്തിന്റെ ഒപ്പിട്ട ഒരു കോപ്പി എനിക്കു കിട്ടി []

പേര് :

ഒപ്പ് :

തീയതി :

പങ്കെടുക്കുന്ന ആളുമായുള്ള ബന്ധം :

സാക്ഷിയുടെ പേര് :

പഠനത്തിലില്ലാത്ത ബന്ധപ്പെടാവുന്ന വ്യക്തി

ഡോ. മാലരാമനാഥൻ, പ്രൊഫസർ, AMCHSS, SCTIMST, നൈതീക കമ്മിറ്റി മെമ്പർ
സെക്രട്ടറി, ഫോൺ: 0471-2446234, Email: iec.mem.sec@sctimst.ac.in

(സമ്മതപത്രം വാങ്ങുന്നയാളുടെ പ്രസ്താവന)

മെഡിക്കൽ റിസർച്ച് പ്രോജക്ടിനാവശ്യമായ സമ്മതപത്രത്തിനു വേണ്ടുന്ന എല്ലാഘടകങ്ങളും തൃപ്തികരമായി നിർവഹിച്ചിരിക്കുന്നുവെന്ന് ഞാൻ ബോധ്യപ്പെടുത്തുന്നു. പഠനപങ്കാളിയുമായി ഗവേഷണപദ്ധതിയെപ്പറ്റി സാങ്കേതികേതര പദങ്ങളുപയോഗിച്ച് എല്ലാവിവരങ്ങളെപ്പറ്റിയും ചർച്ച നടത്തുകയും പ്രതീക്ഷിക്കാവുന്ന അപകടസാധ്യതകളും പാർശ്വഫലങ്ങളും വിശദീകരിക്കുകയും ചെയ്തു. പങ്കാളിയെ ചോദ്യങ്ങൾ ചോദിക്കാൻ പ്രേരിപ്പിക്കുകയും എല്ലാചോദ്യങ്ങൾക്കും ഉത്തരം നൽകുകയും ചെയ്തു എന്നും ഞാൻ സാക്ഷ്യപ്പെടുത്തുന്നു.

ഒപ്പ്:

തീയതി :

ഡോ. ഡോൺ ജോസ് പാലമറ്റം (പ്രധാന ഗവേഷകൻ)

സീനിയർ റെസിഡന്റ്, **CVTA, SCTIMST.**

(ഫോൺ : 9440377506)

INFORMED ASSENT FORM

I, Dr. Don Jose Palamattam working as Senior Resident in Dept. Of Cardiac Anaesthesia , Sree Chitra Tirunal Institute of Medical Science and Technology, Trivandram, request you to take part in my research study titled “Bedside Chest Ultrasound in Post Operative Paediatric Cardiac Surgery Patients: Comparison with Bedside Chest Radiography.”

This study will be a comparison between ultrasound of chest and X ray of chest. Chest X ray is routinely done in post operative intensive care unit, but is associated with harmful radiation.

I am trying to learn about your chest using a new technique called Ultrasound. It will benefit for you as no radiation will be used to study your chest. I want to learn about your chest after surgery of the heart and the various pathological conditions that can occur after surgery. This study is intended to minimize Chest x ray radiation.

This study is done when you are asleep and you wouldn't know that the study is being done. This is a painless procedure and you wouldn't face any discomfort. There are no complications from this study.

There is no compulsion for you to participate in this study. This study is voluntary, which means that you decide whether or not to take part in the study. Being in this study is up to you, and no one will be upset in any way if you do not want to participate or even if you change your mind later. It is never going to affect your treatment even if you do not participate.

Please talk this over with your parents before you decide whether or not to participate. I have asked your parents to give their permission for you to take part in this study. But even if your parents said “yes” to this study, you can still decide to not take part in the study, and that will be fine. If you decide to be in the study I will not tell anyone else what you do in the study.

You may ask any questions about the study

Signing here means, that you have read this form, or have had it read to you, and that you are willing to be in this study.

Name:

Signature:

Date:

Age:

Name of witness:

Relation to participant :

You can also contact Study Independent Person-----Dr. Mala Ramnathan, Professor,
AMCHSS & IEC Member Secretary , SCTIMST (0471-2446234). **Email:**
iec.mem.sec@sctimst.ac.in

Declaration by Person Obtaining Assent Form

I attest that the requirements for informed assent for the study described in this form have been satisfied. I have discussed the research project with the participant and explained to him/her in non-technical terms all of the information pertaining to this study, including any risks and adverse reactions that may reasonably be expected to occur. I further certify that I encouraged the participant to ask questions and that all questions asked were answered in simple language

Signature:

Date:

Dr. Don Jose Palamattam ,
Senior Resident, CVTA,
SCTIMST. (Ph No: 9440377506)

കാര്യബോധത്തോടെയുള്ള അനുവാദപത്രം

പ്രഖ്യാപനം

പഠന ശീർഷകം:

ഹൃദയ ശസ്ത്രക്രിയവേിവരുന്ന കുട്ടികളായ രോഗികളെ, കുട്ടികളുടെ കാർഡിയോതൊറാസിക് തീവ്യപരിചരണ വിഭാഗത്തിൽ വച്ച് ശസ്ത്രക്രിയക്കുശേഷം കിടക്കയ്ക്കരുകിൽവച്ച് നടത്തുന്ന നെഞ്ചിന്റെ അൾട്രാസൗന്റിന്റെയും നെഞ്ചിന്റെ റേഡിയോഗ്രഫിയുടെയും താരതമ്യം.

തിരുവനന്തപുരം ശ്രീചിത്ര തിരുനാൾ മെഡിക്കൽ സയൻസസ് ആന്റ് ടെക്നോളജിയിൽ കാർഡിയാക് അനസ്തേഷ്യ വിഭാഗത്തിൽ സീനിയർ റെസിഡന്റായി പ്രവർത്തിക്കുന്ന ഡോ. ഡോൺ ജോസ് പാലമറ്റം എന്ന ഞാൻ നടത്തുന്ന ഹൃദയ ശസ്ത്രക്രിയവേിവരുന്ന കുട്ടികളായ രോഗികളെ, കുട്ടികളുടെ കാർഡിയോതൊറാസിക് തീവ്യപരിചരണ വിഭാഗത്തിൽ വച്ച് ശസ്ത്രക്രിയക്കുശേഷം കിടക്കയ്ക്കരുകിൽവച്ച് നടത്തുന്ന നെഞ്ചിന്റെ അൾട്രാസൗന്റിന്റെയും നെഞ്ചിന്റെ റേഡിയോഗ്രഫിയുടെയും താരതമ്യം എന്ന ഗവേഷണ പഠനത്തിൽ പങ്കാളിയാ കാൻ താങ്കളോട് അഭ്യർത്ഥിക്കുന്നു.

നെഞ്ചിന്റെ അൾട്രാസൗന്റും നെഞ്ചിന്റെ എക്സ്റെയും തമ്മിലുള്ള താരതമ്യമാണ് ഈ പഠനം. നെഞ്ചിന്റെ എക്സ്റേ ശസ്ത്രക്രിയാനന്തരം തീവ്യപരിചരണ വിഭാഗത്തിൽ പതിവായി ചെയ്യുന്നതാണ്. പക്ഷേ അത് റേഡിയേഷനുള്ളതിനാൽ ദോഷകരമാണ്.

അൾട്രാസൗണ്ട് എന്ന പുതിയ സങ്കേതമുപയോഗിച്ച് താങ്കളുടെ നെഞ്ചിനെപ്പറ്റി പഠിക്കാനാണ് ഞാൻ ശ്രമിക്കുന്നത്. താങ്കൾക്ക് നെഞ്ചിൽ റേഡിയേഷനേൽക്കുന്നില്ല എന്ന നേട്ടം ഉാകും. ശസ്ത്രക്രിയാനന്തരമുള്ള താങ്കളുടെ നെഞ്ചിനെപ്പറ്റിയും ശസ്ത്രക്രിയക്കുശേഷം ഉായ അതിന്റെ വ്യത്യസ്ത പതോളജിക്കൽ സാഹചര്യങ്ങളുമാണ് ഞാൻ പഠിക്കാനാഗ്രഹിക്കുന്നത്. നെഞ്ചിലെ എക്സ്റേ റേഡിയേഷൻ പരിമിതപ്പെടുത്തുക എന്നതാണ് ഈ പഠനത്തിന്റെ ഉദ്ദേശം.

ഈ പഠനം നടത്തുന്നത് താങ്കൾ ഉറങ്ങുമ്പോഴാണെന്നതിനാൽ അത് താങ്കൾ അറിയില്ല. ഇത് വേദനാഹിതമായ ഒരു നടപടിയാകയാൽ താങ്കൾക്ക് ബുദ്ധിമുട്ട് നേരിടേവരില്ല. ഈ പഠനത്തിൽനിന്നും സങ്കീർണ്ണതയൊന്നുമുണ്ടാകില്ല.

താങ്കൾ പഠനത്തിൽ പങ്കെടുക്കുന്നതുകൊണ്ട് സങ്കീർണ്ണതകളൊന്നുമുണ്ടാകില്ല. ഈ പഠനം സ്വമേധയായുള്ളതാണ്, അതിനർത്ഥം ഈ പഠനത്തിൽ പങ്കെടുക്കണോ വേയോ എന്ന് താങ്കൾക്ക് തീരുമാനിക്കാമെന്നാണ്. പഠനത്തിൽ പങ്കെടുക്കുന്നത് താങ്കളുടെ തീരുമാനപ്രകാരമാ

ണ്, താങ്കൾ പങ്കെടുക്കുന്നില്ല എന്നതോ പിന്നീട് താങ്കളുടെ മനസ്സു മറു എന്നതോ ആരോയും നിരാശരാക്കുന്നില്ല. താങ്കൾ പങ്കെടുത്തില്ലെങ്കിലും താങ്കളുടെ ചികിത്സയെ അത്ബാധി ക്കില്ല.

പങ്കെടുക്കണോ വേയോ എന്ന് തീരുമാനിക്കുന്നതിനുമുമ്പ് ദയവായി താങ്കളുടെ മാതാപി താക്കളുമായി സംസാരിക്കുക. താങ്കളുടെ മാതാപിതാക്കളോട് സമ്മതം തരണമെന്ന് ഞാൻ ആവശ്യപ്പെട്ടിട്ടു്. പക്ഷേ താങ്കളുടെ മാതാപിതാക്കൾ സമ്മതം നൽകിയാലും താങ്കൾക്ക് പഠന ത്തിൽ പങ്കെടുക്കേന്ന് തീരുമാനിക്കാം, അതും കൃപ്യമില്ല. താങ്കൾ പഠനത്തിൽ പങ്കെടുക്കാൻ തീരുമാനിച്ചാൽ പഠനത്തിൽ താങ്കളെന്തുചെയ്യുന്നു എന്ന് ഞാനാരോടും പറയില്ല.

പഠനത്തെപ്പറ്റി താങ്കൾക്ക് ഏതു ചോദ്യവും ചോദിക്കാം.

ഇതിൽ ഒപ്പിടുന്നതിനർത്ഥം താങ്കൾ ഈ പത്രിക വായിച്ചു/വായിച്ചുകേട്ടു എന്നും താങ്കൾക്ക് ഈ പഠനത്തിൽ പങ്കെടുക്കാൻ സമ്മതമാണെന്നുമാണ്.

പേര്.....

ഒപ്പ്

തിയതി

വയസ്സ്

സാക്ഷിയുടെ പേര്

പങ്കാളിയുമായുള്ള ബന്ധം

താങ്കൾക്ക് പഠനത്തിൽബന്ധമില്ലാത്ത വ്യക്തിയെ ബന്ധപ്പെടാൻ ഇൻസ്റ്റിറ്റ്യൂഷണൽ എത്തിക്സ് കമ്മിറ്റി അംഗവുമായി ബന്ധപ്പെടുന്നതിന് ദയവായി സ്ഥാപനത്തിലെ നൈതീക കമ്മിറ്റി മെമ്പർ സെക്രട്ടറി ഡോ. മാല രാമനാഥൻ പ്രൊഫസർ AMCHSS, ബന്ധപ്പെടാം. ഫോൺ 0471 2524234, email: iec.mem.sec@sctimst.ac.in

(അനുവാദപത്രം വാങ്ങുന്നയാളുടെ പ്രസ്താവന)

മെഡിക്കൽ റിസർച്ച് പ്രോജക്ടിനാവശ്യമായ സമ്മതപത്രത്തിനു വേണ്ടി എല്ലാ ഘടകങ്ങളും തൃപ്തികരമായി നിർവഹിച്ചിരിക്കുന്നുവെന്ന് ഞാൻ ബോധ്യപ്പെടുത്തുന്നു. പഠനപങ്കാളിയുമായി ഗവേഷണപദ്ധതിയെപ്പറ്റി സാങ്കേതികേതര പദങ്ങളുപയോഗിച്ച് എല്ലാ വിവരങ്ങളെപ്പറ്റിയും ചർച്ച നടത്തുകയും പ്രതീക്ഷിക്കാവുന്ന അപകടസാധ്യതകളും പാർശ്വഫലങ്ങളും വിശദീകരിക്കുകയും ചെയ്തു. പങ്കാളിയെ ചോദ്യങ്ങൾ ചോദിക്കാൻ പ്രേരിപ്പിക്കുകയും എല്ലാ ചോദ്യങ്ങൾക്കും ഉത്തരം നൽകുകയും ചെയ്തു എന്നും ഞാൻ സാക്ഷ്യപ്പെടുത്തുന്നു.

സമ്മതപത്രം വാങ്ങുന്ന ആളുടെ പേരും ഒപ്പും

തീയതി

ഡോ. ഡോൺ ജോസ് പാലമറ്റം

സീനിയർ റെസിഡന്റ്, **CVTA,**

SCTIMST

(ഫോൺ 9440377506)

CHEST ULTRASOUND DATA CHART

PATIENT ID:

PATIENT NAME:

AGE:

SEX:

DIAGNOSIS:

SURGERY:

POST OPERATIVE DAY:

INTUBATION: YES/NO

MODE OF VENTILATION: PRVC/ SIMV(PRVC)/ CPAP/ T-PIECE/ OTHER

S.no	SIGNS/ FINDINGS	ANTERIOR				AXILLARY				POSTERIOR			
		UPPER		LOWER		UPPER		LOWER		UPPER		LOWER	
		R	L	R	L	R	L	R	L	R	L	R	L
1	BAT'S APPEARANCE												
2	PLEURAL LINE												
3	SLIDING SIGN												
4	LUNG PULSE												
5	SEASHORE SIGN												
6	BARCODE SIGN												
7	LUNG POINT												
8	QUADRANGULAR SIGN												
9	SINUSOIDAL SIGN												
10	MAXIMUM DISTANCE BETWEEN PLEURAL LAYERS												
11	A-LINE												
12	B-LINE												
13	Z-LINE												
14	TISSUE LIKE PATTERN												
15	AIR BRONCHOGRAM [STATIC(S)/DYNAMIC(D)]												

DIAPHRAGM ANALYSIS BY ULTRASOUND

S.NO		RIGHT	LEFT
1	DIAPHRAGMATIC MOVEMENT ON MECHANICAL VENTILATOR(CONTROLLED VENTILATION)		
2	DIAPHRAGMATIC EXCURSION DURING SPONTANEOUS VENTILATION(ASSISTED VENTILATION/POST EXTUBATION)		

➤ FINAL DIAGNOSIS AS PER LUNG ULTRASOUND:

- SUBCUTANEOUS EMPYSEMA:
 - PNEUMOTHORAX:
 - PLEURAL EFFUSION:
 - INTERSTITIAL EDEMA:
 -
 - CONSOLIDATION:
 - ATELECTASIS
 - PNEUMONIA
 - PERICARDIAL EFFUSION/CARDIAC TAMPONADE
 - DIAPHRAGMATIC PARALYSIS
 - ENDOBRONCHIAL INTUBATION
 - POSITION OF NASOGASTRIC TUBE
 - POSITION OF CENTRAL VENOUS CANNULA
 - POSITION OF CHEST DRAINS:
-
-

➤ -THERAPEUTIC INTERVENTIONS PLANNED:

BED SIDE CHEST X-RAY DATA CHART

1.SUBCUTANEOUS EMPYSEMA: RIGHT HEMITHORAX LEFT HEMITHORAX ABSENT

2.PNEUMOTHORAX: RIGHT HEMITHORAX LEFT HEMITHORAX ABSENT

3.PLEURAL EFFUSION: RIGHT HEMITHORAX LEFT HEMITHORAX ABSENT

4. INTERSTITIAL EDEMA: PRESENT ABSENT

5.CONSolidATION: RIGHT UPPER HEMITHORAX RIGHT LOWER HEMITHORAX

 LEFT UPPERHEMITHORAX LEFT LOWER HEMITHORAX ABSENT

6. MEDIASTINAL WIDENING: PRESENT ABSENT

7. ABNORMAL DIAPHRAGMATIC ELEVATION: RIGHT LEFT ABSENT

8. ENDOTRACHEAL TUBE: NORMAL ABOVE T2 BELOW T4

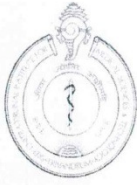9. NASO GASTRIC TUBE: Oesophagus Stomach Duodenum

10. POSITION OF CENTRAL VENOUS CANNULA:

11. POSITION OF CHEST DRAINS:

FINAL DIAGNOSIS AS PER CHEST X-RAY:

THERAPEUTIC INTERVENTION PLANNED:



Technical Advisory Committee (Clinical Studies)
SREE CHITRA TIRUNAL INSTITUTE FOR MEDICAL SCIENCES & TECHNOLOGY
THIRUVANANTHAPURAM – 695011, INDIA

TAC Registration No: SCT-/S/2018/740

Date: 23.05.2018

Project title: BEDSIDE CHEST ULTRASOUND IN POST OPERATIVE PAEDIATRIC CARDIAC SURGERY PATIENTS: COMPARISON WITH BEDSIDE CHEST RADIOGRAPHY

Principal Investigator:	
Dr. Don Jose Palamattam, Senior Resident, Department of Anaesthesiology, SCTIMST, Degree: M.D (Anaesthesiology), M.B.B.S.	
Co-Principal Investigator(s)	
Dr. Rupa Sreedhar, Professor and Head, Department of Anesthesiology, SCTIMST Degree: Post-Doctoral Certificate Course (PDCC): Cardiothoracic Vascular and Neurosurgical Anesthesiology. D.N.B. (Anesthesiology), M.D. (Anesthesiology), D.A. (Anesthesiology), M.B.B.S.	
Co- Investigator(s)	
Dr. Shrinivas Gadhinglajkar, Professor, Department of Anesthesiology, SCTIMST	Degree: Post-Doctoral Certificate Course (PDCC): Cardiothoracic Vascular and Neurosurgical Anesthesiology. M.D. (Anesthesiology), M.B.B.S.,
Dr. Prasanta Kumar Dash, Professor, Department of Anesthesiology, SCTIMST	Degree: Post-Doctoral Certificate Course (PDCC): Cardiothoracic Vascular and Neurosurgical Anesthesiology. M.D. (Anesthesiology), M.B.B.S.
Dr. Subin Sukeshan, Associate Professor, Department of Anesthesiology, SCTIMST	Degree: DM (Cardio Thoracic and Vascular Anesthesia), M.D. (Anesthesiology), M.B.B.S.
Dr Baiju S Dharan, Professor, Department of Cardiovascular & Thoracic Surgery, SCTIMST	Degree : MCH (Cardiovascular And Thoracic Surgery), M.S (General Surgery), M.B.B.S
Dr. Santhosh Kumar K, Associate Professor, Department of IS & IR, SCTIMST	Degree : Post-Doctoral Certificate Course (PDCC) : Imaging Sciences and Interventional Radiology, M.D. (Radiology), M.B.B.S.

Members who participated in the TAC meeting on 19/05/2018

Dr. Rupa Sreedhar (Chairperson)
Dr. Prasantakumar Dash
Dr. Sanjay G
Dr. Krishna Kumar K
Dr. Sankara Sarma P
Dr. Sylaja PN
Dr. Ashalatha. R
Dr. Bijulal S
Dr. Jayadevan ER
Dr. Syam K
Dr. Varghese T. Panicker
Dr. K. Shivakumar (Member Secretary)

Dr. Rupa Sreedhar, Dr. Syam K, Dr. Sylaja PN, Dr. Prasantakumar Dash, Dr. Varghese T. Panicker and Dr. Ashalatha. R stayed away from the proceedings when the projects in which they are involved as investigator were discussed (#736,737, 738, 740, 741,743,744, 746, 749, 752).

Risk Classification of the project (Minimum/ Moderate/ High): Minimum

Requirement of DSMB: No

Recommended members of DSMB: Not applicable

Recommendations of TAC:

Recommended for consideration of IEC in the light of the responses received from the investigator
The PI may note that there can be no additions / alterations in the documents approved by TAC when they are submitted to the IEC.


Signature of the Member Secretary, TAC (Clinical Studies)

Note for IEC

Copy of the investigator's responses to questions/suggestions from TAC is attached (Appendix-1).

Appendix-1

Since the study involves primarily radiological modalities (USG Chest and X-ray Chest) for patient evaluation, it is better to include a radiologist also in the study group.

Answer: Dr. Santhosh Kumar K, Associate Professor, Department of Imaging Sciences and Interventional Radiology (IS & IR) has been added in the study as Co- Investigator as suggested.



श्री चित्रा तिरुनाल आयुर्विज्ञान और प्रौद्योगिकी संस्थान, त्रिवेन्द्रम
तिरुवनन्तपुरम - ६९५०११, केरल, इंडिया

SREE CHITRA TIRUNAL INSTITUTE FOR MEDICAL SCIENCES AND TECHNOLOGY, TRIVANDRUM
Thiruvananthapuram - 695 011, Kerala, India
(An Institute of National Importance under Govt. of India)

Grams : Chitramet, Phone : +91-471-2443152, Fax : +91-471-2550728 / 2446433, E-mail : sct@sctimst.ac.in, Website : www.sctimst.ac.in

Institutional Ethics Committee (IEC Regn No. ECR/189/Inst/KL/2013/RR-16)

SCT/IEC/1223/JUNE-2018

03.08.2018

Dr. Don Jose Palamattam
Senior Resident
Department of Anaesthesiology
SCTIMST, Thiruvananthapuram

Dear Dr. Don Jose Palamattam,

The Institutional Ethics Committee reviewed and discussed your application to conduct the study entitled "BEDSIDE CHEST ULTRASOUND IN POST OPERATIVE PAEDIATRIC CARDIAC SURGERY PATIENTS: COMPARISON WITH BEDSIDE CHEST RADIOGRAPHY" (IEC/1223)" on 16th June, 2018.

The following documents were reviewed:

Original submission

1. Covering letter addressed to the Chairman, IEC, SCTIMST dated 22.05.2018 with check list
2. TAC Approval Letter
3. IEC Application Form
4. Project Proposal
5. Proforma
6. Information Sheet and Informed Consent Form in English and Malayalam
7. CV of Principal Investigator and Co-Principal Investigators

Revised submission

1. Covering letter addressed to the Chairman, IEC, SCTIMST dated 18.07.2018 with check list
2. Response to recommendations of IEC
3. Copy of IEC Recommendation Letter dated 19.06.2018
4. TAC Approval Letter
5. IEC Application Form
6. Project Proposal
7. Proforma
8. Information Sheet and Informed Consent Form in English and Malayalam
9. Informed Assent Form in English and Malayalam
10. CV of Principal Investigator and Co-Principal Investigators

Page 1 of 2

The following members of the Ethics Committee were present at the meeting held on 16th June, 2018 at Noshir H Wadia Conference Hall, AMCHSS, SCTIMST

SL. No.	Member Name	Highest Degree	Gender	Scientific /Non Scientific	Affiliation with Institution(s)
1.	Dr. R V G Menon	M Tech, PhD	Male	Lay Person (Chairman)	No
2.	Dr. Rema M. N	MD	Female	Basic Medical Scientist	No
3.	Dr. Kala Kesavan. P	MBBS, MD	Female	Basic Medical Scientist	No
4.	Dr. K R S Krishnan	M.E., Ph.D.	Male	Medical Technology	Yes
5.	Dr. S S Giri Sankar	LL.M. Ph.D.	Male	Legal Expert	No
6.	Dr. Aneesh V Pillai	BA. LLB (Hons.), LLM, Ph. D, SET (Law)	Male	Legal Expert	No
7.	Mr. Satheesh Chandran	MSW, PGDPM	Male	Lay person/ NGO/ Social Scientist	No
8.	Dr. Harikrishna Varma PR	Ph.D(Materials Science)	Male	Medical Technology	Yes
9.	Dr. P. Manickam	BSMS, MSc (Epid),PhD	Male	Health Science Expert/ Social Scientist	No
10.	Smt. Sathi Nair	MA (English Literature)	Female	Lay Person	No
11.	Dr. Christina George	MD Psychiatry	Female	Clinician	No
12.	Dr. Anand Kumar A	MD, DM	Male	Clinician	No
13.	Dr. V. Raman Kutty	M D, M Phil, M P H	Male	Health Sciences Expert/Clinician	Yes
14.	Dr. Mala Ramanathan	PhD	Female	Social Scientist (Member Secretary)	Yes

IEC Decision

The IEC approved the conduct of the study in the present form.

Remarks:

The Institutional Ethics Committee expects to be informed about the progress of the study, any SAE occurring in the course of the study, any changes in the protocol and patient information/informed consent and asks to be provided a copy of the final report.

There was no member of the study team who participated in voting / decision making process. The ethics committee is organized and operated according to the requirements of Good Clinical Practice and the requirements of the Indian Council of Medical Research (ICMR).

Sincerely,


Mala Ramanathan
 Member Secretary, IEC

PLAGIARISM CHECK



Plagiarism Checker X Originality Report

Similarity Found: 14%

Date: Sunday, July 28, 2019

Statistics: 944 words Plagiarized / 6225 Total words

Remarks: Low Plagiarism Detected - Your Document needs Optional Improvement.

BEDSIDE CHEST ULTRASOUND IN POST OPERATIVE PAEDIATRIC CARDIAC SURGERY PATIENTS: COMPARISON WITH BEDSIDE CHEST RADIOGRAPHY

INTRODUCTION: Traditionally, chest imaging in post operative cardiac surgical patients, is performed using bedside chest radiography (CXR). It is considered as standard of care to evaluate intra-thoracic structures including heart, lung, mediastinum and their abnormalities. CXR also evaluates position of chest tubes, mediastinal tubes, central venous lines, pulmonary artery catheters, endotracheal tubes and enteral feeding tube [1].

Respiratory complication is one of the major causes of morbidity and death in cardiac post operative patients in adult and pediatric population. Whenever there is a suspicion of intra thoracic pathology including improper position of tubes and catheters, the need for repeated bedside CXR and thus subsequent unavoidable radiation exposure is inevitable.

Other factors leading to the need for repetition of bedside CXR are suboptimal X-ray films, improper positioning of patient and poor correlation with CT scan [2]. Each bedside CXR exposes a patient to 0.02 milli-sieverts of radiation [3]. Though it looks invariably small, repeated CXRs exposes patient to increasing amounts of radiation.

Paediatric age group especially neonates, have greater areas of exposure, due to small body surface area and are thus sensitive to hazardous effects of ionizing radiation. The threat of developing immune dysfunction, cataract, cognitive decline and malignancy in later part of life is a possibility [4]. Therefore, effort should be made to minimize radiation exposure whenever possible [5]. Chest ultrasound (CUS) is a fast, repeatable

and radiation free methodology.

It is simple to use and requires a limited period of training [6]. It allows for bedside detection of primary pulmonary pathologies [7] such as pleural effusion, pneumothorax, lung atelectasis, or secondary pulmonary pathologies due to cardiac causes (interstitial pulmonary oedema, basal atelectasis) and conditions such as diaphragmatic palsy, subcutaneous emphysema, pericardial effusion, cardiac tamponade and endobronchial intubation [8].

INTERNET SOURCES:

- 0% - Empty
- 0% - <http://tlcr.amegroups.com/article/view/1>
- 0% - <https://www.sciencedirect.com/science/ar>
- 0% - <https://www.mcgill.ca/anesthesia/files/a>
- 0% - http://wikimd.org/index.php/Usmle_Step_3
- 0% - <https://naturalsociety.com/radiation-exp>
- 0% - https://www.bing.com/aclk?ld=e33a_Obu2Lf
- 0% - <https://efsa.onlinelibrary.wiley.com/doi>
- 0% - <https://www.sciencedirect.com/science/ar>
- 0% - <https://refugeecouncil.org.uk/wp-content>
- 0% - <https://emj.bmj.com/content/35/4/258>
- 0% - <http://www.jbiomed.com/v01p0009.htm>
- 0% - <https://www.ncbi.nlm.nih.gov/pmc/article>
- 0% - <https://www.researchgate.net/publication>
- 0% - <https://patents.google.com/patent/WO2011>
- 0% - <https://www.sciencedirect.com/science/ar>
- 0% - <https://www.researchgate.net/publication>
- 0% - <https://clinicalgate.com/nosocomial-infe>
- 0% - <https://www.researchgate.net/publication>
- 0% - <https://cihsr.in/clinical-services/>
- 0% - <https://www.sciencedirect.com/topics/vet>
- 0% - <https://www.researchgate.net/publication>
- 0% - <https://www.researchgate.net/publication>
- 0% - <http://www.bjcv.org/article/2706/en-us/>

MASTER CHART

S.No	Ip No	Age	Sex	Diagnosis	Surgery	POD	Diagnosis by CXR	Diagnosis by Chest USG	Intervention Taken
1	433042	3 yrs	M	OS-ASD mild PAH GDLV	ASD closure	0	normal study	normal study	
2	458268	11 months	F	large PDA GDLV	PDA interruption	1	normal study	normal study	
3	422007	4yrs 11 months	M	Post SCA CoA	CoA repair	0	Lt interstitial edema	Lt interstitial edema	
4	408692	7yrs 3months	F	OS-ASD no PAH GDLV	ASD closure	1	Lt interstitial edema	Lt interstitial edema	diuretics given
5	368036	5yrs	M	TOF sev Infund PS, mild LPA stenosis	ICR	0	normal study	normal study	
6	397739	9y 6m	F	OS-ASD mild PAH GDLV	OS-ASD closure	1	normal study	normal study	
7	204860	18yrs	M	p/TOF with ICR, now with Sev PR	Redo+ PVR (#23 PM magna)	0	normal study	normal study	
8	453023	10 m	M	p/TOF with ICR, now with Sev PR	Redo+ PVR (#23 PM magna)	0	interstitial edema	interstitial edema	
9	451628	4yrs	M	SA-VSD, sev PAH, mild TR GDLV	VSD closure	1	interstitial edema	interstitial edema	diuretics given
10	456167	6 months	M	SAVSD RCC prolapse GDLV	VSD closure	0	Left upper lobe cosolidation	Left Upper Lobe Atelectasis	lung recruitment
11	455931	5 months	M	DORV, hypo RV, UnBal AVCD	R BDG	1	normal study	normal study	
12	444681	3yr 5 months	M	SAVSD RCC prolapse GDLV	VSD closure	0	normal study	left basal atelectasis and interstitial lung	recruitment
13	443491	9 months	M	multiple VSD, Sev PAH, B/L SVC	VSD closure	1	normal study	normal study	
14	443491	9 months	M	SP-Vsd Rcc prolapse GDLV	VSD closure	0	interstitial edema	left basal atelectasis with minimal	diuretics given
15	453663	4yrs 6 months	F	comp bal AVCD, sev TR, mod MR, ASD, sev f AVCD repair	ICR	1	interstitial edema	interstitial edema	
16	427271	3yrs 1month	F	Dorv, sev Infun PS GDLV	ICR	0	interstitial edema	interstitial edema	diuretics given
17	413271	4yrs 4 months	M	TA, VSD, Sev PS, OSASD	rt BDG	1	normal study	normal study	
18	408304	10 yrs 6 months	M	SV-ASD, no PAH , GDBV	Wardens Repair	0	normal study	normal study	
19	456137	2 yrs	F	SV-ASD RUPV to SVC-RA Jn, mild PAH, GDBV	Wardens Repair	0	normal study	normal study	
20	415506	4yrs 7 month	M	large PM VSD, mod TR, sev PAH	PA Banding	1	normal study	Rt basal interstitial edema	
21	455095	3months	M	PM VSD, mod PAH, GDBV	VSD closure	0	Rt interstitial edema	Rt interstitial edema	diuretics given
22	457061	1 month 23 days	M	outflow Muscular VSD, sev PAH dilated LA/LV	VSD closure	1	Rt upper pnemothorax	Rt upper pnemothorax	suction given
23	412468	3yr 8months	M	TOF with spells, GD PA, rt arch	ICR	0	normal study	normal study	
24	366625	12yr 10months	M	TOF GDPA, Conf PA	ICR	1	Rt upper lobe consolidation	Rt upper lobe consolidation	
25	427589	2yrs	F	TOF GDPA, Conf PA	ICR	0	Rt upper lobe consolidation	Rt upper lobe consolidation	
26	430345	2yr 8m	M	SV-ASD, RUPV to SVC-RA Jn, no PAH	Wardens Repair	0	interstitial edema	interstitial edema	
27	433198	2yr 3m	F	SA-VSD mild PS, mild PAH, LA/LV overload	VSD closure	1	interstitial edema	interstitial edema, Lt basal minima	diuretics given
28	417020	7yr 1m	M	OSASD mild PAH	ASD closure	0	normal study	normal study	
29	389833	6yrs 5m	F	OSASD RA/Rv dilated	ASD closure	1	normal study	normal study	
30	455154	5 months	M	SA VSD, OS-ASD, sev PAH, mild PS	VSD closure	0	normal study	normal study	

30	428337	4yr 10m	M	SA-VSD, sev val PS, GDBV	ICR	1	normal study	Lt interstitial edema	diuretics given
						0	normal study	normal study	
31	377054	4yr 5m	M	Ebsteins Anomaly of TV, sev Tr, no PAH	Ebsteins repair	1	normal study	normal study	
						0	normal study	normal study	
						1	normal study	normal study	
32	444940	9m 18d	F	Comp Bal AVCD, Mod MR, Mod TR, Sev PAH AVCD repair		0	b/l interstitial edema	B/L interstitial edema + Lt minimal diuretics given	
						1	b/l interstitial edema	B/L interstitial edema + Lt minimal diuretics given	
33	329131	7yr 3m	M	SA-VSD mild AR, no PAH	VSD closure	0	normal study	normal study	
						1	normal study	normal study	
34	457770	3m	F	large PDA, aberrant Rt SCA OSASD, mild PAH	vascular ring division + PDA division	0	Rt interstitial edema	Rt interstitial edema	
						1	Rt Mz atelectasis + Lt interstitial ec	Rt Mz atelectasis + Lt interstitial ec lung	recruitment , diuretics given
35	454989	5yr 8m	M	PM VSD, sev AR, mild PAH, dilated LV, GDLV	VSD closure + AV repair	0	normal study	normal study	
						1	normal study	normal study	
36	457036	6m	F	mild post Lt SCA COA, large PDA, sev PAH, C COA	repair + PDA interruption	0	Rt UZ consolidation + Lt interstitial	Rt UZ atelectasis + Lt interstitial ed lung	recruitment , diuretics given
						1	normal study	normal study	
37	374379	5yr	M	SA VSD, OSASD, PDA, sev PAH	VSD closure	0	Rt interstitial edema	Rt interstitial edema	diuretics given
						1	normal study	normal study	
38	298015	15yr 4m	M	TOF, sev PS, GDLV, NC	ICR	0	normal study	normal study	
						1	normal study	normal study	
39	451531	9m	M	TOF, sev PS, LPA from PDA, S/p BPV, spells	ICR + LPA plasty	0	Lt basal consolidation	Lt basal atelectasis + Rt interstitial lung	recruitment , diuretics given
						1	normal study	normal study	
40	300006	16yr 5m	M	s/p BDG for TA, SV (LV)	Fontans Completion	0	normal study	normal study	
						1	normal study	normal study	
41	427883	5yr 2m	M	multiple ASD, Ra/rv dilated	ASD closure	0	normal study	normal study	
						1	normal study	normal study	
42	352221	6yr 3m	M	TOF Conf PA, Valvular PS	ICR	0	Rt interstitial edema + Rt pleural e	Rt interstitial edema + Rt pleural e	ICD placed
						1	normal study	normal study	
43	403067	11yr 5m	M	OS-ASD, Ra/rv dilated, no PAH	ASD closure	0	normal study	normal study	
						1	normal study	normal study	
44	458187	2yr 5m	M	ALCAPA sev LV dys, mod MR	LCA translocation	0	lt basal consolidation	lt basal atelectasis	lung recruitment
						1	lt basal consolidation	lt basal atelectasis	lung recruitment
45	399641	3yr 2m	M	TOF MAPCAS s/p Melbourne shunt, DiGeorge	REDO ICR	0	Rt basal consolidation	Rt basal atelectasis	lung recruitment
						1	Rt interstitial edema	Rt interstitial edema	diuretics added
46	416658	16yr 5m	F	TOF good PA, sev PS	ICR	0	normal study	normal study	
						1	elevated Rt hemidiaphragm	Rt interstitial edema	diuretics added
47	431699	1yr 8m	F	hypo TV, small RV, VSD, IAS aneurysmal	VSD closure	0	Lt interstitial edema	Lt interstitial edema	diuretics added
						1	normal study	normal study	
48	416621	2y 4m	F	p/PA band for DILV, mild AVVR, good SV Fn	BDG	0	normal study	Lt interstitial edema	diuretics added
						1	normal study	normal study	
49	445331	10m	F	Large SA-VSD, long seg PA, GDBV	ICR	0	interstitial edema	interstitial edema	diuretics added
						1	normal study	Lt basal atelectasis + mild Lt pleural	lung recruitment
50	402205	3yr 3m	F	DORV, inlet VSD, sev val PS, conf PA, Lt arch	Root Translocation	0	normal study	Rt minimal pleural effusion	
						1	normal study	normal study	
51	443840	4yr 10m	M	SV-ASD, RUPV to SVC RA Jn, mild PAH, GDBV	Wardens Repair	0	normal study	normal study	
						1	elevated Rt hemidiaphragm	normal study	
52	429740	2yr 1m	M	TOF conf PA, b/l SVC, coronary crossing RVC	ICR	0	normal study	normal study	
						1	interstitial edema	interstitial edema, Rt minimal pleu	diuretics added
53	433916	14yr 10m	M	SA-VSD, mid muscular VSD, sev PAH	VSD closure	0	interstitial edema	interstitial edema	
						1	interstitial edema , rt minimal pleu	interstitial edema , rt minimal pleu	diuretics added
54	378791	4yr 6m	M	SA-VSD, RCC prolapse, mod AR	VSD closure	0	normal study	normal study	
						1	normal study	normal study	
55	436756	9yr 1m	F	ACHD SPVSD RCC prolapse mild AR no PAH	VSD closure	0	normal study	normal study	
						1	normal study	normal study	
56	458940	3m	F	TGA IVS, PDA, retro pul LCx, pres LV, mod P	ASO	0	interstitial edema, Lt basal consoli	interstitial edema , Lt basal atelect lung	recruitment
						1	interstitial edema , Lt basal consoli	interstitial edema , Lt basal atelect lung	recruitment
57	405639	2yr 11m	M	Large SA-VSD, mod PS, mild AR	VSD closure + pul valvotomy	0	normal study	normal study	
						1	normal study	normal study	
58	399220	9yr 1m	F	OSASD , PDA sev PAH	ASD closure + PDA ligation	0	elevated Rt hemidiaphragm	Rt hemidiaphragm sluggish	

59	319897	9yr 9m	M	OP-ASD, cleft AML,mild MR, inlet VSD, Dow AVCD repair		1 0	normal study normal study	Rt basal atelectasis, Rt Hemidiaphragm lung recruitment b/l interstitial edema
60	447401	9y 3m	M	OS ASD mild TR GDLV SR ASD closure		1 0	normal study normal study	normal study normal study
61	343994	17yr 11m	F	s/p SAM excision, now with Re- LVOTO REDosternotomy+ Kono+ AVR		0 1	Lt interstitial edema normal study	Lt interstitial edema diuretics added Lt interstitial edema
62	423921	2y	M	DILV s/p PA banding BDG		0 1	Rt interstitial edema normal study	Rt interstitial edema diuretics added normal study
63	457164	7m	F	AP window AP window repair		0 1	Rt basal interstitial edema Rt basal consolidation	Rt basal interstitial edema diuretics added normal study
64	417875	2yr 3m	F	unbal AVCD SA-VSD, s/p pA banding, cleft A BDG + AV repair		0 1	Lt Upper consolidation Rt interstitial edema	Lt Upper atelectasis + Rt interstitial lung recruitment , diuretics Rt interstitial edema
65	445553	9m	F	TOF sev infund PS, good PA ICR		0 1	Lt basal consolidation + Lt minimal Lt minimal pleural effusion	Lt basal atelectasis + Lt minimal pleural lung recruitment Lt minimal pleural effusion
66	447858	9m	M	TOF PS good PA, no Add VSD ICR		0 1	normal study Rt interstitial edema	normal study Rt interstitial edema diuretics added
67	395487	4y 3m	F	SV-ASD mild PAH RUPV to SVC RA Jn Wardens Repair		0 1	B/l interstitial edema B/l interstitial edema	B/l interstitial edema B/l interstitial edema
68	454967	4m	M	SA-VSD sev PAH, GDLV VSD closure		0 1	normal study Rt interstitial edema	normal study Rt Mz atelectasis + Rt interstitial lung recruitment , diuretics
69	427919	1yr 8m	M	TOF with GD PA ICR		0 1	normal study normal study	normal study normal study
70	376764	14yr 7m	F	OS-ASD, ra/rv overload mild PAH, GDLV ASD closure		0 1	normal study normal study	normal study normal study
71	272375	11yr 4m	M	s/p ICR now with sev TR, LPA origin stenosis Redo+ TV repair+ LPA plasty+ PAF		0 1	rt interstitial edema normal study	normal study normal study
72	433484	1yr 4m	F	comp AVCD PA LPA origin stenosis BDG + LPA plasty		0 1	Rt interstitial edema normal study	Rt interstitial edema rt interstitial edema
73	295934	11y 4m	M	DORV SA-VSD, sev PAH, mod PR, LVOTO GD ICR		0 1	normal study Lt minimal pleural effusion	Lt minimal pleural effusion Lt minimal pleural effusion
74	389686	3yr 11m	M	DORV Sa-VSD val and infun PS, apical VSD, ICR		0 1	Rt interstitial edema normal study	Rt interstitial edema normal study
75	443458	6yr 10m	M	PM-VSD, sev inf PS, RCC prolapse, mild AR, ICR		0 1	normal study normal study	normal study normal study
76	436560	3y4m	M	TOF PS good PA, NC ICR		0 1	normal study normal study	normal study normal study
77	412199	5yr 4m	M	OS-ASD No PAH GDLV ASD closure		0 1	normal study normal study	normal study normal study
78	231011	14yr 2m	F	TOF s/p RVOT patch sev PS Redo Sx+ Rvoto resection+ Rvot p		0 1	normal study normal study	normal study normal study
79	384191	4yr 7m	F	Pink TOF Conf PA GDLV ICR		0 1	normal study normal study	normal study normal study
80	396077	10yr 2m	F	Os-ASD, No PAH, GDLV ASD closure		0 1	normal study Lt interstitial edema	normal study Lt interstitial edema diuretics added
81	446054	1yr 5m	M	SA-VSD long seg PA, PDA dep Pul circulation BDG + PA plasty		0 1	normal study Lt hemidiaphragm elevated	Lt interstitial edema Lt interstitial edema, Lt Diaphragm sluggish movement
82	341421	14yr 5m	F	SP-VSD, No PAH VSD closure		0 1	normal study normal study	normal study normal study
83	452886	7m	M	Comp Bal AVCD PDA PAH AVCD repair		0 1	normal study Lt basal consolidation and Rt inter	Lt basal atelectasis Lt basal atelectasis + Rt interstitial diuretics added, lung recruitment + PEEP
84	444280	1yr 2m	F	TOF mild LPA stenosis, GDLV ICR		0 1	Lt basal consolidation normal study	Lt basal atelectasis lung recruitment + PEEP normal study
85	446357	10m	F	DILV sev PS small PDA, conf PA, GDLV BDG		0 1	normal study normal study	normal study normal study
86	269620	11yr 4m	M	TA, SV(LV), TGA, SA-VSD, PS, S/p BDG mod ITCPC+MV repair		0 1	Lt basal consolidation Lt basal consolidation	Lt basal atelectasis lung recruitment + PEEP Lt basal atelectasis lung recruitment + PEEP
87	406041	15yr 3m	F	OS-ASD no PAH GDLV OS-ASD closure		0 1	normal study normal study	normal study normal study

88	378458	4yr 5m	F	DORV VSD sev PS Good PA	ICR+ PV valvotomy	1 0	normal study Rt interstitial edema	normal study Rt interstitial edema + Rt minimal p diuretics added
89	452719	6m 15d	M	SP-VSD sev PAH mild PS	VSD closure	1 0	normal study normal study	normal study Rt interstitial edema
90	377614	4yr 11m	F	TA DTGA s/p PA Banding	Redo Sx+BDG+ MPA interruption	1 0	Rt interstitial edema normal study	Rt interstitial edema, Rt minimal pi diuretics added Lt interstitial edema diuretics added
91	432657	2y	M	Partial AVCD sev MR no PAH	ICR	1 0	normal study B/L interstitial edema	normal study B/L interstitial edema diuretics added
92	439800	13yr 1m	F	SV-ASD RUPv to SVC-RA Jn, no PAH	Wardens Repair	1 0	B/L interstitial edema normal study	B/L interstitial edema normal study
93	445697	1yr 3m	M	DORV large SA-VSD mod PS sev PAH	VSD closure	1 0	normal study B/L interstitial edema	normal study B/L interstitial edema diuretics added
94	445121	9m	M	Long seg PA SA-VSD LPA origin stenosis, clef BDG+ LPA plasty		1 0	normal study Rt endobronchial intubation	normal study Rt endobronchial intubation, Rt int Et tube pulled out by 1 cms, diuretics added
95	319161	9y	M	SA-VSD mild AR RCC prolapse LSVC mild PAI VSD closure		1 0	normal study normal study	normal study normal study
96	412463	6yr 9m	F	SV-ASD RUPV to RA mild PAH GDLV	Wardens Repair	1 0	normal study normal study	mild pericardial effusion normal study
97	385990	4y 5m	M	s/p RMBTS for long Seg PA, SA-VSD, MAPCA ICR + conduit + MAPCAS ligation		1 0	normal study Lt interstitial edema	Rt interstitial edema Lt interstitial edema, Rt minimal pi diuretics added
98	245913	14yr	M	TOF conf PA, apical VSD, GDBV, SR	ICR	1 0	Lt interstitial edema normal study	Lt interstitial edema normal study
99	450068	5yr 11m	F	MVP of AML & PML sev MR mild TR GDLV	MV repair	1 0	normal study Lt interstitial edema	normal study Lt interstitial edema, Lt basal atele lung recuritment , diuretics
100	377513	4 yr 7m	M	TOF conf PA, small PDA, GDBV	ICR	1 0	normal study normal study	normal study Lt interstitial edema diuretics added
101	426382	2yr	M	TOF val PS GDLV SR	ICR	1 0	normal study normal study	normal study normal study
102	389063	8yr 1m	M	SA-VSD long seg PA LPA origin stenosis MAF ICR + conduit + unifocalisation		1 0	normal study normal study	normal study normal study
103	387641	6yr 8m	M	SV-ASD, RUPV to SVC-RA Jn mild PS	Wardens Repair	1 0	normal study normal study	normal study normal study
104	414820	9yr 1m	F	OS-ASD no PAH	ASD closure	1 0	normal study normal study	normal study normal study
105	444629	1yr	M	TOF sec sub val PS GDPA conal Br cross RVO ICR		1 0	normal study Lt upper consolidation	Rt interstitial edema diuretics added Lt upper atelectasis lung recuritment
106	390320	4yr 2m	M	TOF sub Pul PS GDPA conal br crossing RVO ICR		1 0	normal study normal study	normal study normal study
107	386265	4yr 5m	F	Multiple VSD sev PAH S/P PA band GDLV	VSD closure+ PA debanding	1 0	normal study Lt interstitial edema	normal study Lt interstitial edema diuretics added
108	441354	1yr 11m	F	TOF GDPA GDLV SR	ICR	1 0	Lt interstitial edema normal study	B/L interstitial edema B/L interstitial edema + Lt minimal diuretics
109	396749	6yr 2m	M	OS-ASD GDLV SR	ASD closure	1 0	B/L interstitial edema normal study	B/L interstitial edema + Lt minimal diuretics normal study
110	254257	14yr 4m	F	TA VSD PS ASD s/p BDG + Atrial Septectomy Redo + TCPC		1 0	normal study normal study	normal study normal study
111	426419	3yr 9m	F	OS-ASD mild PAH GDLV	OS-ASD closure	1 0	normal study normal study	Lt interstitial edema Rt interstitial edema
112	464580	11m	M	Long seg PA VSD Conf PA LPA origin stenosi ICR with conduit		1 0	Rt interstitial edema normal study	Rt interstitial edema normal study
113	384237	4yr 4m	M	CCHD MA hypo LV S/p PA banding Atrial seq Redo + BDG		1 0	B/L interstitial edema normal study	B/L interstitial edema normal study
114	439275	1yr 11m	F	ACHD PM VSD indirect Gerbode defect	VSD closure	1 0	Lt interstitial edema pneumopericardium	Lt interstitial edema + Lt basal atel lung recuritment , diuretics Rt upper atelectasis + Rt upper pne suction given
115	390614	10yr 11m	F	PM-VSD, no PAH, GDLV SR	VSD closure	1 0	normal study normal study	normal study Rt upper atelectasis + Lt minimal p lung recuritment , diuretics
116	454643	9m	M	DORV large SA-VSD sev PS GDPA	BDG	1 0	Rt pleural effusion Rt interstitial edema	Rt pleural effusion diuretics added Rt interstitial edema

117	440080	1yr 8m	M	SA-VSD no PAH GDLV SR	VSD closure	1 0	Rt interstitial edema normal study	Rt and Lt interstitial edema normal study	diuretics added
118	438635	9yr 3m	F	OS-ASD GDLV SR	ASD closure	1 0	normal study normal study	normal study normal study	
119	404535	3yr 2m	M	TOF GDPA GDLV s/p LMBTS	Redo ICR+ BTS take down	0 1	B/L interstitial edema normal study	B/L interstitial edema normal study	diuretics added
120	392390	3yr 11m	M	DILV Res ASD s/p PA Band GDPA GDLV	Redo + BDG	0 1	normal study normal study	normal study normal study	
121	353516	6yr 3m	M	CCHD SI DC Interrup IVC b/I SVC OS-ASD SV(Kawashima repair		0 1	normal study normal study	Rt basal atelectasis normal study	lung recruitment
122	387113	4yr 8m	M	TOF addl apical VSD GDPA RVH	ICR	0 1	normal study normal study	normal study normal study	
123	455124	9yr 2m	F	OS-ASD no PAH	ASD closure	0 1	normal study normal study	normal study normal study	
124	467826	3yr 11m	F	PM VSD sev PAH GDBV	VSD closure	0 1	Rt interstitial edema Rt interstitial edema	Rt interstitial edema Rt interstitial edema	diuretics added
125	270184	11yr 9m	M	CCHD TV PS SV(LV) S/p BDG	TCPC	0 1	normal study normal study	normal study normal study	
126	427450	7yr 1m	F	SV ASD GDLV SR	Wardens Repair	0 1	normal study normal study	normal study normal study	
127	439735	2yr	M	CCHD TOF Conf PA GDLV SR	ICR	0 1	normal study normal study	normal study normal study	
128	435324	2yr 6m	M	CCHD TOF Val + Supra Val PS	ICR	0 1	Rt interstitial edema normal study	Rt interstitial edema normal study	diuretics added
129	375771	5yr 5m	M	OS ASD SA VSD no PAH SR	ASD + VSD closure	0 1	normal study normal study	normal study normal study	
130	385369	6yr 9m	F	OSASD no PAH GDLV	ASD closure	0 1	normal study normal study	normal study normal study	
131	425266	4yr 9m	M	OSASD GDLV No PAH	ASD closure	0 1	normal study normal study	normal study normal study	
132	443322	10yr 4m	F	OSASD mild Pah GDLV	ASD closure	0 1	normal study normal study	normal study normal study	
133	427717	2yr 2m	M	CCHD TOF Conf PA Addl VSD Rt arch	ICR	0 1	Lt basal consolidation Lt basal consolidation + Rt Pneumc	Lt basa atelectasis+ Lt pleural effus Lt basal atelectasis+ Lt pleural effu	diuertics + recruitment diuertics + low suction
134	434852	1yr 9m	F	CCHD pink TOF Addl apical VSD GDPA	ICR	0 1	normal study normal study	normal study normal study	
135	449644	1yr 3m	M	SA VSD sev PAH SR	VSD closure	0 1	normal study normal study	normal study normal study	
136	393201	4yr 7m	F	DILV SV(LV) VSD PS PDA	BDG	0 1	normal study normal study	normal study normal study	
137	350594	6yr 7m	M	CCHD SV(RV) s/p BAS S/p PA banding	BDG	0 1	Rt Pneumothorax normal study	Rt Pneumothorax normal study	ICD placed
138	454663	10yr 8m	F	OSASD GDLV SR	ASD closure	0 1	normal study normal study	normal study normal study	
139	417037	3yr 1m	F	TOF Rt ARCH small MAPCAS	ICR	0 1	Rt interstitial edema normal study	Rt interstitial edema normal study	diuretics added
140	460616	3yr 1m	F	ACHD multiple VSD sev PAH	VSD closure	0 1	Rt interstitial edema Rt interstitial edema	Rt interstitial edema Rt interstitial edema	diuretics added
141	233809	14yr 7m	M	CCHD DILV Lt posed aorta s/p PA band + BD TCPC + PPI		0 1	normal study normal study	normal study normal study	
142	402804	7yr 6m	M	PM VSD RCC prolapse mild AR	VSD closure	0 1	normal study normal study	normal study normal study	
143	410762	10 yr 5m	F	OSASD mild PAH GDLV	ASD closure	0 1	normal study normal study	normal study normal study	
144	394468	7yr 9m	F	Sev MR, Flial AML, GDLV SR	MV repair	0 1	normal study normal study	normal study normal study	
145	429013	7yr 8m	F	OSASD no PAH GDLV	ASD closure	0 1	normal study normal study	normal study normal study	

146	371230	10yr 8m	F	OSASD GDLV SR	ASD closure	1	normal study	normal study	
						0	Rt lower zone congestion	Rt basal interstitial edema	diuretics added
147	378949	6yr 10m	F	CCHD PA VSD Conf PA LPA stenosis B/I SVC	ICR + conduit + LPA plasty	1	normal study	normal study	
						0	normal study	Lt interstitial edema	
148	453820	10m	M	PM VSD Sev PAH mild PS GDLV SR	VSD closure	1	normal study	normal study	
						0	Lt interstitial edema	B/L interstitial edema	
149	429359	4yr 4m	F	OSASD GDLV SR	ASD closure	1	B/L interstitial edema	B/L interstitial edema	
						0	normal study	normal study	
150	397387	10yr 6m	M	OSASD + val PS GDLV SR	ASD closure + pulmonary valvoto	1	normal study	normal study	
						0	normal study	normal study	
151	466191	6m	F	ACHD PM VSD Sev PAH GDLV	VSD closure	1	normal study	normal study	
						0	normal study	normal study	
152	419006	4yrs	M	ACHD SAVSD small ASD sev PAH	VSD closure	1	normal study	Rt interstitial edema	
						0	B/L interstitial edema + Lt lower lo	B/L interstitial edema + Lt lower lo	recruitment + diuretics added
153	465037	9m	F	CCHD comp AVCD mild AVVR sev PAH	AVCD repair	1	normal study	Rt interstitial edema	
						0	B/L interstitial edema	B/L interstitial edema	diuretics added
154	410568	3yr 8m	M	CCHD TOF sub val + val PS GDBV	ICR	1	normal study	Rt interstitial edema	
						0	normal study	normal study	
155	440483	9yr 7m	M	ACHD SV-ASD RUPV to SVC RA Jn b/I SVC	Wardens Repair	1	normal study	normal study	
						0	normal study	normal study	
156	448242	10yr 8m	F	CCHD complete AVCD AML cleft mod MR m AVCD repair		1	normal study	normal study	
						0	normal study	normal study	
157	456770	10yr 10m	F	ACHD OSASD GDLV SR	OS ASD closure	1	normal study	normal study	
						0	normal study	Rt interstitial edema	
158	459532	1yr 6m	F	ACHD PMVSD sev PAH	VSD closure	1	normal study	normal study	
						0	normal study	normal study	
159	454968	4yr	M	ACHD PM VSD RCC prolapse mild AR	VSD closure	1	normal study	normal study	
						0	normal study	normal study	
160	435664	3yr 10m	M	ACHD OS ASD RV overload	ASD closure	1	normal study	normal study	
						0	normal study	normal study	
						1	normal study	normal study	