

**PROSPECTIVE COMPARATIVE STUDY OF HEMODYNAMIC
PARAMETERS FOLLOWING EXCISION OF BRAIN
ARTERIOVENOUS MALFORMATIONS – A PILOT STUDY**



Submitted for PDF Cerebrovascular Surgery

By

Dr. MOHAMED AMJAD JAMALUDDIN

December 2020

Department of Neurosurgery

Sree Chitra Tirunal Institute for Medical Sciences & Technology

Thiruvananthapuram – 695011

**PROSPECTIVE COMPARATIVE STUDY OF HEMODYNAMIC
PARAMETERS FOLLOWING EXCISION OF BRAIN
ARTERIOVENOUS MALFORMATIONS – A PILOT STUDY**




Submitted by : Dr. MOHAMED AMJAD JAMALUDDIN

Programme : PDF Cerebrovascular Surgery

Month & year of submission : December 2020

CERTIFICATE

This is to certify that the thesis entitled “**PROSPECTIVE COMPARATIVE STUDY OF HEMODYNAMIC PARAMETERS FOLLOWING EXCISION OF BRAIN ARTERIOVENOUS MALFORMATIONS – A PILOT STUDY** ” is a bonafide work of Dr. Mohamed Amjad Jamaluddin, conducted in the Department of Neurosurgery, Sree Chitra Tirunal Institute for Medical Sciences & Technology, Thiruvananthapuram (SCTIMST) during the period from January 2020 to December 2020. This thesis is submitted to SCTIMST in partial fulfilment of rules and regulations of PDF Cerebrovascular Surgery programme.



Prof. Easwer HV

Professor And Head

Department of Neurosurgery

SCTIMST, Thiruvananthapuram

CERTIFICATE

This is to certify that the thesis entitled “**PROSPECTIVE COMPARATIVE STUDY OF HEMODYNAMIC PARAMETERS FOLLOWING EXCISION OF BRAIN ARTERIOVENOUS MALFORMATIONS – A PILOT STUDY** ” is a bonafide work of Dr. Mohamed Amjad Jamaluddin, conducted in the Department of Neurosurgery, Sree Chitra Tirunal Institute for Medical Sciences & Technology, Thiruvananthapuram (SCTIMST), under my guidance and supervision.



Prof. Mathew Abraham

Professor

Department of Neurosurgery
SCTIMST, Thiruvananthapuram

DECLARATION

This thesis titled **“PROSPECTIVE COMPARATIVE STUDY OF HEMODYNAMIC PARAMETERS FOLLOWING EXCISION OF BRAIN ARTERIOVENOUS MALFORMATIONS – A PILOT STUDY”** is a consolidated report based on a bonafide study of the period from January 2020 to December 2020, done by me under the Department of Neurosurgery, Sree Chitra Tirunal Institute for Medical Sciences & Technology, Thiruvananthapuram. This thesis is submitted to SCTIMST in partial fulfilment of rules and regulations of PDF Cerebrovascular Surgery programme.



Dr. Mohamed Amjad Jamaluddin,

Department of Neurosurgery,
SCTIMST, Thiruvananthapuram

ACKNOWLEDGEMENT

The guidance of Prof. Mathew Abraham, Professor of the Department of Neurosurgery, has been invaluable. I am extremely grateful and indebted for his contributions and suggestions, which were of invaluable help during the entire work. He will always be a constant source of inspiration to me.

I am grateful to Dr Santhosh Kumar K, Additional Professor in Imaging Sciences & Interventional Radiology for his valuable instruction and generous assistance, which helped in completion of this thesis.

I owe a deep sense of gratitude to Prof. Easwer HV, Professor and Head of Neurosurgery for his invaluable advice, encouragement and guidance, without which this work would not have been possible.

I am deeply indebted to Prof. Krishnakumar K, Dr George CV, Dr B Jayanand Sudhir, Dr Prakash Nair, Dr Tobin George, Dr Ganesh Divakar for the constant drive. Their critical remarks, suggestions, helped me in achieving a high standard of work.

I would like to thank the following persons for their significant contribution towards the realization of the study – Reshmi Chadyan and Surabhi Chandran, Neuropsychologists in Department of Neurosurgery (Neuropsychology Assessments), Dr Arun and Dr Vikas, Senior Residents in Department of Imaging Sciences & Interventional Radiology (Imaging Protocols & Radiologic Measurements)

I thank Jaypalsinh Gohil and all my juniors for being by my side all along. I thank my colleagues for their constant encouragement and support.

Finally, I appreciate my mother's, my wife Bismi's and my son Raahil's sacrifice, constant care and support which helped me in the accomplishment of this thesis.

TABLE OF CONTENTS

1. Introduction	1
2. Review of Literature.....	2
3. Aims and objectives	4
4. Materials and Methods	5
5. Results	8
6. Discussion	20
7. Limitations	27
8. Conclusion.....	28
9. References	29
10. Appendix	32
i. Data collection sheet	
ii. IEC approval letter	
iii. Plagiarism report	
iv. Informed consent	
v. Patient Information Sheet	

INTRODUCTION

Brain arteriovenous malformations (bAVMs) have many varied presentations. In addition, due to its high flow nature, it can place stress on the hemodynamic homeostasis of the entire cranial cavity by steal phenomenon. This can lead to significant neuropsychological disturbance distant from the location of the bAVMs. The study intends to look into the hemodynamic changes occurring in the different circulations inside the cranium before and after the excision of bAVMs.

The pathophysiology of bAVMs has ever eluded neuroscientists. Brain bAVMs are arteriovenous short-circuits which cause conundrums in the hemodynamics of the brain and thus also in its functioning. More than half of adults with bAVMs present with either intracerebral, intraventricular, or subarachnoid hemorrhages. The rest of them present with either seizures or neurological deficits or even can be incidental findings. The exact pathogenesis and the physiological alterations, leading to the varied presentations as well as the difficulties that manifest at the time of interventions, have been unmapped yet. The alterations in hemodynamics have been studied to understand the risk of rupture of bAVMs. Transit time seems to be shorter in those bAVMs presenting with seizures. Contrary to what was speculated earlier, hemodynamic studies have shown that venous outlet obstruction seems to be the most important risk factor for rupture of bAVMs. This has led to extensive research on the hemodynamics of bAVMs beyond the architecture of these vascular lesions.

REVIEW OF LITERATURE

As the bAVMs diverts blood supply from mainstream circulation, a significant steal phenomenon occurs which can lead to hypoperfusion and hypo-functioning of the normal cortical tissues. This has been supported by the alterations in the cognitive and neuropsychological disturbances associated with bAVMs. There is altered hemodynamics which can be studied in detail by a variety of newer modalities. A definite correlation between hypo-functioning and hemodynamic change has not been studied in detail. Once the bAVMs are excised, there is a normalization of the cerebral circulation, and a significant improvement in the neuropsychology is expected. As per scientific reasoning, a corresponding normalization of the hemodynamic change is also to be expected. A detailed study of the hemodynamic changes that occur after excision of bAVMs can help in understanding the factors favoring a better outcome viz-a-viz to the preoperative hemodynamic status. This can help in prognosticating as well as help in decision-making regarding the modality of treatment of bAVMs, in the future. The current Spetzler-Martin grade is a surrogate marker of the ease of surgical excision rather than the risk of rupture.

Any intervention for bAVMs management aims to eliminate the risk of bleed due to bAVMs while minimizing/ eliminating any neurological damage/ deficit to the patient. This can be done only if the architecture of such bAVMs is studied in detail.

Qualitative assessment of hemodynamics of bAVMs is now possible with recent imaging technology and software advances such as quantitative MRA, time-resolved spin-labelled MRA as well as DSA (1–3). Wall shear stress reflects the pressure of blood against the vessel wall endothelium, which might be the critical factor responsible for vessel remodeling. The latest MRA technology can mark the

changes in wall shear stress before and after intervention which can be used to understand the natural history of the high flow bAVMs (4,5).

Need for study

A variety of parameters have been described using 4D diagnostic subtraction angiogram such as mean transit time, Time to peak, bolus arrival time, full width at half maximum, trans-nidal time, peak density time, time to half-peak opacification, nidal volume, nidal flow, flow index, venous index, Feeding Artery / Internal Carotid Artery ratio, stasis index. Such indirect flow parameters differ between different grades of bAVMs as well as between unbled and bled bAVMs (2,3,6–10).

Practically, a combination of a few of the above parameters that can be derived from a 3D diagnostic angiogram can help in understanding the change in the hemodynamics status of the bAVMs. The change in hemodynamics can be made by comparing the parameters before and after surgery in vessels like the ipsilateral internal carotid artery, contralateral carotid artery, etc.

AIMS AND OBJECTIVES

Primary Objective

To study the change in hemodynamic parameters in patients undergoing excision of brain arteriovenous malformations

Secondary Objective

To correlate the change of hemodynamic parameters with

1. Neurological outcome
2. Neuropsychological change

MATERIALS AND METHODS

Study setting: The study was conducted in the Department of Neurosurgery, Sree Chitra Tirunal Institute for Medical Sciences and Technology, Thiruvananthapuram. The initial and immediate postoperative assessment was carried out in the neurosurgery ward while the follow-up assessments were carried out in the outpatient clinic customized with the scheduled outpatient visits of the patients. No additional cost burden was incurred by any of the patients.

Study duration: Recruitment to the study was done, after obtaining Institutional Ethics Committee (IEC), from August 2020 to November 2020.

Study design: A prospective observational single-center study

Study sample: The target study sample size was 10 consecutive patients who will undergo surgical resection of the arteriovenous malformations. At the end of the study, approximately 5 patients were recruited for the study.

Inclusion criteria:

1. Brain arteriovenous malformations
2. Age > 28 years
3. Cooperative for neuropsychology study
4. Undergoing in-hospital angiogram

Exclusion Criteria

1. Patients planned preoperatively for partial excision
2. Patients being operated on an emergency basis such as for hematoma evacuation or raised intracranial pressure
3. Not willing for surgery
4. DSA done outside
5. Non-cooperative for neuropsychology

Ethical clearance

Ethical clearance was obtained from the Institute Ethical Committee of Sree Chitra Tirunal Institute for Medical Sciences and Technology, Thiruvananthapuram as per order IEC/1549 dated 17.08.2020. The study was initiated only after obtaining ethical clearance.

Informed consent

Informed written consent was taken from all participants explaining the purpose of research, voluntary nature of participation, protection of confidentiality of the participants, right to withdraw from the study at any time, need for extra time during a follow-up visit for detailed clinical examination, and no additional cost burden shall be incurred upon the participants.

Preoperative Assessment

Once any patient was identified in the out-patient clinic to be a candidate suitable for surgical excision of bAVMs, he/ she was advised to undergo a diagnostic subtraction angiogram as per routine protocol. The clinical procedure to acquire angiogram data from a patient is to insert the catheter from the femoral artery after which the catheter is navigated slowly through the carotid arteries and the angiogram images are obtained in the Philips Allura cath lab machine. If the patient consents to surgery, the patient was counseled for inclusion into the study. Preoperative neuropsychological assessment was done using a standard set of neuropsychological batteries. The angiogram data were retrieved and further processed using Philips proprietary software.

Surgery

Patients underwent surgery according to the standard protocol for bAVMs like any patient would have outside the study.

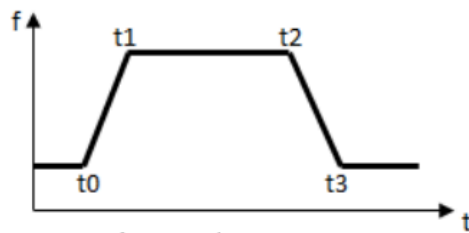
Postoperative assessment

Once any patient was discharged and allowed a healing time of a minimum of 1 month, the post-operative neuropsychological assessment was done using the same standard set of neuropsychological batteries used preoperatively. The postoperative angiogram data were retrieved and further processed using Philips proprietary software.

Angiogram Software Analysis

The Philips software was used to derive the following data from the angiogram by drawing the ROI curve as depicted below.

- Model fit to the time density curve:



- Time of Arrival = t_0
- Time to Peak = $t_1 + t_2$
- Wash-in rate: $\int_{t_1}^{t_2} (t_2 - t_1)f(t) dt - \int_{t_1}^{t_2} f(t) dt / (t_2 - t_1)(t_2 - t_0)$
- Width = $\frac{t_2 + t_3}{2} - (t_0 + t_1)/2$
- Area under Curve:

$$A = \int_{t_0}^{t_3} k(f(t) - f(0)) dt$$

Statistical Analysis

Descriptive Statistics were employed. No data analysis was done as the case numbers were very small and no pre and post-intervention could be done. No analysis shall be made to understand gender, ethnicity, class, race, or caste.

RESULTS

A total of 5 patients were recruited for the study. Of these patients, two underwent preoperative diagnostic subtraction angiogram as their diagnostic imaging suggestive of surgically amenable bAVMs. But after the DSAs, both patients opted out of the surgery and hence a postoperative DSA could not be done. Three patients who underwent surgery for bAVMs after August 2020 were recruited for the study and were included in the study. Their contralateral side was used as control but a meaningful analysis could not be done as the preoperative angiograms were not available as well as the number of cases was too small.

Case 1

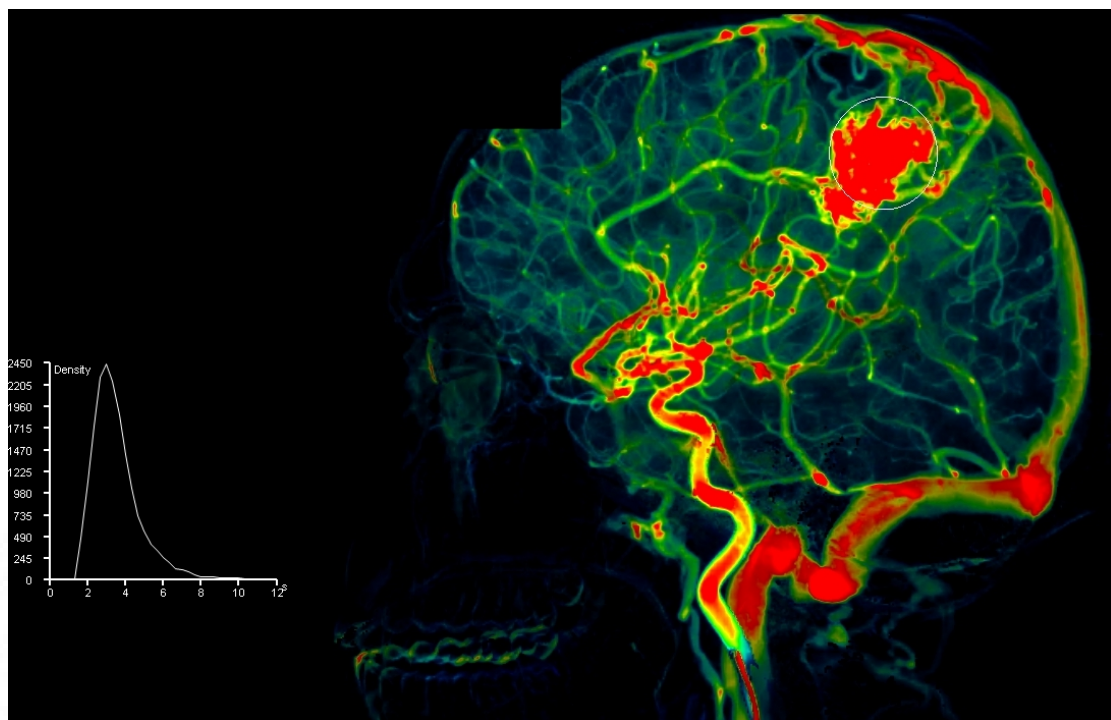
A 21-year-old old male who had sudden left-sided weakness and seizures in 2002 underwent right pterional craniotomy and partial excision of bAVM on 10th January 2003. He was kept on follow-up for the residual bAVM. On 11th September 2020, he developed sudden onset headache and vomiting for which he was managed conservatively and advised DSA. Angiogram revealed an bAVM of compact nidus measuring 23x21x27 mm in the right posterior frontal region. Arterial supply was noted from hypertrophied posterior parietal branches of the right pericallosal arteries and recurrent artery of Heubner from the right ICA through en-passage feeders. There was also a supply from the right ECA through the right superficial temporal artery. Drainage was noted to the Vein of Galen in addition to the SSS. No feeding artery aneurysm was noted.

The patient was offered various options including surgery, embolization as well as radiosurgery. The patient was not willing for surgery and opted for radiosurgery at a later date. The neuropsychological assessment could not be done as he was never admitted to the neurosurgical ward for any definitive surgery.

Pre-operative Hemodynamic Parameters

Area	Parameter	Right	Left
Frontal	Arrival Time	1.4	
	Time to Peak	2.2	
	Wash-in Rate	87	
	Width	3.3	
	Area under the curve	4657	
	Mean Transit Time	2.3	
Parietal	Arrival Time	1.7	
	Time to Peak	1.7	
	Wash-in Rate	500	
	Width	2.8	
	Area under the curve	16900	
	Mean Transit Time	1.8	
Temporal	Arrival Time	1.5	
	Time to Peak	2.0	
	Wash-in Rate	147	
	Width	3.6	
	Area under the curve	7088	
	Mean Transit Time	2.2	

Figure 1: Screenshot during the hemodynamic assessment showing ROI at the region of interest



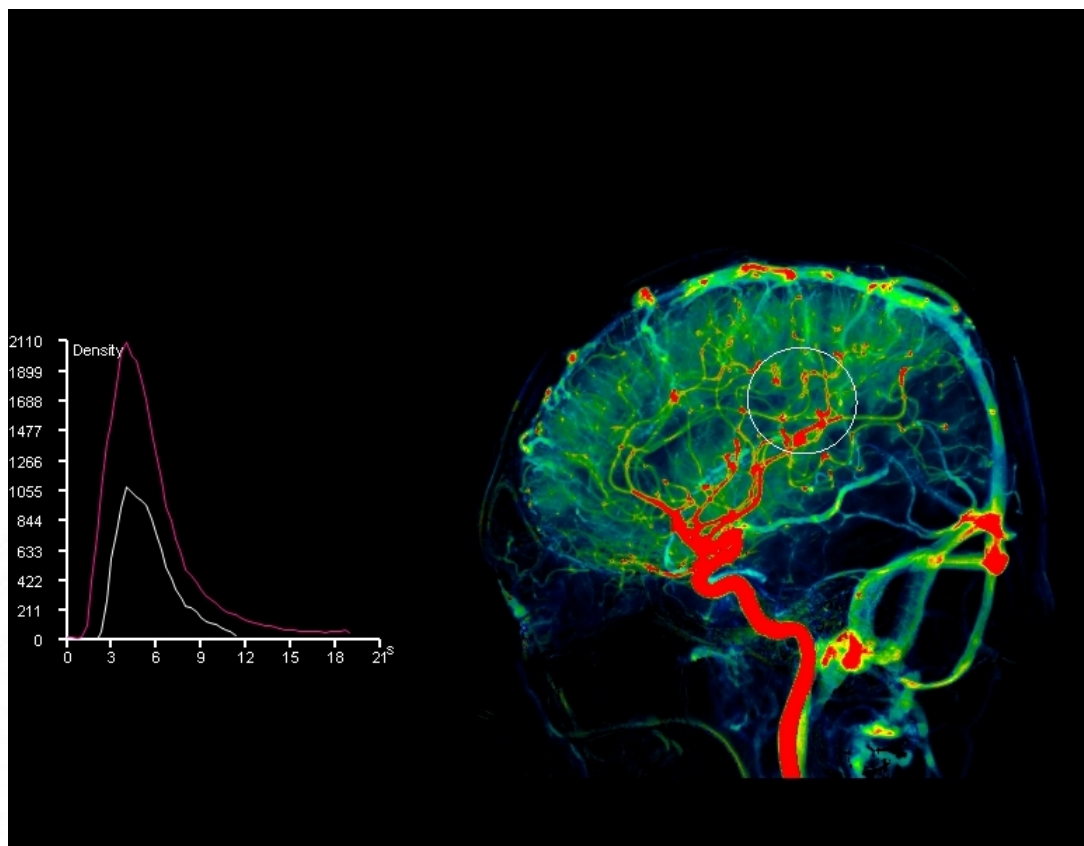
Case 2:

A 40-year-old male presented with a moderate intensity headache of 2 months duration. Neurological examination was unremarkable. MRI done outside revealed a left parietal bAVM measuring 8x28x10 mm. Angiogram done on 14th October 2020 showed a DVA with intense arterial phase stain medusa head pattern of the superficial medullary veins seen in the left inferior parietal lobule (supramarginal gyrus) on left ICA injection. The veins of DVA are draining into a large collector vein in a candelabra zone which is seen draining into left posterior parietal cortical vein that eventually drains into the left transverse sinus. The collector vein is seen opacified early in the arterial phase. Features were suggestive of DVA and hence surgery was deferred. The neuropsychological assessment could not be done as he was never admitted to the neurosurgical ward for any definitive surgery.

Pre-operative Hemodynamic Parameters

Area	Parameter	Right	Left
Frontal	Arrival Time	2.6	1.6
	Time to Peak	2.3	2.9
	Wash-in Rate	141	81
	Width	3.6	4.1
	Area under the curve	10449	8096
	Mean Transit Time	2.5	3.1
Parietal	Arrival Time	2.7	1.7
	Time to Peak	2.2	2.6
	Wash-in Rate	175	269
	Width	3.9	4.3
	Area under the curve	12376	28601
	Mean Transit Time	2.4	2.8
Temporal	Arrival Time	2.5	1.5
	Time to Peak	2.5	3.0
	Wash-in Rate	156	187
	Width	2.7	4.7
	Area under the curve	10902	21387
	Mean Transit Time	2.6	3.2

Figure 2: Screenshot during the hemodynamic assessment showing ROI at the region of interest



Case 3:

An 18-year-old male had multiple seizure episodes since the age of 10 years. His semiology consisted of paraesthesia involving the right upper and lower limbs which resolves spontaneously after 5 minutes. During a few episodes, he also had weakness of the right lower limb which impaired his gait. Workup done revealed a left postcentral gyrus bAVM with an as sparse nidus of size 30x18x11mm. Primary arterial feeders were from the posterior parietal branch of left MCA, superior and inferior parietal branches of left ACA. An intranidal aneurysm of 2.6x2.4mm was seen in the posteroinferior part. Drainage was noted to the SSS through a venous sac. Left parietal craniotomy and total excision of bAVM was done on 17th November

2020. Arterialized large cortical vein is seen along with multiple dilated cortical veins, below which bAVM was seen. Two feeding arteries to bAVM were seen running close to the cortical vein, which was closely separated and the branch supplying precentral gyrus was preserved. bAVM was dissected off surrounding parenchyma. bAVM had a poor plane with surrounding parenchyma and at places where hemosiderin staining was present had a good plane. bAVM was completely dissected off surrounding parenchyma and feeding vessels were clipped with veck clips. Postoperative Check DSA revealed no residual nidus.

Pre-operative Neuropsychological Assessment

Deficit scores in mental speed, and verbal learning and memory. All other scores fall within the normal range of functioning without any significant deviations. A low score in working memory and processing speed. The score for verbal comprehension and perceptual reasoning falls within the normal range of functioning without any significant deviation from the normative percentile scores. An IQ score of 79 indicates a borderline level of intelligence.

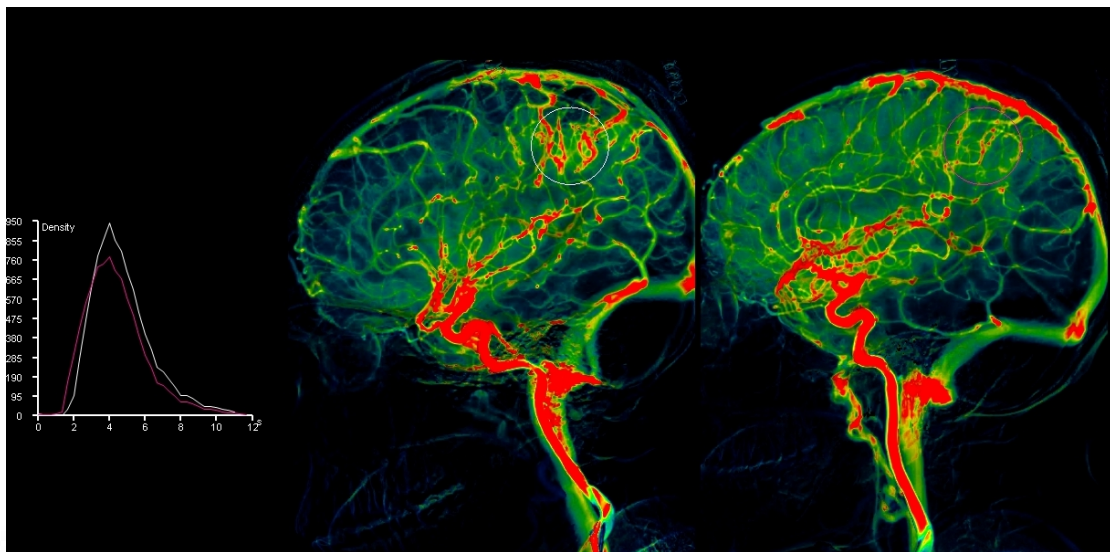
Post-operative Neuropsychological Assessment

Deficit scores in divided attention, visual working memory, mental speed, Visuo-constructive ability, and verbal learning and memory. All other scores fall within the normal range of functioning without any significant deviations. A low score in perceptual reasoning, working memory, and processing speed. The score for verbal comprehension falls within the normal range of functioning without any significant deviation from the normative percentile scores. An IQ score of 75 indicates a borderline level of intelligence.

Post-operative Hemodynamic Parameters

Area	Parameter	Right	Left
Frontal	Arrival Time	1.4	2.0
	Time to Peak	2.4	2.5
	Wash-in Rate	96	60
	Width	3.2	3.4
	Area under the curve	6784	4512
	Mean Transit Time	2.5	2.5
Parietal	Arrival Time	1.6	2.2
	Time to Peak	2.4	2.2
	Wash-in Rate	112	144
	Width	3.6	3.5
	Area under the curve	8150	9093
	Mean Transit Time	2.5	2.3
Temporal	Arrival Time	1.6	1.7
	Time to Peak	2.5	2.3
	Wash-in Rate	82	131
	Width	4.3	3.7
	Area under the curve	6488	7322
	Mean Transit Time	2.7	2.5

Figure 3: Screenshot during the hemodynamic assessment showing ROI at the region of interest in the ipsilateral and contralateral sides



Case 4:

A 20-year-old male presented with a history of sudden onset headache on 18th March 2020 associated with vomiting and weakness of left upper and lower limbs. Imaging revealed a right frontoparietal hematoma with few enlarged vessels. Angiogram on 17th July 2020 (done outside) showed a micro bAVM in the right middle frontal region measuring 8 x 5 x 6 mm (SM grade 2). Right Fronto Temporal Craniotomy and Excision of bAVM done on 11th November 2020. 2x2 cm cystic cavity filled with yellowish color fluid was found in the right frontal operculum. After exploring the frontal lobe in the opercular area, a sparse bAVM found with en passage feeding vessels from M3 branches was found. Feeding vessels were meticulously separated and cauterized. 2 major cortical veins draining veins and bAVM nidus were removed in-toto along with gliotic tissue of the frontal lobe.

Pre-operative Neuropsychological Assessment

Deficit scores in focused attention and visual scanning, verbal fluency, and verbal comprehension. All other scores fall within the normal range of functioning without any significant deviations. A low score in working memory and processing speed. All other scores fall within the normal range of functioning without any significant deviation from the normative percentile scores. An IQ score of 84 indicates a low average level of intelligence.

Post-operative Neuropsychological Assessment

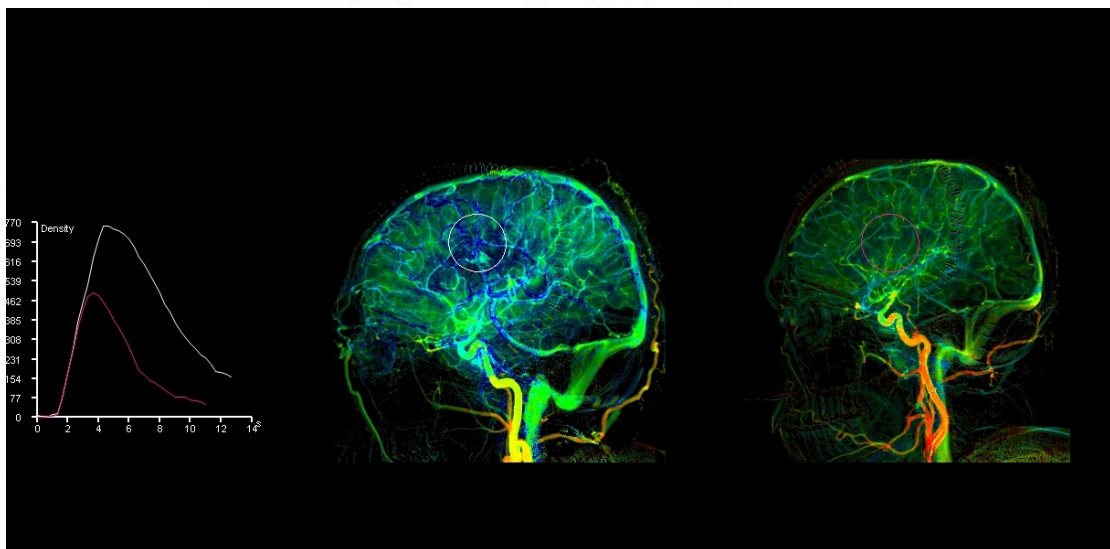
All the scores fall within the normal range of functioning without any significant deviations from the normative percentile scores. A low score in working memory. All other scores fall within the normal range of functioning without any significant deviation from the normative percentile scores. An IQ score of 94 indicates an average level of intelligence.

Post-operative Hemodynamic Parameters

Area	Parameter	Right	Left
Frontal	Arrival Time	1.7	1.6
	Time to Peak	3.8	2.6
	Wash-in Rate	75	68
	Width	5.3	4.1
	Area under the curve	13893	5953
	Mean Transit Time	4.4	2.9
Parietal	Arrival Time	1.9	2.0
	Time to Peak	3.5	2.7
	Wash-in Rate	102	62
	Width	4.5	3.9
	Area under the curve	15111	6159
	Mean Transit Time	3.8	3.0
Temporal	Arrival Time	1.5	2.0

	Time to Peak	3.5	3.2
	Wash-in Rate	126	54
	Width	4.9	3.9
	Area under the curve	17994	5003
	Mean Transit Time	3.9	3.4

Figure 4: Screenshot during the hemodynamic assessment showing ROI at the region of interest in the ipsilateral and contralateral sides



Case 5:

A 23-year-old female had presented on 28th September 2019 with vomiting, inability to talk, and facial deviation to the right. She was diagnosed with left frontal opercular bAVM with intraparenchymal bleed and underwent 17% glue embolization with complete obliteration of the deep part of the nidus on 7th November 2019. Before surgery, she was well preserved except for minimal dysphasia. She underwent left frontoparietal craniotomy and excision of the residual bAVM on 20th August 2020. Dilated arterialized vein with nidus seen in left premotor and motor area. The gliotic area due to the previous hemorrhage seen around the nidus. bAVM was supplied hypertrophied MCA M3 branches and draining into via cortical vein into SSS. bAVM

resected and arterial branches supplying bAVM coagulated. The post-operative angiogram showed normal outline and branching pattern of all major arteries including the ICA, ACA, MCA, PCA and vertebrobasilar system. No evidence of any steno-occlusive lesions or aneurysms/ ectasia seen. No abnormal blush or early draining veins seen.

Pre-operative Neuropsychological Assessment

Deficit scores in Visual N Back (2 back hits) test. Normal range of performance in all the other tests in NIMHANS neuropsychological battery without any significant deviation from the normative percentile scores. IQ score of 75 indicating a borderline level of intelligence. Performance in WAIS 4 shows low scores in processing speed, perceptual reasoning and working memory.

Post-operative Neuropsychological Assessment

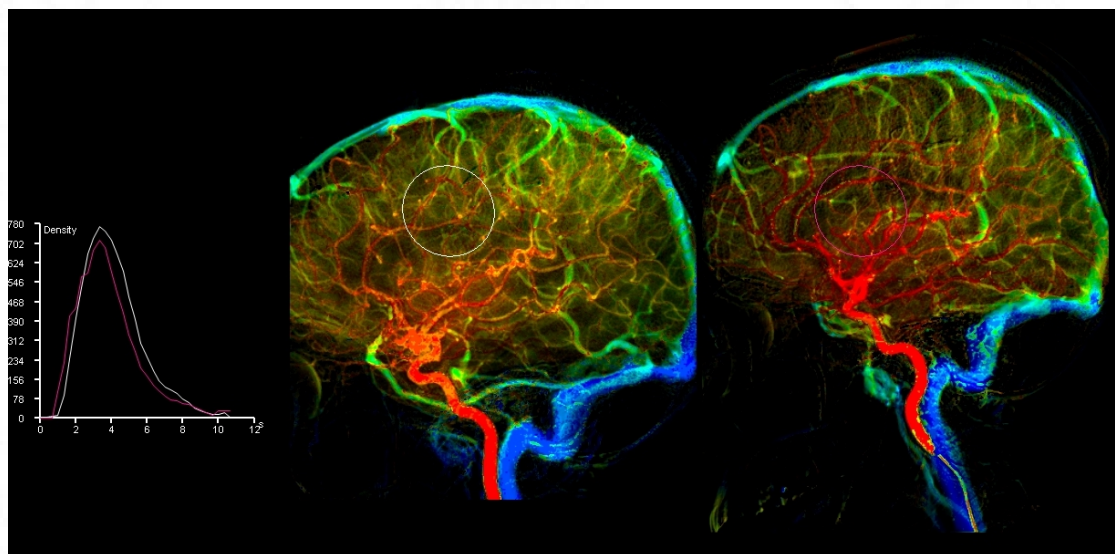
Deficient scores in Visual N Back and Digit vigilance test (errors) demonstrating difficulty in visual working memory and sustained attention. Significant improvement in memory of faces compared to the pre-surgery assessment. Normal range of performance in all the other tests compared to the normative percentile scores. An IQ score of 79 indicating a borderline level of Intelligence.

Post-operative Hemodynamic Parameters

Area	Parameter	Right	Left
Frontal	Arrival Time	1.3	1
	Time to Peak	2.6	2.6
	Wash-in Rate	103	91
	Width	3.8	3.5
	Area under the curve	8361	7308
	Mean Transit Time	2.7	2.8
Parietal	Arrival Time	1.5	1.3
	Time to Peak	2.5	2.9

	Wash-in Rate	136	97
	Width	3.6	3.9
	Area under the curve	10131	9496
	Mean Transit Time	2.6	3.0
Temporal	Arrival Time	1.1	0.9
	Time to Peak	2.5	2.7
	Wash-in Rate	138	115
	Width	3.8	3.8
	Area under the curve	10187	10165
	Mean Transit Time	2.7	2.9

Figure 5: Screenshot during the hemodynamic assessment showing ROI at the region of interest in the ipsilateral and contralateral sides



DISCUSSION

The annual rate of haemorrhage in bAVMs is approximated to be 2-4% (8,11,12). Each bleeding episode is estimated to have 10% mortality and 30-50% morbidity (7,11,13–15). This has prompted neurosurgeons to tackle bAVMs with different modalities of treatment – microsurgery, endovascular as well as radiosurgery(16). The alterations in hemodynamics have been studied to understand the risk of rupture of bAVMs. Transit time seems to be shorter in those bAVMs presenting with seizures. Contrary to what was speculated earlier, hemodynamic studies have shown that venous outlet obstruction seems to be the most important risk factor for rupture of bAVMs. This has led to extensive research on the hemodynamics of bAVMs beyond the architecture of these vascular lesions. The attitude towards unruptured bAVMs has been changing constantly as neuroscientists have found out more neuropsychological dysfunction that can be attributed to hemodynamic changes.

Because arteriovenous malformations are developmental, chronic lesions they have been able to provide unique information about the brain. Functional displacement simply because brain tissue located within the bAVM is non-functional. Brain reorganization was likely a function of the chronic bAVM lesion and suggested that there is a pre-existing language network that is malleable to change with structural reorganization due to chronic neuronal lesions(17).

As the bAVMs divert blood supply from mainstream circulation, a significant steal phenomenon occurs which can lead to hypoperfusion and hypo-functioning of the normal cortical tissues. This has been supported by the alterations in the cognitive and neuropsychological disturbances associated with bAVMs. Mahalick et al found out that bAVM confined to one region can alter the functions of the other ipsilateral areas as well as the contralateral hemisphere. This finding supports the hypothesis that

vascular steal causes the dysfunction of the contralateral hemisphere in addition to the ipsilateral one(18).

A characteristic and consistent feature of bAVM is the dilatation of the feeding arteries and draining veins. The feeding arteries gradually transition from normal to increasingly abnormal at the point of the fistula. The pathological abnormalities can be entirely explained by the physiological response to these fistulae. Following surgical resection of an bAVM, the dilated arteries and veins eventually return to normal or thrombose. However, limited studies are detailing the timing and nature of these changes(19).

Once the bAVMs are excised, there is a normalization of the cerebral circulation, and a significant improvement in the neuropsychology is expected. As per scientific reasoning, a corresponding normalization of the hemodynamic change is also to be expected. A detailed study of the hemodynamic changes that occur after excision of bAVMs can help in understanding the factors favoring a better outcome viz-a-viz to the preoperative hemodynamic status. This can help in prognosticating as well as help in decision-making regarding the modality of treatment of bAVMs, in the future.

Hemodynamic experiments have changed considerably after the digital era when faster computers have become cheaper and readily available. Experiments of cerebral hemodynamics using complex parameters and derivations were initially attempted in aneurysms as well as vasospasm as the measurements were relatively straightforward because they had only one causative vessel when compared to an bAVMs which has heterogenous intranidal flow in addition to the presence of multiple feeding arteries as well as draining veins(20–22). Tenjin et al were able to

prove that no difference exists in the flow dynamics of side-wall aneurysms and bifurcation aneurysms by hemodynamic studies(22).

Chen et al have found out that embolization therapy with Glubran has significantly increased the diastolic blood pressure, systolic blood pressure, mean arterial pressure, and pulsation index while decreasing the average blood flow velocity. This has led to improved hemodynamics of cerebral circulation. Shorter contrast means transit time (MTT) through the nidus, a lower ratio of time to peak draining vein/ feeding artery, and the presence of venous varices can suggest high flow through the bAVM nidus and point to a subset of unruptured bAVMs that have intralesional micro-hemorrhages which in the future could have bled (2,3).

Despite multiple studies, no consensus has been made on the relationship between draining vein pressure and the risk for hemorrhage (16). Specifically, the presence of intranidal or feeder artery aneurysms, which are thought to be angio-architectural surrogates of high bAVM inflow, can be predictive of hemorrhage. Besides, the presence of venous outflow obstruction as evidenced by venous stenosis, deep venous drainage, deep bAVM location, and a single draining vein, has been associated with increased hemorrhage risk.

The presence of a single draining vein or severe stenosis/ occlusion of the venous drainage has been proven to increase the risk of hemorrhage. Higher feeding artery intravascular pressure has also been noted in ruptured bAVMs when compared to unbled ones (1).

The mean transit time of feeding arteries was significantly shorter in ruptured bAVMs when compared to unruptured bAVMs while the difference between MTT of ruptured and unruptured bAVMs was not significant (todaka2003). This is in contrast to the suggestion made by Norris et al that those bAVMs where contrast took more

time to peak in the feeding vessel had more chance to bleed(15,16,23). The MTT of the feeding artery and the draining vein was significantly shorter in small bAVMs when compared to larger bAVMs but the difference in the vessel diameter not significant despite being narrower(16). If intravascular pressure is indeed directly proportional to flow velocity, pressure in the feeding artery and draining vessels will be higher in small bAVMs than in large bAVMs(16). Todaka et al also suggested that fast intranidal inflow, as well as high MTT ratio of Draining vein to feeding artery, are risk factors for hemorrhage in bAVMs(16).

Shakur et al were the first to evaluate the role of Pulsatility Index (PI) and resistance index (RI) in the feeding artery of bAVMs using QMRA. They found PI and RI to be significantly lower in bAVM proximal arterial feeders compared to normal contralateral vessels, subsequently resulting in significantly higher flow volume and flow velocities in feeding arteries. There was no significant association of PI or RI with hemorrhagic presentation, exclusive deep venous drainage, venous stenosis, single draining vein, or deep location(24).

QDSA hemodynamic analysis to calculate the ratio of inflow to outflow gradient and determined a stasis index to represent flow restriction in selected ROIs. The stasis index of the most prominent drainage vein was significantly associated with hemorrhagic presentation in bAVMs. The stasis index rose as the inflow gradient increased and the outflow gradient decreased. At the drainage vein, increased inflow gradient suggested increased venous inflow, and decreased outflow gradient indicated stagnant venous drainage(25).

Neuropsychological investigations of patients with bAVM have yielded mixed results concerning the localization of function, and most neurocognitive studies have not been able to demonstrate the kinds of impairment typically seen with acute focal

lesions in corresponding brain regions. Waltimo and Putkonen conducted one of the earliest studies of the cognitive sequelae of bAVMs by using well-validated measures. They found that the average intelligence quotient of patients with bAVMs did not differ from the normal population. Moreover, no differences were revealed on any of the neuropsychological instruments between individuals with left- or right-sided lesions. Even the association between previous hemorrhage and cognitive impairment did not reach statistical significance(26,27).

AVMs may manifest as a progressive loss of mental or neurological function from cerebral ischemia due to diversion of blood flow from the brain through the bAVMs. Neuropsychological correlation of the effects of this altered cerebral blood flow was demonstrated in the preoperative evaluations of the bAVMs patients. After surgical excision of the bAVM, statistically, significant improvements were documented on tasks involving short-term and long-term verbal memory, long-term visual-spatial memory, verbal learning, verbal intelligence, visual-perceptual intelligence, and overall intellectual functioning(28). The fact that especially high-grade lesions scored lower in their composite score implies that a steal phenomenon caused by the bAVM is in fact a whole-brain problem(29).

More than 71.4% of the patients demonstrated deficits in at least one of the eight neurocognitive domains. Patients with ruptured bAVMs showed deficits in more than one cognitive domain, including memory and verbal fluency(30). Preoperatively, some degree of cognitive impairment is common in patients harboring bAVMs, which in turn also depends on the patient's level of independence, occupation in addition to the characteristics of the bAVMs. The basis of impaired cognition may lie in the effects of hemorrhage compression of surrounding tissue, or chronic cerebral hypoperfusion(31). This produces both regional arterial hypotension and venous

hypertension resulting in chronic cerebral hypoperfusion. This may in turn be associated with altered neuronal structure and function and neurological or neuropsychological deterioration(31).

At early postoperative follow-up, there was a trend towards reduced scores in most areas of assessment. The exception was in the area of memory and learning in which scores tended to increase. These results confirm that in the short term (4–6 weeks post-operative) this group of patients showed a trend towards cognitive decline, although the magnitude was small. For each given neuropsychological variable, most patients did not show a significant change from pre-operative status at one month after surgery (31). However, for the proportion that did show a change, deterioration was more common than improvement. Patients can be warned that at 4–6 weeks following surgery they will not yet have improved maximally, and they should allow up to a full year for cognitive recovery (31). The cognitive decline that was present in most tests became insignificant at evaluation during the late follow-up period. This improvement can be attributed to the evacuation of hematoma, natural history in the recovery following hemorrhage as well as normalization of the cerebral hemodynamics resulting in the normalization of the cerebral perfusion (31).

Patients with larger bAVMs, higher grades as well as those which had ruptured had worse neuropsychological status than others (31). A study showed that the deterioration in occupational efficiency was more marked for patients with higher education and those in skilled professions. This significant change in the early follow-up was not found in the late follow-up period (31).

Future

Readily availability and frequent usage of diagnostic imaging have increased the incidence of incidentally detected bAVMs and the confusion of if,

when, and how to treat them (16). As decisions in many cases are being made empirically, it is essential to have objective criteria to guide the physician (16). Clinical decision making in the management of bAVMs, especially unbled ones, remains a matter of debate. Although the Spetzler-Martin grading system has already proved its usefulness, it does not take into account angioarchitectonic features that may put individual patients at disproportionate risk for neurological deficits from a hemorrhage (16). A detailed evaluation of the hemodynamic change after an intervention can help in arriving at a consensus towards the ideal modality of treatment (2,3). In cases where surgical resection is not feasible, hemodynamic studies, in the future, can help us predict the occurrence of bleed as well as complications, thereby guiding us when to stop embolization or perform further embolization. In cases undergoing preoperative embolization, hemodynamic studies can help determine the best plan for sufficient blood flow reduction (2,3). The pilot study needs to be continued in the future with the recruitment of more candidates to generate more meaningful analytical results, longer follow-up for allowing normalization of brain functions and healing in addition to a standardized procedure with a comparison between preoperative and postoperative angiograms.

LIMITATIONS

- Inability to determine the exact time of return to normal has led to the assumption of an empirical duration of follow-up of 3-6 months.
- Lack of proper control for comparison as the opposite hemispheric function and vessel architecture is completely different than the involved hemisphere and none of the patients could be compared in the pre and postoperative period due to the short time of the study
- The small volume of the patient precluded any detailed analysis which mainly needed to be subdivided based on the presentation with or without hemorrhage.
- A large number of bAVM patients are children who need general anesthesia and cannot be done in the Philips Allura interventional radiology suite
- AVM are elective cases are admitted according to the surgical waiting list
- One postoperative patient turned to be COVID-19 positive and could not be called for a postoperative angiogram and neuropsychological assessment
- The cardiology cath lab was closed multiple times because of the COVID-19 outbreak
- Given the COVID-19 pandemic and the associated lockdown, there was a significant delay in obtaining corrections in the Malayalam informed consent as well as the patient information sheet which delayed the TAC and IEC approval process.
- Neuropsychological assessments are prolonged with a good rapport needed between the examiner and the examinee essentiality of which is questionable in pandemic times

CONCLUSION

- The pilot study has been successful in defining the protocol needed for performing the perfusion-based angiogram and the methodology required to derive the parameters from the available raw data
- The pilot study needs to be continued in the future with
 - recruitment of more candidates
 - longer follow-up for allowing normalization of brain functions and healing
 - standardized procedure with a comparison between preoperative and postoperative angiograms

REFERENCES

1. Bendok BR, El Tecle NE, El Ahmadih TY, Koht A, Gallagher TA, Carroll TJ, et al. Advances and Innovations in Brain Arteriovenous Malformation Surgery. *Neurosurgery*. 2014 Feb 1;74(suppl_1):S60–73.
2. Chen Q-Y, Zhu X-R, Zhang Y. The Hemodynamic Changes in Patients with Cerebral Arteriovenous Malformations before and after Interventional Embolization Therapy with Glubran 2 Acrylic Glue. *Eur Neurol*. 2017;78(3–4):169–75.
3. Chen X, Cooke DL, Saloner D, Nelson J, Su H, Lawton MT, et al. Higher Flow Is Present in Unruptured Arteriovenous Malformations With Silent Intralesional Microhemorrhages. *Stroke*. 2017 Oct;48(10):2881–4.
4. Alaraj A, Shakur SF, Amin-Hanjani S, Mostafa H, Khan S, Aletich VA, et al. Changes in Wall Shear Stress of Cerebral Arteriovenous Malformation Feeder Arteries After Embolization and Surgery. *Stroke*. 2015 May 1;46(5):1216–20.
5. Alaraj A, Amin-Hanjani S, Shakur SF, Aletich VA, Ivanov A, Carlson AP, et al. Quantitative Assessment of Changes in Cerebral Arteriovenous Malformation Hemodynamics After Embolization. *Stroke*. 2015 Apr;46(4):942–7.
6. Kumar YK, Mehta SB, Ramachandra M. Computer simulation of Cerebral Arteriovenous Malformation—validation analysis of hemodynamics parameters. *PeerJ*. 2016 Jan 26;5:e2724.
7. Kaminaga T, Hayashida K, Iwama T, Nishimura T. HEMODYNAMIC CHANGES AROUND CEREBRAL ARTERIOVENOUS MALFORMATION BEFORE AND AFTER EMBOLIZATION MEASURED WITH PET. 2019;6.
8. Jo K-I, Kim J-S, Hong S-C, Lee J-I. Hemodynamic Changes in Arteriovenous Malformations After Radiosurgery: Transcranial Doppler Evaluation. *World Neurosurg*. 2012 Feb;77(2):316–21.
9. Donzelli GF, Nelson J, McCoy D, McCulloch CE, Hetts SW, Amans MR, et al. The effect of preoperative embolization and flow dynamics on resection of brain arteriovenous malformations. *J Neurosurg*. 2019 May;1–9.
10. Busch KJ, Kiat H, Stephen M, Simons M, Avolio A, Morgan MK. Cerebral hemodynamics and the role of transcranial Doppler applications in the assessment and management of cerebral arteriovenous malformations. *J Clin Neurosci*. 2016 Aug;30:24–30.
11. Ondra SL, Troupp H, George ED, Schwab K. The natural history of symptomatic arteriovenous malformations of the brain: a 24-year follow-up assessment. *J Neurosurg*. 1990 Sep 1;73(3):387–91.
12. Norris JS, Valiante TA, Wallace MC, Willinsky RA, Montanera WJ, terBrugge KG, et al. A simple relationship between radiological arteriovenous

- malformation hemodynamics and clinical presentation: a prospective, blinded analysis of 31 cases. *J Neurosurg.* 1999 Apr 1;90(4):673–9.
13. Wilkins RH. Natural History of Intracranial Vascular Malformations: A Review. *Neurosurgery.* 1985 Mar 1;16(3):421–30.
 14. Spetzler RF, Hargraves RW, McCormick PW, Zabramski JM, Flom RA, Zimmerman RS. Relationship of perfusion pressure and size to risk of hemorrhage from arteriovenous malformations. *J Neurosurg.* 1992 Jun 1;76(6):918–23.
 15. Norris JS, Valiante TA, Wallace MC, Willinsky RA, Montanera WJ, terBrugge KG, et al. A simple relationship between radiological arteriovenous malformation hemodynamics and clinical presentation: a prospective, blinded analysis of 31 cases. *J Neurosurg.* 1999 Apr;90(4):673–9.
 16. Todaka T, Hamada J, Kai Y, Morioka M, Ushio Y. Analysis of Mean Transit Time of Contrast Medium in Ruptured and Unruptured Arteriovenous Malformations: A Digital Subtraction Angiographic Study. *Stroke.* 2003 Oct;34(10):2410–4.
 17. Lantz ER, Meyers PM. Neuropsychological Effects of Brain Arteriovenous Malformations. *Neuropsychol Rev.* 2008 Jun;18(2):167–77.
 18. Mahalick DM, Ruff RM, Hoi SU. Neuropsychological Sequelae of Arteriovenous Malformations. *Neurosurgery.* 1991 Sep 1;29(3):351–7.
 19. Morgan MK, Guilfoyle M, Kirollos R, Heller GZ. Remodeling of the Feeding Arterial System After Surgery for Resection of Brain Arteriovenous Malformations: An Observational Study. *Neurosurgery.* 2019 Jan 1;84(1):84–94.
 20. Illies T, Forkert ND, Saering D, Wenzel K, Ries T, Regelsberger J, et al. Persistent Hemodynamic Changes in Ruptured Brain Arteriovenous Malformations. *Stroke.* 2012 Nov;43(11):2910–5.
 21. Ivanov A, Linninger A, Hsu C-Y, Amin-Hanjani S, Aletich VA, Charbel FT, et al. Correlation between angiographic transit times and neurological status on admission in patients with aneurysmal subarachnoid hemorrhage. *J Neurosurg.* 2016 Apr;124(4):1093–9.
 22. Tenjin H, Asakura F, Nakahara Y, Matsumoto K, Matsuo T, Urano F, et al. Evaluation of Intraaneurysmal Blood Velocity by Time-Density Curve Analysis and Digital Subtraction Angiography. 1998;5.
 23. Matsumoto K, Urano M, Hirai M, Masaki H, Tenjin H, Mineura K. Haemodynamic evaluation of cerebral arteriovenous malformations by quantification of transit time using high speed digital subtraction angiography: basic considerations. *J Clin Neurosci.* 2000 Sep;7:39–41.
 24. Shakur SF, Amin-Hanjani S, Mostafa H, Aletich VA, Charbel FT, Alaraj A. Relationship of pulsatility and resistance indices to cerebral arteriovenous

- malformation angioarchitectural features and hemorrhage. *J Clin Neurosci*. 2016 Nov;33:119–23.
25. Lin TM, Yang HC, Lee CC, Wu HM, Hu YS, Luo CB, et al. Stasis index from hemodynamic analysis using quantitative DSA correlates with hemorrhage of supratentorial arteriovenous malformation: a cross-sectional study. *J Neurosurg*. 2019 Apr;1–9.
 26. Waltimo O, Putkonen AR. Intellectual performance of patients with intracranial arteriovenous malformations. *Brain J Neurol*. 1974 Sep;97(3):511–20.
 27. Lazar RM. Neuropsychological function and brain arteriovenous malformations: redefining eloquence as a risk for treatment. *Neurosurg Focus*. 2001 Nov;11(5):1–4.
 28. Mahalick DM, Ruff RM, Heary RF, U HS. Preoperative Versus Postoperative Neuropsychological Sequelae of Arteriovenous Malformations. *Neurosurgery*. 1993 Oct 1;33(4):563–71.
 29. Bradac O, Pulkrabkova A, Lacy P de, Benes V. Neuropsychological Performance after Brain Arteriovenous Malformations Treatment. *J Neurol Surg Part Cent Eur Neurosurg*. 2017 Jul;78(4):321–8.
 30. de Souza Coelho D, Fernandes de Oliveira Santos B, Silva da Costa MD, Silva GS, Cavalheiro S, Santos FH, et al. Cognitive performance in patients with cerebral arteriovenous malformation. *J Neurosurg*. 2020 May;132(5):1548–55.
 31. Marshall GA, Jonker BP, Morgan MK, Taylor AJ. Prospective study of neuropsychological and psychosocial outcome following surgical excision of intracerebral arteriovenous malformations. *J Clin Neurosci*. 2003 Jan 1;10(1):42–7.

QUESTIONNAIRE

Sree Chitra Tirunal Institute for Medical Sciences & Technology

Proforma

"PROSPECTIVE COMPARATIVE STUDY OF HEMODYNAMIC PARAMETERS FOLLOWING EXCISION OF BRAIN ARTERIOVENOUS MALFORMATIONS – A PILOT STUDY"

A. GENERAL INFORMATION

Anonymized Patient ID:

Age, sex, family history

B. CLINICAL DETAILS

H/o Bleed: Yes/ No

 If Yes, Time since bleed:

Spetzler-Martin grading

Presentation - Headache, haemorrhage, seizure, neuro-deficit

Intra-parenchymal/ intra-ventricular bleed:

Hydrocephalus:

Radiological Findings:

Neuropsychology.

1. Wechsler's memory scale.

2. Wisconsin card sorting test.

3. Wechsler's adult intelligence score.

4. Trail making test.

5. Tests for disconnection: tactile naming, tactile lecture, constructional tests, tachioscopic naming, Dichotic listening test.

C. PREOPERATIVE ANGIOGRAM FINDINGS

Mean transit time

Time to peak

Bolus arrival time

Full width at half maximum

Trans-nidal time

Peak density time
Time to half-peak opacification
Nidal volume
Nidal flow
Flow index
Venous index
A-Vt
A-Vt index
FA/ICA ratio
Cmax/ROI
Stasis index

D. INTRAOPERATIVE EVENTS

Associated anomaly- Aneurysm, Cavernoma:

Elective AVM excision; Emergency AVM Excision/hematoma evacuation; AVM excision following failed embolization/staged Rx:

E. POST-OPERATIVE EVENTS

Duration of the ventilator support:
Duration of ICU stay:
Duration of post-op hospital stay:
GCS on POD 5
Cranial nerve deficit
Neurological deficit
Aphasia
Hemianopia
Wound infection

F. STATUS ON DISCHARGE

GCS

Motor and speech status

Any other deficit

Neuropsychology.

1. Wechsler's memory scale.
2. Wisconsin card sorting test.
3. Wechsler's adult intelligence score.
4. Trail making test.
5. Tests for disconnection: tactile naming, tactile lecture, constructional tests, tachioscopic naming, Dichotic listening test.

G. STATUS ON FOLLOW UP ON 3 MONTHS

GCS

Motor and speech status

Any other deficit

mRs score

Neuropsychology.

1. Wechsler's memory scale.
2. Wisconsin card sorting test.
3. Wechsler's adult intelligence score.
4. Trail making test.
5. Tests for disconnection: tactile naming, tactile lecture, constructional tests, tachioscopic naming, Dichotic listening test.

H. FOLLOWUP ANGIOGRAM FINDINGS (all modified for excised

AVM)

modified Mean transit time

modified Trans-nidal time

modified Flow index

modified Venous index

modified A-Vt

modified A-Vt index

modified FA/ICA ratio

modified C_{max}/ROI

modified Stasis index

IEC APPROVAL



**SREE CHITRA TIRUNAL INSTITUTE FOR MEDICAL SCIENCES & TECHNOLOGY
THIRUVANANTHAPURAM—695 011, INDIA.**

(An Institute of National Importance under Govt.of India)

Phone—(91)0471—2443152 Fax—(91)0471—2446433, 2550728, Grams—Chitramet
email : sct@sctimst.ac.in Web site—www.sctimst.ac.in

CONFIDENTIAL



**SREE CHITRA TIRUNAL INSTITUTE FOR MEDICAL
SCIENCES AND TECHNOLOGY, TRIVANDRUM
THIRUVANANTHAPURAM-695011.**

**INSTITUTIONAL ETHICS COMMITTEE (IEC) MEETING
(IEC Regn No. ECR/189/Inst/KL/2013/RR-16)**

SCT/IEC/1549 /AUGUST-2020

17.08.2020

Dr. Mohamed Amjad Jamaluddin
Postdoctoral Fellow
Department Of Neurosurgery
SCTIMST, Thiruvananthapuram

Dear Dr. Mohamed Amjad Jamaluddin,

The Institutional Ethics Committee reviewed and discussed your application to conduct the study entitled "**PROSPECTIVE COMPARATIVE STUDY OF HEMODYNAMIC PARAMETERS FOLLOWING EXCISION OF BRAIN ARTERIOVENOUS MALFORMATIONS –A PILOT STUDY (IEC/ 1549)**" on July 10-17, 2020.

The following documents were reviewed:

Original documents

1. Covering Letter addressed to the Chairman, IEC, SCTIMST dated 26.06.2020	10. CV of Dr. Mohamed Amjad Jamaluddin,
2. TAC Approval Letter	11. CV of Dr. Mathew Abraham
3. IEC Application Form	12. CV of Dr. Easwer HV
4. Project Proposal	13. CV of Dr. Santhosh Kumar K
5. Proforma	14. CV of Dr. Jaypalsinh Asoksinh Gohil
6. Patient Information Sheet in English	15. CV of Dr. Immaneul Thomas without TCMC registration number
7. Patient Information Sheet in Malayalam	16. Declaration Form
8. Informed Consent Form in English	17. Covering letter addressed to the Director, SCTIMST from Dr. Mohamed Amjad Jamaluddin
9. Informed Consent Form in Malayalam	18. An email request from Dr. Immaneul Thomas

Revised documents

<ol style="list-style-type: none"> 1. Revised IEC Checklist 2. Covering letter addressed to the Chairman, IEC, SCTIMST dated 6th August 2020 3. Revised proposal (with title changes) 4. Revised IEC Application form with signatures from PI and all Co-PIs (except Dr.Immanuel Thomas-whose email consent is attached) 5. Declaration form signed by PI and all Co-PIs (except Dr.Immanuel Thomas whose email consent is attached) 6. Forwarding letter from HOD, dated June 26 2020 7. Proforma 8. TAC-Clinical studies Clearance with comments and responses 9. Revised Patient information sheet in English 10. Revised Patient information sheet in Malayalam 	<ol style="list-style-type: none"> 11. Consent form in English 12. Consent form in Malayalam 13. CV of PI Dr. Mohamed Amjad Jamaluddin, with TCMC Registration 14. CV of Co-PI Dr. Mathew Abraham with TCMC Registration 15. CV of Co-PI Dr. Easwer HV with TCMC Registration 16. CV of Co-PI Dr. Santhosh Kumar K with TCMC Registration 17. CV of Co-PI Dr. Jaypalsinh Asoksinh Gohil with Gujarat Medical Council Registration 18. CV of Dr. Immanuel Thomas without TCMC registration number (PhD) 19. Approval from Director, SCTIMST dated June 22 2020 to include Dr.Immanuel Thomas as part of study team
---	--

The following members of the Ethics Committee were present at the meeting held on July 10-17, 2020 at the offices and residences of the members

SL. No.	Member Name	Highest Degree	Gender	Scientific /Non Scientific	Affiliation with Institution(s)
1.	Dr. R V G Menon	M Tech, PhD	Male	Lay Person (Chairman)	No
2.	Dr. Rema M. N	MD	Female	Basic Medical Scientist	No
3.	Dr. Kala Kesavan. P	MBBS, MD	Female	Basic Medical Scientist	No
4.	Smt. Sathi Nair	MA (English Literature)	Female	Lay Person	No
5.	Dr. Christina George	MD Psychiatry	Female	Clinician	No
6.	Dr. Harikrishnan S	MD, DM (Cardiology) DNB (Cardiology)	Male	Clinician	Yes
7.	Dr. Mala Ramanathan	PhD	Female	Social Scientist (Member Secretary)	Yes

IEC Decision

The IEC approved the conduct of the study in the present form.

Remarks:

The Institutional Ethics Committee expects to be informed about the progress of the study, any SAE occurring in the course of the study, any changes in the protocol and patient information/informed consent and asks to be provided a copy of the final report.

There was no member of the study team who participated in voting / decision making process. The ethics committee is organized and operated according to the requirements of Good Clinical Practice and the requirements of the Indian Council of Medical Research (ICMR).

Sincerely,



Mala Ramanathan
Member Secretary, IEC



Plagiarism Checker X Originality Report
Similarity Found: 6%

Date: Sunday, December 13, 2020

Statistics: 327 words Plagiarized / 5237 Total words

Remarks: Low Plagiarism Detected - Your Document needs Selective Improvement.

The annual rate of haemorrhage in bAVMs is approximated to be 2-4% (8,11,12). Each bleeding episode is estimated to have 10% mortality and 30-50% morbidity (7,11,13–15). This has prompted neurosurgeons to tackle bAVMs with different modalities of treatment – microsurgery, endovascular as well as radiosurgery(16). The alterations in hemodynamics have been studied to understand the risk of rupture of bAVMs. Transit time seems to be shorter in those bAVMs presenting with seizures. Contrary to what was speculated earlier, hemodynamic studies have shown that venous outlet obstruction seems to be the most important risk factor for rupture of bAVMs. This has led to extensive research on the hemodynamics of bAVMs beyond the architecture of these vascular lesions. The attitude towards unruptured bAVMs has been changing constantly as neuroscientists have found out more neuropsychological dysfunction that can be attributed to hemodynamic changes.

Because arteriovenous malformations are developmental, chronic lesions they have been able to provide unique information about the brain. Functional displacement simply because brain tissue located within the bAVM is non-functional. Brain reorganization was likely a function of the chronic bAVM lesion and suggested that there is a pre-existing language network that is malleable to change with structural reorganization due to chronic neuronal lesions(17). As the bAVMs divert blood supply from mainstream circulation, a significant steal phenomenon occurs which can lead to hypoperfusion and hypo-functioning of the normal cortical tissues. This has been supported by the alterations in the cognitive and neuropsychological disturbances associated with bAVMs. Mahalick et al found out that bAVM confined to one region can alter the functions of the other ipsilateral areas as well as the contralateral hemisphere. This finding supports the hypothesis that

INFORMED CONSENT

Code Number: _____ Participant's name: _____

Age: _____

I, Mr. / Mrs. / Miss. _____ is suffering from brain arteriovenous malformation which has been planned for excision after verifying and discussing the data obtained from my clinical history, examination & imaging. I have also expressed my willingness for surgical management of my disease condition.

What if I consent for the trial?

I will undergo the surgery for brain arteriovenous malformation as planned. An angiogram has already been obtained as a part of my preoperative workup which shall be processed as mentioned in PIS. The doppler shall be performed prior to surgery as well as a similar angiogram and trans-cranial doppler will be repeated at 3-6 months post-operative at a convenient time as part of your routine out-patient follow-up which shall be processed for research in this study. In addition, neuropsychological testing shall be done prior to and 3-6 months after surgery. This study is being conducted to understand the correlation between the change in hemodynamics and neuropsychology that occurs due to surgical excision. If I have any further questions, I know that I am free to ask **Dr. Mohamed Amjad Jamaluddin, Department of Neurosurgery, SCTIMST (Ph: 04712524647, Email: amjad96@sctimst.ac.in)**. I can also contact a study independent contact person **Dr. Mala Ramanathan, Member Secretary, IEC, SCTIMST (Email iec.mem.sec@sctimst.ac.in , Ph No: 0471-2524234)**

What if I do not consent for the trial?

If I do not consent for this trial, I will undergo surgery as usual. There will be no change in the timing of surgery nor in the plan of surgery as well as the routine follow-up protocol I was supposed to undergo.

I _____, _____ of _____
declare that

I have read the above information provide to me regarding^[1]the study: **“PROSPECTIVE COMPARATIVE STUDY OF HEMODYNAMIC PARAMETERS FOLLOWING EXCISION OF BRAIN ARTERIOVENOUS MALFORMATIONS”** and have clarified any doubts that I had.

I also understand that my participation in this study is entirely voluntary. I am free to withdraw permission to participate at any time without affecting my usual treatment/ legal rights

I understand that the study staff and institutional ethics committee members will not need my permission to look at my health records even if I withdraw from the trial. I agree for this access

I understand that my identity will not be revealed in any information released to third parties or published

I voluntarily agree to take part in this study

Patient's name

Witness

Date

I attest that the requirements for informed consent for the medical research project described in this form have been satisfied. I have discussed the research project with the participant and explained to him/ her in nontechnical terms all of the information contained in this informed consent, including any risks and adverse reactions that may reasonably be expected. I further certify that I encouraged the participant to ask questions and that all questions asked were answered.

Name and Signature of Person Obtaining Consent

PATIENT INFORMATION SHEET

"PROSPECTIVE COMPARATIVE STUDY OF HEMODYNAMIC PARAMETERS FOLLOWING EXCISION OF BRAIN ARTERIOVENOUS MALFORMATIONS"

Principal Investigator:
Name: Mohamed Amjad Jamaluddin (Dr) M.S, MCh (Neurosurgery) MRCS Address: Postdoctoral Fellow, Department Of Neurosurgery, SCTIMST, Medical College P.O., Thiruvananthapuram, Kerala, India, Pin - 695011
Co-Prinicpal Investigator:
Name: Mathew Abraham (Dr) M.S., M.Ch (Neurosurgery), FRCS (Edin.) Address: Professor, Department of Neurosurgery, SCTIMST, Medical college P.O., Thiruvananthapuram, Kerala, India, Pin - 695011
Co- Investigator(s)
(1) Name: Easwer HV(Dr) M.Ch (Neurosurgery) Address: Professor, Department of Neurosurgery, SCTIMST, Medical college P.O. Thiruvananthapuram, Kerala, India, Pin - 695011
(2) Name: Santhosh Kumar K (Dr) MD (Radiology), PDCC (Neuroradiology) Address: Additional Professor, Department Of Imaging Sciences and Interventional Radiology, SCTIMST, Medical College P.O., Thiruvananthapuram, Kerala, India, Pin - 695011
(3) Name: Jaypalsinh Asoksinh Gohil (Dr) M.S, MCh (Neurosurgery) Address: Postdoctoral Fellow, Department Of Neurosurgery, SCTIMST, Medical College P.O., Thiruvananthapuram, Kerala, India, Pin - 695011
(4) Name: Prof. Dr. Immaneul Thomas, MA, PhD Address: Retired Professor and Head, Department of Psychology, Kerala University, Kariyavattom, Trivandrum

You are planned for surgery for the brain arteriovenous malformation you are suffering from, after personally verifying and discussing the data obtained from your clinical history, examination and imaging. This management option is followed by surgeons worldwide for the brain arteriovenous malformation you are suffering from. The approach has been proved to be safe and effective with comparably acceptable postoperative morbidities. Angiogram is done preoperatively and postoperatively as a part of routine protocol for all patients undergoing any kind of management/intervention for brain arteriovenous malformation, including surgical excision.

Brief description risks and benefits of the study to you:

We intend to recruit few patients with brain arteriovenous malformations who are planned for surgery into a study named as "**PROSPECTIVE COMPARATIVE STUDY OF HEMODYNAMIC PARAMETERS FOLLOWING EXCISION OF BRAIN ARTERIOVENOUS MALFORMATIONS**". In this study, we intend to study the changes that occur in hemodynamics of the blood flow in blood vessels supplying the arteriovenous malformation as well as the different parts of the brain. This is done by comparing angiograms and trans-cranial doppler done prior to and after the excision of arteriovenous malformation which will yield certain parameters which can be compared. These changes in hemodynamics is then compared to the neuropsychological changes occurring as a result of excision of arteriovenous malformation.

Brief description risks and benefits of the study to you:

There shall be no cost burden to you. There will be no deviation from routine management protocol because of the study. There will no additional invasive procedure or tests because of the study. Angiograms are performed preoperatively or postoperatively for all patients undergoing any sort of intervention for brain arteriovenous malformation. These routine angiograms contain only certain parameters which are relevant clinically. But for study purpose, certain research parameter shall be calculated which is done using the same software that was used to acquire your angiogram images. Neuropsychological assessment as well as trans-cranial doppler shall be done free of cost during your preoperative waiting time in Neurosurgical ward as well as during the waiting time during the follow-up visit. No

personal details of yours shall be used nor shall be revealed and the hospital number will be the code number.

Brief description of benefits of the study to others:

The results of this study are expected to have a powerful influence on the surgical methods used for management of brain arteriovenous malformations in centres around the world. This study will help neurosurgeons to understand the impact of this surgery for brain arteriovenous malformations and further help to counsel patients who are planned for the surgery.

What if you consent for the study?

You have consented for surgical excision of the brain arteriovenous malformation. Based on your totally voluntary choice, as per this study if you consent, your clinical data shall be assessed at appropriate timeframes. You will undergo the surgery for brain arteriovenous malformation as any other patient. As part of diagnostic workup itself, you would have already undergone a diagnostic cerebral angiogram. After surgery, you will again undergo another diagnostic angiogram 3-6 months later. These are in concordance with the routine management protocol of the hospital as like any other patient. These routine angiograms contain only certain parameters which are relevant clinically. But for study purpose, certain research parameter shall be calculated which is done using the same software that was used to acquire your angiogram images. Neuropsychological assessment as well as transcranial doppler shall be done free of cost during your preoperative waiting time in Neurosurgical ward as well as during the waiting time during the follow-up visit. These parameters are compared with your clinical data to look for any significance.

What if you do not consent for the study?

Even if you do not consent for this study, you will undergo surgery as usual without any change in the timing or plan of surgery you were supposed to undergo. You shall still undergo two angiograms, prior to and after surgery, in concordance with the routine management protocol of the hospital

Will you have to pay for the investigations?

Imaging investigations required for the purpose of the study are part of routine

protocol for the surgery. No added imaging shall be done and there will no additional cost to you. You will need to come only on your usual review date for the study. Routine follow up visits are required.

Will your personal details be kept confidential?

The results of this study will be published in a medical journal but you will not be identified by name in any publication or presentation of results. However, people associated with the study, without your additional permission, may review your medical notes.

If you have any further questions, please ask **Dr. Mohamed Amjad Jamaluddin, Department of Neurosurgery, SCTIMST (Ph: 0471-2524647, Email: amjad96@sctimst.ac.in)**. For any clarifications regarding the study's ethics clearance you may contact the **Dr Mala Ramanathan, Member Secretary of the SCTIMST-IEC. The phone number is: 0471- 2524234 and the email id is iec.mem.sec@sctimst.ac.in**

Dr Mohamed Amjad Jamaluddin
Principal investigator

അറിവോടെയുള്ള സമ്മതപത്രം

കോഡ് നം: _____ പങ്കാളി (രോഗിയുടെ പേര്:

മസ്തിഷ്ക ധമനികളുടെ വൈകല്യത്തിനു എന്റെ, (ശ്രീമാൻ/ശ്രീമതി _____യുടെ രോഗവിവരണം, ശരീരപരിശോധന, സ്കാനുകൾ എന്നിവ പഠിക്കുകയും ചർച്ച ചെയ്യുകയും ചെയ്ത ശേഷം ഡോക്ടർമാർ ശസ്ത്രക്രിയ ചെയ്യാൻ തീരുമാനിച്ചിരിക്കുന്നു. ഞാൻ ഈ ശസ്ത്രക്രിയക്ക് സമ്മതം നൽകിയിട്ടുണ്ട്.

പഠനത്തിനായി ഞാൻ സമ്മതം നൽകിയാൽ എന്തു ചെയ്യും?

എനിക്ക് മസ്തിഷ്ക ധമനികളുടെ വൈകല്യത്തിനു ശസ്ത്രക്രിയ നടത്തപ്പെടും. ശസ്ത്രക്രിയക്ക് മുൻപും ശസ്ത്രക്രിയക്ക് 3-6 മാസങ്ങൾക്ക് ശേഷവും ആൻജിയോഗ്രാം ചെയ്യും. ഈ അസുഖം മൂലം എന്റെ മാനസികശേഷിയ്ക്ക് വ്യതിയാനം ഉണ്ടാകുകയും അത് ശസ്ത്രക്രിയയിലൂടെ മെച്ചപ്പെടുകയും ചെയ്യുന്നുണ്ടോ എന്നും ഈ വ്യത്യാസം എന്റെ മസ്തിഷ്ക ധമനികളിലെ രക്ത ഒഴുക്കിൽ ഉണ്ടായ വ്യത്യാസം കാരണമാണോ എന്നും അറിയാനുള്ളതാണ് ഈ പഠനത്തിന്റെ കൂടുതൽ വിശദാംശങ്ങൾ വിവരണപത്രത്തിൽ വിശദീകരിച്ചിട്ടുണ്ട്. എനിക്ക് എന്തെങ്കിലും ചോദ്യങ്ങൾ ഉണ്ടെങ്കിൽ ഡോ. മുഹമ്മദ് അംജദ് ജമാലുദ്ദീൻ മായി ബന്ധപ്പെടാം (ന്യൂറോസർജറി വിഭാഗം, 0471 2524647, amjad96@sctimst.ac.in) എന്ന് എനിക്കറിയാം. പഠനത്തിന്റെ ധാർമിക വശത്തെ സംബന്ധിച്ച് എന്തെങ്കിലും ചോദ്യങ്ങൾ ഉണ്ടെങ്കിൽ എനിക്ക് ശ്രീചിത്ര തിരുനാൾ ഇൻസ്റ്റിറ്റ്യൂട്ട് ഫോർ മെഡിക്കൽ സയൻസസ് ആൻഡ് ടെക്നോളജി സ്ഥാപനത്തിൽ കമ്മ്യൂണിറ്റി കാര്യദർശിയുമായി ബന്ധപ്പെടാം (04712524234, iec.mem.sec@sctimst.ac.in)

പഠനത്തിനായി ഞാൻ സമ്മതിക്കുന്നില്ലെങ്കിലോ?

ഈ പഠനത്തിനു ഞാൻ സമ്മതിക്കുന്നില്ലെങ്കിലും ശസ്ത്രക്രിയ ചെയ്യുന്ന സമയത്തിലോ രീതിയിലോ മാറ്റം വരുത്താതെ എനിക്ക് ശസ്ത്രക്രിയ നടത്തുന്നതായിക്കും.

മേൽപ്പറഞ്ഞ വിവരങ്ങൾ പഠനവുമായി ബന്ധപ്പെട്ട് ഞാൻ വായിച്ചിട്ടുണ്ട്. എന്നിക്കുണ്ടായിരുന്ന സംശയങ്ങളെല്ലാം ഞാൻ വ്യക്തമാക്കി. ഈ പഠനത്തിലെ എന്റെ പങ്കാളിത്തം പൂർണ്ണമായും സ്വമേധയാ ഉള്ളതാണെന്നും ഞാൻ മനസ്സിലാക്കുന്നു. എന്റെ സാധാരണ ചികിത്സ/ നിയമ അവകാശത്തെ ബാധിക്കാതെ എപ്പോൾ വേണമെങ്കിലും എനിക്ക് അനുമതി പിൻവലിക്കാവുന്നതാണ് എന്നും ഞാൻ മനസ്സിലാക്കുന്നു. ഈ പഠനത്തിൽ നിന്നും പിൻവാങ്ങിയ ശേഷവും എന്റെ ആരോഗ്യ രേഖകൾ പരിശോധിക്കാൻ പഠന ജീവനക്കാർക്കും സ്ഥാപനഎതിർസ്കമ്മിറ്റി അംഗങ്ങളും എന്റെ അനുമതി ആവശ്യമില്ലെന്ന് ഞാൻ മനസ്സിലാക്കുന്നു. ഞാൻ ഈ പരിശോധനയ്ക്കായി സമ്മതിക്കുന്നു. മൂന്നാം കക്ഷികൾക്ക് നൽകുന്ന അല്ലെങ്കിൽ പ്രസിദ്ധീകരണത്തിനായി നൽകുന്ന വിവരങ്ങളിൽ എന്റെ വ്യക്തിത്വം വെളിപ്പെടുത്തപ്പെടുകയില്ല എന്നു ഞാൻ മനസ്സിലാക്കുന്നു.

മസ്തിഷ്ക ധമനികളുടെ വൈകല്യങ്ങളുടെ ശസ്ത്രക്രിയക്ക് മുൻപും പിൻപും ധമനികളുടെ ഘടനയും ഒഴുക്കും താരതമ്യപ്പെടുത്തുന്ന പഠനത്തിൽ പങ്കെടുക്കാൻ ഞാൻ സ്വമേധയാ സമ്മതിക്കുന്നു

എന്റെ (രോഗി) പേരും ഒപ്പും
തീയതി

സാക്ഷിയുടെ പേരും ഒപ്പും

വൈദ്യസംബന്ധമായ ഗവേഷണ പഠനത്തിനായി ഈ രൂപത്തിൽ വിശദീകരിച്ചിട്ടുള്ള അംഗീകൃത സമ്മതപത്രം ആവശ്യപ്പെട്ടതായി ഞാൻ സാക്ഷ്യപ്പെടുത്തുന്നു. ശസ്ത്രക്രിയ സംബന്ധമായ ഏതെങ്കിലും തരത്തിലുള്ള യുക്തിപരമായി അപകടസാധ്യതകളും പ്രതീക്ഷിക്കാമെന്നും ഞാൻ പങ്കാളിയുമായിട്ടുള്ള ഗവേഷണപഠനത്തെക്കുറിച്ചുള്ള എല്ലാ വിവരങ്ങളും സാങ്കേതികമല്ലാത്തഭാഷയിൽ അവർക്ക് വിശദീകരിച്ചുകൊടുക്കുകയും ചെയ്തിട്ടുണ്ട്. ചോദ്യങ്ങൾ ചോദിക്കാൻ ഞാൻ പ്രോത്സാഹിപ്പിക്കുകയും എല്ലാ ചോദ്യങ്ങൾക്കും ഉത്തരം നൽകുകയും ചെയ്തു എന്ന് ഞാൻ സാക്ഷ്യപ്പെടുത്തുന്നു.

അനുവാദം വാങ്ങുന്ന വ്യക്തിയുടെ പേരും ഒപ്പും
തീയതി

രോഗികൾക്കായുള്ള വിവരണപത്രം

“മസ്തിഷ്ക ധമനികളുടെ വൈകല്യങ്ങളുടെ ശസ്ത്രക്രിയക്ക് മുൻപും പിൻപും ധമനികളുടെ ഘടനയും ഒഴുക്കും താരതമ്യപ്പെടുത്തുന്ന പഠനം”

ഗവേഷകർ:

മുഖ്യ ഗവേഷകൻ	മുഹമ്മദ് അംജദ് ജമാലുദ്ദീൻ (ഡോ.) എം.എസ്. (ജനറൽ സർജറി), എം. സി. എച്ച് (ന്യൂറോസർജറി) എംആർസിഎസ് (എഡിൻ)	പോസ്റ്റ് ഡോക്ടറൽ ഫെല്ലോ, ന്യൂറോസർജറി വിഭാഗം, ശ്രീചിത്ര തിരുനാൾ ഇൻസ്റ്റിറ്റ്യൂട്ട് ഫോർ മെഡിക്കൽ സയൻസസ് ആൻഡ് ടെക്നോളജി, തിരുവനന്തപുരം 695011
സഹമുഖ്യ ഗവേഷകൻ	മാത്യു എബ്രഹാം (ഡോ.) എം.എസ്., എം. സി. എച്ച് (ന്യൂറോസർജറി), എഫ്ആർസിഎസ് (എഡിൻ.)	പ്രൊഫസർ & മേധാവി, ന്യൂറോസർജറി വിഭാഗം, ശ്രീചിത്ര തിരുനാൾ ഇൻസ്റ്റിറ്റ്യൂട്ട് ഫോർ മെഡിക്കൽ സയൻസസ് ആൻഡ് ടെക്നോളജി, തിരുവനന്തപുരം 695011
സഹ ഗവേഷകൻ	ഇൗശ്വർ എച്ച്. വി. (ഡോ.) എം. സി. എച്ച് (ന്യൂറോസർജറി)	പ്രൊഫസർ ന്യൂറോസർജറി വിഭാഗം, ശ്രീചിത്ര തിരുനാൾ ഇൻസ്റ്റിറ്റ്യൂട്ട് ഫോർ മെഡിക്കൽ സയൻസസ് ആൻഡ് ടെക്നോളജി, തിരുവനന്തപുരം 695011
സഹ ഗവേഷകൻ	സന്തോഷ് കുമാർ കെ. (ഡോ.)	അഡീഷണൽ പ്രൊഫസർ, ഇമേജിംഗ് സയൻസസ് ആൻഡ്

	എം. ഡി., പി.ഡി.സി.സി. (ന്യൂറോറേഡിയോളജി)	ഇന്റർവെൻഷണൽ റേഡിയോളജി വിഭാഗം, ശ്രീചിത്ര തിരുനാൾ ഇൻസ്റ്റിറ്റ്യൂട്ട് ഫോർ മെഡിക്കൽ സയൻസസ് ആൻഡ് ടെക്നോളജി, തിരുവനന്തപുരം 695011
സഹ ഗവേഷകൻ	ജെയ്‌പാൽസിംഗ് ഗോഹിൽ എം.എസ്. (ജനറൽ സർജറി), എം. സി. എച്ച് (ന്യൂറോസർജറി)	പോസ്റ്റ് ഡോക്ടറൽ ഫെല്ലോ, ന്യൂറോസർജറി വിഭാഗം, ശ്രീചിത്ര തിരുനാൾ ഇൻസ്റ്റിറ്റ്യൂട്ട് ഫോർ മെഡിക്കൽ സയൻസസ് ആൻഡ് ടെക്നോളജി, തിരുവനന്തപുരം - 695011
സഹ ഗവേഷകൻ	ഇമ്മാനുവൽ തോമസ് എം.എ (സൈക്കോളജി) പി.എച്ച്.ഡി	റിഡി. പ്രൊഫസർ & മേധാവി സൈക്കോളജി വിഭാഗം, കേരള യൂണിവേഴ്സിറ്റി, കാര്യവട്ടം, തിരുവനന്തപുരം

നിങ്ങളുടെ രോഗവിവരണം, ശരീരപരിശോധന, സ്കാനുകൾ എന്നിവ പഠിക്കുകയും ചർച്ച ചെയ്യുകയും ചെയ്ത ശേഷം മസ്തിഷ്ക ധമനികളുടെ വൈകല്യങ്ങളുടെ ശസ്ത്രക്രിയ ചെയ്യാൻ ഡോക്ടർമാർ തീരുമാനിച്ചിരിക്കുന്നു. ലോകമെമ്പാടുമുള്ള ഡോക്ടർമാർ ഈ അസുഖത്തിനു ഈ ശസ്ത്രക്രിയ ഉപയോഗിച്ചുവരുന്നു. നിങ്ങൾ ഈ ശസ്ത്രക്രിയക്ക് സമ്മതം നൽകിയിട്ടുണ്ട്. ഈ ശസ്ത്രക്രിയയ്ക്ക് മുൻപും പിൻപും ഉള്ള മസ്തിഷ്ക ധമനികളുടെ ഘടന അറിയുവാൻ ഡോക്ടർമാർ ആൻജിയോഗ്രാം നടത്തിവരുന്നു. അതിനാൽ ശസ്ത്രക്രിയയ്ക്ക് മുൻപും ശസ്ത്രക്രിയയ്ക്ക് 3-6 മാസങ്ങൾക്ക്ശേഷവും ഒരു ആൻജിയോഗ്രാം ചെയ്യുന്നതാണ്.

പഠനത്തിനായി നിങ്ങൾ സമ്മതം പറഞ്ഞാൽ എന്തുചെയ്യും?

നിങ്ങളുടെ പങ്കാളിത്തം പൂർണ്ണമായും സ്വമേധയാ ഉള്ളതാണ്. ശസ്ത്രക്രിയയ്ക്ക് മുൻപും ശസ്ത്രക്രിയയ്ക്ക് 3-6 മാസങ്ങൾക്ക്ശേഷവും ഒരു ആൻജിയോഗ്രാം ചെയ്യുന്നതാണ്. ഈ അസുഖം മൂലം നിങ്ങളുടെ മാനസികശേഷിയ്ക്ക് വ്യതിയാനം ഉണ്ടാകുകയും അത് ശസ്ത്രക്രിയയിലൂടെ മെച്ചപ്പെടുകയും

ചെയ്യുന്നു. എന്നും ഈ വ്യത്യാസം നിങ്ങളുടെ മസ്തിഷ്ക ധമനികളിലെ രക്തക്കുഴലിൽ ഉണ്ടായ വ്യത്യാസം കാരണമാണോ എന്നും അറിയാനുള്ളതാണ് ഈ പഠനം. നിങ്ങൾ ഈ പഠനത്തിന് സമ്മതിക്കുകയാണെങ്കിൽ, കമ്പ്യൂട്ടർ മുഖേന ഈ ആൻജിയോഗ്രാഫി രക്തക്കുഴൽ പഠിക്കുകയും അത് നിങ്ങളുടെ രോഗലക്ഷണങ്ങളുമായി താരതമ്യപ്പെടുത്തുന്നതാണ്. അതിലൂടെ രോഗചികിത്സാ സംബന്ധമല്ലാത്ത സാധാരണ ഗതിയിൽ നിർണ്ണയിക്കപ്പെടാത്ത ചില ഗവേഷണമൂല്യങ്ങൾ കമ്പ്യൂട്ടർ സോഫ്റ്റ്‌വെയർ മുഖേന ലഭിക്കുന്നതാണ്. ഇതിനുപരി ശസ്ത്രക്രിയയ്ക്കു മുൻപും ശസ്ത്രക്രിയയ്ക്കു 3-6 മാസങ്ങൾക്കു ശേഷവും ഒരു ട്രാൻസ് - ക്രാനിയൽ ഡോപ്ലർ നിങ്ങൾക്ക് സൗജന്യമായി നിങ്ങളുടെ സന്ദർശനവേളയിലെ കാത്തിരിപ്പു സമയത്തിൽ റസിഡന്റ് ഡോക്ടർ ചെയ്യുന്നതാണ്. ഇതിലൂടെ ലഭിക്കുന്ന ഗവേഷണമൂല്യങ്ങൾ നിങ്ങളുടെ മനശാസ്ത്രത്തിൽ ശസ്ത്രക്രിയ ഉണ്ടാക്കിയ വ്യത്യാസം താരതമ്യപ്പെടുത്തി പഠിക്കുന്നതാണ്. പഠനത്തിനായി നിങ്ങളുടെ ശസ്ത്രക്രിയക്ക് 3 മാസത്തിനും 6 മാസത്തിനും ശേഷമുള്ള ആശുപത്രിസന്ദർശന തീയതികളിൽ യാതൊരു ഇടപെടലുകളും ഉണ്ടാകില്ല. അധിക സ്കാനുകളോ ചെലവോ ഉണ്ടാകുന്നതല്ല. ഈ പഠനങ്ങൾ നിങ്ങളുടെ സൗകര്യപ്രദമായ സമയത്ത് പതിവ് ആശുപത്രി സന്ദർശനത്തിനിടയിൽ ചെയ്യും.

പഠനത്തിനായി നിങ്ങൾ സമ്മതിക്കുന്നില്ലെങ്കിലോ?

ഈ പഠനത്തിനു നിങ്ങൾ സമ്മതിക്കുന്നില്ലെങ്കിലും ശസ്ത്രക്രിയ ചെയ്യുന്ന സമയത്തിലോ രീതിയിലോ മാറ്റം വരുത്താതെ നിങ്ങൾക്ക് ശസ്ത്രക്രിയ നടത്തുന്നതായിക്കും.

പഠനത്തിനായി നിങ്ങൾക്ക് അധികചെലവ് ഉണ്ടാവുമോ?

ശസ്ത്രക്രിയയ്ക്കായുള്ള പതിവ് ചെലവും സ്കാനുകളുടെ ചെലവും നിങ്ങൾക്ക് ഉണ്ടാകും. അധിക സ്കാനുകളോ ചെലവോ നിങ്ങൾക്ക് ഉണ്ടാകുന്നതല്ല. ഈ പഠനത്തിനായി ഉപയോഗിക്കുന്ന ട്രാൻസ് ക്രാനിയൽ ഡോപ്ലർ പരിശോധനയ്ക്ക് അധികചെലവോ സന്ദർശനമോ ആവശ്യം വരില്ല.

നിങ്ങളുടെ വ്യക്തിഗത വിശദാംശങ്ങൾ രഹസ്യമായി സൂക്ഷിക്കുമോ?

ഈ പഠനത്തിന്റെ ഫലങ്ങൾ ഒരു വൈദ്യസംബന്ധമായ ജേണലിൽ പ്രസിദ്ധീകരിക്കും. എന്നാൽ ഫലങ്ങളുടെ അവതരണത്തിലോ പ്രസിദ്ധീകരണത്തിലോ നിങ്ങളെ തിരിച്ചറിയാൻ കഴിയില്ല. എന്നിരുന്നാലും ഈ പഠനവുമായി ബന്ധപ്പെട്ട ഗവേഷകർക്ക് നിങ്ങളുടെ രേഖകളെ അവലോകനം ചെയ്യാം.

നിങ്ങൾക്ക് എന്തെങ്കിലും ചോദ്യങ്ങൾ ഉണ്ടെങ്കിൽ ഡോ. മാത്യു ഏബ്രഹാമു മുഹമ്മദ് അംജദ് ജമാലുദ്ദീൻ മായി ബന്ധപ്പെടാം (ന്യൂറോസർജറി വിഭാഗം, 0471 2524647, amjad96@sctimst.ac.in). പഠനത്തിന്റെ ധാർമ്മിക വശത്തെ സംബന്ധിച്ച് എന്തെങ്കിലും ചോദ്യങ്ങൾ ഉണ്ടെങ്കിൽ നിങ്ങൾക്ക് ശ്രീചിത്ര തിരുനാൾ ഇൻസ്റ്റിറ്റ്യൂട്ട് ഫോർ മെഡിക്കൽ സയൻസസ് ആൻഡ് ടെക്നോളജി സ്ഥാപനത്തിൽ സകമ്മിറ്റി കാര്യദർശിയുമായി ബന്ധപ്പെടാം (04712524234, iec.mem.sec@sctimst.ac.in)

