

**SREE CHITHRA THIRUNAL INSTITUTE FOR
MEDICAL SCIENCES & TECHNOLOGY**

**OPERATIVE OUTCOME IN DISTAL ANTERIOR
CEREBRAL ARTERY ANEERYSMS**

PRITHVI VARGHESE

LIST OF PROCEDURES DONE

PROJECT REPORT

TITLE

**A STUDY OF OPERATIVE OUTCOME
IN DISTAL ANTERIOR CEREBRAL
ARTERY ANEURYSMS**

NAME : DR. PRITHIVI VARGHESE


PROGRAMME : M.Ch NEURO SURGERY

MONTH & YEAR OF SUBMISSION : NOVEMBER 1998

SREE CHITRA TIRUNAL INSTITUTE FOR MEDICAL SCIENCES AND TECHNOLOGY TRIVANDRUM 695 011	Name	
	Page	of
	Date	

CERTIFICATE

I, Dr. **PRITHVI VARGHESE**.....hereby declare that I have actually performed all the procedures listed/carried out the project under report.

Signature.....

Place: **Trivandrum**

Name in capital letters

Date : **8/11/98.**

PRITHVI VARGHESE.....

Forwarded. He has carried out minimum requirement of procedures/etc.


Signature
Head of the Department

SREE CHITRA TIRUNAL INSTITUTE FOR MEDICAL SCIENCES AND TECHNOLOGY TRIVANDRUM 695 011	Name	
	Page	of
	Date	

ACKNOWLEDGMENT

I am grateful first of all to Dr. Suresh Nair, Professor and ^{Addl} Head of the Department of Neurosurgery for the guidance and advice.

The suggestions and encouragement of Dr. Dilip Panicker, Dr. Bhaskar, Dr. Uma, Dr. Rajneesh and Dr. Girish have been invaluable.

I am indebted to all my colleagues for their support.

Special thanks to my wife, Nisha for the company and help.

Dr. Prithvi Varghese

CONTENTS

1. PREFACE	1
2. INTRODUCTION.....	2
3. AIMS AND OBJECTIVES.....	3
4. MATERIALS AND METHODS	4
5. REVIEW OF LITERATURE.....	6
6. RESULTS AND ANALYSIS	31
7. DISCUSSION	40
7. SUMMARY AND CONCLUSIONS	48
8. REFERENCES	49

SREE CHITRA TIRUNAL INSTITUTE FOR MEDICAL SCIENCES AND TECHNOLOGY TRIVANDRUM 695 011	Name	
	Page	of
	Date	

PREFACE

Intracranial aneurysms account for 51% of cases of subarachnoid haemorrhage, excluding trauma. The incidence of subarachnoid haemorrhage is between 6 and 10.9 per 100,000 population per year. Based on various studies it can be stated that less than 2 percent of the entire population will have an intracranial aneurysm, and such an aneurysm will rupture in less than 1% of the population and will be the cause of death in 0.5 percent.

DISTAL ANTERIOR CEREBRAL ARTERY ANEURYSMS

INTRODUCTION

Distal anterior cerebral artery aneurysms arise from the anterior cerebral artery distal to the anterior communicating artery. DACA aneurysms are uncommon and they comprise 2-9.2% (mean 4.4%) of all intracranial aneurysms. Most series reports fewer than 20 patients.

Although often relatively small these aneurysms pose special difficulties to the surgeon.

Reviews stress that patients with DACA aneurysms have a high incidence of multiple aneurysms. DACA aneurysms are similar to intracranial aneurysms found at other location; they are saccular and probably flow related. Most patients with DACA aneurysms come to medical attention because of subarachnoid haemorrhage. However a significant number of DACA aneurysms are detected incidentally especially with wider use of magnetic resonance imaging.

In this study all cases of distal anterior cerebral artery aneurysms that were admitted to the Department of Neurosurgery, SCTIMST in the period 1984-1998 are reviewed. The different parameters including mode of presentation, associated anomalies, aneurysm characteristics, treatment and outcome have been studied.

AIMS AND OBJECTIVES

The aims and objectives of the present study include :

1. Study of the natural history, clinical presentation and characteristics of the DACA aneurysms.
2. Study of the prognostic factors in cases of DACA aneurysms.
3. Study about the anomalies associated with DACA aneurysms.
4. Study about the differences in outcome of DACA aneurysms when compared to other intracranial aneurysms.
5. Study about the problems related to surgical management of DACA aneurysms.

MATERIALS AND METHODS

During the period from April 1984 to January 1998, 936 patients were treated in the Department of Neurosurgery, SCTIMST, Trivendrum for aneurysmal subarachnoid haemorrhage. Of these patients 27 had distal anterior cerebral artery aneurysms. These patients are the subject of the study.

The study was a retrospective one, and the data were collected by reviewing the patient's case records. The details of clinical presentation, associated features, radiographic findings and surgical outcome were analysed by examining the case records.

Patients were graded preoperatively using WFNS system based on Glasgow Coma Scale.

Grade I - GCS 15.

Grade II - GCS 13-14; no deficits.

Grade III - GCS 13-14; with neurological deficits.

Grade IV - GCS 8-12; with or without deficits.

Grade V - GCS 3-7; with or without deficits.

Only patients in Grade III or above were operated.

All patients underwent 4 vessel cerebral angiography.

The surgical outcome results were analyzed using Glasgow Outcome Scale.

5 - Good recovery.

4 - Moderate disability (disabled but independent).

3 - Severe disability (conscious but disabled).

2 - Persistent vegetative state.

1 - Death.

The surviving patients were called for follow up and subjected to detailed examination.

REVIEW OF LITERATURE

Distal anterior cerebral artery aneurysms are uncommon. Most clinical series report fewer than 20 patients. Among the various series on distal anterior cerebral artery aneurysms, the largest has been reported by Juha Hernesniemi et al* (8). The reported series of more than ten cases of DACA aneurysms are the following (17).

Series	No. of patients	Incidence (%)
Laitinen and Snellmann (1960)	24	4.5
McKissock et al (1960)	15	2
Shycker's and Drake (1973)	24	5.5
Dechaume et al (1973)	12	3.6
Yanasgil and Carter (1974)	13	3.4
Kinoshita and Matsujado (1975)	10	6.7
Nukui and Aiba (1978)	26	?
Yoshimoto et al (1979)	34	5.6
Becker and Newton (1979)	12	?
Yanargil (1984)	23	2.3
Mann et al (1984)	11	5.5
Kuwabara et al (1984)	18	5.2
Wisoff and Flamm (1987)	20	4.1
Ogasawara et al (1987)	18	6
Sindon et al (1988)	19	?
Kawamara et al (1988)	29	4.1
Ohno et al (1990)	92	9.2
Hernesniemi et al (1992)	84	5.5

Anatomy of anterior cerebral artery

The Distal Anterior Cerebral Artery (DACA) includes the anterior cerebral and its branches distal to the anterior communicating artery. The DACA courses anteriorly and superiorly from the anterior communicating artery to the genu of corpus callosum where it bifurcates into the superior callosomarginal and inferior pericallosal arteries. The two DACAs run parallel to each other a few millimeters apart on the medial surface of the olfactory area in the interhemispheric fissure. The ACA is located in the pericallosal sulcus or more superiorly in the callosomarginal sulcus. The DACA terminates at the parieto occipital fissure.

The ACA is divided in the following manner (24). The portion extending from internal cortical artery to anterior communicating artery is designated A1 segment. The portion distal to ACom artery is referred to as pericallosal artery and is subdivided into four segments; A2 through A5. The A2 segment extends from ACom artery to a region between rostrum and genu of corpus callosum. The A3 segment courses around genu to the rostral part of body of corpus callosum. In the lateral view an imaginary line parallel to and just behind coronal suture divides the A4 and A5 segments (2,3).

The diameters of A2 is 2.6mm (0.9-4mm) (19). The branches of DACA have been classified as being central or cerebral (5). The central ones consisted of branches to optic chiasm, suprachiasmatic area and anterior forebrain inferior to corpus callosum. The cerebral vessels are cortical, subcortical and callosal

branches. The cortical branches are as follows : A2 - orbito frontal and frontopolar; A3 - anterior internal frontal, middle internal frontal and callosomarginal; A4 - paracentral; A5- superior and inferior parietal (18). The posterior internal frontal artery arose from A3 or A4 with equal frequency as well as from callosomarginal artery. The pericallosal was the most common artery of origin of the cortical branches A distal ACA irrigates the contralateral hemisphere in 64% of brains (18).

The callosomarginal trunk varies inversely with the size of pericallosal artery. When it has a well formed trunk it lies in the sulcus above the cingulate gyrus and follows a course roughly parallel to that of pericallosal artery. Its branches ascend on the medial surface of the hemisphere and continue onto the lateral convexity for about 2cm. Portions of the premotor, motor and sensory areas are included in its area of perfusion. It terminates in the paracentral lobule. After giving rise to its cortical branches the pericallosal artery passes around the splenium of the corpus callosum on a fine tortuous vessel to terminate in the choroid plexus in the roof of third ventricle. Marino (15) considered there were 11 main cortical branches of ACA; orbito frontal, frontopolar, internal frontal (anterior, middle and posterior), terminal paraventral, precuneal, parieto occipital, posterior pericallosal, callosomarginal and pericallosal. While the origin and branching patterns of ACA vary the territories of vascular supply are more constant; orbito frontal, frontopolar, anterior internal frontal, middle internal frontal, posterior internal frontal, paracentral, superior internal parietal and inferior internal parietal.

The anomalies commonly encountered in the ACA are an unpaired artery, an artery giving a branch to the contralateral hemisphere, and a triplicate artery (1). An azygos ACA has been reported in 0.2 to 3.7% of angiographically studied cases (9). The splenium of the corpus callosum is supplied by the dorsal callosal arteries, which originate from the PCA; these anastomose with the terminal branches of the pericallosal artery. Krayenbühl and Yasargil found that the variations of the frontopolar, callosomarginal and pericallosal arteries with respect to site of origin, diameter and course were so considerable that they could be summarized only with great difficulty.

The orbital branch of pericallosal or A2 is the first branch. It may arise either directly from the infracallosal segment or from a common trunk that also gives rise to the frontopolar artery. The orbital arteries lie either on the medial surface of the hemisphere or on the inferior surface of the frontal lobe. They course forward to supply the mediobasal region of the frontal lobe (the gyrus rectus, the medial orbital gyri, and the olfactory bulb and tract). The orbital artery may be absent or multiple.

The frontopolar artery arises from the infracallosal segment of the pericallosal or A2 artery. It may arise from the callosomarginal artery when the latter has a proximal origin. It passes anteriorly along the medial surface of the cerebral hemisphere in a gentle curve, following a horizontal course towards the frontal pole. It supplies the anterior portion of the medial and lateral surfaces of the superior frontal gyrus. It is variable in size and not always recognizable angiographically.

The A2 segment was considered by Perlmutter and Rhoton to have an average length of 28mm (range 22-30mm) with 4.8 perforators (range 0-10) going to the suprachiasmatic area, anterior diencephalon, and rostrum of corpus callosum. An average of 1.2 (0.4) basal perforators originated in the first 5mm of the A2 segment. Forty-six percent arose from the lateral wall of the artery, and 43% from the superior wall. Most of these branches terminated in the gyrus rectus (29%) or inferior frontal regions (31%), while other sites include anterior perforated substance (15%) and dorsal optic chiasm and suprachiasmatic area (12%). The remaining three segments of the distal ACA ranged in length from 27 to 41mm and gave off approximately three perforators each to the corpus callosum. Perlmutter and Rhoton found communications between the A2 distal to the A.Com A in 2% of dissections. Connections between the two ACA may occur either proximally or distally to the aneurysm. Aneurysms may occur at the apex of a single pericallosal artery. The pericallosal arteries from both sides may unite to form what has been termed a supreme A.Com A.

Triple ACA were demonstrated in 8% of normal brains. Kwak and Associates (11) found median ACA arising from the A.Com A in 4.4% of 296 cases with single aneurysms. A third of median ACA arising from the A.Com A was found in 2% of the dissections of Perlmutter and Rhoton. This median vessel courses superiorly and posteriorly over the dorsum of the corpus callosum. It gives branches to the paracentral lobules bilaterally. It has been reported in 1.5% to 10% of brains. The post communicating segments of the ACA can be

unpaired in 0.5% to 5% of cases (eight series reviewed by Krayenbühl and Yasargil).

Bilateral involvement of the distal ACA can produce paraplegia and bilateral crural (leg) sensory loss, which may mimic spinal cord disease. Mental disturbances such as akinetic mutism or dementia may also result. Occlusion of the distal ACA beyond the origin of the recurrent artery of Heubner produces mainly a contralateral hemiplegia with crural predominance. Slight reduction in superficial sensation and severe impairment of deep sensation in the contralateral lower limb may result from both central and sensory cortical ischemia. Aphasia of a transient nature is common following supplementary speech area involvement. Mesial frontal lobe ischemia can result in hypokinesia. Lesions around the fornix or anterior commissure may result in memory impairment and confusion. Paracentral pathology can reduce control of the urinary and rectal sphincters.

The falx cerebri is a dural fold that separates the cerebral hemispheres. It extends from the frontal bone to the occipital and from the superior sagittal sinus to the inferior. The sickle shaped structure attaches to the crista galli anteriorly and the internal occipital protuberance posteriorly. It is narrower anteriorly than posteriorly. Its height varies considerably but the free margin of its anterior portion lies above the genu of the corpus callosum and the pericallosal sulcus. The free margin of the posterior portion almost always lies on the splenium. Pericallosal artery is below the margin of the falx. A long portion of the paricallosal artery is free to shift across the midline underneath the falx. The

callosomarginal artery, on the other hand, lies above the pericallosal artery with only the most anterior portion below the free margin of the falx. The remainder lies between the falx and the cerebral hemisphere, and thus displacement across the midlines is prevented by the falcine rigidity

Etiology and Pathogenesis of intracranial aneurysms in general

Morphologically intracranial aneurysms can be classified into :

1. Saccular
2. Fusiform
3. Dissecting

The causative factors implicated in the formation of intracranial saccular and fusiform aneurysms are as follows :

A. *Haemodynamic*

1. Uneven pulsatile pressure head distribution at apex of bifurcations, branchings or outer aspect of curves, causing local degeneration of internal elastica.
2. Increase flow from
 - a) Distal arteriovenous malformation.
 - b) Aplasia, hypoplasia, or ligation of contralateral vessel normally present.
 - c) Persistent carotid - basilar anastomosis (trigeminal, otic, hypoglossal, proatlantal) and basilar - middle meningeal anastomosis.
1. Increased blood pressure (and possibly associated vessel defect in)
 - a) Coarctation of aorta.
 - b) Autosomal dominant polycystic kidney disease.
 - c) Fibromuscular dysplasia, renal arteries.

B. Structural

1. Combined media and elastica defects.
2. Preaneurysmal lesions : infundibula, thin area, microaneurysms.

C. Genetic

1. Familial intracranial aneurysms - dominant inheritance.
2. Genetic or possibly genetic syndromes associated with blood vessel abnormalities and reported with intracranial aneurysms:

Ehrler - Danlos syndrome, Marfan's syndrome, Pseudoxanthoma elasticum, Rendu-Osler-Weber syndrome, Klippel-Trenaury - Weber syndrome, type III collagen deficiency.

D. Traumatic

1. Skull fracture.
2. Penetrating Foreign body.
3. Surgical injury.

E. Infections

1. Bacterial.
2. Fungal.

F. Neoplastic

1. Metastatic : Choriocarcinoma, atrial myxoma, undifferentiated carcinoma.
2. Primary neoplasm.
3. Aneurysm associated with neoplasm : Pituitary adenomas.

G. Other disorders affecting blood vessels

1. Granulomatous (giant cell) angitis.
2. Systemic lupus erythematosus.
3. Moyamoya disease.
4. Sickle cell anemia.

H. Radiation induced saccular aneurysm

Fusiform aneurysms

A. Atherosclerosis

Most common cause of elongated, distended (dolichoectatic) cerebral vessels.
Posterior circulation most affected.

B. Structural

1. Long areas of loss of normal elastica and media.
2. Diffuse arterial fibromuscular dysplasia.

C. Genetic

Possibly genetic conditions associated with fusiform aneurysms include Marfan's syndrome, pseudoxanthoma elasticum.

B. Infections

- .. Syphilis.

E. Other disorders of blood vessels

- .. Giant cell arteritis

F. Hemodynamic

- .. Coarctation of aorta.

G. Radiation induced fusiform aneurysm.

The common saccular aneurysm is probably acquired by hemodynamically induced degeneration of the arterial wall.

Bacterial aneurysms make up under 5% of all cases of intracranial aneurysms. The most common cause is a streptococcal infection in a patient with bacterial endocarditis. Mortality is relatively low in patients treated with appropriate high-dose antibiotics and surgery.

Traumatic aneurysms are uncommon and can result from either blunt or penetrating head trauma. The majority of patients have associated skull fractures. Penetrating injuries result from a variety of missiles and surgical instruments. These aneurysms are usually located on the supratentorial circulation at sites other than branching points and are most commonly single. Their presence should be considered in delayed deterioration following head injury. The sac may have an irregular contour, a neck may be absent, and there may be delayed filling and emptying on angiography. The outlook is poor without direct surgical treatment

Embolization of tumour cells in to the cerebral arteries may result in aneurysm formation. The most common neoplasms to metastasizes to the brain and form an aneurysm is atrial myxoma, although it more commonly causes arterial occlusion with cerebral infarction. Choriocarcinoma and other metastatic neoplasms may rarely form aneurysms by tumor embolization. Gliomas may invade the walls of major cerebral arteries and form saccular aneurysms.

The possibility that some tumours stimulate the growth of aneurysms in nearby blood vessels has also been raised. However it is not clear whether the incidence of such aneurysms exceeds what would normally be expected; brain tumours and aneurysms are both relatively common, so instances of both conditions in the same patient are inevitable.

There is nevertheless, considerable surgical relevance to the finding of an aneurysm in the intracavernous or supraclinoid portion of the carotid artery in

pituitary adenomas. The increased incidence of aneurysms is seen particularly with growth hormone - secreting adenomas. The association of aneurysms and pituitary tumours also includes aneurysms mimicking tumours, aneurysms occurring following intraoperative injury to carotid artery and aneurysms developing after irradiation of the sella. Distinguishing aneurysms and pituitary neoplasms is a diminishing problem in the era of magnetic resonance imaging (MRI).

It is now widely accepted that the damage to the internal elastic lamina by hemodynamic factors is the critical pathologic change. Stehbens (22) reviewed the etiology of intracranial saccular aneurysms and concluded that there was no evidence for the congenital, developmental or inherited weakness of the arterial wall. He believed the most plausible explanation was that aneurysms are acquired lesions due to hemodynamic stress upon the relatively unsupported arterial bifurcations of the cerebral arteries.

These arteries are predisposed to degenerate because of their thin walls and lack of abundant elastic tissue, including absence of external elastic lamina. Factors that alter blood flow, such as vessel occlusions, arteriovenous malformations, and hypertension and disease that affect connective tissue may accelerate the degenerative processes. It should not be forgotten, however, that in addition to absence of the elastica, all aneurysms show absence of media.

Crompton examined 149 cases at autopsy (4). He found medial defects, intimal cushions and even changes in the internal elastica in cerebral arterial forks at birth, although he did not find that all these lesions increased in size and number with increasing age.

Elastic degeneration appeared first in the intimal pads around the bifurcation, then in the elastica over medial defects. He found that large medial defects were unusual in the first decade but thereafter became progressively more common.

Arterial hypertension and renal polycystic disease were associated with increased number of large medial defects.

The consensus now is that atherosclerosis does not lead directly to the formation of aneurysms. Intimal proliferations occur at the mouth of all aneurysms and to some extent at the sites of early aneurysmal change.

Apical regions are affected much more frequently than could be explained by chance alone. The absence of a distinct media in the sac wall was emphasized. The sac wall was still capable of organization and repair. Rather than a medial defect being the earliest change, funnel - shaped dilatations, areas of thinning and small - evaginations are thought to be the essential preaneurysmal lesions, since they are associated with severe degenerative changes in the internal elastic lamina that had areas of thinning or evagination. Stehbens denies that small vessels arising from the apex of forks, vestiges of primitive capillary plexuses, or inflammatory processes are important in the pathogenesis of aneurysms.

The role of abnormalities of type III collagen in the etiology of saccular aneurysms remains unclear. Ostergaard and Oxlund found a deficiency in type III collagen in middle cerebral arteries of 6 to 14% patients who die of aneurysmal subarachnoid hemorrhage. This was accompanied by an increase in arterial extensibility but not an alteration in the mechanical strength of the arteries. Brachial arteries from the same cases were biomechanically normal even though they had less type III collagen. Other studies have not identified deficiencies of type III collagen produced by skin fibroblasts of patients with aneurysms.

Pathology of intracranial arterial saccular aneurysms

A. Light microscopy

The aneurysmal sac lacks normal layers.

Intima : Normal or shows subendothelial proliferations consisting of several layers of smooth muscle cells and connective tissue enveloped by internal elastic membrane usually situated at the mouth of the sac : there may be foam cells.

Internal elastic lamina : Usually absent or reduced to fragments : may be hypertrophied and duplicated at margin of aneurysm.

Muscularis layer of media : Ends abruptly at neck of aneurysm.

Aneurysm wall : May vary greatly in thickness. Larger aneurysms with thick walls may have a laminated appearance, with fibrous tissue layers having hemosiderin deposits and cholesterol and foam cells, interposed between them. Thin areas may consist of only endothelium and adventitial fibrous tissue, but usually some fibrohyaline tissue is interposed.

Rupture site : Usually the thinnest area of the dome of the sac. Fibrin plug or layer is present at break in the wall. Thrombus is associated within the sac. In remote ruptures, the fibrin is infiltrated by capillaries from the arachnoid. These can traverse the wall to regions of intimal proliferation. Microhemorrhages can occur in the wall from these capillaries.

Lumen : May contain thrombus of varying degrees of organization : dense hyaline a acellular tissue may occur in an organized thrombus.

Adventitia : The loose fibrous tissue may be infiltrated by leukocytes, lymphocytes and hemosiderin-laden phagocytes if there has been previous hemorrhage.

Parent artery : Usually shows atherosclerotic changes, most marked in intimal pads at entrance to sac : foam cells, lipophages and cholesterol clefts are seen.

B. Electron microscopy

1. Scanning microscopy shows :

Regressive changes in endothelium, such as ballooning, craters and cytoplasmic bridges. At gaps between endothelial cell junctions, platelets and leukocytes adhere. Endothelium may be missing altogether.

Adventitia may look normal.

2. Transmission microscopy shows :

Endothelial cells containing intracytoplasmic vacuoles, empty or full of lipid material.

Beneath the endothelium there is often a grossly thickened basement membrane, which is multilaminar or reticulated.

Fragments of elastica still present have lost their fibrillar structure. Scanty and sclerotic smooth muscle cells exist in the wall. Some contain hyaline patches, others autophagic vacuoles. Connective tissue - contains some well-preserved fibroblasts. Extracellular lipid is common. Collagen fibres of variable length are arranged haphazardly. There is an abundant intercellular space - containing lipofuscin granules.

Etiology of DACA aneurysms

A variety of diseases and anomalies are associated with DACA aneurysms (26) including over other intracranial aneurysms. The incidence of coexisting disorders is about 37.5 percent and includes the following :

- other intracranial aneurysms, commonly of middle cerebral (8) (17) (25) and internal carotid arteries.
- Arterio venous malformations (16).
- Azygos anterior cerebral arteries.
- Bihemispheric anterior cerebral artery.
- Supreme anterior communicating artery.
- Polycystic kidney disease (7).
- Coarctation of aorta.
- Hypertension.
- Craniosynostosis.
- Agencies of corpus callosum.

Like other intracranial aneurysms. DACA aneurysms can be categorized as saccular (congenital), mycotic atherosclerotic or traumatic. The majority of DACA aneurysms are of saccular type presumably of congenital origin. The location of the aneurysm on the ACA is related to the etiology. Proximally located aneurysms are most likely to be congenital in origin whereas distal lesions may be mycotic or traumatic.

Approximately two-thirds (14) of DACA aneurysms are located near the genu of the corpus callosum at the bifurcation of the pericallosal and callosomarginal arteries, where the pericallosal artery frequently makes an abrupt bend posteriorly. (Type 3 of Pertuiset). The proximal, distal and frontobasal DACA aneurysms are less common. The etiology of most of these aneurysms is believed to be similar to that of berry aneurysms located on the circle of Willis, which occur at the bifurcations of vessels and are characterized pathologically by fragmentation and loss of the internal elastica and thinning of the media.

The description by Laitinen and Snellman of the occurrence of a communication between the pericallosal arteries at the genu of the corpus callosum in conjunction with DACA aneurysms has been cited as evidence for a congenital etiology. These authors have termed this anomalous communicating vessel, the supreme anterior communicating artery. Yasargil and carter noted similar arterial connections and suggest that although a developmental etiology is possible, it is just as likely that an anatomic variation may create a flow disturbance leading to aneurysm formation (26).

Most DACA Aneurysms located beyond the genu of the corpus callosum are secondary to trauma, infection (mycotic), or tumour embolization, or are idiopathic. A larger percentage of DACA aneurysms than aneurysms at other intracranial locations occur as a result of infection or trauma.

Traumatic aneurysms, of which DACA aneurysms are second in incidence only to those of cortical branches of the middle cerebral artery, result from either direct or indirect trauma. Direct trauma results in aneurysm formation when a penetrating object, surgical manipulation, or overlying skull fracture damages the wall of an artery in its path-way. Indirect vascular injury is usually associated with a significant closed head injury and is probably secondary to the deformity, shearing and compression occurring with the traumatic acceleration and deceleration of the brain. The arterial injury producing DACA aneurysms may be secondary to compression of the vessel on the adjacent free edge of the falx during a transient shift of the brain beneath this rigid structure.

If the injury to the arterial wall is incomplete, the damaged internal elastic lamina and media of the artery allow dilatation in a manner similar to a congenital (true) berry aneurysm. False aneurysms occur when all layers of the arterial wall are lacerated with resultant hemorrhage. The hematoma is contained by surrounding brain and the periphery becomes organized over the next few days.

Mycotic aneurysms result from infected emboli (usually from bacterial endocarditis) that infect the arterial wall by direct extension from the lumen.

DACA aneurysms of embolic origin are usually located on the most distal branches. A DACA - aneurysm located far from the genu of the corpus callosum should raise the suspicion of either a mycotic or traumatic origin. Pertuiset and coworkers classified the sites of origin of DACA (16) aneurysms as follows :

- I. Immediately distal to A.Com artery
- II. At the origin of the frontopolar artery.
- III. At the origin of the callosomarginal.
- IV. On the pericallosal artery distal to III.
- I. On the callosomarginal artery.

Type I and II are called infra or sub callosal and Type III, IV and V are called supracallosal. Reviews stress that patients with distal anterior cerebral artery aneurysms have a high incidence of multiple aneurysms (8,) (17) (25). In the series that were reviewed 37.5% of patients with DACA aneurysms have multiple aneurysms.

Incidence of multiple aneurysms in patients with DACA aneurysms

Series	No. of Patients	Multiple aneurysms (%)
Synckem and Drake (1973)	24	25
Nukin and Aiba (1978)	26	34.6
Yoshimoto et al (1979)	34	43.3
Yasargil (1984)	23	52.2
Wisoff and Flamm (1987)	20	55.5
Kawamura et al (1988)	29	34.5
Ohno et al (1990)	42	42.9
Hernesneimi et al (1992)	84	46.4

Clinical presentation

The most common presentation of DACA aneurysms is subarachnoid hemorrhage, with or without neurological deficit. However, intracerebral hemorrhage commonly occurs after rupture of DACA aneurysms, presumably because the aneurysm is just apposed to the cerebral hemispheres as well as because of the relative paucity of related subarachnoid cisterns. It is often difficult to clinically differentiate the subarachnoid hemorrhage caused by DACA aneurysm from one of the anterior communicating artery. DACA aneurysm may also present with intraventricular hemorrhage, corpus callosal haemorrhage or interhemispheric subdural haematoma (2) (6).

There is, however, a high incidence of pyramidal signs, especially a crural predominant hemiparesis or contralateral lower extremity monoapresis. This sign may be transient and should be looked for early.

DACA aneurysms may also present with mental deterioration and urinary incontinence, simulating a frontal lobe tumor or normal pressure hydrocephalus. The full syndrome produce by occlusion of the DACA with sparing of the recurrent artery of Hurbner was first described by Critchely. This consists of a variable neurological deficits, contralateral hemi or monoplegia, superficial sensory impairments, transient aphasia, loss of memory or confusion, sphincteric dysfunction, catatonic posturing, forced grasping and hypokinesia, and visual agnosia if the occlusion extends posterior to the parieto-occipital fissure.

Iatrogenic occlusion of a major branch of the distal anterior cerebral artery does not invariably result in a deficit, however. Synckers and Drake reported four cases in which there was no deficit following occlusion of the pericallosal or callosomarginal artery.

Laitinen and Snellman reported mental confusion in one-half and papilloedema in about one-third of their 14 patients, 13 of whom presented with a subarachnoid hemorrhage.

Other manifestations include intraventricular hemorrhage and compression of the optic nerve by an inferiorly directed frontopolar aneurysm, as well as the incidental finding of a DACA aneurysm during arteriography for unrelated symptoms (3).

The results of surgical treatment of DACA aneurysms have generally been good. In the literature, operative mortality ranges from 0 to 25 percent (3) (12) (21) (23) (26). Fortunately with technical advances in microsurgery and anaesthesia the mortality and morbidity are decreasing (8) (14) (17) (21) (25).

Surgical approaches

Aneurysms that arise immediately distal to the anterior communicating artery or at any point proximal to the middle of the genu of the corpus callosum are within the operating field of the anterior communicating artery and can be approached subfrontally or pterionally. Laitinen and snellman operated on 10 of their patients who had a DACA aneurysm through a subfrontal approach by

locating the internal - carotid artery and following the ACA to the pericallosal bifurcation. These and other authors have pointed out the difficulty of this approach. All other series have used an interhemispheric approach as described by Yasargil (26) and Carter and Wilson et al. This surgical approach is recommended for any DACA aneurysm distal to the midline of the corpus callosum. Preoperative treatment is identical to that for any other intracranial aneurysm.

Shucart (24) uses three different approaches for DACA aneurysms. For those on A2 segment just distal to A.Com artery a standard pterional craniotomy is used. For DACA aneurysms more than 1cm. distal to A.Com artery a basal frontal interhemispheric approach is used. For more distal aneurysms a direct interhemispheric approach is used.

A troublesome problem in the interhemispheric approach is that of ascending veins which often restrict the working area along the falx even though an exposure width of only 20mm is sufficient. In cases it is not possible to work between the veins, an attempt should be made preserve the larger veins.

As the fundus of the aneurysm is usually buried in one or both cingulate gyri, it is very important to limit lateral retraction of the right hemisphere to a few millimeters, so as not to avulse the fundus away from the parent artery.

Removal to Hematoma

Hematoma should be removed early in dissection to provide additional working room. If the hematoma has penetrated the ventricle, its removal will allow the ventricle to collapse and further decompress the brain. Hematoma immediately around the aneurysms, however, should be left until proximal to distal control of the parent arteries has been gained.

Identification of parent arteries

The depth of the falx will vary and cannot be used as a guide to identification of the corpus callosum cistern. When the falx is shallow, exposure may be more difficult as the adjacent gyri on each hemisphere tend to adhere by their pial surfaces.

Ideally, proximal control should be gained first, but in cases of distal anterior cerebral artery aneurysm this has usually not been possible. Exposing the aneurysm between the cerebral hemispheres generally brings the surgeon to the parent arteries distal to the aneurysm. Some confusion may be encountered distinguishing the pericallosal arteries from the frontopolar callosomarginal or even more superficial arteries, as these arteries are paired and variable in size. The cingulate gyri may be very adherent and be mistaken for the corpus callosum.

Identification of the pericallosal arteries depends upon the recognition of the corpus callosum cistern with its transversely running, parallel, white fibres. By following a cortical artery proximally, one has good method for finding the

pericallosal artery. With identification of the pericallosal arteries, dissection is continued within the corpus callosum cistern until the aneurysm is approached. Attention should then be directed to the proximal side of the aneurysm and both pericallosal arteries exposed to provide proximal control with temporary clips should premature rupture occur.

As the fundus of the aneurysm is usually extended to the right or left side and fixed to the cingulate gyrus, the exploration of the A2 segments proximal to the aneurysm can be accomplished either by passing along the opposite cingulate gyrus or by dissecting the arachnoid and pia around the dome of the aneurysm and mobilizing it.

Aneurysm dissection

With proximal and distal control of the arteries assured, the surgeon may begin dissection of the neck of the aneurysm. In situations where the aneurysm is covered by the cingulate gyrus, it may be helpful to perform a small subpial resection of the gyrus to expose the aneurysm fundus. Each pericallosal artery and each frontopolar or callosomarginal artery, as the case may be, must be separated from the neck of the aneurysm prior to the application of a clip. Sclerosis of the neck of the aneurysm and encroachment of the lumen of the aneurysm or the lumen of the arterial branches cause difficulty in adequately defining the neck of the lesion.

Aneurysm clipping

As with aneurysms at other locations, the aneurysm is best clipped by a technique of successive bipolar coagulation followed by application of a clip, further coagulation as necessary, and reapplication of a clip, until satisfactory clip placement has been achieved.

Because these lesions are often broad based on sclerotic, it may be advisable to use temporary clips, open the aneurysm to remove the atheromatous contents, coagulate, and then apply a permanent clip. Liberal use of papverine to the anterior cerebral arteries is indicated throughout the procedure as these small arteries are especially vulnerable to spasm.

Fundus resection

Following clipping, the fundus is resected, further bipolar coagulation performed as necessary, and adequate clip placement ascertained. All haematoma should be removed from the corpus callosum cistern and the arteries freed from any restraining attachment that might kink or distort them with release of retraction. With good haemostasis the wound is closed.

Summary

In summary, the steps in the treatment of a distal anterior cerebral artery aneurysm include :

1. Right paramedian frontal craniotomy. Left or right pterional and paramedian craniotomy, if additional aneurysms are to be clipped.
2. Dural flap refracted medially without compromise of superior sagittal sinus.
3. Preservation of ascending veins when possible. Release of 20-30cc cerebrospinal fluid through a lumbar drain.
4. No more than a few millimeters (5-10mm) retraction of the mesial right frontal lobe.
5. Identification of the pericallosal arteries in the corpus callosum cistern, distal to aneurysm.
6. Removal of intracerebral and intraventricular haematoma if present.
7. Exposure of the parent arteries proximal to the aneurysm.
8. Dissection of the aneurysm neck and identification of all arteries.
9. Separation of the adhesion between two pericallosal arteries.
10. Clipping of aneurysm neck, fundus resection, coagulation and replacement of the clip.
11. Liberal use of papaverine.
12. Haemostasis and closure.

RESULTS AND ANALYSIS

Incidence

A total of 936 patients were admitted and treated in our institute for subarachnoid haemorrhage due to ruptured intracranial aneurysms during the period April 1984 to January 1998. These patients had a total number of 1065 aneurysms. Of these patients 27 had DACA aneurysms and constituted our study group.

DACA aneurysms thus constituted 2.6% of all surgically treated aneurysms. Multiple aneurysms were present in 7 of these patients and among these patients 2 had incidental DACA aneurysms.

Age

The majority of patients belonged to fifth and sixth decades of life. There was one patient of less than 20 years of age.

Age	Number
1-10	-
11-20	1
21-30	2
31-40	1
41-50	11
51-60	8
61-70	3
71-80	1
Total	27

Sex

The male, female ratio was approximately equal as has been reported in other series.

Male	14
Female	13
Total	27

Presentation

Bleed was the most common mode of presentation with 25 of the 27 patients giving history of bleed. In the remaining two patients, bleeding was due to rupture of another intracranial aneurysm.

Among the patients who presented with bleed, the majority had subarachnoid haemorrhage alone. In addition to the bleed one patient had paraparesis, another had urinary incontinence as the presenting symptom.

Presentation	Number	Percentage (%)
SAH	13	48
SAH + ICH	6	22
ICH	4	15
ICH+IVH	2	7.5
Incidental	2	7.5

Past history of migraine

A definite past history of migraine was available in 3 patients constituting 11%.

History of rebleed

Five of the patients (20%) gave history suggestive of rebleed. Four of these patients had 2 episodes in one week, whereas the fifth patient has three episodes in 2 weeks.

History of warning leaks

None of the patients gave history suggestive of warning leaks.

Activity during bleed

In fourteen of the patients, various form of exertion preceded the bleed. These included lifting weights, walking, straining for defecation etc. In the others, the bleed occurred while the patient was resting.

Associated anomalies

DACA aneurysms are reported to have a high incidence of associated anomalies. Similar finding were noticed in this series also.

AVM	=	1
Azygos ACA	=	1
Polycystic kidney	=	1
Systemic Hypertension	=	6

The AVM was in the right cingulate gyrus. One patient was a known case of cerebral palsy.

Multiple aneurysms

Seven of the 27 patients had multiple aneurysms, as follows :

MCA	=	3
PCOM	=	2
Basilar top	=	1
ACOM	=	1

Preoperative grading

All the patients were graded preoperatively according to WFNS grading system. Majority of the patients were in grade I (19 out of 27).

Grade	Number	Percentage (%)
Grade I	19	70
Grade II	4	15
Grade III	2	7.5
Grade IV	2	7.5
Grade V	-	-

Not all patients in Grade I with a GCS scale of 15/15 were free of deficits. One patient had hemiparesis and another patient had pre existing cerebral palsy with quadriparesis.

CT Scan findings

Sub arachnoid haemorrhage was detected in 13 cases. 10 of these patients had blood in interhemispheric fissure. In 6 patients there was both subarachnoid haemorrhage and intracerebral haematoma. In all cases the intracerebral

haematoma was in the frontal lobe. One patient had bilateral medial frontal intracerebral haematoma. In three cases enhancement suggestive of DACA aneurysms was seen in the CT Scan. The scan was done on an average of less than 10 day after the bleed. Two patients had intraventricular haemorrhage in the III ventricle and both these cases were associated with intracerebral haemorrhage. In none of the 25 cases who presented with history of bleed, was the CT Scan normal. In 2 patients DACA aneurysms was not the source of bleed.

CT Scan findings	Number of cases
SAH	13
SAH + ICH	6
ICH	4
ICH+IVH	2
Normal	-
Infarct	1
Hydrocephalus	1

Size of the aneurysms

Size	Number	Percentage (%)
Small	14	52
Large	13	48
Giant	-	-

Side of the aneurysms

There was a preponderance of the left side.

Side	Number	Percentage (%)
Right	10	37
Left	17	63

Etiology of the aneurysms

In the vast majority (25/27) the etiology was considered to be 'congenital'.

In one patient the aneurysms was of mycotic origin; the patient was a known case of cyanotic heart disease with infective endocarditis. In another patient the aneurysms was due to an arteriovenous malformation of cingulate gyrus

Vasospasm

Clinical vasospasm was observed in 5 patients and all these patients had angiographic vasospasm also. The incidence of angiographic vasospasm alone is 18.5% (5/27).

Focal - Nil
Segmental - 5
Diffuse - Nil

The vasospasm affected the A2 segments in all cases.

Site of the aneurysms

Majority of the aneurysms arose at the origin of callosomarginal (19/27).

Site	Number
Type I - Immediately distal to ACOM artery	1
Type II - At origin of frontopolar	4
Type III - At origin of callosomarginal	19
Type IV - On Pericallosal	2
Type V - On callosomarginal	1

Surgery

All the aneurysms were clipped using standard microsurgical techniques.

The approaches used were as follows :

Fundus projection

Adherent to frontal lobe - 20
 Buried in frontal lobe - 4
 Free - 3

Preoperative findings

Peroperative evidence of atheromatous vessels were seen in five cases. There was one associated AVM. Preoperative rupture occurred in six patients and were managed appropriately. The outcome was not altered by the preoperative rupture.

Follow up

All the patients were requested to come for follow up. Of these 21 patients responded either by coming for the follow up or by replying to a detailed

questionnaire. There was one operative mortality and the remaining five patients were lost of follow up.

Surgery

All the aneurysms were microsurgically clipped. The approaches were :

Interhemispheric	-	26
Basal frontal interhemispheric	-	1
Pterional	-	Nil

Multiple aneurysms were tackled through an extended craniotomy or were operated in a later date.

Check angiogram was done in five of the patients either during earlier follow ups or recently. Check angiograms are not done routinely in this institute as the aneurysmal sac is punctured and opened after the clipping.

The average hospital stay of all the twenty seven patients was 15 days suggesting a favourable outcome.

Outcome

Outcome was graded according to the glasgow outcome scale (GOS).

- 5 - Good recovery.
- 4 - Moderate disability (disabled but independent).
- 3 - Severe disability (conscious but disabled).
- 2 - Persistent vegetative state.
- 1 - Death.

The mean follow up was 2.6 years. There was one operative mortality.

The overall outcome was as follows at the end of 1 year follow up.

GOS Grade	Number	Percentage (%)
5	18	66.6
4	3	14.8
3	-	-
2	-	-
1	1	3.7

Among the five patients lost for follow up 4 were discharged in GOS Grade 5 and one patient was discharged in GOS Grade 2. The patient who was discharged with a GOS Grade 2 and who was lost to follow up had bilateral anterior cerebral artery territory infarct. The outcome at five years was similar to the outcome at one year except that 2 more patients who had a GOS Grade 5 at one year were lost to follow up.

Other complication noted in this series as fresh post operative problem were :

Behavioural changes	- 7
Contralateral lower limb weakness	- 10
Paraparesis	- 2
Meningitis	- 1

Most of these changes were transient and improved completely by the time of discharge, except in 3 patients who had persisting contralateral lower limb weakness.

DISCUSSION

Review of literature of various series reveals that the distal anterior cerebral artery aneurysms are rare and comprise between 2.0 and 9.2 percent (mean 4.4 percent) of all intracranial aneurysms (13) (16).

In this series 27 DACA aneurysms are being reported. It forms 2.4% of all surgically treated intracranial aneurysms in our institute during the period of study.

Comparing the data from different series with more than 20 DACA aneurysms (17).

Series	No. of patients with DACA aneurysms	Incidence (%)
Snyckem and Drake (1973)	24	5.5
Nukai and Aiba (1978)	26	-
Yasargill (1984)	23	2.3
Wisoff and Flamm (1987)	20	4.1
Kawamura et al (1988)	29	4.1
Onho et al (1990)	42	9.2
Hernesinemi et al (1992)	84	5.5
Present (1998)	27	2.4

Age

The majority of patients were in the fifth and sixth decades of life.

Series	No. of patients with DACA aneurysms	Mean Age
Yasargil	23	44.4
Ohno et al	42	54.0
Hernesniemi	84	48.6
Present	27	47.9

Sex

The sex incidence has been seen to be approximately equal in this series.

Most series however report a slight male preponderance (8).

Series	Male : Female
Yasargil	15 : 8
Ohno et al	18 : 24
Hernesniemi	43 : 41
Present	14 : 13

Associated Anomalies

DACA aneurysms have been reported to be associated with a variety of anomalies. The reported incidence of co-existing disorders is as high as 37.5 percent. In this series, six patients had systemic hypertension (22.2%). Hernesniemi et al reported 33% incidence of hypertension in their series of DACA

aneurysms. One patient in our series had polycystic kidney and this association has been reported by various other authors.

Presentation

Various studies indicate that although majority of patients present with rupture of the aneurysms, DACA aneurysms can also be an incidental finding. The DACA aneurysms has been known to be associated with other aneurysms. As in other series', MCA aneurysms were the ones most commonly associated with DACA aneurysms (8) (17) (25) In our series also; it was seen in 3 of our patients (11.1%). One patient in our series had a basilar top aneurysm also. In both the patients who were detected to have an incidental DACA aneurysm, the aneurysm which had bled was the one at the MCA bifurcation.

Intracerebral haematoma

Higher incidence of intracerebral haemorrhage was noted in our series also (37%). A total of ten patients had intracerebral haemorrhage involving the frontal lobes.

Rebleeding

Five of the patients (20%) gave history suggestive of rebleed. Early surgery is therefore advised. Two of the patients who gave history of rebleed were in WFNS grade 4 when first seen. Both improved neurologically, before being taken up for surgery.

Vasospasm and cerebral infarction

Incidence of vasospasm in DACA aneurysm is approximately the same as that of other aneurysms. In this series the incidence of angiographic vasospasm was 18.5% (5/27). Four of these patients had evidence of ischaemic neurologic deficits. One patient had CT Scan evidence of infarction.

Location of aneurysms

As in other series, the most common location of DACA aneurysm in our series, was at the origin of callosal marginal artery (Type III).

The following chart compares the incidence of the type III aneurysm in various series.

Series	No. of patients with DACA aneurysms	No. of type III %Aneurysm	Incidence
Hernesniemi	84	72	83.3
Ohno	42	34	89.5
Yasargil	23	16	69.7
Present	27	19	70.4

Multiple DACA aneurysms

Several series report multiple DACA aneurysms (8) (17) (26). In the 84 patients of Hernesniemi series there were 92 DACA aneurysms. In the 42 patients

of Ohno series there were 49 DACA aneurysms. However in this series there was no instance of multiple DACA aneurysms, although there were aneurysms at other sites.

Multiple aneurysms

The incidence of multiple aneurysms in this series has been 25.9% (7/27).

This is low when compared to other series (8) (17).

Series	Incidence of multiple aneurysms
Ohno et al	42.9%
Hernesniemi	46.4%
Yasargill	52.2%

Outcome

The outcome of surgically treated DACA aneurysms does not differ much from other aneurysms when standard microsurgical techniques are used. Comparing our series results with a few of the well published series.

Series	Good	Moderate	Severe	Vegetative	Death
Yasargill (1984)	20	1	2	-	-
Ohno et al (1990)	36	-	2	-	4
Hernesniemi et al	38	10	5	-	12
Present (1998)	18	3	-	-	1

The Hernesniemi series results does not include incidental DACA aneurysms. The following factors were considered to be of prognostic significance.

1. Timing and outcome

10 out of the 25 patients with ruptured DACA aneurysms were operated between the first and second weeks. This indicates that the time period between aneurysms rupture and surgery was more in our series of DACA aneurysms.

No definite correlation could be obtained in most of the patients with regard to the timing of surgery and outcome.

Timing of surgery and outcome (GOS)

	No.	1	2	3	4	5
1-3 days	-	-	-	-	-	-
4-7 days	3	3	-	-	-	-
1-2 weeks	10	4	4	2	-	-
2-4 weeks	8	4	1	1	1	1
1-3 months	4	3	-	1	-	-
> 3 months	-	-	-	-	-	-

2. Presentation and outcome

No correlation could be obtained regarding the presentation and outcome. The two patients with intraventricular haemorrhage did not have any worse prognosis.

	No.	1	2	3	4	5
SAH	13	5	1	-	-	1
ICH	4	2	2	-	-	-
SAH + ICH ⁶	5	-	1	-	-	
IVH	2	2	-	-	-	-
Incidental	2	2	-	-	-	-

3. Size of the aneurysms

The outcome of patients also did not vary with regard to the size of the aneurysms.

	No.	1	2	3	4	5
Large	13	7	3	2	-	1
Small	14	9	2	3	-	-

4. Preoperation grade and outcome

Patients with a better WFNS grade pre-operatively, tended to have a better outcome.

	No.	1	2	3	4	5
I	19	13	3	3	-	-
II	4	1	3	-	-	-
III	2	-	-	1	-	1
IV	2	1	-	-	1	-
V	-	-	-	-	-	-

5. Vasospasm and outcome

Angiographic vasospasm is probably associated with a poor outcome.

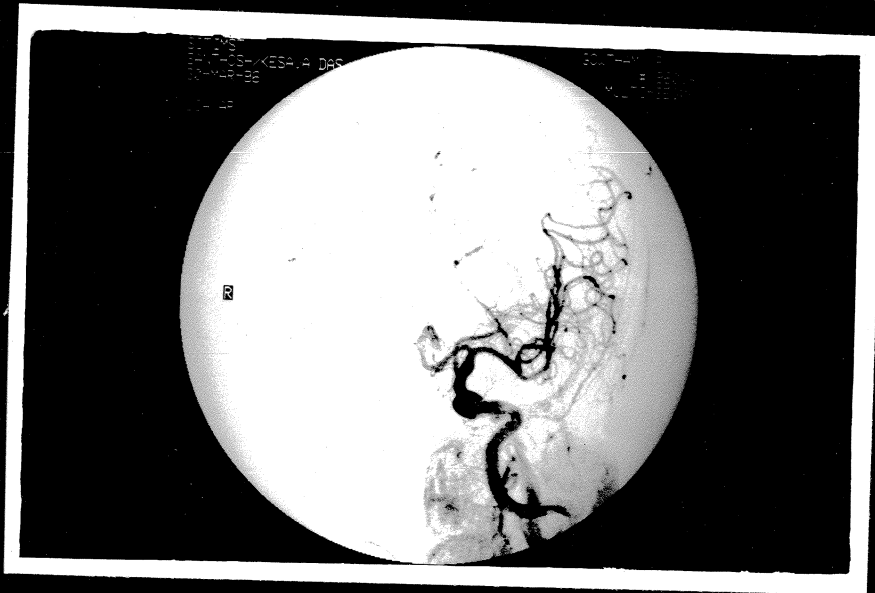
	No.	1	2	3	4	5
Clinical	3	3	-	-	-	-
Angiographic		5	3	1	-	-1

In addition to the above parameters the following parameters were also studied, and were not found to have an influence on the outcome.

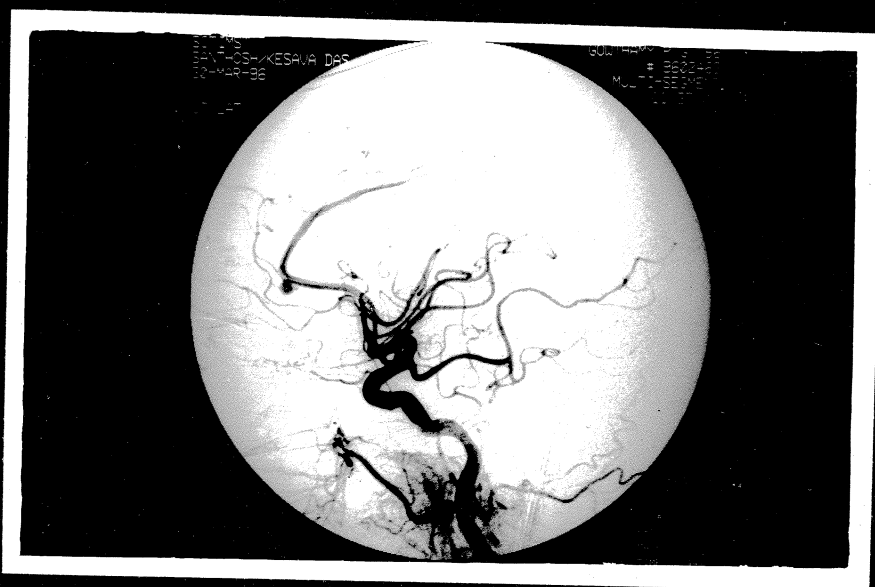1. Associated anomalies
2. Intraoperative rupture
3. Location of the aneurysm
4. Age
5. Sex
6. Rebleed
7. Multiple aneurysms

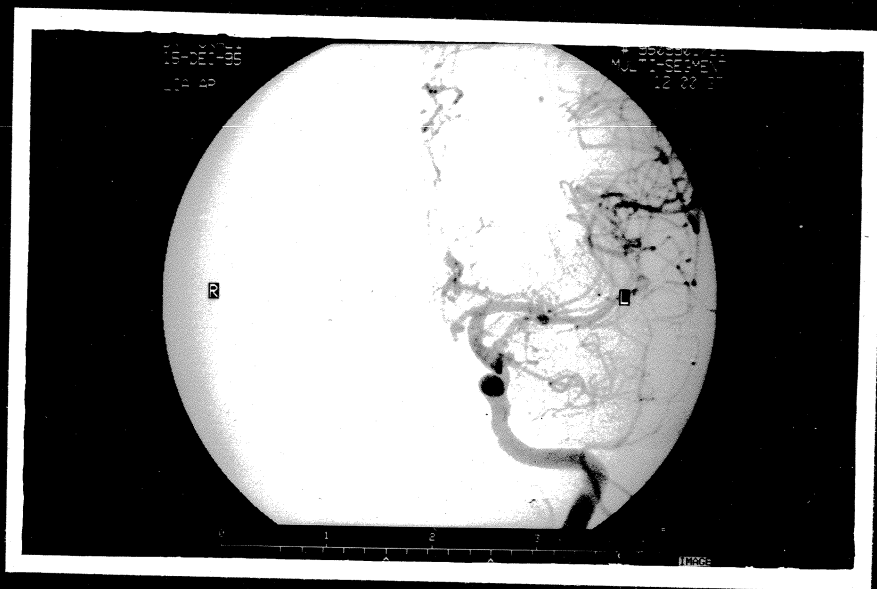
SUMMARY AND CONCLUSIONS

- Distal anterior cerebral artery aneurysms are rare intracranial aneurysms (2.4%).
- The male-female ratio is approximately equal.
- The majority of patients belong to the fifth and sixth decades of life.
- Distal anterior cerebral artery aneurysms are commonly associated with other aneurysms; seven out of twenty seven patients had aneurysms at other sites. However no patients had multiple aneurysms in the distal anterior cerebral artery.
- Distal anterior cerebral artery aneurysms may be associated with various systemic anomalies like hypertension or polycystic kidney.
- Bleed accounts for majority of the clinical presentation (92.6%).
- There is a high incidence of intracerebral haemorrhage (44.5%).
- The aneurysms in all twenty seven patients were saccular in contrast to other reports.
- Majority of the aneurysms were found to arise at the site of origin of callosomarginal artery (19/27).
- Majority of the aneurysms are either adherent to or buried in the frontal lobe.
- The surgical treatment of the aneurysms presents special difficulties because of factors like narrow interhemispheric space, adhesion of cingulate gyri and adherence of these aneurysms to frontal lobes.
- All the aneurysms in this series could be clipped in contrast to some of other series.
- Transient behavioural changes and contralateral lower limb weakness are common after surgery.
- Distal anterior cerebral artery aneurysms have been earlier described as malignant aneurysms because of their poor outcome. However with current microsurgical techniques excellent results can be obtained in the large majority of patients.

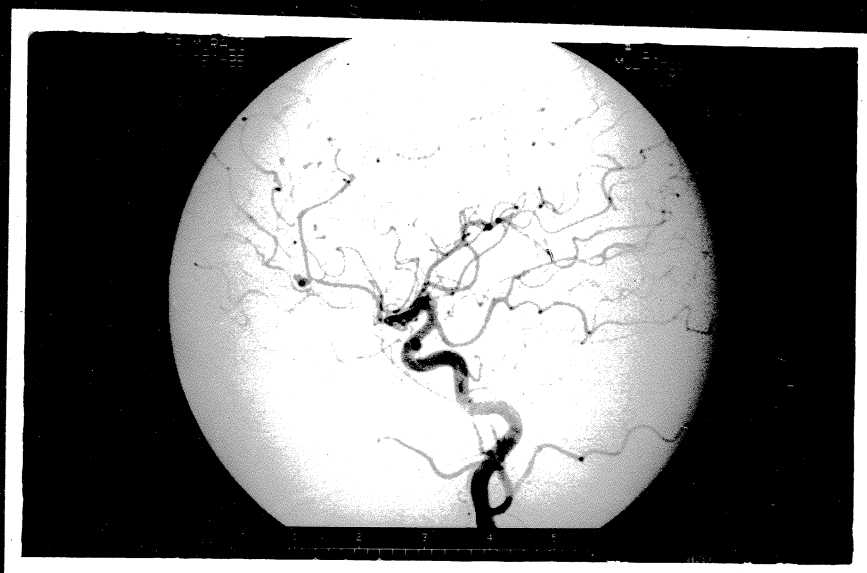


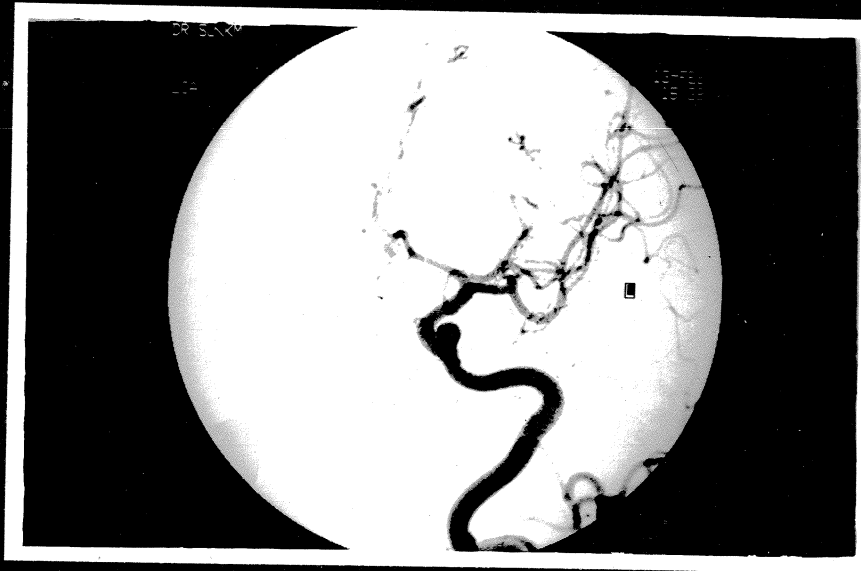
*DACA aneurysm arising at the origin of callosomarginal artery-
Angiographic appearance in AP and lateral views*



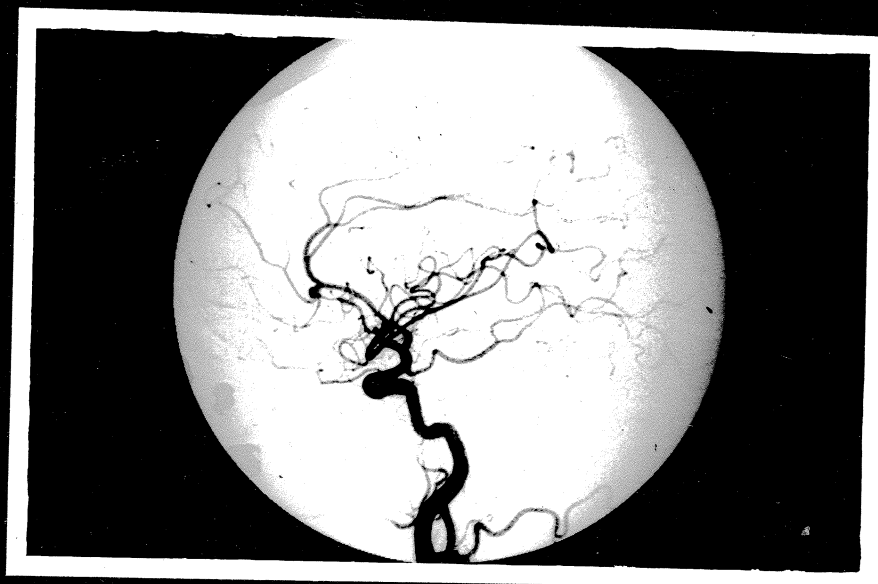


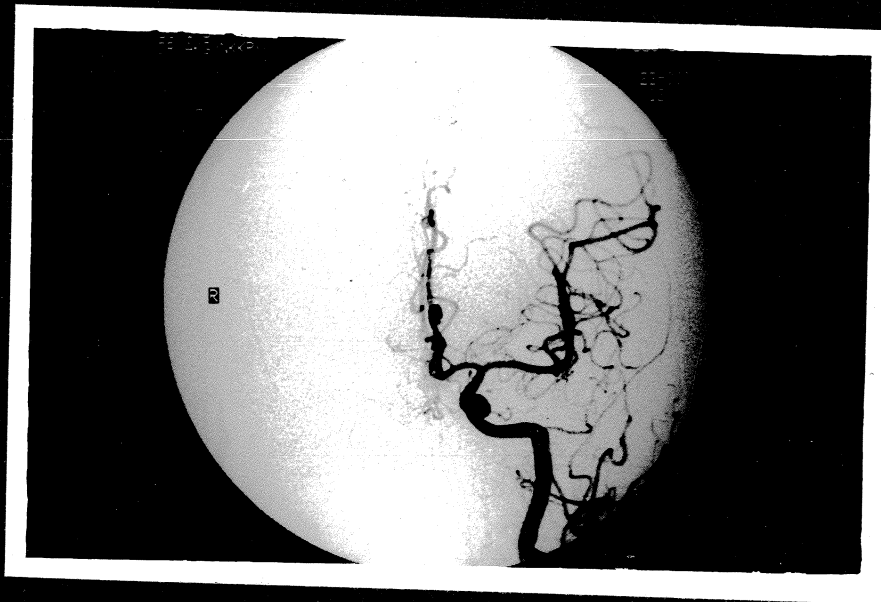
*DACA aneurysm arising at the origin of fronto-polar artery -
Angiographic appearance in AP and lateral views*






*DACA aneurysm at the origin of fronto-polar artery
with vasopasm of pericallosal arteries-
Angiographic appearance in AP and lateral views*





*DACA aneurysm arising on the pericallosal artery -
Angiographic appearance in AP and lateral views*



REFERENCES

1. Baptista AG : Studies on the arteries of brain : II : The anterior cerebral artery : Some anatomic features and their clinical implications. *Neurology*, 13 : 825-835, 1963.
2. Batjer HH, Samson D : Distal anterior cerebral artery aneurysms, in *Neurosurgical Operative Atlas, Vol.2*, Baltimore, Williams and Wilkins, 1992, pp. 119-132.
3. Becker DH, Newton TH : Distal anterior cerebral artery aneurysms. *Neurosurgery*, 1979; 4 : 495-503.
4. Crompton MR : The pathogenesis of cerebral aneurysms. *Brain*, 1966; 89 : 797-814.
5. Dunker RO, Harris AB : Surgical anatomy of proximal anterior cerebral artery. *J Neurosurgery*, 1976; 44 : 359-367.
6. Fein JM, Rovit RL : Interhemispheric subdural haematoma secondary to haemorrhage from a callosal-marginal artery aneurysm. *Neuroradiology*, 1 : 183-186, 1970.
7. Fisher RG, Ciminello V : pericallosal aneurysms. *J Neurosurgery*, 1966; 25 : 512-515.
8. Hernesniemi J, Tapaninaho A, Vapalahti M, et al : Saccular aneurysms of the distal anterior cerebral artery and its branches. *Neurosurgery*, 1992; 31 : 994-999.
9. Huber P, Braun J, Hirschmann D, Agyeman JF : Incidence of berry aneurysms of the unpaired pericallosal artery : Angiographic study. *Neuroradiology*, 1980; 19 : 143-147.
10. Krayenbuhl HA, Yasargil MG : Radiological anatomy and topography of the cerebral vessels (the cerebral arteries) in *Cerebral angiography*. Philadelphia, JB Lippincot, 1968; ed.2 : 20-84.
11. Kwak R, Niizuma H, Hatanaka M, Suzuki J : Anterior communicating artery aneurysms with associated anomalies. *J Neurosurgery*, 1980; 52 : 162-164.

12. Laitinen L, Snellman A : Aneurysms of the pericallosal artery : A study of 14 cases verified angiographically and treated mainly by direct surgical attack. *J Neurosurgery*, 1960; 17 : 447-458.
13. Locksley H, Sahs AL, Knowler L : Report on the cooperative study of intracranial aneurysms and subarachnoid haemorrhage. Section II. General survey of cases in the central registry and characteristics of the sample population. *J Neurosurgery*, 1966; 24 : 922-932.
14. Mann KS, Yue CP, Wong G : Aneurysms of the pericallosal - callosomarginal junction. *Surgical Neurology*, 1984; 21 : 261-266.
15. Marino R Jr. : The anterior cerebral artery : I. Anatomoradiological study of its cortical territories. *Surgical Neurology*, 1976; 5 : 81-87.
16. Nelson M Oyesikn, Daniel L Barrow, in *Neurosurgery*, second edition by Robert H Wilkins and Setti S. Rengachary, 1997; p.2327.
17. Ohno, K. Monma S. Suzuki R. et al : Saccular aneurysms of the distal anterior cerebral artery. *Neurosurgery*, 1990; 27 : 907-913.
18. Perlmutter D, Rhoton AL Jr. : Microsurgical anatomy of the distal anterior cerebral artery. *J Neurosurgery*, 1978; 49 : 204-228.
19. Rhoton AL Jr., Saeki N, Perlmutter D, Zeal A : Microsurgical anatomy of common aneurysm sites. *Clinical Neurosurgery*, 1978; 26 : 248-306.
20. Shucart WA : Distal anterior cerebral artery aneurysms, in Appuzo MLJ (ed) : *Brain surgery. Complication avoidance and management*. New York, Churchill Livingstone, 1993; 1035-1040.
21. Sindou M, Pelisson-Guyotat I, Mertens P, et al : Pericallosal aneurysms. *Surgical Neurology*, 1988; 30 : 434-440.
22. Stebhens WE : Etiology of intracranial berry aneurysms. *J Neurosurgery*, 1989; 70 : 823-831.
23. Thoman DGT, Paterson A : Results of treatment of pericallosal aneurysms. *J Neurol Neurosurg Psychiatry*, 1975; 38 : 827.

24. Ugur Ture, Yasargil MG, Ali T Krisht : The arteries of the corpus callosum : A microsurgical anatomic study. *Neurosurgery*, 1996; 39 : 1076.
25. Wisoff JH, Flamm ES : Aneurysms of the distal anterior cerebral artery and associated vascular anomalies. *Neurosurgery*, 1987; 20 : 735-741.
26. Yasargil MG, Carter LP : Saccular aneurysms of the distal anterior cerebral artery. *J Neurosurgery*, 1974; 40 : 218-223.
27. Yasargil MG : Surgery of the intracranial aneurysms and results in *Microneurosurgery*, Vol. II, clinical consideration. Stuttgart; George-Thieme Verlag, 1984; 224-231.
28. Yoshimoto T, Uchida K, Suzuki J : Surgical treatment of distal anterior cerebral artery aneurysms, *J Neurosurgery*, 1979; 50 : 40-44.