

SREE CHITRA TIRUNAL INSTITUTE FOR MEDICAL SCIENCES AND TECHNOLOGY

Thiruvananthapuram – 695011, India



WORK RECORD

Name : DR ROHIT DUTTA

Course : MCh

Discipline : CARDIOVASCULAR AND THORACIC SURGERY

Year of Study : Jan 2013 – Dec 2015

CERTIFICATE

I hereby certify that I have performed / assisted all the procedures listed in the work record.

Place: Thiruvananthapuram

Signature :

Date: SEP 2015

Name : **DR ROHIT DUTTA**

FORWARDED

The above candidate has satisfactorily carried out the minimum required procedures

Place: Thiruvananthapuram

Signature :

Date: Sep 2015

Name : (Prof.Jayakumar K)

Head of the department

Department of CVTS

SCTIMST,
Thiruvananthapuram

PROCEDURES PERFORMED

PROCEDURE	NUMBER OF CASES
ASD CLOSURE	2
VSD CLOSURE	1
PE DRAINAGE	1
PD INSERTION	3

PROCEDURES ASSISTED

ADULT CARDIAC SURGERY

PROCEDURE	NUMBER OF CASES
CABG	137
OPCAB	4
CABG + LV PLICATION	2
DVR	16
ASD+CABG	1
AVR + CABG	11
MVR + CABG	5
DVR + CABG	1
CABG + MV REPAIR	4
LA MYXOMA EXCISION	1
SUPRACORONARY ASC AO REPLACEMENT	1
MODIFIED BENTALL'S PROCEDURE	7
MODIFIED BENTALL'S PROCEDURE+CABG	1
AVR	25
AVR+ASD	1
AVR+VSD+CABG	1

PROCEDURES ASSISTED ADULT CARDIAC SURGERY

PROCEDURE	NUMBER OF CASES
MVR+TVA	2
MVR	49
MVR + TVA	2
MV REPAIR	6
ASD CLOSURE + MVR	4
DVR + TVA	2
ASD CLOSURE	19
ASD CLOSURE + TVA	1
THORACOTOMY ASD CLOSURE	1

PROCEDURES ASSISTED

CONGENITAL HEART SURGERY

PROCEDURE	NUMBER OF CASES
MINI STERNOTOMY ASD CLOSURE	2
ASD CLOSURE	15
TRUNCUS ARTERIOSUS	2
KAWASHIMA REPAIR	1
AORTIC VALVE REPAIR	1
VSD CLOSURE	13
ARCH REPAIR	2
RASTELLI PROCEDURE	1
ICR (TOF)	21
ICR + PA PLASTY	9
SCIMITAR	1
ASO	7
ASO + VSD CLOSURE	3
SENNING'S PROCEDURE	2
AVR+SAM EXCISION	1
HEMIMUSTARD+BDG	1
ICR WITH CONDUIT	4

PROCEDURES ASSISTED

CONGENITAL HEART SURGERY

PROCEDURE	NUMBER OF CASES
TCP	4
LCA TRANSLOCATION	4
TAPVC REPAIR	2
COA REPAIR	2
PA BANDING	2
BDG	9
RMBTS	6
EXCISION OF SAM	2
PDA LIGATION	1
DOUBLE SWITCH	2
CAVCD	4
RV PSEUDOANEURYSM EXCISION	1
VSD CLOSURE +AV REPLACEMENT	1

PROCEDURES ASSISTED
THORACIC AND VASCULAR SURGERY

PROCEDURE	NUMBER OF CASES
LOBECTOMY	2
AV FISTULA	1

MISCELLANEOUS PROCEDURE

PROCEDURE	NUMBER OF CASES
EPICARDIAL PPI LEAD PLACEMENT	1
PE DRAINAGE	4
EXPL LAPAROTOMY + ILEO COLIC RES + JEJUNO TRANS ANASTAMOSIS	1
PMMC FLAP REPAIR FOR DSWI	4
HOMOGRAFT HARVESTING AND TRIMMING	8
STERNAL WIRE REMOVAL	1
WOUND DEBRIDEMENT AND SUTURING	2
RE EXPLORATIONS FOR BLEEDING	4

CASES PERFORMED

LIST OF OPEN HEART CASES PERFORMED

S.NO	H.NO	NAME	AGE	SEX	DOS	DIAGNOSIS	PROCEDURE	SUPERVISED BY
1	384022	SOMAN P S	64	M	14/5/2015	ACHD OS ASD,GD LV, SR	TPP CLOSURE OF ASD	DR. VARGEHESE T PANICKER
2	378428	JOBIN MEPPURATHU	17	M	26/06/2015	ACHD,SP VSD,MILD AR,NO PAH,SR	VSD CLOSURE	DR.SABARINATH MENON
3	386607	VISHNU A.	17	M	29/2015	ACHD,OS ASD,GD LV,NC,SR	DC OF ASD	DR.BINEESH KR

CASES ASSISTED

S.NO	H.NO	NAME	AGE	SEX	DOS	DIAGNOSIS	PROCEDURE	SURGEON
1	354294	SAINUDEEN M.	65	M	04/Jan/2013	CAD,TVD,SEV LV DYSFN,OLD AW/IW MI,MILD MR,SR,HTN,DM	CABG X 5 GRAFTS(LIMA-LAD,RSVG-MAJOR DIAGONAL,MAJOR OM,RPDA,RPLB(PDA GRAFT PIGGY BACKED TO PLB GRAFT)	DR. PRAVEEN VARMA P.K.
2	353183	SELVANESAN E.	61	M	08/Jan/2013	SEV CAL AS,MILD AR,CAD-SVD,MILD LV DYSFUNCTION,LBBB	AVR#21 PM,CABG X 2,LIMA TO LAD,RSVG TO MAJ D	DR. PRAVEEN VARMA P.K.
3	250745	SREEKUMAR K.P.	50	M	10/Jan/2013	CAD,S/P PCI TO LAD(2006), DVD, OLD AWMI, MOD LVD, SR, HTN,DM	CABG X 3GRAFTS (LIMA-LAD,RSVG-OM1,OM 2)	DR. PRAVEEN VARMA P.K.
4	309091	OMANA P	32	F	15/Jan/2013	RHD, SEV AR, SEV AS, MOD MS, MILD MR, MILD PAH, GOOD LV, SR	DVR (MVR# 25 SJM + PARTIAL PMLP, AVR # 17 SJ REGENT)	DR. BINEESH K. R.
5	332986	REEDA RAJENDRAN R	45	F	15/Jan/2013	RHD,SEV MR,DIL LA,GD LV, AF,NC	MVR #27 CHVP+PMLP.	DR. VARGHESE T.PANICKER
6	348699	KALADHARAN P	56	M	15/Jan/2013	CAD,DVD,UA,GOOD LV,SR,HTN,SR	CABG X 4 GRAFTS(LIMA-LAD,RSVG-D1,D2,OM1)	DR. JAYAKUMAR K
7	330831	SAINABA BEEVI.J	61	F	16/Jan/2013	RHD,SEV MS, MOD PAH,GOOD LV, AF	MVR#25 SJM	DR. VIVEK V. PILLAI
8	249248	GANESH KUMAR E.	52	M	16/Jan/2013	CAD,TVD,GD LV,SR, DM,HTN, DLP	CABGX 5 GRAFT,LIMA TO LAD,RSVG TO D1,OM1,OM2,PDA	DR. VIVEK V. PILLAI
9	319725	PUSHPALATHA THILAKAN	47	F	24/Jan/2013	RHD,P/OMV(99)SEV CAL RE- MS,MILD AR,SEV TR,MOD PAH,AF,NC	MVR # 23 SJM, TVA 28 MC3 RING	DR. PRAVEEN VARMA P.K.
10	354067	RAJA DAS P	52	M	28/Jan/2013	CAD,DVD, GD LV,DR,DM	CABG X 2G (LIMA-LAD, RSVG-MAJ DIAGONAL)	DR. JAYAKUMAR K
11	343263	SREELATHA L.S.	36	F	30/Jan/2013	MVP OF AML&PML,SEV MR,OS ASD,MILD PAH, GD LV,SR	MV REPAIR(# 28 SADDLE RING)+ ASD CLOSURE	DR. VIVEK V. PILLAI
12	342054	VELLAMMAL N	17	F	30/Jan/2013	SEV MR,GD LV,SR	MVR #25 CHVP WITH PML PRESERVATION	DR. BINEESH K. R.
13	344360	MURUGAYYA SASAYYA	62	M	06/Feb/2013	CAD,TVD, GD LV, SR, DM,HTN	CABGX3 (LIMA-LAD, RSVG- MAJ OM,RPDA)	DR. PRAVEEN VARMA P.K.
14	354155	RAJU A	47	M	14/Feb/2013	POST PTB SEQUELAE,RIGHT LOWER LOBE ASPERGILLOMA; HBSAG+	WEDGE RESECTION OF APICAL SEGMENT OF RT LOWER LOBE	DR. BALASUBRAMONIAM K.R.
15	334073	FATHIMA P	51	F	18/Feb/2013	RHD,SEV MS, MOD PAH,GOOD LV, AF	MVR#27 SJM	DR. VIVEK V. PILLAI
16	337194	RAJU N.	46	M	18/Feb/2013	SEV AR, GD LV, SA VSD, SR	AVR#27 MEDTRONIC +VSD CLOSURE	DR. VIVEK V. PILLAI
17	340155	SUSEELA R	36	F	18/Feb/2013	RHD,SEV MS, MILD AR, MOD PAH,GOOD LV, AF	MVR #27 SJM +PMLP	DR. VARGHESE T.PANICKER
18	354993	VINOD .V.K	54	M	25/Feb/2013	CAD,TVD, GD LV, SR, DM,HTN	CABGX 3GRAFT(LIMA-LAD, RSVG-MAJ DIAG,ACUTE MARGINAL)	DR. JAYAKUMAR K
19	9008705	BIJU V.M.	36	M	27/Feb/2013	RHD, SEV MS, MOD AR, GD LV, SR	DVR (MVR#23 SJM+PMLP,AVR#27CHVP)	DR. PRAVEEN VARMA P.K.
20	350420	CHANDRASEKHARAN NAIR P	57	M	04/Mar/2013	SEV CAL AS, CON LVH, SR	AVR#21 PM	DR. VARGHESE T.PANICKER

21	357311	NIRMALA .A	69	F	07/Mar/2013	CAD,TVD, GD LV, SR, DM,HTN	CABGX 4 GRAFT(LIMA-LAD,RSVG-MAJ DIAG,OM,RPDA)	DR. JAYAKUMAR K
22	347470	SREEKUMAR B.	58	M	08/Mar/2013	CAD,TVD, GD LV, SR, DM,HTN	CABG X5 GRAFT(LIMA-LAD,RSVG-OM, DIAG,RI,RPLB2)	DR. JAYAKUMAR K
23	356687	SUNNY D	47	M	11/Mar/2013	CAD, TVD, ATHEROSCLEROSIS, MOD LV DYS, SR, DM ,HTN, DLP	CABG X 4 GRAFT(LIMA-LAD, RSVG-D1,OM,PDA)	DR. PRAVEEN VARMA P.K.
24	357265	SAINULABDEEN K.	68	M	12/Mar/2013	CAD,TVD, GD LV, SR, DM,HTN	CABGX5 GRAFT(LIMA-LAD,RSVG-MAJ DIAG,MAJ OM,PDA,RI) AND LEFT VENTRICULAR PLICATION	DR. JAYAKUMAR K
25	356687	SUNNY D	47	M	12/Mar/2013	P/CABG	S/P CABG RE EXPLORATION	DR. PRAVEEN VARMA P.K.
26	348502	SUJITHA P.K	28	F	14/Mar/2013	RHD,SEVERE MS,MODERATE MR,MODERATE PAH,AF	MVR#25SJM WITH PMLP	DR. PRAVEEN VARMA P.K.
27	351383	DIVAKARAN A K	71	M	14/Mar/2013	CAD,TVD,GDLV,SR,COPD	CABGX4 GRAFT(LIMA-LAD,RSVG-PRE CRUX,OM,DIAG)	DR. PRAVEEN VARMA P.K.
28	350748	RAJAMMA C.	65	F	15/Mar/2013	CAD,TVD,GD LV,SR,DM,HTN,DLP,LEFT CAROTID STENOSIS	CABG X 6 GRAFT(LIMA-D1,RSVG-LAD,TER D1,MAJ OM, TER OM1, RPDA)	DR. JAYAKUMAR K
29	341177	SAFIYUDEEN M	51	M	18/Mar/2013	RHD,SEVMS,MILD CAD,AF,HTN	MVR#25SJM	DR. VARGHESE T.PANICKER
30	351638	MUTHAMMAL.M	43	F	18/Mar/2013	CAD,DVD,RECENT AWTMI,FAIR LV,SR,DM,HTN,DLP	CABGX 3 GRAFT(LIMA-LAD, TERM OM,PDA)	DR. PRAVEEN VARMA P.K.
31	352608	ASOK KUMAR	48	M	19/Mar/2013	ACHD,SVASD,PAPVC,SVD,GD LV, SR,DM,DLP	CABGX1G(LIMA-LAD) ASD CLOSURE(DOUBLE PATCH REPAIR)	DR. VIVEK V. PILLAI
32	351105	SHEELA S	45	F	20/Mar/2013	CAD,DVD,IWMI,GDLV,SR,DM,HTN,DLP	CABGX 3GRAFT(LIMA-LAD, RSVG-LAD,RPDA)	DR. PRAVEEN VARMA P.K.
33	326101	SURENDRAN K.	47	M	20/Mar/2013	SEV CAL AS, SEV AR, MILD MR, GD LV, SR,NC	AVR#21CHVP	DR. PRAVEEN VARMA P.K.
34	354561	INDIRA.P	42	F	05/Jul/2013	RHD,SEV MS,SEV AS,SEV AR,GDLV,MILD MR, MILD PAH,AF,NC	DVR(MVR # 25 CHVP, # AVR 19 SJR)	DR. PRAVEEN VARMA P.K.
35	353934	SEETHAMMA .N	66	F	05/Jul/2013	P/ CABG	STERNAL WOUND DEBRIDEMENT AND SECONDARY SUTURING	DR. VIVEK V. PILLAI
36	353031	CRUZ .R	58	M	08/Jul/2013	CAD,DVD,OLD IWMI, GDLV,DM,DLP, SR	CABG X 3 GRAFT(LIMA- LAD, RSVG - MAJ DIAGONAL (D2), RCA	DR. PRAVEEN VARMA P.K.
37	357373	RAJESH V.A	22	M	09/Jul/2013	RHD, SEV MS, MOD MR, PAH, SR	MVR(CHVP#25)	DR. PRAVEEN VARMA P.K.
38	353200	VALSALAN T K	40	M	09/Jul/2013	CAD, DVD, MVP, SEV MR, GDLV,MILD PAH, DLP, SR,EX SMOKER	CABG X 2 GRAFT (RSVG-LAD, RAMUS), MV REPAIR # 30 SADDLE RING+ P3 PLICATION,+ PM COMMISUROPLASTY	DR. VIVEK V. PILLAI
39	355381	SANKARAN .T.K	65	M	10/Jul/2013	RHD, SEVCAL MS,CAD,MILD LVD, SR,HTN,SEIZURE DISORDER	MVR # 25 SJM	DR. PRAVEEN VARMA P.K.
40	355320	JEYAKUMAR .K	33	M	25/Jul/2013	RHD,SEV MS,SEV PAH,LA CLOT,GDLV,MILD RVD,AF	MVR#31 SJM + PMPL+ LA CLOT REMOVAL	DR. VARGHESE T.PANICKER
41	356713	SELVI S	29	F	26/Jul/2013	RHD, MVP OF AML(A3 SEGMENT) SEV MR, ? P/ IE,	MV REPAIR (PARA COMMISSURAL	DR. VIVEK V. PILLAI

						MILD TR, GD LV , NO PAH, SR	ALFIERI REPAIR + # 26 SADDLE RING ANNULOPLASTY)	
42	352039	ANTHRAYOSE M.	55	M	29/Jul/2013	CAD, TVD, SEV CAL AS, MILD AR,GDLV, SR,DLP	AVR # 23 CHVP +CABGX 4 GRAFT(LIMA- LAD, RSVG- MAJ DIAG, MAJ OM , RPDA)	DR. PRAVEEN VARMA P.K.
43	323946	ANIL A.	35	M	30/Jul/2013	ACHD, OS ASD, MOD PAH, GD LV, SR	TANNED PERICARDIAL PATCH CLOSURE OF OS ASD	DR. ASHOK KUMAR C J
44	364518	NISHA EDWARD	28	F	31/Jul/2013	ACHD, SVASD, PAPVC, MILD PAH, SR	ACHD, DOUBLE TANNED PERICARDIAL PATCH REPAIR OF SVASD, PAPVC REROUTING OF RUPV, MILD PAH, SR	DR. BINEESH K. R.
45	348425	RATHEESH K.	24	M	08/Aug/2013	THROMBOSIS OF MV, S/P DVR FOR SEV CAL MS,MOD AR,MOD LVD,SR	RE DO MVR #25 CHVP WITH PREVIOUS INTACT #21 CHVP AVR	DR. PRAVEEN VARMA P.K.
46	354921	RADHINI .R	30	F	12/Aug/2013	RHD,SEV MS,MILD MR,SEV TR,SEV PAH,SR	MVR # 23 CHVP+PMPL+ TV REPAIR 30 MC 3 RING	DR. VARGHESE T.PANICKER
47	346888	SHAJI K B	51	M	12/Aug/2013	RHD,SEV CAL MS,GD LV,ECTATIC CORONARY,DM	MVR# 27 SJM	DR. PRAVEEN VARMA P.K.
48	20791	GOPINATHAN.A.	64	M	13/Aug/2013	RHD,SEV CAL MS,MOD MR,SEV PAH,GDLV,AF,NC,S/P ASD CLOSURE(86)	MVR # 25 SJM+PMLP	DR. PRAVEEN VARMA P.K.
49	9907003	SYAMALA G.	53	F	14/Aug/2013	RHD,S/P PTMC,SEV RE MS,MOD MR,MOD PAH,GDLV, LA CLOT, PFO, AF,NC	MVR # 25 SJM+PMLP+ LA CLOT EXTRACTION+LAAE+ PFO CLOSURE	DR. VARGHESE T.PANICKER
50	219554	ZACHRIA PANICKER.P.T.	69	M	15/Aug/2013	CAD, TVD, S/P CABG, AC MESENTERIC ISCHEMIA	EXPLORATORY LAPAROTOMY+RESECTION OF DISTAL JEJUNUM, ILEUM, CAECUM AND ASCENDING COLON WITH JEJUNO TRANSVERSE ANASTAMOSIS	DR. VIVEK V. PILLAI
51	301359	JAYACHANDRAN P S	29	M	29/Aug/2013	S/P ASD CLS + MV REPAIR + TV REPAIR FOR PAVCD, CLEFT AML (2006), SEV MR, MOD-SEV TR, MOD PAH, FAIR LV, AF	MVR# 33 SJM + PMLP + TV REPAIR (#34 CE CLASSIC RING TV ANNULOPLASTY)	DR. PRAVEEN VARMA P.K.
52	357886	SREEKALA S.	43	F	30/Aug/2013	SEV CAL AS,GDLV,SR,NC	AVR # 19 SJR	DR. PRAVEEN VARMA P.K.
53	366515	SANKARANKUTTY NAIR V.	65	M	03/Sep/2013	ADENOCA RT UL, DM,HT,CAD-S/P CABG(2005)	RT UPPER LOBECTOMY	DR. UNNIKRISHNAN.M
54	356778	PREETHY P.	30	F	04/Sep/2013	RHD,SEV MS,SEV AS,MOD AR,MILD MR,GDLV, SMALL AORTIC ROOT, SR	DVR (AV# 17 SJR+ MV#23 SJM + PMLP)+ AORTIC AUGMENTATION PLASTY(BOVINE PERICARDIUM)	DR. PRAVEEN VARMA P.K.
55	365565	RAVEENDRAN K.	57	M	12/Sep/2013	CAD, SVD, SEV AS, GD LV, SR	AVR # 23 CHVP +CABGX1 GRAFT (OM 3)	DR. VIVEK V. PILLAI
56	314341	SAMEERA C M	26	F	08/Oct/2013	CCHD,TOF,ADD MUSC VSD, PDA, PFO, GOOD PA,NC	ICR+TAP(GP CLOSURE OF DC VSD, DC ADDL VSD, MONOCUSP RECONSTRUCTION OF RVOT) +PDA LIGATION+ PFO MADE RESTRICTRIVE	DR. SABARINATH MENON

57	343397	SWATHY MOHAN	13	F	01/Jan/2014	ACHD, OS ASD, HAPVC OF LEFT PV, GD LV, SR	CS CUT BACK AND TANNED PERICARDIAL PATCH REPAIR	DR. SABARINATH MENON
58	239666	AMMURAJ.R.	8	F	10/Jan/2014	CCHD, TA, LARGE VSD, SEV PS, S/P BDG, GOOD LV, SR	FENESTRATED EXTRACARDIAC FONTAN WITH 22 MM PTFE TUBE GRAFT AND 4 MM FENESTRATION	DR. SABARINATH MENON
59	343510	GOWTHAM G SATHYAN	3	M	21/Jan/2014	ACHD, OS ASD, MODERATE PS, SR	TPP CLOSURE OF OS ASD + PULMONARY VALVOTOMY	DR. SABARINATH MENON
60	372447	B/O SARANYA	0	F	23/Jan/2014	POST OP BT SHUNT WITH STERNAL WOUND INFECTION	STERNAL REWIRING	DR. BAIJU S.DHARAN
61	371682	SREEHARI P.	0	M	24/Jan/2014	CCHD, TGA, L POSED AORTA, CRISS CROSS HEART, LARGE INLET VSD, HYPOPLASTIC RV	ASO + VSD CLOSURE + PFO MADE RESTRICTIVE	DR. BAIJU S.DHARAN
62	371682	SREEHARI P.	0	M	26/Jan/2014	P/ASO	DSC	DR. THOMAS MATHEW
63	326886	VEMPADI MADA SUDALI B.	5	M	30/Jan/2014	SEV SUBVALVULAR AND VAL PS, CON PA ANAT, CS ATRESIA, SA VSD, OS ASD SR	TRANS RA ICR	DR. BAIJU S.DHARAN
64	371801	VELMURUGAN S	1	M	03/Feb/2014	CCHD, TA SEV PS ASD B/L SVC SR	B/L BDG	DR. THOMAS MATHEW
65	338540	AKASHRAJ S R	4	M	03/Feb/2014	ACHD, POST ASD, PFO, GD LV, SR	TPP CLOSURE OF POSTERIOR ASD + DIRECT CLOSURE OF PFO	DR. MRITHYUNJAYA V KALMATH
66	354913	AYYAPPAN .S	1	M	05/Feb/2014	S/P SENNING'S PROCEDURE WITH PERICARDIAL EFFUSION	PERICARDIAL EFFUSION DRAINAGE	DR. SABARINATH MENON
67	357925	FATHIMATH SUHARA	1	F	07/Feb/2014	CCHD, DORV, MULTIPLE VSD, ANEURYSMAL MPA, SEVERE PAH	ICR - TUNNELING OF LV - AORTA + DIRECT CLOSURE OF MULTIPLE VSD + MPA REDUCTION PLASTY	DR. BAIJU S.DHARAN
68	8701054	USHA.R.	53	F	10/Feb/2014	SEV CAL AS,MILD AR,MILD MS, GDLV,SR,HYPOTHYROID	AVR #17 SJR	DR. VIVEK V. PILLAI
69	366368	BHAVYA S B	1	F	11/Feb/2014	ACHD,LARGE SA VSD,SMALL ASD,SEV PAH,GD LV,SR	GP VSD CLOSURE + PDA INTRUPTION	DR. THOMAS MATHEW
70	240909	KAVITHA.K.	20	F	17/Feb/2014	CCHD TOF, GD PA ANATOMY NORMAL CORONARIES, SR	ICR+MONOCUSPRECONSTRUCTION OF RVOT PATCH+TAP	DR. BAIJU S.DHARAN
71	370408	ASWIN P	0	M	25/Feb/2014	ACHD,MULTIPLE VSD,SEV PAH,GD LV,SR	MULTIPLE MUSCULAR VSD CLOSURE+ APICAL EXCLUSION+ REENDOCARDIZATION	DR. BAIJU S.DHARAN
72	369126	SIVARNA VEENA P	6	F	24/Mar/2014	ACHD.SV ASD,SR	WARDEN'S PROCEDURE	DR. MOHAMMED IDHREES A.
73	365572	PREMNATH V.	42	M	02/Apr/2014	CAD, TVD, GD LV,SR, DM, HTN, DLP	CABGX 5 GRAFT(LAD,MAJ DIAG, ACUTE MARGINAL,RPDA,RPLP)	DR. VIVEK V. PILLAI
74	374498	PRASANNA KUMAR K.K.	65	M	03/Apr/2014	CAD, LMCA+TVD, REC ACS (IWMI), GOOD LV, SR	CABG X 5 GRAFTS (LIMA-LAD, RSVG- D1, RI, MAJ OM, DIST RCA)	DR. JAYAKUMAR K
75	375620	RAJAGOPAL D.	59	M	11/Apr/2014	CAD,SVD, GD LV SR,DM	OP CABX1 GRAFT(LIMA-LAD)	DR. JAYAKUMAR K
76	368676	SATHYAN C	64	M	14/Apr/2014	S/P CABG FOR CAD,TVD,DM,HTN,SSI OF MEDIASTINAL WOUND	PM MYOCUTANEOUS FLAP	DR. VARGHESE T.PANICKER
77	374016	THANU PILLAI S	62	M	14/Apr/2014	CAD, TVD, REC AWMIMILD LMCA,SR	CABG X 5 GRAFT(LIMA-LAD, MAJ DIAG, OM, PDA,RAMUS)	DR. JAYAKUMAR K

78	375580	RANGAN K	61	M	16/Apr/2014	SEV AS, MOR AR,CAD, SVD,GD LV, CONCENTRIC LVH,SR,DM	AVR#19 PM, CABG X1 GRAFT(RSVG- LAD)	DR. JAYAKUMAR K
79	373436	KUMARAN POTTY N.	62	M	22/Apr/2014	CAD, DVD, MOD- SEV LV DYSFUNCTION, SEV PAH, SR, DM(RECENT MI) SEV MR	CABGX 1GRAFT(RSVG- DISTAL OM) + MVR 25 PM	DR. VIVEK V. PILLAI
80	370525	BABURAJ .E	55	M	23/Apr/2014	CAD,TVD,SEV LV DYSFUNCTION,MILD PAH,SR(LV ANEURYSM- ANT WALL)	CABGX 3 GRAFT(LIMA-LAD, RSVG-MAJ DIAGONAL,OM) LINEAR PPLICATION OF LV(ANT WALL)	DR. PRAVEEN VARMA P.K.
81	369616	PRINSON J	34	M	23/Apr/2014	RHD, SEV MS , MILD MR, SEV PAH,GD LV, SR P/CMV	MVR# 27 CHVP	DR. VARGHESE T.PANICKER
82	366527	THANKACHAN D	72	M	25/Apr/2014	SEV CAL AS, MILD AR, LVH, GDLV,CAD,SVD,P/ PCI TO RCA, SR, PORCELIN AORTA	NIL	DR. VARGHESE T.PANICKER
83	372881	NILA A.S.	16	F	25/Apr/2014	OS ASD,GDLV,SR	TPP OSASD CLOSURE (RIGHT THORACOTOMY)	DR. VARGHESE T.PANICKER
84	376727	LISSY ASOKAN	45	F	29/Apr/2014	P/CABG, P/ FACIOTOMY LEFT LOWER LIMB FOR ACUTE LIMB ISCHEMIA	SSG AND DEBRIBEMENT AND SECONDARY SUTURING OF FACIOTOMY LEFT LOWER LIMB	DR. BINEESH K.R.
85	368823	PRABHAKARAN .K	71	M	29/Apr/2014	SEV CAL AS, MOD AR, GDLV, SR, CAD, SVD, P/ GANGRENE (L) COLON (OPTD), B/L CAROTID ARTERY STENOSIS, B/L PVOD, VARICOSE VEINS	AVR+19 PM+ CABG X 2 GRAFT (OM, RPDA)	DR. VIVEK V. PILLAI
86	377279	B/O SREEJA SHIJU	0	M	02/May/2014	CCHD,DTGA,MULTIPLE VSD, P/ BAS,PDA,GD LV, SEV PAH, SR, ILCX2R	ASO+ MULTIPLE VSD CLOSURE	DR. BAIJU S.DHARAN
87	251033	SUJITH S.	9	M	06/May/2014	CCHD, PA, CONF PA, SAVSD, LT ARCH, LPA STENOSIS, LARGE MAPACAS.,SR	ICR WITH RA- PA CONDUIT(#23 HOMOGRAFT) + RIGHT MAPCA LIGATED AND LEFT MAPCA UNIFOCALIZATION + LPA PLASTY +PFO	DR. BAIJU S.DHARAN
88	342257	FATHIMA HASNA T P.	12	F	07/May/2014	CCHD, TOF, INF PS, FAIR PA, NC, SR	ICR + RVOT PATCH	DR. SABARINATH MENON
89	378460	B/O ASHA	0	F	09/May/2014	CCHD, TA, MOD- SEV PS,VSD,ASD,PDA DEPENDENT CIRCULATION,B/L SVC, SR	RMBTS WITH 3 MM PTFE GRAFT.	DR. THOMAS MATHEW
90	378460	B/O ASHA	0	F	10/May/2014	P/ RMBTS		DR. THOMAS MATHEW
91	272755	ARPUTHARAJ M.	16	M	12/May/2014	SP VSD RCC PROLAPSE,TRIVIAL AR,NO PAH , SR	TRANS RA-PA ICR (GOTEX PATCH CLOSURE OF SP VSD+ INFUNDIBULAR RESECTION)	DR. THOMAS MATHEW
92	378762	AADHYA K P	0	F	13/May/2014	ALCAPA, SEVERE LV DYSFUNCTION, MILD MR, SR	LCA TRANSLOCATION+ PDA INTRUPPTION	DR. BAIJU S.DHARAN
93	370955	ADITHYAN R.M.	3	M	15/May/2014	ACHD,SV ASD, PAPVC OF RUPV,GD LV, SR	ASD CLOSURE + REROUTING OF PAPVC OF RUPV (DOUBLE PATCH TECHNIQUE)	DR. THOMAS MATHEW
94	336927	MUNISHWARI M.	18	F	16/May/2014	CCHD,TOF, DC VSD,SUPRA VALVULAR AND INFUNDIBULAR PS,CONFLUENT PA ANATOMY,GD LV,SR	ICR WITH RVOT PATCH	DR. BAIJU S.DHARAN

95	378207	ABHIIRAMII ANILKUMAR K	0	F	19/May/2014	SEV COA,MID MUSCULAR VSD, OS ASD, MOD PAH, RECTOVAGINAL FISTULA	COA REPAIR(RESECTION AND END TO END ANASTOMOSIS	DR. THOMAS MATHEW
96	374225	AKSHAYA S.S.	0	F	20/May/2014	RASTELLI TYPE A CAVCD, MILD AVVR, MULTIPLE MUSCULAR VSD, SEV PAH, PFO, SR	CAVCD REPAIR (TWO PATCH TECHNIQUE) + DC OF MULTIPLE VSD + PFO LEFT OPEN + STERNUM KEPT STENTED	DR. BAIJU S.DHARAN
97	377021	HAPZIBA R	0	F	21/May/2014	ACHD, MULTIPLE VSD, SEV PAH, SR	PA BAND 29 MM	DR. SABARINATH MENON
98	237310	ANJANA U.	9	F	23/May/2014	SI,LC,PA,VSD,P/ BILATERAL BDG, SR	TCPC (20 MM PTFE GRAFT)+ 4 MM FENESTRATION	DR. BAIJU S.DHARAN
99	342118	ASWAJITH BAIJU	2	M	26/May/2014	ACHD,SA VSD, ADDL MUSCULAR VSD, SEV PAH,SR,DOWNS SYNDROME	GOTEX PATCHCLOSURE OF SA VSD, DC MULTIPLE MUSCULAR VSD, PFO LEFT OPEN	DR. BAIJU S.DHARAN
100	336774	ATHRIN V A	3	M	27/May/2014	CCHD,TOF, CONFLUENT PA, SR, ABSENT THYMUS	ICR+ INFUNDIBULAR RESECTION	DR. SABARINATH MENON
101	379582	B/O RAJITHA	0	M	28/May/2014	CCHD, OBSTRUCTED SC TAPVC, SEV PAH,PDA, ASD,SR	TAPVC REPAIR	DR. BAIJU S.DHARAN
102	364521	CHRIS ANTO A	3	M	29/May/2014	ACHD,OS ASD,GD LV, SR	TPP CLOSURE OF OS ASD	DR. SABARINATH MENON
103	369484	FATHIMA HISANA.K	1	F	29/May/2014	ACHD, LARGE PDA,SEV PAH,CONG RUBELLA SYND,P/DC	PDA INTRUPTION (LEFT LATERAL THORACOTOMY)	DR. SABARINATH MENON
104	345201	GOWRI SANKAR .P	2	M	02/Jun/2014	CCHD, TOF, GOOD PA , SR, NC, SPELLS	ICR	DR. SABARINATH MENON
105	368700	AANIJA M J	2	F	03/Jun/2014	ACHD VSD SEV HYPERKINETIC PAH GD BV FN, SR	GORETEX PATCH CLOSURE OF VSD + PFO LEFT OPEN	DR. SABARINATH MENON
106	364851	ABHINAV V A	0	M	04/Jun/2014	CCHD,TOF,CONFLUENT PA ANATOMY, GD LV, SR, SPELLS	ICR+ TAP+MONOCUSP RECONSTRUCTION OF RVOT	DR. SABARINATH MENON
107	366603	AHAD ALI S	0	M	06/Jun/2014	CCHD,DTGA, DC VSD, MOD PS, MILD MR/TR,PDA, SEV PAH, ADDL MID MUSCULAR VSD, SR, NC	REV PROCEDURE+ MV COMMISSUROPLASTY	DR. BAIJU S.DHARAN
108	209359	SRUTHI RAJ.K.	11	F	09/Jun/2014	CCHD,TOF,P/LMBTS(2003),P/BPV(2009)P/BDG+LMBTS INTRPN(2010),LAD CROSSING RVOT CONFLUENT PA, SR	ICR+27 PULMONARY HOMOGRAFT+BDG TAKEDOWN + PFO OPEN	DR. BAIJU S.DHARAN
109	360200	REYA BETTY.A	1	F	10/Jun/2014	TOF WITH DCVSD,INFUNDIBULAR& VALVULAR PS, RPA ORIGIN STENOSIS. GDLV, SR, NC	ICR+MPA AND RPA PLASTY	DR. SABARINATH MENON
110	334380	ASWIN S	5	M	10/Jun/2014	ACHD,OS ASD,GD LV, SR, B/L SVC	TPP CLOSURE OF OS ASD	DR. SUDIP DUTTA BARUAH
111	376576	B/O DIVYA	0	F	11/Jun/2014	SI, MC, CC-TGA, SP VSD, MILD MS, ASD, SEV PAH, SR	PA BANDING TO # 22 MM	DR. SABARINATH MENON
112	376023	MAHALAKSHMI M	4	F	11/Jun/2014	CCHD TOF INFUNDIBULAR AND VALVEOLAR PS ADDL MID MUSC AND APICAL VSD SR NC	ICR, TAP, MONOCUSP RECONSTRUCTION OF RVOT, DIRECT CLOSURE OF MULTIPLE MID MUSCULAR AND APICAL VSD.	DR. SABARINATH MENON
113	348948	SUBISH . S	3	M	13/Jun/2014	ACHD,OS ASD, GD LV, PDA, SR	TPP CLOSURE OF OS ASD	DR. SABARINATH MENON
114	366417	ASHMI.K.S	0	F	17/Jun/2014	CCHD PA VSD CONF PA, P/PDA STENTING, SINGLE	BDG+ CONFLUENCE AND LPA	DR. SABARINATH

						CORONARY, LPA STENOSIS, SR	PLASTY WITH BPP	MENON
115	366372	HANNA FATHIMA R. F	3	F	18/Jun/2014	ACHD,SV ASD, PAPVC RUPV & RMPV, GD LV, SR	DOUBLE PATCH REPAIR OF SV ASD	DR. SUDIP DUTTA BARUAH
116	246208	ABHIJITH.M.NAIR	9	M	19/Jun/2014	CCHD SS DC P/BDG(06) SV(LV) PS JUXTAPOSED AA ,PDA,SR NC	EXTRA CARDIAC TCPC+ 4.5 MM FENESTRATION+PDA INTRUPPTION	DR. BAIJU S.DHARAN
117	377694	MAHALEKSHMI.K.S.	0	F	20/Jun/2014	SS,LC,DTGA,VSD,ASD,PDA, 1L2RCX,PRESERVED LV, MOD TR, SR, DIAPHRAGM EVENTRATION	ASO+VSD CLOSURE+ ASD MADE RESTRICTIVE+PDA INTRUPPTION+ TV REPAIR+ PLICATION OF EVENTRATION OF RIGHT DIAPHRAGM	DR. BAIJU S.DHARAN
118	377694	MAHALEKSHMI.K.S.	0	F	21/Jun/2014	P/ASO	DSC	DR. SABARINATH MENON
119	367750	SREENANDHA K	0	F	24/Jun/2014	CCHD, PA,VSD,CONFLUENT PA,GD LV,SR,S/L SVC	RMBTS(4MM PTFE GRAFT)	DR. SABARINATH MENON
120	362455	CELIN YESUDAS	72	M	04/Jul/2014	CAD,TVD,GD LV,SR,DM,HTN,DLP	CABGX 3 GRAFT(LIMA-LAD, RSVG-MAJ OM, DISTAL RCA)	DR. VIVEK V. PILLAI
121	373431	VELAYUDHAN E.K.	63	M	07/Jul/2014	CAD,TVD,MOD LVD,SR,HTN	CABGX 5 GRAFT (LIMA-LAD, RSVG-DIAG, OM1,OM3,PDA)	DR. JAYAKUMAR K
122	376436	RAJENDRAN K.V	78	M	08/Jul/2014	CAD,TVD,GDLV,SR,DM,HTN	CABGX 6 GRAFT(LIMA-LAD,RSVG-MAJ DIA,OM1,TERMINAL OM,PDA,PLB)	DR. JAYAKUMAR K
123	368254	REGHUNATHAN PILLA S	52	M	09/Jul/2014	CAD,DVD,GDLV,SR,HTN,DLP.	CABGX5 GRAFT(LIMA-LAD,RSVG-MAJ DIAG,OM1,OM2,OM3)	DR. JAYAKUMAR K
124	307009	SIVARAJAN S	53	M	11/Jul/2014	CAD,TVD,MOD LVD,MILD MR,SR,DM,DLP, B/L PVOD	CABGX 4 GRAFT(LIMA-LAD,RSVG-D1, TERMINAL OM,PDA)+LINEAR PLICATION	DR. PRAVEEN VARMA P.K.
125	375181	ABDUL JALAL M	62	M	14/Jul/2014	CAD,TVD.GDLV,SR, DM,HTN, OLD PULMONARY TUBERCULOSIS	CABGX 5 GRAFT(LIMA-LAD, RSVG-DIAG, RI,OM1,PDA)	DR. VIVEK V. PILLAI
126	379270	SHANMUGAM P	45	M	15/Jul/2014	UAV,SEV CAL AS,MILD AR,MILD MR,SR,NC	AVR# 25 CHVP	DR. VARGHESE T.PANICKER
127	371967	PRAKASINI AMMA	55	F	16/Jul/2014	DIL ASC AORTA ROOT,MOD AR,DIL LV,GDLV,SR	BENTALLS PROCEDURE (19 CHVP + 22 ALBO GRAFT)	DR. JAYAKUMAR K
128	381268	BABU T V	46	M	17/Jul/2014	CAD,LMCA,DVD,GDLV,SR,DLP	CABGX5 GRAFT(LIMA-LAD,RSVG-D1,OM1,OM2,TERM OM)(OM2 PIGGY BACKED TO OM1)	DR. JAYAKUMAR K
129	329952	KARTHIKA M	14	F	18/Jul/2014	RHD,SEV MR,MILD MS,MOD TR,,SR	MVR #25 CHVP	DR. PRAVEEN VARMA P.K.
130	354235	MUHAMMED KUTTY .K.T	51	M	21/Jul/2014	CAD,DVD,GDLV,DLP,SR	CABGX 3 GRAFT(LIMA-LAD, RSVG-DIAGONAL, PDA)	DR. PRAVEEN VARMA P.K.
131	381732	NAZARUDEEN A.R.	55	M	22/Jul/2014	CAD,TVD,MOD-SEV LV DYSFUNCTION ,SR,DM,HTN,DLP	CABGX 6 GRAFT(LIMA-LAD,RSVG-MAJ DIAG,OM, PDA,PLB)	DR. JAYAKUMAR K
132	364641	SUBBALEKSHMY L	51	F	23/Jul/2014	RHD,SEV MS,MOD MR,MOD TR,MOD PAH,,AF,GDLV,NC	MVR#29 CHVP+PMLP	DR. VARGHESE T.PANICKER
133	321020	MEENA .P	51	F	24/Jul/2014	RHD,SEV MS,,SEV AS, MOD AR,MILD TR, AF,NC	DVR(AVR#19CHVP+ MVR#25CHVP)+ PARTIAL PMLP+ LA	DR. VARGHESE T.PANICKER

							APPENDAGE EXCLUSION	
134	372848	BABU C	45	M	25/Jul/2014	CAD,TVD,GDLV,SR,DM.	CABG X4 GRAFT(LIMA-LAD,RSVG-D1,OM1,PDA)	DR. PRAVEEN VARMA P.K.
135	372138	BALACHANDRAN K.	40	M	25/Jul/2014	SV ASD,PFO +,MOD PAH,GDLV,SR,NC.	TPP CLOSURE OF SV ASD(DOUBLE PATCH TECHNIQUE)	DR. BINEESH K.R.
136	374286	JANSON V.J.	33	M	29/Jul/2014	ACHD,SV ASD,GD LV,SR PFO	ASD CLOSURE (DOUBLE PATCH TECHNIQUE) + PFO CLOSURE	DR. SIVAPRASAD V.
137	379714	SAMUEL J	58	M	30/Jul/2014	BAV,SEV CALCIFIC AS,CON LVH,GDLV,SR	AVR# 19PM	DR. BINEESH K.R.
138	33766	MARYS.E.L.	52	F	31/Jul/2014	RHD/S/P CMV,SEV AR,MOD AS,MOD MS,MILD MR,S/P CMV,GDLV,NC,AF	DVR(AVR19 CHVP+MVR 25CHVP)	DR. VARGHESE T.PANICKER
139	375039	CHANDRAN NAIR N	58	M	04/Aug/2014	CAD TVD GDLV SR DM HTN DLP	CABG X6 GRAFT(LIMA-LAD,RSVG-D1,D2. MAJ OM, RPDA,RPLB (D1 PIGGY BACKED TO OM1)	DR. JAYAKUMAR K
140	374489	SIVADASAN E K	48	M	05/Aug/2014	RHD, SEV MS,MILD MR,CAD, GD LV SR	MVR# 25 CHVP	DR. PRAVEEN VARMA P.K.
141	381454	USMAN V E	63	M	06/Aug/2014	CAD TVD FAIR LV DM HTN DLP	CABG X 5 GRAFT(LIMA-LAD,RSVG-MAJ DIAG,OM2,TERMINAL OM, PDA)	DR. JAYAKUMAR K
142	213448	BABU T.	56	M	07/Aug/2014	CAD REC STEMI TVD SR DM HTN DLP EX SMOKER	CABGX 4 GRAFT (LIMA-LAD, RSVG-D1,MAJ OM,PRE CRUX RCA)	DR. JAYAKUMAR K
143	379289	GOPINATHAN PILLAI R	60	M	08/Aug/2014	SEV AS,MILD AR,GDLV,HTN,SR	AVR # 23 PM	DR. VARGHESE T.PANICKER
144	376296	AHAMED KHAN M	56	M	18/Aug/2014	CAD TVD OLD STEMI MODLVD SR DM HTN	CABG X 4 GRAFT(LIMA-LAD, RSVG-DIAGONAL,TERMINAL OM, AM-PDA)	DR. VIVEK V. PILLAI
145	373907	CICILY P.J.	60	F	19/Aug/2014	S/P CABG WITH SSI STERNAL WOUND DEHISENCE	STERNAL WOUND DERIDEMENT WITH PECTORALIS MAJOR ROTATION FLAP WITH SECONDARY SUTURING	DR. JAYAKUMAR K
146	370354	VALLINAYAGAM G	52	M	20/Aug/2014	SEV CAL AS CONC LVH CAD DVD GDLV SR	AVR+CABG X 2 GRAFT(AVR#21 CHVP+ RSVG- D1,D2(D2 PIGGYBACKED TO D1))	DR. PRAVEEN VARMA P.K.
147	9009798	SULAIMAN.K.	53	M	20/Aug/2014	RHD ,SEV MS, MOD MR,MILD PAH, GDLV, SR, DM	MVR #27 CHVP	DR. VARGHESE T.PANICKER
148	361643	ARIFA BEEVI .N	55	F	21/Aug/2014	CAD, DVD, GDLV,DM, HTN, HYPOTHYROIDISM	CABG X 4 GRAFT(LIMA-LAD, RSVG-D2,D3, PLB)	DR. JAYAKUMAR K
149	375111	XAVIER K T	52	M	22/Aug/2014	CAD,TVD,SEV LVD,SR,DM,HTN,DLP	CABG X 5 GRAFT(LIMA-LAD, RSVG-D1,OM1,TERMINAL OM,RPDA){ TERMINAL OM PIGGY BACKED TO D1) + DISTAL LAD VEIN PLASTY	DR. PRAVEEN VARMA P.K.
150	9510100	SASIKALA.N	41	F	25/Aug/2014	RHD,SEV MS,SEV AS,S/P CMV,GD LV,MOD PAH,AF,NC.	DVR(#AVR 17 SJR+ # 25CHVP)	DR. PRAVEEN VARMA P.K.
151	372918	PRASANNAN PILLAI	51	M	25/Aug/2014	CAD,DVD,PERFORATED AML, SEV MR,IE,SEV PAH,GDLV,AF.	MV REPAIR (SUPERIOR SEPTAL APPROACH) TPP REPAIR OF AML	DR. VARGHESE T.PANICKER

							(A1) PERFORATION + MVA #28 SADDLE RING + CABG X 1 GRAFT(RSVG- LAD)	
152	382933	SUKUMARAN M.K.	67	M	26/Aug/2014	CAD,TVD,SEV MR,FAIR LV,SR,DM,COPD	CABGX 4 GRAFT (LIMA- LAD , RSVG - D1,OM4, RPDA) + # 30 SADDLE RING+ MOD ALFERI REPAIR	DR. PRAVEEN VARMA P.K.
153	359922	ABDUL JABBAR.H	52	M	27/Aug/2014	CAD,SVD,SEV AR,AORTIC ROOT ANEURYSM,S/P TEVAR,HTN	MODIFIED BENTALLS PROCEDURE (AVR #25 MH+ 28 ALBO GRAFT)	DR. JAYAKUMAR K
154	381062	BABU B	61	M	28/Aug/2014	CAD,TVD,FAIRLV,SR,DM,HTN,DLP	CABG X4 GRAFT (LIMA-LAD, RSVG- D2, MAJ OM, PDA)	DR. JAYAKUMAR K
155	383723	GIRIJA M.K.	66	F	01/Sep/2014	CAD,TVD,HTN,DLP,SR,GDLV,H/O CONTRAST ALLERGY	CABG X 4 GRAFT(LIMA-LAD, RSVG- MAJ OM, RAMUS, RCA)	DR. JAYAKUMAR K
156	374733	PRABHAVATHY.L	61	F	02/Sep/2014	CAD,LMCA,TVD,GDLV,SR	CABG X 3 GRAFT (RSVG- LAD, MAJ DIAG MAJ OM)	DR. VIVEK V. PILLAI
157	372994	PEETHAMBARAN .B.	63	M	03/Sep/2014	CAD,OLD IWMI, TVD,GD LV, SR, B/L EMPHYSEMATOUS LUNG	CABG X 3 GRAFT(LIMA-LAD, RSVG- MAJ OM, DISTAL PDA)	DR. JAYAKUMAR K
158	381788	JOSE A.L	64	M	04/Sep/2014	CAD,DVD,GDLV,SR,DM,SR	CABGX 3 GRAFT(LIMA-LAD, RSVG- D1,INFERIOR BRANCH OM,PDA)	DR. VIVEK V. PILLAI
159	300053	SURAYAKUMAR K.	60	M	05/Sep/2014	CAD TVD GDLV SR DM	CABG X 5 GRAFTS (LIMA - LAD; RSVG - D1, D2, MAJ OM, RPDA)	DR. JAYAKUMAR K
160	379081	VASANTHA R	52	F	10/Sep/2014	RHD SEV CAL AS LVH GOOD LV SR,HTN, HYPOTHYROIDISM	AVR# 19 CHVP	DR. VARGHESE T.PANICKER
161	355199	MARIAMMAL .S	40	F	11/Sep/2014	RHD, SEV AS, SEV MS, MOD MR, GDLV, AF	DVR(AVR# 17 CHVP+ MVR# 23CHVP)	DR. VARGHESE T.PANICKER
162	371719	MOIDEEN KUTTY K.K	53	M	12/Sep/2014	CAD TVD LMCA MOD LVD S/P PTCA TO RCA SR DM NEPHROPATHY	CABGX 5 GRAFT(LIMA-LAD, RSVG- D1,D2, TERM OM, PDA)(TERM OM PIGGY BACKED TO D2)	DR. VIVEK V. PILLAI
163	380645	RAVI K	53	M	16/Sep/2014	CAD,DVD,GDLV,SR,DM,HTN,DLP	CABGX 4 GRAFT(LIMA-LAD, RSVG- D1,OM1,TERM OM)	DR. JAYAKUMAR K
164	383361	SHAJI MON P.	54	M	17/Sep/2014	CAD,TVD,GDLV,SR	CABG X3 GRAFT(LIMA-LAD, RSVG- D1, RPDA)	DR. JAYAKUMAR K
165	245966	SUTHAN.T.	27	M	17/Sep/2014	RHD, S/P BMV SEVERE RE- MS, SEVERE PAH, MILD TR, SR	MVR # 25 CHVP + PARTIAL PMLP	DR. BINEESH K.R.
166	379429	AMMINI R	34	F	18/Sep/2014	RHD,S/P CMV,SEV MS,MILD MR,GDLV,SR	MVR# 25 CHVP	DR. BINEESH K.R.
167	239284	MADHUSOODHANAN S.	58	M	18/Sep/2014	CAD,TVD,S/P PCA TO LCX,GDLV,SR,DM,HTN	CABGX 3 GRAFT(LIMA-LAD, RSVG- OM1, RPDA)	DR. JAYAKUMAR K
168	369338	THAMPI L	58	M	19/Sep/2014	CAD,REC ACS, TVD,MOD LVD,SR,DM,HTN,DLP,CVA(OLD)	CABG X 4 GRAFT(LIMA-LAD, RSVG- DISTAL LAD, MAJ DIAG, MAJ OM, LPDA)	DR. VIVEK V. PILLAI
169	197427	ABHILASH N.	30	M	22/Sep/2014	RHD,SEV MR, MOD MS,DIL LV, GD LV, SR	MVR #31CHVP+ PARTIAL PMLP	DR. VARGHESE T.PANICKER
170	355436	GEETHA .P.V	42	F	23/Sep/2014	RHD SEV MS SEV PAH , GDLV, AF, NC	MVR #27 SJM +PMLP	DR. BINEESH K.R.
171	352393	RADHAMANI .K	41	F	24/Sep/2014	RHD,SEV MS,MOD MR,ASD,SEV PAH,SEV TR,AF	MVR#23 CHVP + TPP ASD CLOSURE+ TVA #30 MC RNG ANNULOPLASTY	DR. VARGHESE T.PANICKER

172	375242	BHAJITH LAL B	36	M	26/Sep/2014	MVP,MOD MR,GDLV,SR	MV REPAIR # 33 TAYLOR RING ANNULOPLASTY + REAIR OF P1, P2 SEGMENT CLEFT+ PMC PLICATION	DR. VARGHESE T.PANICKER
173	355436	SUSEELA D	60	F	26/Sep/2014	RHD,SEV MR, SEV AR, GDLV, SR,	DVR(AVR (19 CHVP+25 CHVP)	DR. VARGHESE T.PANICKER
174	385418	KRISHNAKUMAR K.	47	M	27/Sep/2014	TYPE A STANFORD DISSECTION SEV AR GDLV SR	SUPRA CORONARY ACENDING AORTA REPLACEMENT WITH # 24 ALBO GRAFT	DR. JAYAKUMAR K
175	282206	SEKHARAN K	69	M	29/Sep/2014	CAD,TVD,GDLV,SR,HTN,DLP,B.ASTHMA	CABG X 5 GRAFT(LIMA- LAD, RSVG-D1,OM1,RPDA, RPLB) (D1 PIGGYBACKED TO OM1)	DR. JAYAKUMAR K
176	378699	SIVANKUTTY K R	41	M	29/Sep/2014	CAD,DVD,MILD LVD,SR,POST POLIO,DM,SMOKER	CABG X 3 GRAFT(LIMA-LAD, RSVG-D1, RI)	DR. JAYAKUMAR K
177	373260	SUKUMARAN NAIR	74	M	30/Sep/2014	CAD,TVD,MOD LVD,SR,DM,HTN,DLP,	CABG X 4 GRAFT (LIMA- LAD, RSVG- D2, RI, RCA) (D2 PIGGY BACKED TO RI) (RCA ENDARTERECTOMY)	DR. JAYAKUMAR K
178	384168	YASODHARAN K.	69	M	01/Oct/2014	CADTVD,MOD LVD,SR,DM	CABG X 3 GRAFT(LIMA-LAD, RSVG-D1, EARLY PDA,PLB)	DR. JAYAKUMAR K
179	379055	BABU P Y	63	M	07/Oct/2014	CAD,TVD, B/L PVOD, RT CAROTID OCCLUSION,MILD LVD,SR	CABG X 3 GRAFT(RSVG - LAD, TERMINAL OM, RPDA) (LAD PIGGY BACKED TO OM)	DR. VIVEK V. PILLAI
180	385448	SURENDRAN NAIR P.	56	M	08/Oct/2014	CAD,LMCA,TVD,GDLV,DM,SR	CABG X 5 GRAFT(LIMA-LAD, RSVG-D1, OM2, PDA, PLB) (OM2 PIGGY BACKED TO D1 AND PLB PIGGY BACKED TO PDA)	DR. VIVEK V. PILLAI
181	231294	GOPAKUMAR.S	54	M	09/Oct/2014	CAD,TVD,S/P PCI - RCA,DM,SR	CABGX 4 GRAFT(LIMA-LAD, RSVG-D1,D2,PRE CRUX RCA)	DR. JAYAKUMAR K
182	366997	JOHNSON S	30	M	10/Oct/2014	ACHD OS ASD	TPP CLOSURE OF OS ASD	DR. SIVAPRASAD V.
183	366244	THOMAS YOHANNAN	48	M	13/Oct/2014	SEV MR MOD AR MILD AS AF	DVR(AVR#21CHVP,MVR #31CHVP+ PARTIAL PMPL)	DR. VARGHESE T.PANICKER
184	375248	RAJESWARI S	34	F	14/Oct/2014	RHD SEV MS MOD MR SR	MVR(#25CHVP+PMLP)	DR. BINEESH K.R.
185	366979	RAJI C.K	45	F	15/Oct/2014	RHD,SEV MS,MOD MR,MILD TR, GOOD BV FUNCTION,MOD PAH, SR, NC	MVR # 25 CHVP+PMLP	DR. BINEESH K.R.
186	9505033	THANKAMMA SAVITHRI	56	F	16/Oct/2014	SRD S/P CMV SEV REMS SEV PAH SR	MVR# 23 CHVP+PARTIAL PMLP	DR. BINEESH K.R.
187	375980	SOMAN G	55	M	17/Oct/2014	SEV CAL AS, MOD AR,GD LV, SR, NC	AVR # 19 CHVP	DR. VIVEK V. PILLAI
188	383868	DHAMODARAN C.V.	47	M	29/Oct/2014	CAD,TVD,GDLV,SR,HTN,	CABGX 3 GRAFT(LIMA-LAD, RSVG-OM2, POST CRUX RCA)	DR. JAYAKUMAR K
189	370225	MUTHULEKSHMI B	37	F	29/Oct/2014	RHD,SEV MS,MOD MR,SEV TR,GDLV,AF	MVR# 23 CHVP+ TVA (MC3 #28 EDWARDS RING)	DR. VARGHESE T.PANICKER
190	381551	JAYAN V	50	M	30/Oct/2014	CAD, TVD, P/ PTCA- LAD(2012), GD LV, SR	CABGX 4 GRAFT(RSVG- D1, MAJ OM, RI, DISTAL RCA)	DR. JAYAKUMAR K
191	375814	GOPALA KRISHNAN C K	66	M	30/Oct/2014	CAD,TVD,MOD MR,SEV LVDSR,PSORIAIS	CABGX 4 G(LIMA-LAD, RSVG-MAJ DIAG, MAJ OM, PDA+ MV	DR. VIVEK V. PILLAI

							ANNULOPLASTY # 30 ST JUDE SADDLE RING)	
192	370651	ROJA S	32	F	30/Oct/2014	ACHD, SV ASD, PAPVC OF RUPV, P/ ATTEMPTED ASD CLOSURE(CORONARY SINUS OSTIAL CLOSURE, RESIDUAL SV ASD, +PAPVC, MOD TR, MOD PAH, LSVC, SR	REDOSTERNOTOMY+ DOUBLE PATCH CLOSURE OF SVASD + CS REPAIR+IVC REPAIR UNDER TCA	DR. VARGHESE T.PANICKER
193	386526	SULAIKHA T.P.	42	F	03/Nov/2014	DISSECTION OF ACENDING AORTA, MILD AR, GDLV,SR, HTN, DLP	SUPRA CORONARY ACENDING AORTIC REPLACEMENT WITH 20 ALBO GRAFT	DR. JAYAKUMAR K
194	380699	NAGOOR KHANI H	67	M	04/Nov/2014	CAD,TVD,LMCA,MILD AS,GDLV,SR,HTN,DLP	CABGX 5 GRAFT(LIMA-LAD, RSVG-D1,OM1,OM3,AC MARGINAL PDA)	DR. JAYAKUMAR K
195	384388	GANGADHARAN P.	74	M	04/Nov/2014	SP/CABG, DEEP SSI(STERNUM DEHISCENCE)HCV +	PMMC FLAP COVER AND STERNAL DEBRIDEMENT	DR. JAYAKUMAR K
196	367868	KARTHIKEYAN V	52	M	05/Nov/2014	CAD,TVD,LMCA,MOD LVD,HTN,DLP,DM,AWMI(2011)	CABG X 5 GRAFT(LIMA-LAD, RSVG-D1,D2,MAJ OM, DISTAL RCA) LAD ENDARTERECTOMY WITH VEIN PATCH AUGMENTATION	DR. JAYAKUMAR K
197	285520	SATHYA PALAN S.K.	55	M	06/Nov/2014	CAD,TVD,LMCA,GDLV,SR,HTN	CABGX 6 GRAFT(LIMA -LAD. RSVG-MAJ DIAG, MAJ OM, RI, AC MARGINAL, RPDA)	DR. JAYAKUMAR K
198	382788	REGEENAL R.	61	F	11/Nov/2014	CAD,TVD,LMCA,GDLV,DM,DLP,HTN	CABGX 5 GRAFT (LIMA-LAD, RSVG-D1,OM1,OM2, PDA)	DR. JAYAKUMAR K
199	386900	JOSEPH A. DEVASSY	64	M	12/Nov/2014	CAD,TVD,S/P POBA-LCX,GDLV,HTN,VV	CABG X 4 GRAFT(LIMA- LAD, RSVG-D1, RPLB, RADIAL ARTERY- OM1)	DR. JAYAKUMAR K
200	385356	SINDHU RANI A.S.	43	F	14/Nov/2014	CAD,TVD,GDLV,HTN,DM	CABG X 5 GRAFT(LIMA -LAD, RSVG-D1,MAJ OM, AC MARGINAL, PDA)	DR. JAYAKUMAR K
201	378642	RADHAMANI K	55	F	17/Nov/2014	BAV SEV CAL AS GOOD LV SR NC	AVR # 17 SJR	DR. BINEESH K.R.
202	374943	MUHAMMED A	55	M	18/Nov/2014	TAV, SEV AR,SVD,FAIR LV,SR	MODIFIED BENTALLS PROCEDURE (#21 CHVP WITH 22 MM ALBO GRAFT)+CABG X 1 GRAFT(RSVG-RPDA)	DR. JAYAKUMAR K
203	377009	NAMMALVAR V	31	M	18/Nov/2014	RHD,SEV MR,MOD MS, MILD TR, MOD PAH,AF	MVR # 27 CHVP+PMLP	DR. BINEESH K.R.
204	8806856	JAMANIYA BEEVI.M.	50	F	19/Nov/2014	RHD,SEV CAL MS, GDLV, SEV PAH, SR,NC	MVR # 25 CHVP+PMLP	DR. BINEESH K.R.
205	385839	PRIYA VIMAL S.	34	F	20/Nov/2014	ACHD,OSASD,GD LV,SR,	TPP CLOSURE OF OS ASD	DR. SIVAPRASAD V.
206	338119	MUHAMMED MUSTHAFA C.	40	M	21/Nov/2014	RHD,SEV AR,SEV MR,MOD PAH,MOD LV DYSFUNCTION,DILATED LV,SR,NC	AVR # 25 CHVP + MVR # 27 CHVP + PMLP (SUPERIOR SEPTAL APPROACH)	DR. VARGHESE T.PANICKER
207	383586	ASOKAN R.	59	M	24/Nov/2014	SEV CAL AS CAD LMCA FAIR LV SR, DIALATED AORTA	AVR # 21 PM+ CABGX 4 GRAFT(RSVG- LAD, DIAG, OM, RPDA) +AORTOPLASTY	DR. VIVEK V. PILLAI

208	368450	DAMODARAN K	58	M	24/Nov/2014	RHD,SEV MS,MOD MR,MOD TR,MOD PAH,GDLV,SR,NC,THROMBOCYTOPAENIA	MVR # 25 CHVP + PARTIAL PMLP	DR. BINEESH K.R.
209	339368	SARADAKRISHNARANJAN K S.	69	M	25/Nov/2014	CAD DVD GDLV SR HTN DLP	CABGX 4 GRAFT(LIMA-LAD, RSVG-D1, MAJ OM, RPDA)	DR. JAYAKUMAR K
210	376809	LILLYKUTTY V	75	F	26/Nov/2014	RHD,SEV CAL AS,MILD AR,CAD,DVD,GDLV,SR,DM,HTN	AVR # 17 CHVP + CABG X 2 (RSVG - LAD , RPDA)	DR. VIVEK V. PILLAI
211	387571	THALHATH M.	57	F	27/Nov/2014	DCM SEV LV DYSFN LBBB MILD MR	EPICARDIAL LV LEAD PLACEMENT	DR. VIVEK V. PILLAI
212	373615	ALIYARU KUNJU A.	61	M	27/Nov/2014	CAD TVD GDLV SR DM	CABGX 4 GRAFT (LIMA-LAD, RSVG-TERIMINAL OM, PDA, PLB)	DR. JAYAKUMAR K
213	381561	ABDUL SALAM A	51	M	28/Nov/2014	CAD,LMCA+TVD,GDLV,SR,HTN,DM,DLP	CABG X 5 GRAFT(LIMA-LAD, RSVG-D2, MAJ OM, TERMINAL OM, PRE CRUX RCA)(RCA ENDARTERECTOMY DONE)	DR. JAYAKUMAR K
214	381561	ABDUL SALAM A	51	M	29/Nov/2014	S/P CABG WITH MEDIASTINAL BLEED	RE EXPLORATION, EVACUATION OF CLOT AND HEMOSTASIS	DR. BINEESH K.R.
215	9307695	HARIHARAN.R.(RETD.STAFF)	69	M	01/Dec/2014	CAD,TVD, FAIR LV,SR,HTN,DM	CABG X 4 GRAFT(LIMA- LAD, RSVG-D1, MAJ OM, PDA)	DR. JAYAKUMAR K
216	374895	AYISHA P.P.	52	F	02/Dec/2014	CAD,TVD,GDLV,SR,DM,HTN,DLP,HYPOTHYROIDISM	CABG X 5 GRAFT(LIMA- LAD, RSVG-OM1,OM2,RI,RPDA)	DR. JAYAKUMAR K
217	332969	THANKARAJAN S	63	M	03/Dec/2014	CAD,TVD,MOD LVD,HTN,SR, LV ANEURYSM	CABGX 5 GRAFT(LIMA-LAD, RSVG-D1, OM2, OM3, ACUTE MARGINAL, LV PLICATION)	DR. JAYAKUMAR K
218	378445	RAJENDRAN S	54	M	03/Dec/2014	CAD,LMCA,TVD,NILD LVD,HTN,DLP, BILATERAL PVOD	CABG X4 GRAFT(LIMA- LAD, RSVG-D1, OM UPPER DIVISION, PDA)(OM PIGGY BACKED TO D1)	DR. VIVEK V. PILLAI
219	8703145	NAZAR.K	41	M	04/Dec/2014	SV ASD(SVC),RUPV TO SVC-RA JUNCN,GDLV,SR	REEOUTING OF RUPV BY DOUBLE PATCH TECHNIQUE	DR. BINEESH K.R.
220	382852	SARASAM J.	67	F	04/Dec/2014	CAD,TVD,MILD LVD,FAIR RV,SR,DM	CABG X 4 GRAFT(LIMA-LAD, RSVG-DIAG, MAJOR OM, TERMINAL OM)	DR. JAYAKUMAR K
221	386322	MUHAMMED SHAROOQ A.A.	19	M	05/Dec/2014	SEV MR(MVP P2 SEGMENT)CHORDAL RUPTURE,GDLV,SR	TRIANGULAR RESECTION OF PMLWITH NEOCHORDAL RECONSTRUCTION WITH 4-0 GORTX AND ANNULOPLASTY 31#TAYLOR RING	DR. VARGHESE T.PANICKER
222	384901	HARIFA BEEVI P.	52	F	08/Dec/2014	RHD,SEVERE MS,SEV MR,MOD PAH,SR	MVR#23 CHVP+ PARTIAL PMLP	DR. VARGHESE T.PANICKER
223	9009972	AMMINI.R.	59	F	09/Dec/2014	CAD SVD GDLV, HTN, DLP, SR S/P PCI TO LAD, P/ THYROIDECTOMY, P/ HYSTERECTOMY	OPCAB X 2 G(LIMA- LAD, RSVG- D1)	DR. JAYAKUMAR K
224	381446	SHAHANAS A A	31	F	10/Dec/2014	RHD, SEV MS, MOD TR ,TRIVIAL AS, TRIVIAL AR MOD PAH ANYSMAL LA, AF	MVR # 25 CHVP +PMLP + MC3 TRICUSPID EDWARDS RING ANNULOPLASTY	DR. VARGHESE T.PANICKER
225	378227	SHAJI V J	48	M	10/Dec/2014	MVP SEV MR GDLV SR COPD	MVR # 29 CHVP+ PMLP	DR. VARGHESE T.PANICKER
226	387569	AMMUKUTTY JOSEPH	75	F	11/Dec/2014	CAD TVD GDLV SRDM, HTN , DLP	CABG X 4 GRAFT(LIMA- MAJ	DR. JAYAKUMAR K

							DIAGONAL, RSVG- LAD, TERMINAL OM, RPDA)	
227	388109	ROUF O.	50	M	12/Dec/2014	CAD,TVD,GDLV,SR(SP/PCI TO RCA)	OPCAB X 2 GRAFT(LIMA- LAD, RSVG- D1)	DR. JAYAKUMAR K
228	357033	ASWATHY R MOHAN	20	F	12/Dec/2014	ACHD,OSASD,MILD MR, MILD TR, GDLV/RV,SR,	TPP CLOSURE OF OS ASD	DR. VARGHESE T.PANICKER
229	377646	SANKARAN S	55	M	15/Dec/2014	CAD,TVD,LMCA,GDLV,SR,DM,HTN,DLP,EX SMOKER, BULLOUS LUNGS	CABGX 4 GRAFT(LIMA-LAD, RSVG-D1, TERMINAL OM, RPLB)	DR. JAYAKUMAR K
230	387638	ARUN THOMAS	16	M	16/Dec/2014	ACHD, HAPVC, OS ASD, SR, NC	REROUTING OF HAPVC TO LA + EXTENSION OF OS ASD SUPERIORLY	DR. BINEESH K.R.
231	351887	RAMAMOORTHY S V	54	M	16/Dec/2014	CAD,TVD,GDLV,SR,DM,EXSMOKER	CABG X 5 GRAFT(LIMA-LAD, RSVG-D1, BOTH BRANCHES OF OM, DISTAL RCA)	DR. JAYAKUMAR K
232	385564	SASIDHARAN PILLAI B.	68	M	17/Dec/2014	CAD,TVD,GDLV,HTN,DM,DLP,BA	CABGX 5 GRAFT(LIMA-LAD, RSVG-MAJ DIAG, MAJ OM, PDA, PLB)	DR. JAYAKUMAR K
233	377500	SUBIMOL B	19	M	18/Dec/2014	ACHD,OSASD+ ADD ASD , MILD TR, GD BV FUNC., SR	TPP CLOSURE OF OS ASD(SUPERIOR EXTENSION OF OS ASD TO INCORPORATE ADDL ASD) + BICUSPIDIZATION OF TV	DR. SIVAPRASAD V.
234	388832	ALEYAMMA MATHEW	45	F	19/Dec/2014	CAD,DVD,LMCA,FAIR LV,SR,HTN,DM,DLP	CABG X 3 GRAFT(LIMA-LAD, RSVG-MAJ DIAG, MAJ OM)	DR. JAYAKUMAR K
235	371560	VENKITTARAMA IYER.R	74	M	22/Dec/2014	CAD,TVD,MOD LVD, SR,HTN, PERIFERAL NEUROPATHY	CABGX 5 GRAFT(LIMA-LAD, RSVG -RI, D2, MAJ OM, PDA)	DR. JAYAKUMAR K
236	382301	SASIDHARAN N.	60	M	23/Dec/2014	CAD,TVD,GDLV, HTN,DLP,SR,H/O TIA	CABGX 5 GRAFT(LIMA-LAD, RSVG-MAJ DIAG, MAJ OM, RPDA, RPLB)	DR. JAYAKUMAR K
237	368450	DAMODARAN K	58	M	23/Dec/2014	S/P MVR WITH SSI OF STERNAL WOUND	DEBRIDEMENT	DR. BINEESH K.R.
238	382073	SUNDERASAN K.	60	M	24/Dec/2014	CAD,TVD,GDLV,MILD MR,SR, DM, HTN,DLP,	CABGX 6 GRAFT(LLIMA- LAD, RSVG- D1, OM1, OM2, RPDA, ADDL GRAFT TO LAD)	DR. VIVEK V. PILLAI
239	374447	ANNAMMA	54	F	29/Dec/2014	SEV CAL MS S/P BMV SEV RE MS MILD AR, MOD PAH, MODE TR, ASD, GOOD LV, AF	MVR# 27 CHVP+ PARTIAL PMLP + #28 MC3 RING ANNULOPLASTY+ ASD CLOSURE	DR. VARGHESE T.PANICKER
240	382184	KUNJUMON M V.	58	M	30/Dec/2014	CAD TVD MOD MR MILD LVD SR HTN	CABG X 4 GRAFT(LIMA-LAD, RSVG-D2, MAJ OM, RPDA)	DR. VIVEK V. PILLAI
241	383072	BADARUDEEN M.	60	M	30/Dec/2014	CAD TVD FAIR LV MILD MOD MR,HTN, SR	CABG X 4 GRAFT(LIMA- MAJ DIAGONAL, MAJ OM, RPDA)	DR. VIVEK V. PILLAI
242	368450	DAMODARAN K	58	M	31/Dec/2014	S/P MVR WITH SSI + STERNAL DEHISCENCE	ADVANCEMENT FLAP (RIGHT PECTORALIS MAJOR)	DR. BINEESH K.R.
243	380380	LEVI G	57	M	31/Dec/2014	CAD DVD GDLV SR HTN DLP	CABG X5 GRAFT(LIMA-D3, LAD, D2, MAJ OM, RPDA)	DR. JAYAKUMAR K
244	377155	VIJAYAN K P	56	M	01/Jan/2015	BAV SEV CAL AS MILD AR GDLV SR	AVR #23 CHVP	DR. BINEESH K.R.
245	389314	INDIRA K..	63	F	02/Jan/2015	CAD, TVD ,MILD MR ,FAIR LV, SR, DM, HTN ,DLP, B/L PVOD	CABG X 4 GRAFT (LIMA-LAD, RSVG-BOTH BRANCHES OF OM, RPDA)	DR. JAYAKUMAR K

246	382395	THOMAS MATHEW ADACKANATTU.	44	M	05/Jan/2015	RHD,SEV MR,MILD AR,DIL LV,MILD LVD,SR	MVR # 27 CHVP+PMLP	DR. BINEESH K.R.
247	386961	MURALEEDHARAN PILLAI K.	60	M	05/Jan/2015	CAD,LMCA,TVD,GDLV,SR,DM	CABG X 5 GRAFT(LIMA-LAD, RSVG-RI, MAJ DIAG, PRE CRUX RCA(ENDARTERECTOMY DONE), AC MARGINAL PDA	DR. JAYAKUMAR K
248	385268	THANKAPPAN NAIR C.	60	M	06/Jan/2015	SEV CAL. AS CONC. LVH MILD AR NO PAH SR GDLV DM HTN	AVR # 19 PM	DR. BINEESH K.R.
249	383679	LAWRENCE K LOPEZ.	69	M	06/Jan/2015	CAD TVD MILD LVD SR DM HTN DLP, LV ANEURYSM.	LIMA-LAD, RSVG-MAJ DIAG,MAJ OM, RPDA, RPLB(RPLB PIGGY BACKED TO RPDA) LV PLICATION	DR. JAYAKUMAR K
250	385079	MANOJ C.V.	34	M	07/Jan/2015	SEV AR,DIL LV,P/ASC AORTA TO ABDO AORTA BYPASS GRAFT FOR COA	REDOSTERNOTOMY+ MODIFIED BENTALL PROCEDURE(AVR #23 CHVP+24 ALBOGRAFT)+ REIMPLANTATION OF PROXIMAL END OF GRAFT TO ALBO GRAFT	DR. JAYAKUMAR K
251	376888	JAMES RAJ R	49	M	07/Jan/2015	CAD,IWMI,TVD,MILD LVD,SR,OBSTRUCTIVE SLEEP APNEA	CABGX 5 GRAFT(LIMA-LAD, RSVG-D1, OM1,TERMINAL OM, LPDA)(D1 PIGGY BACKED TO OM1)	DR. JAYAKUMAR K
252	183392	PANCHAMY S.T.	23	F	08/Jan/2015	ACHD,OSASD,SEV PAH,MOD TR,GDLV,SR		DR. BINEESH K.R.
253	385440	JOY T.T.	71	M	08/Jan/2015	CAD,DVD,GDLV,SR,HTN,DLP	CABG X 6 GRAFT(LIMA-LAD, RSVG-D1, D2, MAJ DIAG, TERMINAL OM, PDA	DR. JAYAKUMAR K
254	383558	KUNJAPPY K.	67	M	09/Jan/2015	CAD, TVD, 1`PTCA TO RCA, GDLV, SR ,DLP, PVOD ,BA	CABG X 5 GRAFT(LIMA-LAD, RSVG-RI, MAJ DIAG, OM2, RPDA)	DR. JAYAKUMAR K
255	380231	THOMAS J	62	M	09/Jan/2015	CAD TVD MILD LVD MILD MR MOD PAH SR DM HTN	CABG X 7 GRAFT(LIMA-LAD, RSVG-RI,MAJ DIAG,MAJ OM,TERMINAL OM, ACUTE MARGINAL, PDA)(RI PIGGY BACKED TO MAJ OM)	DR. JAYAKUMAR K
256	384127	GOPINATHAKURUP M.	70	M	12/Jan/2015	MVP OF PML SEV MR MILD PAH GDLV SR NC	MV REPAIR(TRIANGULAR RESECTION OF PML + #29 DURAN ANCORE ANNULOPLASTY RING)	DR. VARGHESE T.PANICKER
257	384798	DAVID G.	58	M	12/Jan/2015	CAD TVD LMCA GDLV SR HTN DLP	LIMA-LAD, RSVG- RI, DIAG, TERMINAL OM, RPDA)(DIAG PIGGYBACKED TO RI)	DR. JAYAKUMAR K
258	224110	BALRAJ.D.	62	M	13/Jan/2015	CAD TVD GDLV SR HTN DLP S/PTCA TO OM SEIZURE DISORDER	CABGX 7 GRAFT(LIMA-LAD, RSVG-D1,D2, OM1, OM2, RPDA, PLB)(D1 PIGGYBACKED TO D2)	DR. JAYAKUMAR K
259	379903	ALEX. C	27	M	13/Jan/2015	SV ASD, PAPVC, GD LV , SR, NC	DOUBLE PATCH REPAIR OF SV ASD	DR. BINEESH K.R.
260	367717	JAYA LAL MOHAN(DR)	63	F	14/Jan/2015	CAD TVD GDLV SR DM HTN DLP	CABG X 4 GRAFT(LIMA-LAD, RSVG-RI, TERMINAL OM, RCA)	DR. JAYAKUMAR K
261	378868	RAVINDRA NATHAN T	54	M	14/Jan/2015	SEV CAL AS MILD AR GDLV SR DM HTN	AVR # 21 CHVP	DR. BINEESH K.R.
262	378062	BALAKRISHNAN K	42	M	15/Jan/2015	S/P CMC RE MS SEVERE PAH MOD MR AF	MVR # 31 MVR+ MODIFIED DEVAGAS TV ANNULOPLASTY	DR. BINEESH K.R.

263	375694	ABDUL RAHMAN KUNJU M	65	M	15/Jan/2015	CAD, TVD, GD LV,SR, DM, HTN, DLP	CABG X 6 GRAFT (LIMA- LAD, RSVG- DIAGONAL, RI MAIN BRANCH AND RI MEDIAL BRANCH, RPDA, RPLB)	DR. JAYAKUMAR K
264	390733	VIJAYA KUMAR P.	61	M	16/Jan/2015	CAD, LMCA, TVD,SEV LV DYSFUNCTION, SR, DM,HTN,DLP	CABGX 4 GRAFT(LIMA-LAD, RSVG-DIAGONAL, OM, RPDA)	DR. JAYAKUMAR K
265	381577	THANKA K	49	F	16/Jan/2015	RHD, SEV CALCIFIC MS,S/P BMV,SEV MS, SEV PAH, GDLV, AF,NC	MVR # 27 CHVP+PARTIAL PMLP	DR. BINEESH K.R.
266	376128	PARAMESWARAN PILLAI M	69	M	19/Jan/2015	CAD,DVD,ATTEMPTED PCI TO RCA,GDLV, SR,DLP	CABGX 5 GRAFT(LIMA-LAD, RSVG-DIAGONAL, OM1,OM3, RPDA)	DR. JAYAKUMAR K
267	384294	SURENDRAN P. (DR)	70	M	20/Jan/2015	CAD,LMCA,DVD OLD MI,RECENT ACS-IWMI, AF, DM	CABGX X 4 GRAFT(LIMA-LAD, RSVG- OM, RPDA, RPLB)	DR. JAYAKUMAR K
268	389148	ABRAHAM T.	63	M	21/Jan/2015	CAD,TVD,SEV.LVD,AWMI(PCI-LAD 2011&2014),PND,SR,DM,HTN,DLP	CABGX 5 GRAFT(LIMA-LAD, RSVG-DIAG, OM2, TERMINAL OM, PDA)(OM2 PIGGY BACKED TO DIAGONAL)	DR. JAYAKUMAR K
269	364818	RAJAGOPAL G	45	M	21/Jan/2015	SEV.CALCIFIC AS. MILD AR, CON.LVH,GDLV,SR DIALATED ACENDING AORTA	AVR# 21 CHVP + AORTOPLASTY	DR. BINEESH K.R.
270	378840	ASSANARU KUNJU K	74	M	22/Jan/2015	CAD, TVD, RECURRENT NSTEMI, SR,GDLV,DM,HT, DLP, CKD	CABGX 5 GRAFT(LIMA- LAD, RSVG-DIAG, OM2, TERMINAL OM, RPDA)	DR. JAYAKUMAR K
271	386463	VIJAYAKUMAR G.	54	M	22/Jan/2015	RHD,SEV MS,MILD PAH,MILD MR,GDLV,LA CLOT,AF,HTN,NC	MVR #31 CHVP+PARTIAL PMLP+ LA CLOT EXTRACTION + LAEE	DR. BINEESH K.R.
272	388214	BHUVANENDRAN NAIR	59	M	23/Jan/2015	CAD LMCA TVD GDLV SR DM HTN	CABG X 5 GRAFT(LIMA-LAD, RSVG-DIAGONAL, OM1,OM2, DISTAL RCA)	DR. JAYAKUMAR K
273	319671	RAJENDRAN K.	52	M	27/Jan/2015	OSASD,MOD MR, SEV TR,GDLV, AF	MVR#29CHVP+TVA#32MC3 RING+TPP CLOSURE OF OSASD	DR. VIVEK V. PILLAI
274	384527	BABU K ABRAHAM	47	M	27/Jan/2015	CAD , TVD GDLV,SR, RECENT IWMI , DM, HT, DLP	CABGX 4 GRAFT(LIMA-LAD, RSVG-D1, MAJ OM, RPDA)	DR. JAYAKUMAR K
275	389379	SREEKUMARAN THAMPI R.	74	M	28/Jan/2015	CAD,TVD,NSTEMI,SR,GDLV,DM, HTN, DLP	CABG X 5 GRAFT(LIMA-LAD, RSVG-DIAGONAL, OM1, TERIMAL OM, RPDA)(TERMINAL OM GRAFT PIGGY BACKED TO OM1 GRAFT)	DR. JAYAKUMAR K
276	389194	RADHAKRISHNAN K.	63	M	29/Jan/2015	CAD TVD, GD LV, SR, DLP	CABGX 4 GRAFT(LIMA-LAD, RSVG-DIAGONAL, DISTAL OM, RPDA)	DR. JAYAKUMAR K
277	391267	SREEJA L.	23	F	30/Jan/2015	CAD/LMCA/TVD/GDLV /SR/HYPOTHYROID,FAMILIAL HYPERCHOLESTEROLEMIA	CABG X 3 GRAFT(LIMA-LAD, RSVG-MAJ OM, DISTAL RCA)	DR. JAYAKUMAR K
278	341464	SHANU SHAJI	3	F	02/Feb/2015	TOF, SUPRA VALVULAR MPA NARROWING,PFO, SR, NC	ICR+MONOCUSPRECONSTRUCTION OF RVOT + TRANSANNULAR PATCH+PFO MDE RESTRICTIVE	DR. SABARINATH MENON
279	344266	ASWATHY PRASAD P.	8	F	03/Feb/2015	CCHD, PA, VSD, P/BDG, SR	BIVENTRICULAR REPAIR+ SAVSD CLOSURE+ RPA/LPA AUGMANTATION PLASTY, INFUNDIBULAR RESECTION+#21 PULMONARY HOMOGRAFT+ BDG TAKE DOWN	DR. BAIJU S.DHARAN

280	381579	SIDHARTH S	4	M	04/Feb/2015	ACHD,MAL ALLIGNED OS ASD,LSVC,GDLV,NO PAH,SR	TPP CLOSURE OF OS ASD	DR. SABARINATH MENON
281	387432	PUGAL R.	1	M	05/Feb/2015	CCHD,LTGA,SP VSD,SEV PAH, SR	ASO+SENNININGS PROCEDURE+SP VSD CLOSURE	DR. BAIJU S.DHARAN
282	380319	DAYANA U.S	17	F	06/Feb/2015	SEV INF PS,S/P ASD+VSD CLOSURE	INFUNDIBULAR RESECTION AND PATCH AUGMENTATION OF RVOT+VSD PATCH EXPLANTATION.	DR. THOMAS MATHEW
283	364705	VIVEK . V.S	4	M	09/Feb/2015	ACHD, SV ASD, GD LV, SR	DOUUBLE PATCH REPAIR	DR. THOMAS MATHEW
284	391763	B/O SANGEETHA	0	M	10/Feb/2015	TAUSSING BING ANOMALY , INTERRUPTED AORTIC ARCH,SP VSD,PRESERVED LV,SR,NC	AORTIC ARCH ADVANCEMENT + ARTERIAL SWITCH OPERATION + GP VSD CLOSURE +INFUDIBULAR RESECTION +TRANS ANNULAR PATCH + MONOCUSP RECONSTRUCTION OF RVOT	DR. BAIJU S.DHARAN
285	339115	FARHAN C.	12	M	11/Feb/2015	ACHD, SVASD, PDA, NO PAH, NC, SR	ASD CLOSURE(DOUBLE PATCH TECHNIQUE)	DR. SABARINATH MENON
286	354126	MITHUN KRISHNA A.	3	M	12/Feb/2015	DI GEORGE SYNDROME , CCHD , TOF , ABSENT PULMONARY VALVE , MOD-SEV PR, MOD PAH , NC , SR	ICR (GP CLOSURE OF DOUBLY COMMITED VSD + INFUNDIBULAR RESECTION) +B/L PA REDUCTION PLASTY WITH PERICARDIAL PATCH + LE COMPTE MANOUVERE DONE + RV- PA PULMONARY # 23 HOMOGRAFT CONDUIT +	DR. THOMAS MATHEW
287	375674	B/O FAREEDHA	0	F	13/Feb/2015	DORV, VSD, MILD COA,SEV PAH,, SR, NC	ICR(LV TUNNEL TO AORTA BY GORTEX PATCH)	DR. THOMAS MATHEW
288	364046	NEHA KURIAKOSE	1	F	16/Feb/2015	SA VSD,SUB AORTIC MEMBRANE,MILD PS,GD PA,SR	TRANS RA ICR (GP CLOSURE OF VSD +INFUNDIBULAR RESECTION) + SUB AORTIC MEMBRANE EXCISION	DR. SABARINATH MENON
289	369138	ABDUL BASITH V P	1	M	18/Feb/2015	DORV ,SA VSD , SEV INF PS ,ADDITIONAL VSD ,SR	LV-->AO ROUTING + ADDITIONAL VSD CLOSURE + INFUNDIBULAR RESECTION +TAP +MONOCUSPRECONSTRUCTION OF RVOT+PFO MADE RESTRICTIVE	DR. SABARINATH MENON
290	391934	SALMAN FARRIS N.P.	0	M	19/Feb/2015	CCHD,DTGA,SP VSD,ASD, NC,GD LV/RV FUNCTION,SR,NC.	ASO + VSD CLOSURE + DIRECT CLOSURE OF ASD.	DR. SABARINATH MENON
291	391934	SALMAN FARRIS N.P.	0	M	20/Feb/2015	S/P ASO, TGA VSD, PDA	DSC	DR. SABARINATH MENON
292	370574	ANSILLA V	1	F	23/Feb/2015	CCHD,RASTELLI TYPE C CAVCD, AML CLEFT,MOD MR, SEV. PAH, SR	ICR (DOUBLE PATCH REPAIR + AML CLEFT REPAIR)	DR. THOMAS MATHEW
293	9702778	RESHMA RAJAN	17	F	24/Feb/2015	UNBALANCED AVCD, LTGA, MAPCAS, SR, S/P BDG	EXTRACARDIAC TCTC WITH 4 MM FENESTRATION	DR. BAIJU S.DHARAN
294	374472	SANJANA S.	1	F	27/Feb/2015	ALCAPA, GD LV,TRIVIAL MR, FIBROELASTOSIS	LCA TRANSLOCATION	DR. THOMAS MATHEW

295	392104	B/O REMYA BINU	0	F	02/Mar/2015	CCHD,PA,VSD,PDA,B/L SVC,SR	ICR+TAP+LPA PLASTY	DR. BAIJU S.DHARAN
296	356761	MOHAMMED ARSHAD FAZIL I.	3	M	03/Mar/2015	CCHD,DILV,PA,VSD,PDA,LPA STENOSIS,SR	BDG+ BILATERAL PA PLASTY +PDA INTERRUPTION (RACHS 2)	DR. SABARINATH MENON
297	384425	MOHAMMED FARHAN M.	0	M	04/Mar/2015	TOF,GOOD PA,H/O SPELLS,SR	ICR+RVOT PATCH REPAIR	DR. THOMAS MATHEW
298	392104	B/O REMYA BINU	0	F	08/Mar/2015	P/ICR +TAP+LPA PLASTY	DSC	DR. SABARINATH MENON
299	389900	MUTHUKUMAR A.	0	M	09/Mar/2015	DTGA,ASD,PDA,REGRESSED LV, PAPVC RLPV TO IVC ,S/P BAS	HEMI MAUSTARD PROCEDURE+BIDIRECTIONAL GLENN+ REROUTING OF RIGHT LOWER PULMONARY VEIN TO ATRIUM	DR. BAIJU S.DHARAN
300	346730	PARASU S SURESH	6	M	10/Mar/2015	ACHD,SP VSD, NO PAH,SR	VSD CLOSURE	DR. SABARINATH MENON
301	383522	FATHIMA HAIFA	1	M	11/Mar/2015	SS,LC,DILV,TGA,L LOOPED VENTRICLE,SR	BDG+ PAB	DR. THOMAS MATHEW
302	392851	B/O SHILPA DAMU	0	M	11/Mar/2015	S/P ASO , PFO MADE RESTRICTIVE WITH STENTED STERNUM	DSC	DR. THOMAS MATHEW
303	352820	JOEL JOSEPH	2	M	12/Mar/2015	TOF,S/P RMBTS(11/2012),NO CHF, GOOD LV, FUNCTIONING BTC	REDOSTERNOTOMY+ ICR+MONOCUSP RECONSTRUCTION OF RVOT +TAP +BT SHUNT TAKE DOWN	DR. BAIJU S.DHARAN
304	362272	THASNI.P	12	F	13/Mar/2015	ACHD ,LSVC, SAVSD, INFUNDIBULAR PS, RCC PROLAPSE, SEV AR,SR	VSD CLOSURE+ INFUNDIBULAR RESECTION+ AV REPAIR+ SUB COMMISSURAL ANNULOPLASTY	DR. THOMAS MATHEW
305	393581	B/O JOPHY	0	M	16/Mar/2015	CCHD,PULM ATRESIA,INTACT IVS,PDA ,P/BAS,NC	RMBTS WITH 3MM PTFE GRAFT+ PDA LIGATION	DR. BAIJU S.DHARAN
306	385364	RIYA MEHRIN	1	F	18/Mar/2015	CCHD,TRUNCUS ARTERIOSUS TYPE 2 ,SEV PAH,SR	TRUNCUS ARTERIOSUS REPAIR + RV TO PULMONARY ARTERY #17 AORTIC HOMOGRAFT	DR. BAIJU S.DHARAN
307	392925	B/O HEERA	0	M	19/Mar/2015	CCHD,DTGA,SMALL PDA,SMALL PFO,GDLV.NSR,BAS	ASO+ PFO CLOSURE	DR. BAIJU S.DHARAN
308	392925	B/O HEERA	0	M	20/Mar/2015	S/P ASO,STENTED STERNUM	DSC	DR. SABARINATH MENON
309	332112	NESRIN. M	4	F	23/Mar/2015	OS ASD,SEV PS,MOD TR,CHB	ASD CLOSURE+PULMONARY VALVOTOMY+ DE VEGA 'S TVA+PPI + PDA LIGATION	DR. SABARINATH MENON
310	329785	SREELAKSHMI	3	F	24/Mar/2015	SV(LV),P/PAB(8/11),CONFLUENT PA/SUB MITRAL ANEURYSM,GDLV	EXCLUSION OF SUB MITRAL ANEURYSM (SUB MITRAL ANEURYSM MARSUPLIZATION,)ATRIAL SEPTECTOMY. DEROOFFING OF CORONARY SINUS, BDG	DR. BAIJU S.DHARAN
311	362747	FATHIMA FAHIMA .O	2	F	25/Mar/2015	ACHD,SA VSD,SEV PAH,NC,SR	VSD CLOSURE + PDA LIGATION	DR. SABARINATH MENON
312	260169	SEHIN P.	8	M	26/Mar/2015	CCHD TA IVS S/P BDG	EXTRACARDIAC FONTANS PROCEDURE WITH 4MM	DR. BAIJU S.DHARAN

							FENESTRATION	
313	348415	MADHAVAN R.	3	M	27/Mar/2015	LARGE MALALIGNED VSD, SEV VAL PS ASD SR	ICR+ PULMONARY VALVOTOMY+TR REPAIR+ MPA PLASTY+ ASD MADE RESTRICTIVE	DR. BAIJU S.DHARAN
314	364109	KHADEEJA JABIN P	4	F	31/Mar/2015	CCHD INFLOW VSD ADDIYIONAL VSD P/PAB (2011),SR	RT THORACOTOMY +BDG	DR. BAIJU S.DHARAN
315	377799	SUDEEP P P	15	M	01/Apr/2015	SVASD,PAPVC OF RUPV ,GDLV,SR	ASD CLOSURE + REROUTING OF PAPVC (DOUBLE PATCH TECHNIQUE)	DR. BINEESH K.R.
316	387617	MARY R.	50	F	02/Apr/2015	SVASD,MILD-MOD PAH,GDLV,SR	ASD CLOSURE+DOUBLE PATCH TECHNIQUE	DR. BINEESH K.R.
317	389352	JAYALEKSHMY S.	55	F	06/Apr/2015	CAD,TVD,REC MI, FAIR LV, MILD CHF, SR, DM, HTN,DLP	CABGX 4 GRAFT(LIMA-LAD, RSVG-OM, RI, PDA)	DR. JAYAKUMAR K
318	393672	JOHN MATHEW	63	M	07/Apr/2015	CAD,TVD,REC ACS,SR, FAIR LV, SR , SINGLE KIDNEY	CABGX5 GRAFT(LIA-LAD, RSVG-DIAGONAL,OM, RCA, AC MARGINAL)	DR. JAYAKUMAR K
319	382562	VENULAL J.P.	39	M	08/Apr/2015	CAD,C/C STABLE ANGINA, SVD, SR	OFF PUMP CABGX1GRAFT(LIMA-LAD)	DR. JAYAKUMAR K
320	347317	ABDUL LATHEEF C.	46	M	08/Apr/2015	RHD,SEV MR,S/P MV REAPIR, MILD MS, MOD TR, MOD PAH, AF,NC	REDOSTERNOTOMY+MVR #29 CHVP	DR. VARGHESE T.PANICKER
321	388115	BALARAJ T.	49	M	09/Apr/2015	CAD,DVD,MILD LVD,HTN,DLP,SR	CABG X 4GRAFT(LIMA-LAD, RSVG-MAJ OM, TERMINAL OM, RI ANTERIOR BRANCH)	DR. JAYAKUMAR K
322	392302	SOMASEKHARA KURUP M.S.	51	M	10/Apr/2015	CAD,TVDRECENT AWMI (02/2015),MOD MR,MILD LVD,SR,DM,H/O PULMONARY EDEMA	CABG X 4 GRAFTS (LIMA-LAD , RSVG -DIAGONAL,OM2,DISTAL RCA)	DR. JAYAKUMAR K
323	387546	RAJESWARI K.	68	F	20/Apr/2015	CAD,TVD,GD LV, SR,DM,HTN,DLP	CABG X 5GRAFT(LIMA-LAD, RSVG-DIAG 1, OM2, TERMINAL OM, RPDA)	DR. JAYAKUMAR K
324	380871	SUBHASH T	57	M	21/Apr/2015	CAD, DVD, MOD LV DYSFUNCTION, SR,DM HTN, DLP	CABG X 3 GRAFT(LIMA- DIAGONAL, RSVG- RPDA, RPLB)	DR. JAYAKUMAR K
325	204351	PHILIP.G.	68	M	22/Apr/2015	CAD, TVD, OLD MI,S/P PTCA, DM,DLP, HTN, GD LV, SR	CABGX 5 GRAFT(LIMA-LAD, RSVG-D1, OM1, RPDA,RPLB)	DR. JAYAKUMAR K
326	386534	CHANDRAN V.	50	M	23/Apr/2015	CAD, REC ACS, TVD, GD LV, HTN,DLP,SR	CABG X 5 GRAFT(LIMA- MID LAD, RSVG- DISTAL LAD, DIAGONAL, OM, RPDA)	DR. JAYAKUMAR K
327	392761	RANSIK K.	16	M	24/Apr/2015	OS ASD,MILD PAH,SR	TPP CLOSURE OF OS ASD	DR. BINEESH K.R.
328	393422	LAIJU K G.	35	M	27/Apr/2015	ACHD,OSASD,SEV PAH, GDLV, SR	TPP CLOSURE OF ASD	DR. VIVEK V. PILLAI
329	386118	SUTHA P.	36	F	28/Apr/2015	RHD,SEV MS,MOD MR,MOD PAH,TRIVIAL AR,SR,GDLV	MVR #25 CHVP + PMLP	DR. BINEESH K. R.
330	386607	VISHNU A.	17	M	29/Apr/2015	ACHD,OS ASD,GDLV,NO PSAH,SR	DC OF ASD	DR. ROHIT DUTTA
331	374785	MINNU SIVADAS	19	F	30/Apr/2015	ACHD,OS ASD,SEV PAH,GDLV,SR	FENESTRATED TANNED PERICARDIAL PATCH CLOSURE OF OS ASD	DR. BINEESH K. R.
332	380884	THOMAS V M	67	M	05/May/2015	CAD,TVD,OLD MI,MILD LVD,SR,DM,HTN,BPH	CABGX 5GR(LIMA-LAD,RSVG-	DR. JAYAKUMAR K

							DIAGONAL,OM1,TERM OM,DISTAL RCA)	
333	383059	BADARUDHEEN M.	55	M	05/May/2015	CAD,ACS(?UA),TVD,GDLV,SR,DM,DLP,?COPD	CABGX5GR(LIMA-PROX LAD,RSVG- DISTAL LAD,OM1,TERM OM,ACUTE MARGINAL)	DR. JAYAKUMAR K
334	394638	DEEPTHI KUMAR .K	45	M	06/May/2015	CAD,ACUTE AWTMI,MILD LVD,SR,HTN	CABGX 4 GR(LIMA-LAD,RSVG- D1,OM2,TERM OM)	DR. JAYAKUMAR K
335	290951	GOPINATHAN S	53	M	06/May/2015	CAD,DVD,RHD,SEV MR,SEV PAH,AF WITH CVR,	CABGX2GRAFTS(RSVG- D1,OM1)+MVR#31SJM+TV REPAIR(33#DURAN ANCOR ANNULOPLASTY RING)	DR. VARGHESE T.PANICKER
336	383525	VEERASUNDARI K.	55	F	07/May/2015	RHD,MOD-SEV AS,MILD MS,MILD AR,GDLV,MOD PAH,NC,SR	AVR (# 19 CHVP)	DR. VARGHESE T.PANICKER
337	382395	THOMAS MATHEW ADACKANATTU.	44	M	08/May/2015	S/P MVR WITH STERNAL SITE GRANULOMA	STERNAL WIRE REMOVAL	DR. BINEESH K. R.
338	390753	VIJAYAN N.	74	M	11/May/2015	SEV CAL AS MILD AR MILD MR DVD GDLV SR DM HTN DLP	AVR#19PM, CABG-(RSVG TO LAD & OM2)(LAD GRAFT PIGGYBACKED TO OM2)	DR. VARGHESE T.PANICKER
339	392809	JOHNY KUTTY K.J.	65	M	12/May/2015	BAV SEV CAL AS, GD LV, SR, DM, HTN	AVR # 21 PM	DR. BINEESH K. R.
340	394612	MANJULABEN M PATEL	40	F	13/May/2015	CONST. PERICARDITIS PTB SEQUELAE R PLEURAL EFFUSION NC SR	PERICARDECTOMY	DR. JAYAKUMAR K
341	384022	SOMAN P.S.	64	M	14/May/2015	ACHD OSASD GDLV NO PAH SR NC	TPP CLOSURE OF OS ASD	DR. VARGHESE T.PANICKER
342	388391	GOPALAKRISHNAN .P.	65	M	14/May/2015	SEV CAL AS MOD AR OSASD GDLV SR	AVR 23 PM	DR. VARGHESE T.PANICKER
343	393792	MADHAVAKURUP N.	56	M	15/May/2015	CAD, TVD, GDLV, TRANSIENT AF, DM, HTN, DLP	CABG X 4 GRAFTS (LIMA - LAD, RSVG - D2, OM1, OM2)	DR. JAYAKUMAR K
344	395006	AYSHA BEEVI H.	55	F	15/May/2015	LA MYXOMA REC STROKE NC SR LT HEMIPLEGIA	LA MYXOMA EXCISION	DR. VARGHESE T.PANICKER
345	389770	PADMAKARAN N.	68	M	18/May/2015	CAD,LMCA,DVD,NSTEMI,GDLV,SR	CABG X 3 GRAFTS(LIMA-LAD,RSVG- D1 AND OM1)	DR. VIVEK V. PILLAI
346	9802877	LALITHAMBIKA.T.	63	F	18/May/2015	RHD, SEV RE-MS, P/BMV, MOD TR, MOD PAH, GDLV, , AF, NC, DM	MVR # 25 CHVP + PMLP	DR. BINEESH K. R.
347	352161	HAMEED KUNJU A	60	M	19/May/2015	CAD,TVD,GDLV,SR,DM,HTN,DLP,THYMIC NODULE	CABG X 4 GRAFTS (LIMA-LAD , RSVG - OM1,OM2,RPDA) + THYMECTOMY	DR. VIVEK V. PILLAI
348	389709	MADHUSOODANAN PILLAI N.	47	M	19/May/2015	RHD,SEV CAL.MS,MOD MR, SEV PAH,SR,GDLV,NC	MVR # 25 CHVP + PMLP	DR. VARGHESE T.PANICKER
349	383572	BEEVIJAN ILIYAS	67	F	20/May/2015	RHD, SEV MS, CAD, DVD, MOD PAH, GDLV, SR,	MVR # 25 PM + CABG X 2 GRAFTS (RSVG - LAD, RPDA)	DR. VIVEK V. PILLAI
350	394848	SUDHA P.	67	F	20/May/2015	BAV, SEV CAL AS, TRIVIAL MR, MOD PAH, GDLV, SR, DM, HTN	AVR # 17 PM	DR. BINEESH K. R.
351	384710	RAMANAN D.	56	M	21/May/2015	CAD,TVD,GDLV,SR,HTN,DM	CABGX3 GR(LIMA - LAD,RSVG-MAJ OM,RPDA)	DR. VIVEK V. PILLAI
352	349623	KUNJAYAMU	54	M	21/May/2015	CAD,SVD,CALC AO,SEV AR,MOD AS,CON	CABGX1 GR(RSVG-DISTAL	DR. VARGHESE

						LVH,SAVSD,MILD LVD,INF PS	RCA)+AVR#23 CHVP+INTERRUPTED CLOSURE OF SAVSD+TV REPAIR	T.PANICKER
353	380086	LEELAVATHY T	62	F	22/May/2015	RHD SEV MS SEV AS MOD AR SEV PAH MILD CAD GDLV DM	DVR (MVR # 23 CHVP + AVR # 19 CHVP)	DR. VIVEK V. PILLAI
354	387309	VIJI PAVITHRAN	34	F	25/May/2015	RHD, SEV AR, MILD MR, MOD LVD, MILD PAH, HYPOTHYROIDISM, ADPKD, MAJ DEPRESSION ILLNESS.	AVR # 21 PM MAGNA	DR. BINEESH K. R.
355	395236	VIMALA CHANDRAN NAIR K.	67	M	25/May/2015	CAD, TVD GDLV SR DM HTN DLP	CABGX 7 GRAFT(LIMA-LAD, RSVG-RI, DIAG, OM1,OM2, RPDA,RPLB)	DR. JAYAKUMAR K
356	393689	SHAJAHAN A.	43	M	26/May/2015	CAD,TVD,GDLV,SR,DLP,DM,HTN	CABGX3 GR(LIMA-LAD,RSVG-D1 & INF BRANCH OF OM	DR. VIVEK V. PILLAI
357	389340	FATHIMA MUHAMMADALI E.M.	42	F	26/May/2015	RHD,SEV MS,GDLV,NO PAH,SR,NC	MVR 25#CHVP+PMLP	DR. BINEESH K. R.
358	394548	SOBHANA RAVI	59	F	27/May/2015	CAD,TVD,MOD LVD, TRIVIAL MR, NO PAH,SR	CABGX 4 GRAFT(LIMA-LAD, RSVG-DIAG, OM, RPDA)+LV PLICATION	DR. JAYAKUMAR K
359	388302	SHAFNA P A.	19	F	27/May/2015	OSASD,MVP OF AML,SEV MR,MOD TR,MILD PAH,SR	MV REPAIR(30#PROFILE 3D ANNULOPLASTY RING)+MODIFIED DEVEGAS+TPP CLOSURE OF OSASD	DR. VIVEK V. PILLAI
360	395746	VIJAYAKUMARAN NAIR G.	66	M	27/May/2015	CAD,TVD,NSTEMI(3/15)GDLV,SR	CABGX4 GR(LIMA-LAD,RSVG-D1,RI AND RPDA)	DR. JAYAKUMAR K
361	201620	SUNIL KUMAR G.	36	M	28/May/2015	RHD,SEV MS,MILD MR,MOD AR,MILD A)S,MOD PAH,FAIR LV,AF,LV CLOT	DVR (MVR # 31 CHVP +PMLP + AVR # 21 CHVP) + LA CLOT REMOVAL + LAEE	DR. BINEESH K. R.
362	392000	DEVANESAN JACOB	62	M	28/May/2015	CAD,LMCA,TVD,GDLV,RECURRENT ANGINA,GDLV,SR,DM,DLP	CABG X 4 GRAFTS (LIMA -LAD ,RSVG-MAJ D,OM,RCA)(RCA ENDARTRECTOMY DONE)	DR. JAYAKUMAR K
363	390101	RAMESH SASIDHARAN NAIR K.	62	M	29/May/2015	CAD,TVD,NSTEMI,MOD-SEV LVD,SR,DM,HTN,DLP	CABGX 6 GRAFT(LIMA-LAD, RSVG-RI,DIAGONAL, OM, RPDA, RPLB)	DR. JAYAKUMAR K
364	33122	SHAJI MATHEW	50	M	01/Jun/2015	S/P ICR FOR TOF, RESIDUAL VSD,SEV AR,NC,SR	VSD CLOSURE +AVR # 25 CHVP	DR. THOMAS MATHEW
365	394248	B/O NISHA	0	M	02/Jun/2015	ACHD,HYPOPLASTIC ARCH, COA,OS ASD, RPA STENOSIS, SR	RADICAL EXTENDED ARCH REPAIR(AUGMENTATION WITH HOMOGRAFT)+COA REPAIR(RESECTION AND END TO END ANASTAMOSIS)+DIRECT CLOSURE OF ASD	DR. BAIJU S.DHARAN
366	312754	SHINAS MUHAMMED	5	M	03/Jun/2015	CCHD, VSD, PS, SR, NC	VSD CLOSURE + INFUNDIBULAR RESECTION	DR. SABARINATH MENON
367	391555	FATHIMATH SUHARA S.	0	F	04/Jun/2015	CCHD, DTGA, LARGE VSD, SEV PAH, MILD PS, SR	ASO +VSD CLOSURE	DR. BAIJU S.DHARAN
368	384696	B/O PUSHPAJA	0	M	08/Jun/2015	CCHD,DTGA,IVS,ASD,S/P BAS,SEV PAH,NC,SR	SENNINGS PROCEDURE	DR. THOMAS MATHEW
369	200641	HARRIS K.S	14	M	09/Jun/2015	CCHD,DILV,HYPOPLASTIC RV,S/P BDG,GDLV,SR	REDOSTERNOTOMY+COMPLETION FONTAN WITH 5MM FENESTRATION	DR. BAIJU S.DHARAN
370	395903	THANKAMANI P.	0	M	10/Jun/2015	CCHD,TA,TGA,VSD,ASD,SR	BDG	DR. SABARINATH MENON

371	354784	ANJANA.B.P.	3	F	11/Jun/2015	PAVCD, CLEFT AML, MILD MR, SR, PAH	REPAIR OF PARTIAL AV CANAL(TPP CLOSURE OF ASD+REPAIR OF CLEFT AML)	DR. THOMAS MATHEW
372	323525	ANNA. S.K	4	F	12/Jun/2015	CCHD, S/P LVOTO RESCTN, B/L BDG FOR TGA,DILV, RV P.ANEURYSM	GORTX PATCH EXCLUSION OF RV PSEUDOANEURYSM+TV REPAIR+ TV ANNULOPLASTY+VSD ENLARGEMENT+CORONARY SINUS DEROOFFING	DR. BAIJU S.DHARAN
373	380879	UVAIS M	8	M	15/Jun/2015	DTGA,IVS,OSASD, REGRESSED LV, SR,NC	MODIFIED SENNING'S REPAIR (RACHS3)	DR. SABARINATH MENON
374	388525	B/O THANKAMANI	0	F	16/Jun/2015	PA,VSD,PDA DEPENDENT CIRCULATION,RCA FROM LAD,DISCONNECTED RPA	RMBTS +LPA AUGMENTATION +PDA LIGATION	DR. BAIJU S.DHARAN
375	291162	ARSHAD B S	6	M	17/Jun/2015	CCHD,SA,LC,LEFT ISOMERISM, DORV, HYPOPLASTIC LEFT AVV,PS	KAWASHIMA PROCEDURE	DR. BAIJU S.DHARAN
376	187156	SINDHU.V.	25	F	18/Jun/2015	CHD, S/P PDA LIG+ SAM EXCISION, RES PDA, SEV LVOTO,AR,MR	PDA CLOSURE BY BPP FROM MPA + SAM EXCISION+ AVR # 21 CHVP	DR. THOMAS MATHEW
377	398257	B/O ARYA	0	F	19/Jun/2015	ACHD,SEV POST SCA COA,PDA DEP CIRC, ARCH HYPOPLASIA,SAVSD, ASD,SEV PAH,GDLV,SR	ARCH ADVANCEMENT+ VSD CLOSURE+ FENESTRATED PATCH CLOSURE OF ASD	DR. BAIJU S.DHARAN
378	379025	JASENA JIJI	3	F	22/Jun/2015	ACHD,SAM,SEV LVOTO,S/P ARCH REPAIR+ COA REPAIR+VSD CLOSURE,GDLV,SR	SAM EXCISION + SEPTAL MYECTOMY	DR. BAIJU S.DHARAN
379	398452	ASHWIN A.S.	0	M	23/Jun/2015	CCHD,DTGA, INTACT IVS, REGRESSING LV,P/BAS, SMALL PDA, SR	ASO	DR. BAIJU S.DHARAN
380	378428	JOBIN MEPPURATHU	17	M	26/Jun/2015	ACHD, SP VSD, MILD AR, NO PAH, SR	VSD CLOSURE	DR. ROHIT DUTTA
381	341057	SHAMLA SHERIN	10	F	29/Jun/2015	ACHD, SEV AS, SEV AR, P/BAV , CON LVH, SR	AV REPAIR	DR. BAIJU S.DHARAN
382	187156	SINDHU.V.	25	F	30/Jun/2015	S/P AVR, INGUINAL SEROMA	SEROMA DRAINAGE	DR. THOMAS MATHEW
383	377369	MOHAMMED MIHRAN A.N	2	M	30/Jun/2015	ACHD,SA VSD,RCC PROLAPSE, MOD PAH, SR, DEV DELAY	VSD CLOSURE +AV REPAIR	DR. THOMAS MATHEW
385	384592	ASHINA J S JOHN	1	M	30/Jun/2015	ACHD, DOUBLE BARREL AORTA, SEV PRE SUBCLAVIAN COA, GD LV,SR	COA REPAIR	DR. BAIJU S.DHARAN
386	187156	SINDHU.V.	25	F	01/Jul/2015	LYMPHATIC LEAK LEFT GROIN	LYMPHATIC LIGATION	DR. THOMAS MATHEW
387	389475	ADHYA KRISHNA K.S.	1	F	01/Jul/2015	ACHD, ASD, VSD, PAH, SR,DOWNS SYNDROME	VSD CLOSURE	DR. THOMAS MATHEW
388	397803	B/O REMYA	0	F	02/Jul/2015	CCHD, TGA, SP VSD, 1LCX2R,DIGEORGE SYNDROME	ASO+VSD CLOSURE+PFO	DR. BAIJU S.DHARAN
389	393032	RIZA FATHIMA A.C.	0	F	03/Jul/2015	ACHD, VSD,SEV PAH,PDA	VSD CLOSURE+ FENESTRATED ASD CLOSURE+ PDA INTERRUPTION	DR. BAIJU S.DHARAN
390	388555	FATHIMA FAIHA T.N.	1	F	06/Jul/2015	TOF,CONFLUENT PA,RT ARCH,NC,SR	ICR+TAP	DR. SABARINATH MENON
391	372616	AROKYA VIJAYI R	1	M	07/Jul/2015	SS,DC,CCTGA,INFLOW VSD,SEV PS,SEV LT AVVR,SR	DOUBLE SWITCH (HEMI MUSTARD + BDG+ RASTELLI PROCEDURE)	DR. BAIJU S.DHARAN
392	348473	JERSHIN JINO	3	M	08/Jul/2015	SS,LC,TOF WITH PA,CONFLUENT PA,NC SR	ICR+RVOT PATCH+ DIRECT CLOSURE OF MULTIPLE MUSCULAR	DR. SABARINATH MENON

							VSD	
393	396281	B/O MEHABOoba	0	M	09/Jul/2015	TYPE II TRUNCUS ARTERIOSUS,PM VSD, SEV PAH, LT ARCH,SR	TRUNCUS ARTERIOSUS REPAIR	DR. BAIJU S.DHARAN
394	389038	GOMATHY P.	7	F	10/Jul/2015	OSASD, LARGE INFLOW VSD WITH MULTIPLE ADDITIONAL MUSCULAR & APICAL VSD, CLEFT AML, MILD MR, GOOD BV FUNCTION, SEVERE PAH	ICR(TPP CLOSURE OF ASD, GORTEX PATCH CLOSURE OF INFLOW VSD, DIRECT CLOSURE OF ADDITIONAL VSDS)	DR. BAIJU S.DHARAN
395	383110	SATHYA .M.	5	F	13/Jul/2015	ACHD INFLOW VSD, PDA ,SEV PAH , SR	VSD CLOSURE+PDA LIGATION+ DIRECT CLOSURE OF ADDL MUSCULAR VSD	DR. THOMAS MATHEW
396	9006622	SANOOP.K.B.	25	M	14/Jul/2015	S/P TCPC FOR DORV SEV PS SINUS NODE DYSFUNCTION JUNC ESCAPE	EPICARDIAL (DOUBLE CHAMBER-LA&RV)PPI	DR. THOMAS MATHEW
397	385438	HASRA FATHIMA	1	F	15/Jul/2015	P/VSD CLOSURE + TV REPAIR, SCHIMITAR SYNDROME	RPV REROUTING TO LA+TV REPAIR	DR. BAIJU S.DHARAN
398	385239	B/O SAJITHA	0	F	16/Jul/2015	PA, IVS ,LARGE ASD, PDA DEP CIRC, CYANOTIC SPELLS	BDG	DR. THOMAS MATHEW
399	344939	AARSHA K VALSARAJ	16	F	17/Jul/2015	TOF,PA,P/RMBTS(98),LMBTS(03),GDLV,SR	ICR WITH CONDUIT REPAIR+B/L BTS TAKE DOWN	DR. THOMAS MATHEW
400	344939	AARSHA K VALSARAJ	16	F	18/Jul/2015	CARDIOPLEGIA CANNULATION SITE AORTIC BLEEDING	RE EXPLORATION WITH SUTURING OF BLEEDING SITE OF AORTA	DR. THOMAS MATHEW
401	399698	B/O SAJIDA	0	M	20/Jul/2015	PA,HYPOPLASTIC TV&RV,ASD,RCA-RV COMMUNICATION,PDA,SR	RMBT SHUNT (3MM PTFE)	DR. SABARINATH MENON
402	388476	NASLIN N.	0	F	21/Jul/2015	LARGE INLET VSD WITH SUBAORTIC EXTENSION,SEV PAH,GDLV,SR	VSD CLOSURE WITH GORTEX PATCH	DR. SABARINATH MENON
403	315050	KHADEEJA NAZEER	7	F	22/Jul/2015	SPVSD,MILD AR,NO PAH,SR,SEIZURE DISORDER,LT HEMIPARESIS	VSD CLOSURE	DR. BAIJU S.DHARAN
405	351704	ANUSHYA.M.	2	F	23/Jul/2015	TOF CON.PA,GDLV,SR,NC	ICR(TAP+MONOCUSP RECONSTRUCTION)	DR. SABARINATH MENON
406	351704	ANUSHYA.M.	2	F	23/Jul/2015	TOF GOOD.PA,SR,NC	ICRWITH TAP	DR. SABARINATH MENON
407	398995	B/O REKHA	0	M	24/Jul/2015	DTGA, SP VSD, PDA SEV PAH, SR NC	ASO+VSD CLOSURE +ASD CLOSURE+ PDA INTERRUPTION	DR. THOMAS MATHEW
408	398995	B/O REKHA	0	M	25/Jul/2015	P/ASO FOR DTGA,SPVSD,SEV PAH,REGRESSED LV(STENTED STERNUM)	DELAYED STERNAL CLOSURE WITH LA LINE REMOVAL	DR. THOMAS MATHEW
409	365248	ANNA RAJU	3	F	27/Jul/2015	DTGA LARGE SAVSD OSASD SEV VAL PS GDLV, NC, SR	RASTELLI PROCEDURE (19# AORTIC HOMOGRAFT)	DR. BAIJU S.DHARAN
410	378742	ARJUN.P	1	M	28/Jul/2015	SA LC CA UNBALANCED AVCD SV (RV) MILD AVVR ABERRANT RSCA	BDG	DR. THOMAS MATHEW
411	303634	ALBIN PATHROSE	6	M	28/Jul/2015	OSASD MOD PAH LT LL COLLAPSE DUE MPA COMPRESSING BRONCHUS	ASD CLOSURE	DR. THOMAS MATHEW
412	349653	MUHAMMED ASEEB T.P.	3	M	29/Jul/2015	TOF, GOOD PAS, SR	ICR+MONOCUSP REPAIR WITH TRANSANNULAR PATCH	DR. SABARINATH MENON
413	353715	SIKHA RAJ .K.P	2	F	30/Jul/2015	TOF ,GOOD PA ANATOMY, SEV INFUNDIBULAR PS, ADDITIONAL MUSCULAR VSD,,SR, MOYA MOYA DISEASE	ICR WITH TAP WITH MONOCUSP RECONSTRUCTION OF RVOT PATC+ DC OF ADDL VSD+ TV REPAIR+ PFO MADE RESTRICTIVE	DR. SABARINATH MENON

414	385239	B/O SAJITHA	0	F	31/Jul/2015	P/BDG FOR PA,IVS,ASD, SSI	WOUND TOILETTING & SECONDARY SUTURING	DR. ROHIT DUTTA
415	399838	B/O RAMSEENA SUDHEER	0	M	31/Jul/2015	ALCAPA,SEV LVD, MILD TO MOD MR,CONTROLLED HF, NO PAH,SR	LCA TRANSLOCATION	DR. BAIJU S.DHARAN
416	399548	SUDHEER KUMAR A.	45	M	03/Aug/2015	CAD TVD GDLV SR DLP HTN	CABG X 5 GRAFT(LIMA-LAD, RSVG-D1, OM1,INFERIOR BRANCH OF OM3, RPDA)	DR. JAYAKUMAR K
417	398518	RADHAKRISNAN NAIR R.	60	M	04/Aug/2015	CAD TVD GDLV SR DM HTN DLP	CABG X 5 GRAFTS (LIMA- LAD, RSVG - D1, OM1, OM2, DISTAL RCA)	DR. JAYAKUMAR K
418	393892	SIVANKUTTI A.K.	48	M	04/Aug/2015	CALCIFIC AORTIC VALVE,SEV AS,MOD AR,TRIVIAL MR,MILD LVD,SR,NC	AVR#23 SJ REGENT	DR. BINEESH K. R.
419	397444	DEEPA ANIL	22	F	05/Aug/2015	MARFAN'S SYNDROME,ANNULO AORTIC ECTASIA,MOD MR,MILD AR,MOD TR,GD LV,SR.	BENTALL'S PROCEDURE # 23 CHVP_+ 24 ALBOGRAFT + MV REPAIR # 35 DURAN ANCORE ANNULOPLASTY RING	DR. JAYAKUMAR K
420	398655	KUMAR P.K.	59	M	06/Aug/2015	CAD, TVD, GDLV, SR, HTN	CABG X 6 GRAFTS (LIMA- LAD, RSVG- D2, OM1, OM2, OM3, DISTAL RCA)	DR. JAYAKUMAR K
421	386592	RAMAKRISHNAN N.	60	M	07/Aug/2015	SEV CALC AS,GDLV, MILD MR,SR,NC	AVR# 21 CHVP	DR. VARGHESE T.PANICKER
422	279520	KANAKA BAI S	66	F	10/Aug/2015	CAD, TVD, GDLV, SR, DLP, HTN, HYPOTHYROID, S/P PCI TO RCA	CABG X 5 GRAFTS (LIMA-LAD, RSVG- DISTAL LAD, D1, MAJ OM, RPDA)	DR. JAYAKUMAR K
423	385464	MOHANAN K.	51	M	11/Aug/2015	CAD,ACS,UA,TVD,GD LV,SR,DM,HTN,DLP	CABGX3GR(LIMA-LAD,RSVG-MAJ OM AND RCA)	DR. JAYAKUMAR K
424	399985	VASANTHAKUMAR A.	34	M	12/Aug/2015	MARFANS SYND, ANNULO AO ECTASIA, SEV AR, DIL LV,MOD LVD,SR	MODIFIED BENTALLS PROCEDURE(AVR 27#CHVP+28 #ALBOGRAFT)	DR. JAYAKUMAR K
425	397261	SONA M.C.	33	F	13/Aug/2015	RHD,SEV CALC MS,TRIV MR,FAIR LV,PAROX AF	MVR#21 CHVP	DR. BINEESH K. R.
426	386654	SOMAN D.	60	M	14/Aug/2015	RHD, SEV CALCIFIC MS,SEV MS, MOD PAH, GDLV,NC	MVR#25 CHVP	DR. BINEESH K. R.
427	389054	ABDUL MAJEED	49	M	17/Aug/2015	RHD SEV CAL MS, MILD MR, AF, GDLV, LEFT POSTEROLATERAL DIAPHRAGMATIC HERNIA	LEFT DIAPHRAGMATIC MESHPLASTY + MVR # 27 SJM	DR. VARGHESE T.PANICKER
428	399425	GEORGE JOSEPH	68	M	17/Aug/2015	CAD TVD, LMCA, SEV LVD, SR, DM, HTN	CABG X 5 GRAFTS (LIMA - LAD, RSVG - RPDA, RPLB, D1, MAJ OM)	DR. JAYAKUMAR K
429	385971	SURESH KUMAR V.	48	M	18/Aug/2015	CAD,TVD,GDLV,P/PCI LAD RCX,SR,DM,DLP,SMOKER	CABG X 4 GRAFTS(LIMA-LAD,RSVG-MAJOR DIAGONAL,MAJOR OM,RPDA)	DR. JAYAKUMAR K
430	400356	BABY KUTTY K.	62	M	19/Aug/2015	CAD,LMCA,TVD,ACS,MILD LVD,SR,DM,HTN,DLP	CABG X 5 GRAFTS(LIMA-LAD,RSVG-MAJOR DIAGONAL,MAJOR OM,RPDA,RPLB)	DR. JAYAKUMAR K
431	396534	ROSE MARY M.	52	F	20/Aug/2015	RHD,SEV MS,SEV AS,MILD LVD,REAC AIRWAY DISEASE	AVR#19 CHVP+ MITRAL VALVE REPAIR(COMMISSUROTOMY+ DECALCIFICATION)	DR. VARGHESE T.PANICKER

432	392777	HAMSAKUTTY K P.	64	M	20/Aug/2015	SEV CAL AS,MOD AR,CONC LVH,GDLV,SR,HTN,HIAT HERNIA,EXTRAPONTINE MYELINOSIS	AVR#21 PM(CEP THEON RSR TFX)	DR. VARGHESE T.PANICKER
433	394583	SREE KUMAR S.	48	M	01/Sep/2015	SEV CALC AS,MOD AR,DIALATED AORTA,GDLV,NC	AVR#21CHVP+AORTOPLASTY	DR. VIVEK V. PILLAI
434	394020	SAKEER HUSAIN	41	M	02/Sep/2015	ACHD, OSASD, MILD MS, MILD MR, TRIVIAL MR, GDLV, SEVERE PAH, SR, NC	ASD CLOSURE(TPP)	DR. VARGHESE T.PANICKER
435	394502	DEVAPALAN NAIR G.	61	M	02/Sep/2015	CAD TVD GDLV SR DM HTN DLP	CABG X 5 GRAFTS(LIMA-->LAD, RSVG-->MAJ OM, MAJ DIAGONAL, RPDA, RPLB PIGGYBACKED TO PDA	DR. JAYAKUMAR K
436	8904127	MARY POULOSE	64	F	03/Sep/2015	RHD P/CMV (1991) RE SEV MS MILD PAH AF CVR NC	MVR# 25 PERIMOUNT PLUS(TPS)	DR. VIVEK V. PILLAI
437	394553	JANAKI P.K.	64	F	04/Sep/2015	CAD TVD GDLV SR DM HTN DLP	CABGX4GR(LIMA-LAD,RSVG-MAJ DIAGONAL,MAJ OM,RPDA)	DR. JAYAKUMAR K
438	393562	THULASIDHARAN NAIR N.	45	M	07/Sep/2015	CAD TVD MILD LVD SR ANAMOLOUS RCAA FROM LCS	CABG X 5 GRAFT(LIMA- MID LAD, RSVG- DISTAL LAD, DIAGONAL, OM, DISTAL RCA)	DR. VIVEK V. PILLAI

INTERESTING CASES

INTERESTING CASES

- **PERICARDECTOMY**
- **EXCISION OF LA MYXOMA**
- **AV REPAIR**
- **ARTERIAL SWITCH OPERATION**
- **MODIFIED BENTALLS PROCEDURE**
- **LCA TRANSLOCATION**
- **COA REPAIR**
- **FONTAN PROCEDURE**
- **CAD WITH FAMILIAL HYPERCHOLESTEROLEMIA**
- **TRUNCUS ARTERIOSUS**

PERICARDECTOMY

DIAGNOSIS: POST TUBERCULAR CONSTRICTIVE PERICARDITIS

PROCEDURE: PERICARDECTOMY

HISTORY: 40 yrs. old female, came with h/o dyspnoea and pedal oedema since 14 years. She was evaluated & found to have tuberculous pleural effusion & was on antituberculous medication for 2 yrs. following which she improved symptomatically. After 5 years she was re-evaluated for weight loss and anorexia & was restarted on ATT. Currently patient c/o intermittent leg edema and dyspnea/anorexia.

DOE FC III ,No PND/AOE.

She was evaluated & found to have restrictive pericarditis

PHYSICAL EXAMINATION: Afebrile, emaciated

Pallor +,bilateralpedeledema +.No icterus/ cyanosis/clubbing/lymphadenopathy.

JVP: Elevated to angle of jaw

PR: 86/min, Regular, All peripheral pulses felt BP: 140/70 mm Hg

CVS:S1 normal, S2 soft, pericardial rub present

RS: Bilateral breath sounds absent in the base.

Stony dullness present bilateral infrascapular and infra-axillary areas.

INVESTIGATIONS:

Blood Investigations: Normal

CXR:CTR 60%, bilateral plural effusion, PVH

ECG:SR, PR 120, QRS axis +45, V1 r/s 2/5, V6 R/S4/0.

Echo: Restrictive physiology, prominent on septal side, biatrial enlargement, normal BV function, mod TR/PAH, mild to mod MR. 6mm PE +.

CAG:Normal coronaries

SURGICAL FINDINGS: Thick Pericardium surrounding all chambers of heart with minimal calcifications.Dense adhesion present with Myocardium.

Pre-op TEE: Gd LV function,Restrictive filing patterns with respiratory variation seen. Post-op TEE: FAIR LV, septum contracting normally.No restrictive pattern with respiration.

CPB DATA & MYOCARDIAL PROTECTION:

Membrane oxygenator & roller pump.

Aortic cannula - 24 Fr Edwards, Venous cannula: Single two stage cannula 34/46.

PROCEDURE: Standard midline sternotomy. Pericardium dissected around aorta first with great precaution avoiding injury to aorta. Then pericardium was incised in midline with help of dissecting scissor and cautery.Rt Pleuralopened suction and 500 ml fluid drained and sent for culture. Rt Pericardium was dissected from inferior surface with help of harmonic scalpel on Rt side with dissection extended up to removal of pericardial adhesions of RA and RV completely and thick calcified pericardium excised and similarly dissection on Lt

side carried out till removal of pericardial adhesions of LV completely, including inferior adhesions with diaphragm. Thick calcified pericardium excised. Rt Pleural drain inserted. Two mediastinal drains inserted, haemostasis confirmed. Chest closed in layers. Sternum closed with 6 no 6 SS wires, subcutaneous tissue with 2-0 vicryl and skin with 3-0 monocryl-subcuticular.

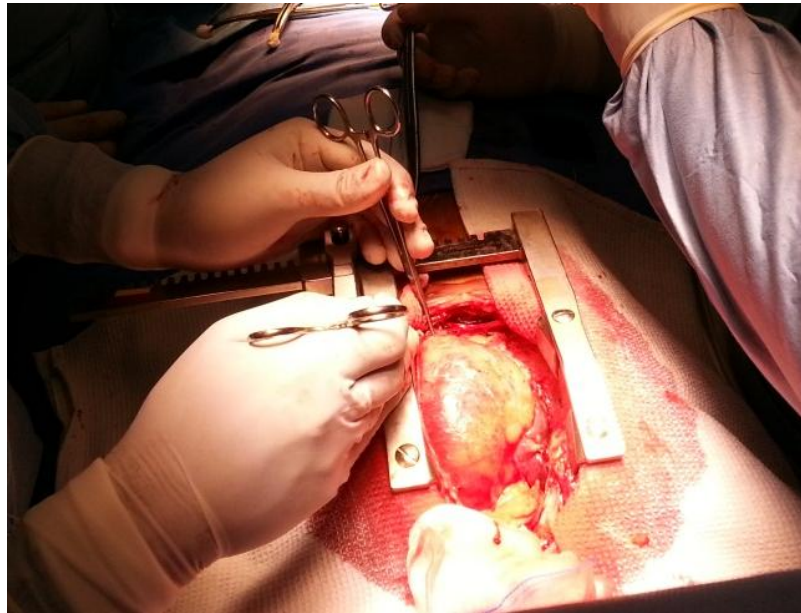
Patient shifted to the ICU with stable hemodynamic for elective ventilation.

COURSE IN HOSPITAL: The post-operative course and recovery in the hospital were uneventful

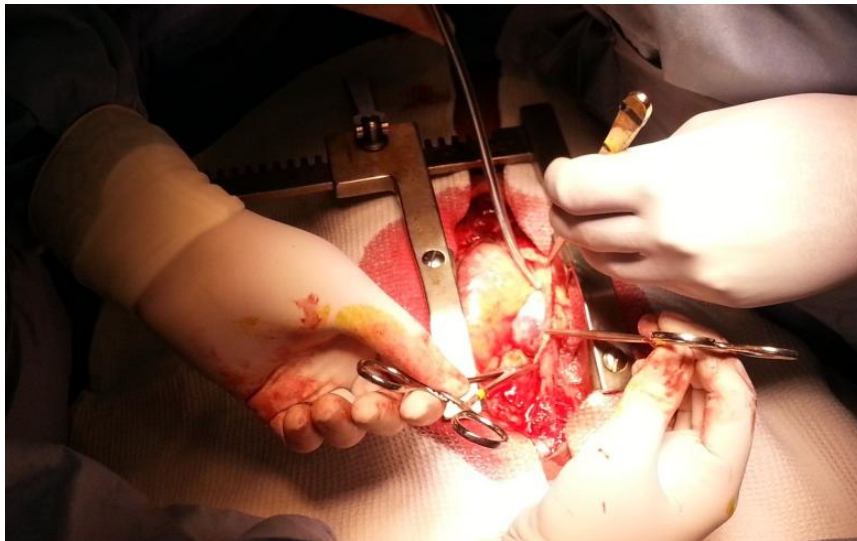
INVESTIGATIONS PRIOR TO DISCHARGE

ECHO: Good LV/RV/PV function, no Pericardial Effusion.

CXR: No pneumothorax, collection.



PERICARDECTOMY



ADHESIOLYSIS

LA MYXOMA

DIAGNOSIS: LA MYXOMA

PROCEDURE: EXCISION OF LA MYXOMA

HISTORY: Patient presented with sudden onset weakness of right upper and lower limbs. No history of headache, vomiting, seizure, altered sensorium

Past History: History of acute right MCA stroke in 10/4/15 thrombolysis with ivtPA, Later on evaluation diagnosed to have left atrial myxoma

ON EXAMINATION: Afebrile, PR- 80/min, peripheral pulses felt. BP - 140/70mm of Hg

No pallor/icterus/cyanosis/ pedal edema/generalised lymphadenopathy

CVS - S1 S2 heard, no S3, no murmurs

RS - B/L NVBS heard no added sounds

CNS

Disoriented ,Bilaterally pupils equal and reactive

Motor system:

Tone:	Right	Left
Upper limb	Hypotonia	normal
Lower limb	Hypotonia	normal
Power:	Right	Left
Upper limb	0/5	5/5

Lower limb			3/5			5/5	
DTR :	BJ	SJ	TJ	KJ	AJ	Plantar	
Right	2+	2+	2+	2+	2+	Extensor	
Left	2+	2 +	2+	2 +	2+	Flexor	

INVESTIGATIONS:

Blood Investigations: Normal

ECG –SR,HR 90/min, QRS axis +30, No ST changes

ECHO- 24x18mm mass attached to LA moving in and out s/o atrial myxoma.

No RWMA, no LA/LV clots/PE,EF -67%; Good LV function

CT Head and angiogram: No early ischemic changes, normal intracranial and extra cranial vessels.

CAG –Normal

SURGICAL FINDINGS

Sternum osteoporotic, mediastinum normal

IAS bulging to RA, PA soft.

Pre op TEE- 22x 25 mm myxoma attached to fossa ovalis

Post Op TEE- No residual ASD, No MR

CPB DATA & MYOCARDIAL PROTECTION:

Heparin protamine chemistry.

Roller pump-membrane oxygenator.

Antegrade root tepid blood cardioplegia.Core cooling to 31 degrees.

Topical iced saline. Aortic root vent.

Ao: 24FrEdwards , SVC 28 RMI , IVC:30 RMI

CPB: 71 min, ACC: 34min.Post procedure fluid: Gain 410 ml, Urine on pump: 350 ml.

PROCEDURE: Median sternotomy. Minimal Thymectomy. Pericardium opened and pericardial well created after harvesting a pericardial patch. SVC dissected and looped below azygous vein entry.Aortic , SVC and IVC purse string taken.Went on bypass with aorto -SVC-IVC cannulation.Cardioplegia cannula inserted and antegradecardioplegia given after cross clamping aorta. Heart arrested immediately in diastole. Topical ice saline applied.SVC, IVC snugged and went on total bypass. SVC-RA Junction opened safeguarding SA node and incision extended on RA till lower border of ASD is seen, proline 5/0 stays taken. Stay suture taken over IAS bulge and excised in total with LA myxoma and sent for HPE.Tanned pericardial patch used for closing of IAS defect. RA closed in 2 layer Heart deaired and cross clamp removed.Heart picked up in sinus rhythm. Ventilation started Came of CPB without supports. Heparin reversed and decannulated in stages.1 RV pacing wire taken . After checking hemostasis, 1 mediastinal and one right pleuro mediastinal drain placed. Sternum closed with 6 stainless steel wires, muscle and subcutaneous tissue with 2-0 Vicryl in 3 layers and subcuticular with 3-0 monocryl. Patient shifted to ICU in stable condition for elective ventilation and monitoring.

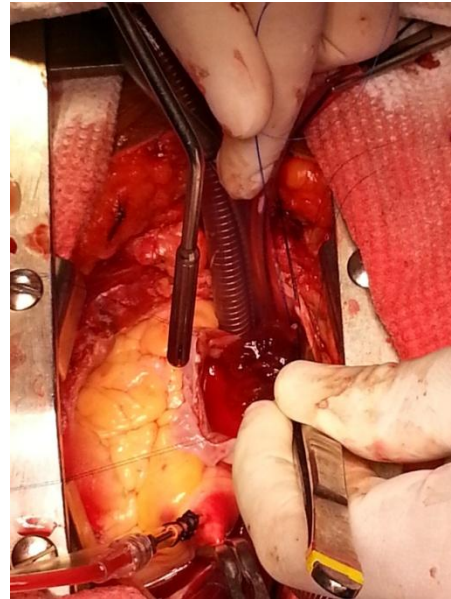
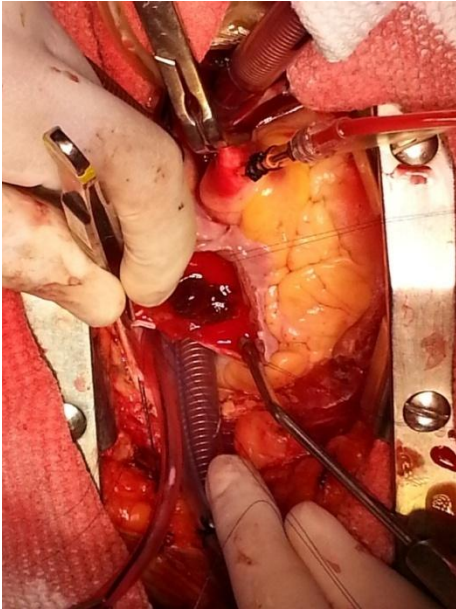
COURSE IN HOSPITAL: The post-operative course and recovery in the hospital were uneventful. For weakness of right side of body patient was advised follow up in Neurology OPD.

INVESTIGATIONS PRIOR TO DISCHARGE

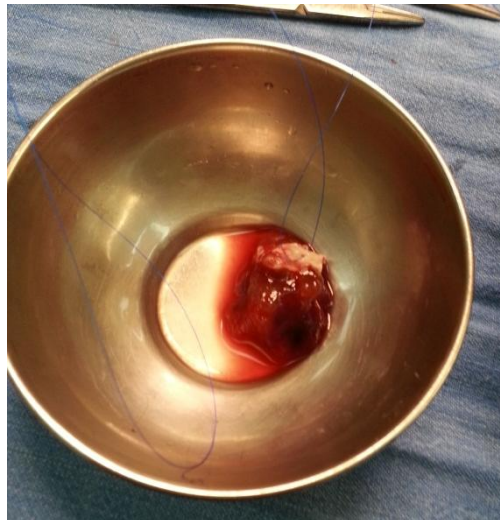
ECHO - No myxoma seen, no MR, No RWMA, no LA/LV clots/PE, EF -67%.

Good LV function

EXCISION OF LA MYXOMA



LA MYXOMA SEEN FROM RA



SPECIMEN OF LA MYXOMA

AV REPAIR

DIAGNOSIS:ACHD,SEV AS,SEV AR, P/BAV,CONCENTRIC LVH,SR

PROCEDURE: AV REPAIR

HISTORY:This second born female child of NCM, born by LSCS at term, with no significant ANH, with birth weight 2.1kg. Diagnosed as CHD when evaluation for pneumonia. H/o feeding /breathing difficulty (+), initially treated with diuretics. BAV done at 3 1/2yrs of age.C/o FC II DOE .No history of spells/TIA. Immunised to age.

PHYSICAL EXAMINATION:

No pallor, icterus, cyanosis, clubbing, LN, Pedal oedema

PR:96/min, regular, all peripheral pulse palpable

BP-120/40 mm of Hg. JVP not raised

CVS: Precordium (N) S1S2(+) ESM at Aortic area 3/6. RS: AE B/L +.

Chest: Clear. P/A Soft, no organomegaly. CNS: No FND.

INVESTIGATIONS:

Blood Investigations: Normal

CXR: CTR 0.60, Lung fields congested. ECG: SR@ 85/min, LVH +, QRS 60+

ECHO: SS, LC, PVS->LA, AO22 LA25 AR 3-4+, Bicuspid AV, NO ASD/VSD.

SURGICAL FINDINGS: Sternum Normal, Mediastinum Normal, SS, LC, Aorta normal, normal systemic and pulmonary venous drainage NRGV, RA/ RV normal

MPA and branch PA of adequate size

Aortic valve:BAV: Annulus 18: Perforation in LCC cusp with thickened leaflet margins and rolled out. Right coronary ostium very small B/L pleura open

Post CBP Line pressure Ao-71/58(64) LV 96/14(57) Gradient approx. 25 mm of Hg

CPB DATA AND MYOCARDIAL PROTECTION:

Heparin-protamine chemistry.

Roller pump. Antegrade del- Nidocardioplegia to aortic root, topical cooling with cold saline. Core cooling to 30 deg.

Aortobicaval cannulation.

Aorta: 18 Fr , RA :24 Fr DLP, IVC:20 Fr DLP

CPB time: 77 min. ACC time: 55 min.

Vent:LA(RSPV) and aortic root vent. Urine on pump 600 ml, Fluid gain 200 ml

PROCEDURE: Standard midline sternotomy. Patch harvested.

Thymectomy done. Aorta /PA and branch PA mobilized. Pericardium and hitched.

Heparinised, Aorto-RA -IVC bypass instituted. PDA chord like, clipped. LA vent

put through RUPV. Cooled. aorta cross clamped. Cardioplegia cannula inserted,

diastolic arrest of the heart achieved. Myocardium protected with iced saline.

Aorta opened 2 cm above AV transversely. Aortic valve Anatomy assessed.

Deformed and perforated leaflet excised. Aorta sized to 18 hegar. Tanned

pericardial patch cut in trapezoid shape, according to cusp length and height.

Aortic valve reconstructed with pericardium and margin sutured with 4/0 Gortex

suture, and commissural resuspension done with 5/0 proline. Valve tested for structural integrity. Rewarming started. Aorta closed in 2 layer with 5/0 proline. 2 RA and 2RV pacing wire taken. Heparin reversed. Decannulated in stages. Heart picked up in SR on 2.5 mcg/kg/min of Dobutamine. Left pleural and Rt pleural mediastinal and one mediastinal drains inserted. Haemostasis achieved. COSEAL spray applied in view of redo surgery in future to prevent adhesions. Chest closed in layers, sternum with 5 No 1 SS wires sternum, 3-0 monocryl for subcutaneous tissue and 4-0 monocryl sutures for skin. Shifted to ICU with stable hemodynamic for elective ventilation with supports of Dobutamine 2.5mcg/kg/min.

COURSE IN HOSPITAL: Uneventful post-operative period.

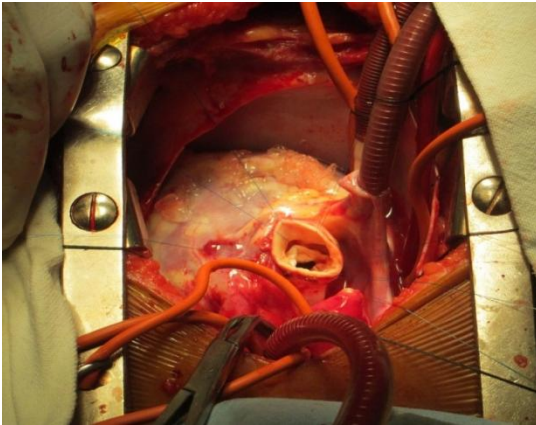
INVESTIGATIONS PRIOR TO DISCHARGE:

ECG: SR, no fresh changes.

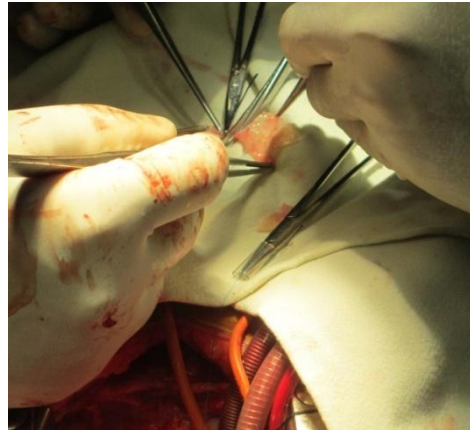
CXR: B/L lung fields clear, no pneumothorax, no effusion.

ECHO: No PE, good LV/RV function, good AR repair, AS 40mmHg, RVSP-23+RA, TR 1-2+.

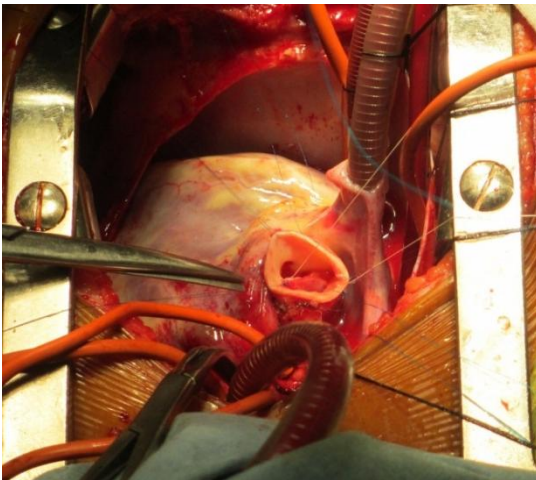
AV REPAIR



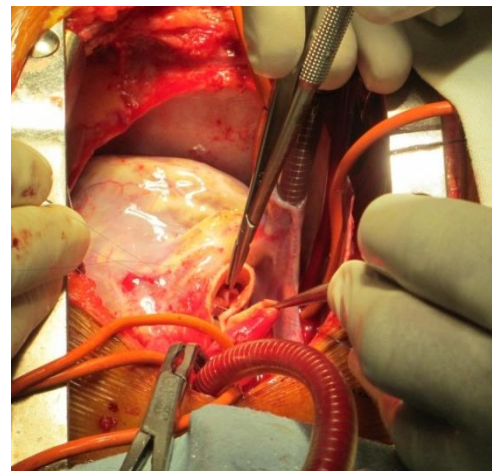
AORTIC VALVE EXPOSED



PERICARDIUM TRIMMING



LEAFLET EXTENSION TECHNIQUE



AORTIC ANASTOMOSIS

ARTERIAL SWITCH OPERATION

DIAGNOSIS:CCHD,DTGA, INTACT IVS, REGRESSING LV,P/BAS, SMALL PDA, SR

PROCEDURE: ASO

HISTORY:15 day old male,3rd born child of NCM, by FTND with birth weight 3.4kg with no significant antenatal history diagnosed as CHD at birth on evaluation for cyanosis.No h/o cyanotic spell,feeding difficulty, breathing difficulty

PHYSICAL EXAMINATION:

Cyanosis +, Afebrile, No pallor/icterus/clubbing

Pulse-130/min, regular, all peripheral pulses palpable SpO2-65%, RR-50/min

CVS:Apical impulse left 5th ICS, S1 S2 + single , 2/6 ESM@LLSB

RS: AEBE, No added sounds

P/A: Soft, no organomegaly, ascites CNS: No FND

INVESTIGATIONS:

Blood Investigations :Normal

CXR: CTR 0.6, Lung fields congested. ECG: SR, 140/min, RVH

ECHO: SS,LC, d-TGA, intact IVS, Small ASD, PDA, Regressing LV

SURGICAL FINDINGS: SS/LC, normal systemic and pulmonary venous drainage, Aorta anterior and PA posterior. PA almost equal to Aorta.

Atrioventricular concordance, Ventriculoarterial discordance, Large ASD (post BAS) present. Intact ventricular septum. Small PDA present. LV regressed.

Coronaries: LCX2R

CPB AND MYOCARDIAL PROTECTION DATA:

Roller pump and Membrane Oxygenator.

Heparin-Protamine chemistry.

Cannulae: Aortic: 10Fr Biomed, RA: 18 BARD, IVC: 14Fr DLP.

Antegrade Delneidocardioplegia, followed by direct ostial cardioplegia.

Myocardium protected with topical iced saline.

Core cooling to 25 degrees.

LA vent through the RSPV, Aortic root vent.

CPB Time: 175min, ACC Time: 116 min.

Urine Output on pump: 55ml, MUF: 100 ml, CUF 300ml.

PROCEDURE: Standard midline sternotomy. Thymectomy done. Patch harvesting pericardiotomy, which was given for tanning. Aorta dissected and PA dissected up to hilum, branches looped. Heparinised. Aorta and RA cannulated and went on Aorto atrial bypass after snugging branch PA's. IVC cannulated and connected and CPB instituted. PDA ligated and divided. LA vent inserted. Marker stays taken on the PA, at the planned sites of coronary translocation. Cooling started. Cardioplegia cannulation done. Aorta cross clamped. Antegradecardioplegia delivered and prompt diastolic arrest of the heart achieved.

Myocardium protected with iced saline slush. Aorta transected. Coronary buttons harvested and adequate length of Coronary arteries mobilised. Neo PA reconstructed with tanned pericardial patch posteriorly and the posterior commissure resuspended. PA transected just below the bifurcation of the PA. Lecompte manoeuvre done. Incisions for coronary buttons made on the neo aorta at the site of marker stitch. Posterior wall of neo aorta anastomosed to the posterior wall of transected distal aorta. Coronary button anastomosis done after confirming the lie of the coronaries and anterior wall anastomosis completed. Rewarming started. Went on total bypass after pushing in the RA cannula into SVC, and snugging SVC and IVC. RA opened and BAS flap identified, and closure done with 6-0 prolene. RA closed in single layer. SVC and IVC de-snugged, back on partial bypass. Dearing done and aortic cross clamp removed. Neo pulmonary artery anastomosed to the PA. Haemostasis confirmed. Heart picked up in sinus bradycardia, for some time required pacing later own rate picked up to 140/min. Came off bypass in stages with supports Milrinone 0.75mcg/kg/min and . MUF done for 100 ML. Protamine reversal. Aorta decannulated. Haemostasis achieved. Two RA, RV pacing wires.2 Mediastinal and left pleural drains inserted. Sternum stented electively. Skin closed with bagota bag. Baby was shifted to CHICU on supports for elective ventilation.

COURSE IN HOSPITAL: Uneventful recovery

INVESTIGATIONS PRIOR TO DISCHARGE:


ECG: SR, no fresh changes.

CXR: B/L lung fields clear, no pneumothorax, no effusion.


ECHO: No Neo AR/PR, Ao 1.2m/s, Neo PA Valve 1m/s

GD LV/RV function, 2mm ASD L->R

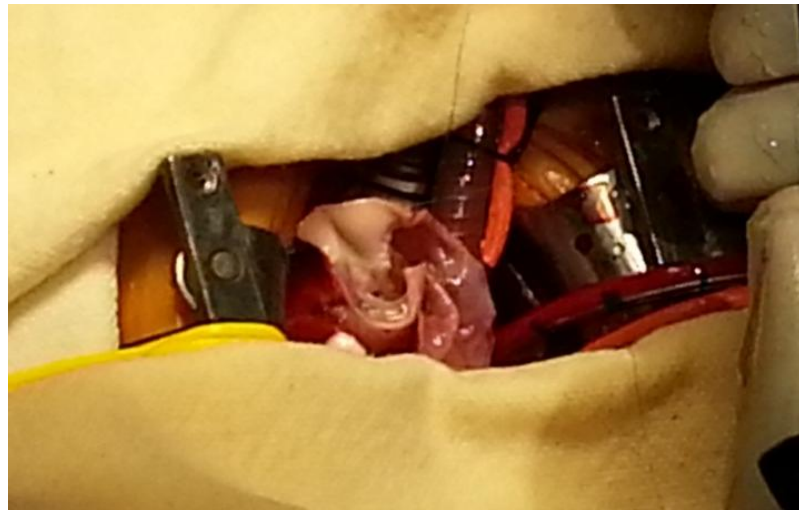ARTERIAL SWITCH OPERATION




AORTA ARISING FROM RV




CORONARY BUTTON HARVESTING



PERICARDIUM FOR POSTERIOR WALL OF NEO PA



CORONARY BUTTON BEING ANASTOMOSED TO NEO AORTA



REPAIR COMPLETED

MODIFIED BENTALLS PROCEDURE

DIAGNOSIS: MARFANS SYND, ANNULO AO ECTASIA, SEV AR, DIL LV,MOD LVD,SR

PROCEDURE: MODIFIED BENTALLS PROCEDURE

(AVR 27#CHVP+28 #ALBOGRAFT)

HISTORY:34 year old male Taxi driver from Coimbatore presented with recent onset DOE FC II. H/o palpitations present. No h/o PND, presyncope, syncope, TIA. Known case of Marfan syndrome. No h/o hypertension, diabetes, dyslipidaemia. No vision complaints No h/o CVA/TIA /seizures. No other medical / surgical illness.

PHYSICAL EXAMINATION:

Thin built. Arm span > Height. Thumb sign absent. Palate high arched.

No pallor/icterus/cyanosis/clubbing /pedal oedema/ raised JVP.

Pulse- 70/min regular, regular, all peripheral pulses palpable.No radio femoral delay.

Bp-130/44 mmHg right arm supine position, High volume collapsing, prominent carotid pulsations. Pistol shot murmur present.

Cardiovascular system: Inspection: Precordium Normal

Palpation: AI: 6th ICS @ 3 cm lateral to MCL. Diffuse apex

Auscultation: S1,S2 +, ESM 2/6 at apex.

Respiratory system: B/L air entry equal,no added sounds

Abdomen: Soft, no organomegaly CNS: No focal neurological deficits.

INVESTIGATIONS:

BLOOD INVESTIGATIONS: Normal

ECG : SR.HR 70/min. QRS Axis +45deg. V1 R/S: 3/9, V6 R/S 21/3

ECHO : LV 80/64, LA 36mm, AO 78mm, EF 40% Mod LVD, MR 2+, AR 4+,

Aortic Annulus 39mm, PAH: 26+ RAP.

SURGICAL FINDINGS

Cardiomegaly present.LV Dilated and hypertrophied.

Aortic root grossly dilated approx 80 mm.Aortic annulus Dilated.

Aortic valve were tricuspid

Preop TEE-Sev AR,Dilated aortic sinus and STJ, Fair LV function,EF-38%,Dilated LV,Global LV hypokinesia

Post op TEE-No Paravalvular leak,PV gradient-9/5 mm Hg.Poor LV function,EF 30%,No RWMA,Global LV hypokinesia.

CPB DATA & MYOCARDIAL PROTECTION:

Membrane oxygenator and roller pump. Aorto atrial cannulation.

Arterial cannulae - 24 Fr

Venous cannula : Two stage cavoatrial cannula 34/46 RMI.

CPB time: 123 mins. ACC time : 94 mins.

Tepid blood direct ostial cardioplegia

Topical cooling with ice slush, core cooling to 29 degrees, RSPV vent.

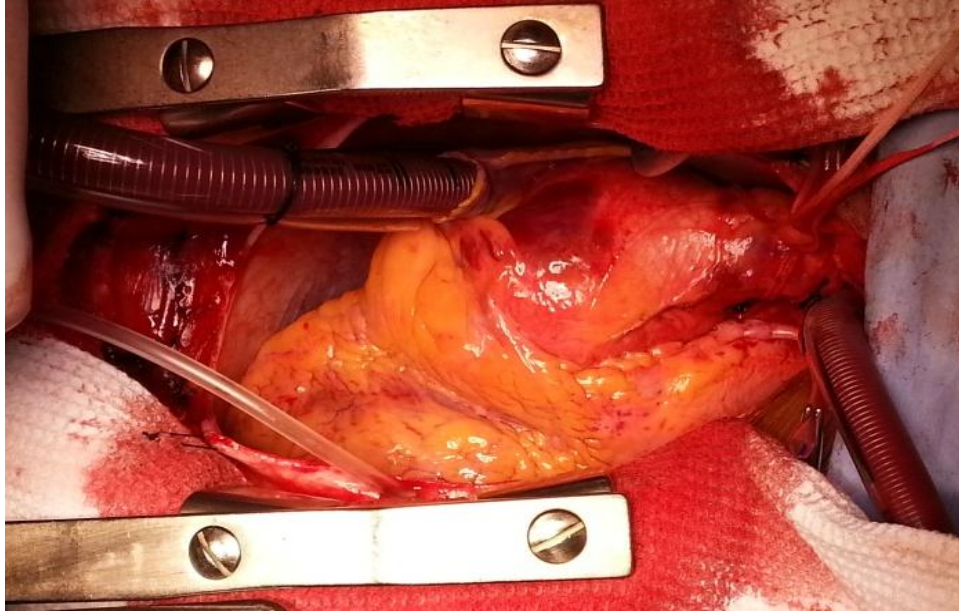
Urine Output on pump- 2300ml.Total fluid loss-800 ml

PROCEDURE: Standard midline sternotomy. Pericardium incised and opened in inverse T shaped incision. Pericardial well created. Aortic and RA cannulated and went on CPB. RSPV vent inserted. Cooled to 29 degrees. Aorta cross clamped and opened. Complete diastolic arrest of the heart attained with tepid blood cardioplegia given through the coronary ostia.

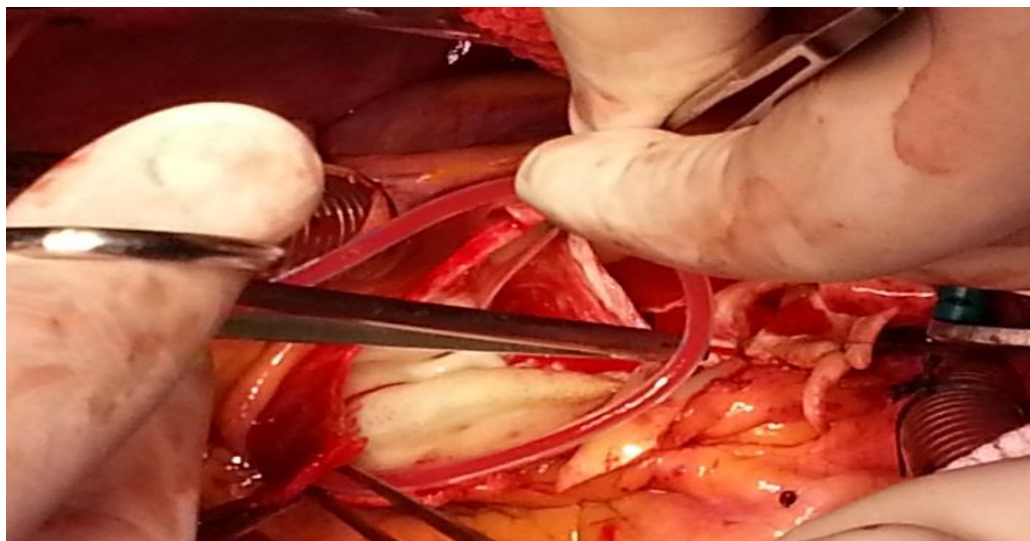
Ascending aorta transected beyond the dilated part. Aortic valve excised. Both Coronary buttons harvested and stay sutures taken. Aortic valve sized. 2-0 Ethibond sutures placed, Composite valve graft conduit created with 27#CHVP and 28# Albograft was prepared. Composite Valve - graft conduit seated and tied with 20 plagettedTicronsutures. Valve movements checked. Left and Right coronary buttons anastomosed to the graft conduit using 5-0 Prolene continuous sutures. Distal anastomosis of the composite graft to the Aorta performed with 3-0 prolene sutures.

Aorta de-aired through the graft and Aortic cross clamp released. RV and skin pacing wire taken and paced at 80 per min. Heart picked up in SR and Came off bypass on pacing with Adrenaline support at 0.05 mics/kg/min. Hemostasis achieved. Pericardial drains placed. Wound closed in layers.

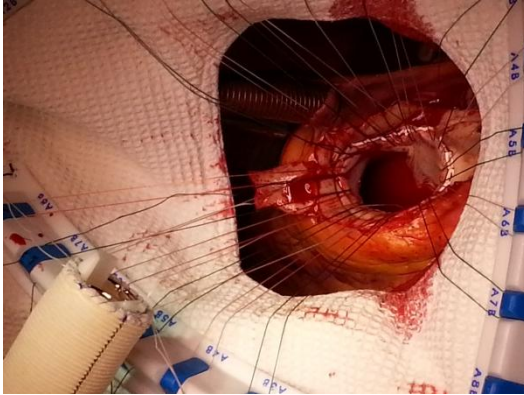
MODIFIED BENTALLS PROCEDURE



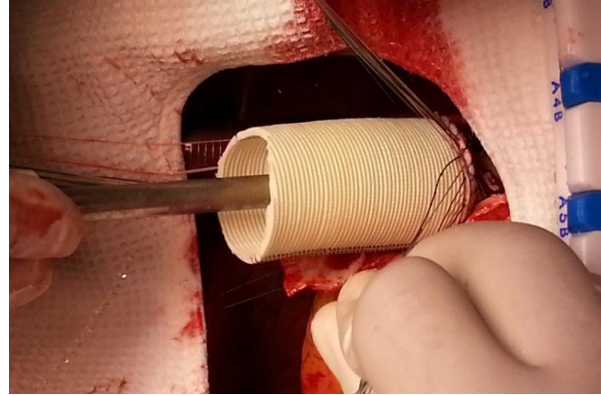DIALATED AORTIC ROOT



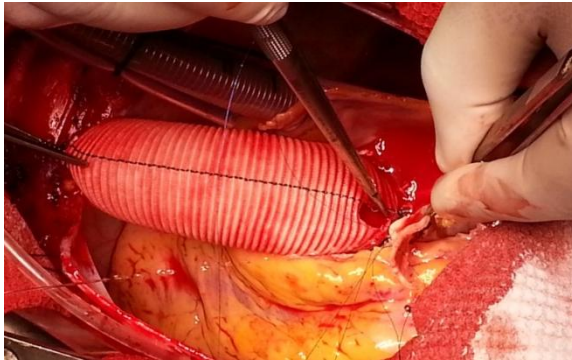
AORTIC VALVE EXCISED



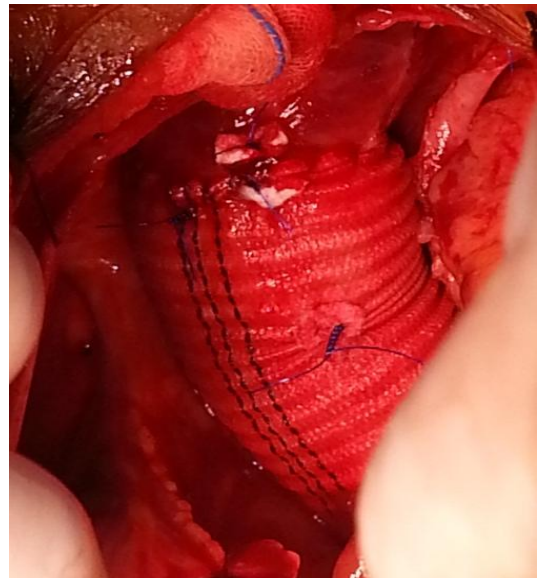
AORTIC VALVE STITCHES



VALVED CONDUIT



CORONARY BUTTON ANASTOMOSIS



COMPLETED PROCEDURE

LCA TRANSLOCATION

DIAGNOSIS:ALCAPA

PROCEDURE: LCA TRANSLOCATION

HISTORY: 5 month old male child first in order born to a NCM parents was delivered at term by FTND with a birth weight of 3.6kg. Child Cried immediately after birth. No h/o cyanosis/ spells/ LOC /seizures. Mother noticed difficulty in breathing at 5month of life was evaluated and found to have CHD. Growth and development was normal. Immunised for age.

PHYSICAL EXAMINATION:Active, . No pallor,icterus,pedaledema ,cyanosis or clubbing.

Pulse-126/min, Regular, all peripheral pulses palpableSpO2-98%. CVS: Precodiumnormal , S1 S2 +, no murmur, Apex at 4th ICS in left MCL. RS: AEBE, NVBS. P/A: Soft, no organomegaly, ascites CNS: No FND

INVESTIGATIONS:

Blood Investigations: Normal

CXR: CTR 0.68, prominent BVM, no effusion.

ECG: SR. 130/min, T inversion in AVL, V5 V6.

ECHO: Septum 9/5. PW s/d- 6/6 LA/AO - 24/14. LVEDV-41, LVSV-27,

EF -34%, SS, LC. LCA from left sinus of PA. 8mm away from LCC. RPA, LPA normal.left arch. No CoA, MR 2-3+, TR -1-2+, RVSP- 20+RA. LV dp/dt - 500mmHg

SURGICAL FINDINGS:

SS, LC. Atrioventricular concordance, Ventriculoarterial concordance, NREGA, Aorta of adequate size. LMCA arising from left facing (posterior) sinus of MPA. RCA arising from Right coronary sinus of Aorta. Abundant collaterals present. RPA and LPA of adequate size. Normal pulmonary venous drainage. Small PDA. Left arch. No COA. Severe LV dysfunction

CPB DATA & MYOCARDIAL PROTECTION:

Roller pump, membrane oxygenator, blood prime. Heparin-Protamine chemistry.

Aortic cannula - 10 Fr Biomedicus, Venous SVC: 22 BARD IVC-14 Fr DLP

Cold antegrade blood cardioplegia initially root and subsequently ostial. Core cooling to 27 degrees.

CPB - 142 mts, ACC - 73 mts.

Vent: LA vent through RSPV & Aortic root vent.

Urine : 20ml, Cuff+Muff : 400ml

PROCEDURE: Primary median sternotomy. Total thymectomy. Pericardial patch harvested & Pericardial well created. Marking stitch over Aorta taken at planned site of LCA translocation. Aorta-PA groove created. MPA & branches dissected (upto hilum) and branch PAs looped. Aorta and RA cannulated and went on bypass. RPA and LPA snugged. PDA transfixed at both ends with 6-0 prolene and divided; followed by clip application at distal end. RSPV vent inserted and cooling started. Aorta and PA separated to root as far as possible. Converted to Aortobicaval bypass. Once temperature reached 27 degrees, Aorta clamped and

cardioplegia given into the root of PA and Aorta. Heart arrested promptly in diastole. Went on total bypass. Tropical cold saline and SVC and IVC snugged. PA opened transversely 1 cm above level of pulmonary annulus. LMCA ostium seen in PA and MPA divided completely. Ostial button with LMCA mobilization done. Controlling & dividing all neighbouring collaterals carefully, Defect in MPA reconstructed with tanned pericardial patch. Plegia given via Aortic root and LMCA ostium. Aorta opened 1 cm above level of LCC and ostial Button sutured to Aorta with 8/0 prolene. Rewarming started. Caval snugger removed. Deairing done and cross clamp released. Heart slowly picked up in sinus rhythm. Two atrial and two ventricular wires placed. Came off with adequate filling pressures Hemostasis achieved. 1 Mediastinal & 1 right mediastinopleural drains placed. Sternum closed with 6 x No 6 S.S wire. Subcutaneous closed with 3-0 Vicryl continuous sutures and skin with 3-0 Monocryl- subcuticular. Shifted to ICU for monitoring and elective ventilation on supports of Milrinone 5 mcg/kg/min.

COURSE IN HOSPITAL: Uneventful

INVESTIGATIONS PRIOR TO DISCHARGE:

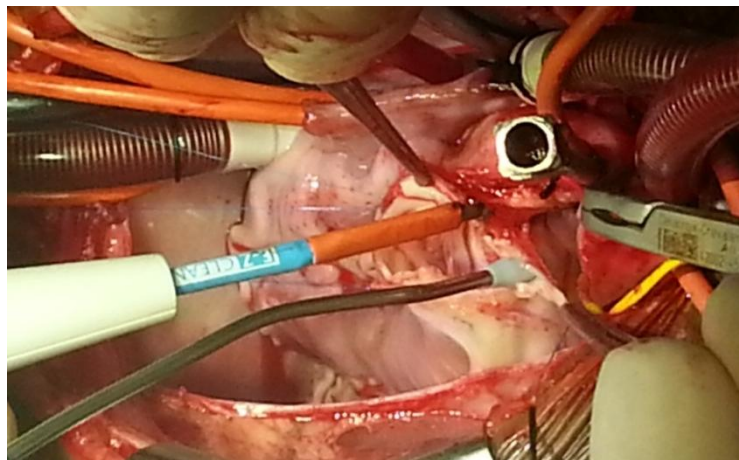
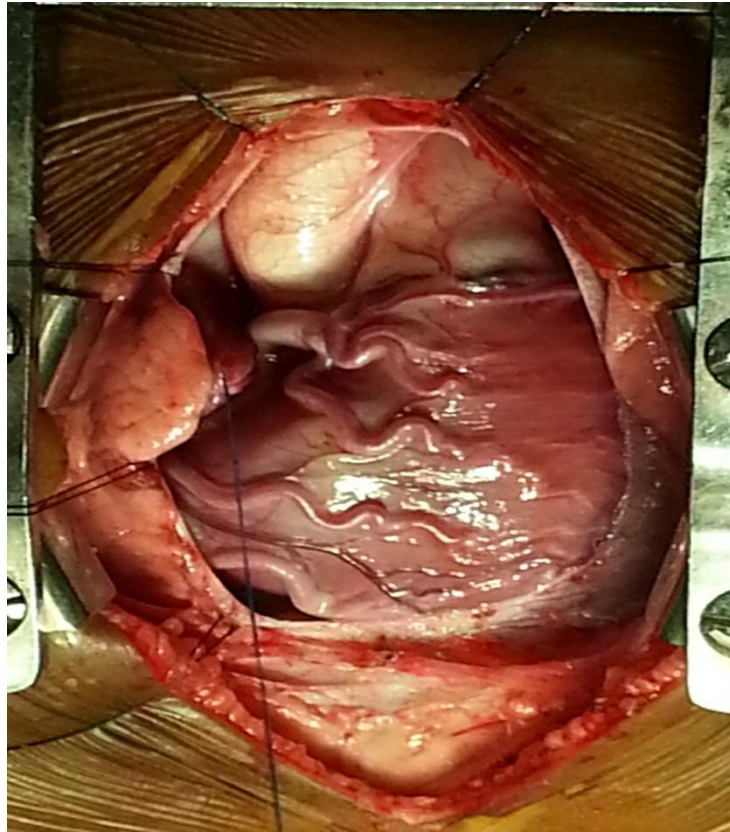
ECG: SR, no fresh changes.

CXR: B/L lung fields clear, no pneumothorax, no effusion.

ECHO: LV: 30/26, EF-30%, LA/Ao-16/11, Laminar flow in LCA, severe LVD,

Ao Vel-0.8ms, MR 1+, TR 1+, good LV/RV function, Trivial PE

LCA TRANSLOCATION



LCA HARVEST

COA REPAIR

DIAGNOSIS: Double barrel aorta with COA

PROCEDURE: COA REPAIR

HISTORY: 1 year old female child born of a NCM by LSCS at full term with birth weight of 2.5kg was diagnosed to have CHD at 4 1/2 month of age when evaluated for recurrent RTI. H/o respiratory difficulty present. No h/o cyanotic spells/ seizures / TIA. Developmental history normal, Immunised to age.

PHYSICAL EXAMINATION:

No pallor/icterus/ cyanosis

HR-120/min ,regular, radiofemoral delay present

BP(R) UL-117/48 mm of Hg (R) LL- 72/44 mm of Hg

CVS: S1S2+, apex at 5th ICS (L) in MCL, 2/6 ESM at LVSB.

Chest-Clear P/A -Soft, no organomegaly CNS- No FND.

INVESTIGATIONS:

Blood Investigation: Normal

CXR: CTR 0.52, normal PBF

ECG: SR, 120/m QRS axis 90

ECHO: SS,LC, Normal venous drainage, AV-VA concordance, CoA gradient

80/30, Double barrel aorta sev CoA narrowest 2.2mm, conc LVH

CT Cardiac: Persistent 5th aortic arches the common trunk giving rise to native vessels. Sev CoA of proximal DTA.

SURGICAL FINDINGS:

SS, LC, Double barrel aorta

Both Left sided Aortic Arch, all 4 vessels arising from upper arch and pre subclavian COA from lower arch.

Thin strand of fibrous cord connecting upper and lower arch.

NO encircling of Trachea or oesophagus present

Chord like PDA. 2 large collaterals from 3-4 ICS,

Post Repair Upper Limb Pressures- 138/92(113) mm Hg. Lower Limb Pressures- 133/87(109) mm Hg

PROCEDURE:- Left Posterolateral thoracotomy incision. Pleural space entered through 3th LICS. Lt Lung retracted. Posterior pleura incised along the line of Descending Thoracic Aorta, posterior to the Lt Vagus Nerve. Proximal DTA, both Arch, PDA, Innominate .A, Left Subclavian Artery, vertebral .A and Left Common Carotid Artery dissected.

Left Recurrent Laryngeal Nerves identified and safeguarded.

PDA, LSCA, Lt. carotid Artery, SCA looped.

3rd and 4th Intercostal arteries and other smaller collaterals ligated and divided at their origin from DTA . Aortic arch clamped base of left carotid artery.

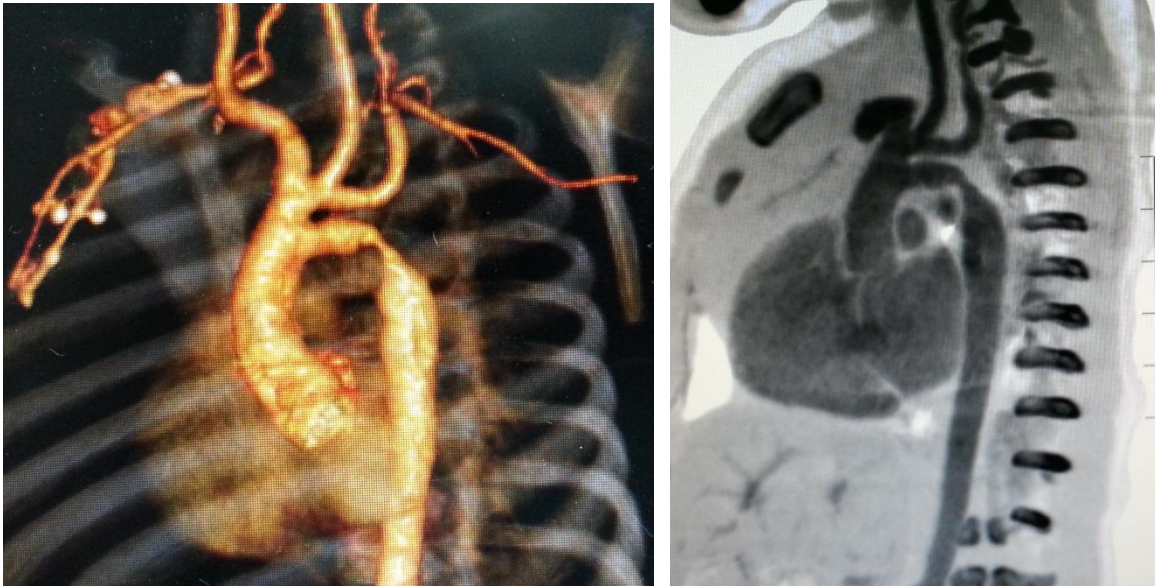
PDA ligated and clipped. Distal Clamp applied in the DTA above the origin of 5th Intercostal Artery.

PDA divided. Coarct segment resected. End to End anastomosis done using 8 - 0 Prolene , continuous sutures in single layer with the lower arch. Distal clamp removed before tightening the sutures. Deaired and tightened the suture. Proximal clamp removed. Haemostasis achieved. Pleura over DTA closed with 6 - 0 Prolene. Left Pleural drain kept. Thoracotomy incision closed in layers. Rib sutures with 2 - 0 Vicryl, Muscle in 2 layers with 3 - 0 Monocryl. S/C tissue with 3 - 0 Monocryl,

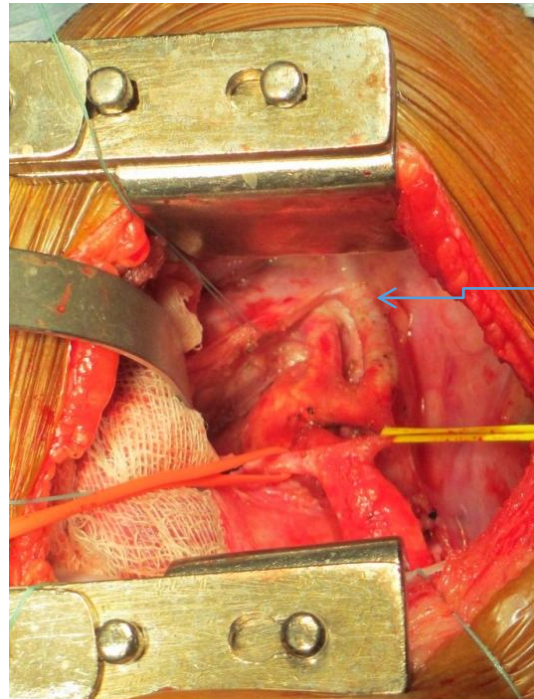
Skin- S/C tissue with 3 - 0 Monocryl .Patient shifted to CHICU for elective ventilation and monitoring

COURSE IN HOSPITAL: Uneventful

Double barrel aorta with COA



Double barrel aorta with COA reconstruction image



ARCH VESSELS

FONTAN SURGERY

DIAGNOSIS: CCHD,DILV, HYPOPLASTIC RV, S/P BDG, GD LV, SR

PROCEDURE: COMPLETION FONTAN WITH 5MM FENESTRATION

HISTORY: This 14 year 2 month old male child born of a NCM by NVD at full term, no significant antenatal history was diagnosed to have CHD routine antenatal screening. Patient had cyanosis since birth.He underwent BDG in 2002 following which cyanosis was reduced. Following 3 years after BDG, patient started having DOE FC II. No h/o cyanotic spells/TIA/seizures. Developmental milestones normal. Immunised to age.

PHYSICAL EXAMINATION:

HR- 82/min SPO2-78% Cyanosis +, clubbing +. No pallor/icterus/edema

CVS: S1S2+, apex at 5th ICS [L] MCL, 2/6 ESM at LUSB.

Chest: clear P/A - Soft, no organomagaly. CNS: Normal

INVESTIGATIONS:

Blood Investigations: Normal

CXR: CTR 0.48, Lung fields clear. ECG: SR@ 72 /min

ECHO: SS,LV IVC-RA, DILV, L-posted Aorta, confluent PA, functionary BDG, (L) arch, good SV , trivial (R) AVVR.

Cardiac CT: SS,LC, DILV hypo plastic (R) ventricle, Aorta arising from (R) ventricle of MPA from (L) ventricle. Aorta (L) and anterior to MPA. Functioning BDG. No MAPCA.

SURGICAL FINDINGS:

SS,LC,NRGA, well functioning BDG, dense adhesions present, fair sized MPA and PA's, No antegrade flow in MPA.

Pre procedure Glenn pressures: 8 mmHg

Post procedure Fontan pressures 15 mmHg

CPB DATA & MYOCARDIAL PROTECTION:

Roller pump, membrane oxygenator, blood prime.

Heparin-Protamine chemistry.

Cannulae: Ao: 21 Fr Edward, SVC: 18 Fr DLP, IVC: 20 DLP

Cooled to 32 deg. Myocardium protected with cold saline.

CPB time: 125 min.

PROCEDURE: Redo sternotomy done with oscillating saw. Adhesions between the heart and the sternum released. RA injured while dissection, controlled with pledgeted suture. Pericardium hitched.

Aorta, SVC, PA's upto hilum, MPA, IVC dissected, looped. Patient heparinised.

Aorto-RA bypass instituted. SVC cannulated connected to circuit.

Decided to do an extracardiac fenestrated Fontan procedure. MPA and branch PA's snugged, MPA transected superior to pulm valve, and closed proximally with

4-0 Prolene. At the confluence of PA's the defect of MPA extended towards the right for anastomosing with the graft.

20 mm PTFE graft prepared and superior end bevelled to conform to RPA anastomotic site. Total length approx 10 cm. Graft sutured proximally to the RPA and MPA opening with 6-0 PTFE sutures.

IVC cannulated distally and snugged, connected to circuit, RAA canula removed. Cardioplegia purse-strings taken, aorta cross clamped and cardioplegia given. The heart arrested promptly in diastole, IVC-RA junction transected, Atrioseptectomy done and coronary sinus unroofed, RA defect closed in two layers. Thereafter the PTFE graft anastomosed to the IVC, end to end using 5-0 PTFE sutures. Heart de-aired via the aortic root.

The tube graft fenestrated with 5 mm punch and anastomosed side to side with the RA, a little away from the fenestration.

Aortic cross clamp released. Heart picked up in sinus rhythm. Came off bypass in stages with good filling pressures on Dobutamine of 5 mic/kg/min. Heparin reversed. Decannulated in stages. Haemostasis secured. LA line introduced.

Two atrial and 2 ventricular wires taken. 2x Mediastinal, 1x Rt and 1x Left pleural drains placed.

Sternum closed with 6 SS No 4 wires. Subcutaneous tissue closed with continuous 2-0 vicryl. Skin closure with interrupted horizontal mattress. Previous scar excised.

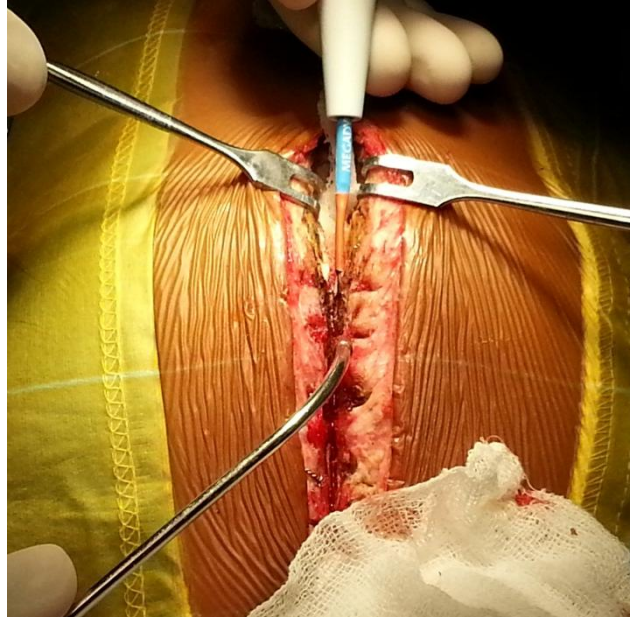
Patient shifted to ICU with stable hemodynamics with dobutamine 5 mic/kg/min.

COURSE IN HOSPITAL: Uneventful Recovery

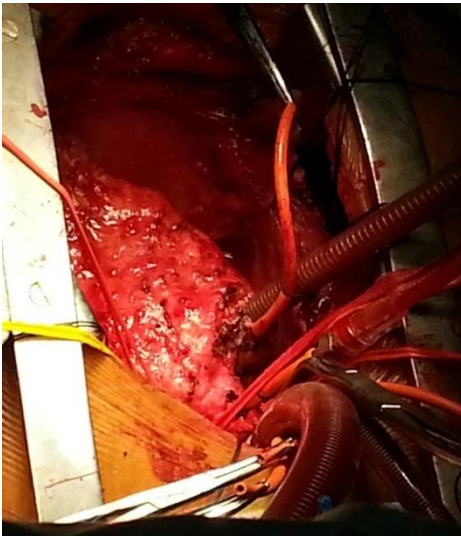
ECHO: Good ventricular function. No PE/Clot, Functioning Fontan

CXR: No pleural effusion.

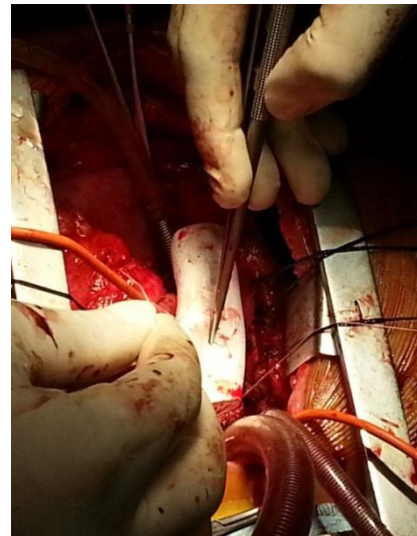
ECG: No fresh changes INR in Range



REDOSTERNOTOMY



**PERICARDIAL ADHESION
RELEASED**



CONDUIT ANASTOMOSIS

CABG FOR CAD WITH FAMILIAL

HYPERCHOLESTEROLEMIA

DIAGNOSIS: CAD/LMCA/TVD/GDLV /SR/HYPOTHYROID,FAMILIAL
HYPERCHOLESTEROLEMIA

PROCEDURE: CABG X 3 GRAFT(LIMA-LAD, RSVG- MAJ OM, DISTAL
RCA)

HISTORY: This 23year old female came with c/o DOE since 9 months. H/o DOE started as FC-II now in FC- III. H/o AOE FC- II.Noh/o PND /orthopnea. No h/o syncope on exertion/ ACS. Past history- No h/o similar complaints in the past. Risk factors DM(-)/ DLP (-)/ HTN (-). No h/o CVA/TIA/Loc/seizures. Other medical / surgical illness - Nil.Family history - Strong family history of CAD.Familial hyper cholesterolemia present.

PHYSICAL EXAMINATION: conscious, oriented, comfortable at rest,
pallor(-)/icterus(-)/cyanosis(-)/clubbing(-)/pedal edema(-).JVP: Not raised.

Multiple subcutaneous xanthomasb/l forearm, tuberous xanthomas over both elbows, nape of neck, achilles tendon Xanthoma present.

HR:80 /min. RR: 18/min. BP:120/56 mmHg.

CVS - precordium (N). Apex in (L) 5th ICS 1cm med to MCL.

S1 S2 (+). No murmur. RS - NAD. P/A - NAD. CNS - NAD.

Allen's test (-).Carotid bruit (-).PVD (-).Varicose vein (-).

INVESTIGATIONS:

Blood Investigations : Normal

S. cholesterol 470 mg/dl, HDL cholesterol 32 mg/dl, TG 44 mg/dl

CXR: CTR: 0.58, prominent BVM, no effusion

ECG: SR@ 68/min, ST Depression in AVF, V4-V6.

CAG: LMCA: ostial 90%

LAD: mid LAD 60%, Distal LAD:40% after bifurcation

LCx- OM60-70%

RCA: Ostial 80%, dominant

SURGICAL FINDINGS:

Sternum normal, Mediastinum Normal, No cardiomegaly, aorta Normal, PA soft, Good LV contractility, No Scars. LIMA of normal calibre and good flows. SVG good caliber, harvested from left leg. LAD: 1.5 mm, plaquey vessel, , arteriotomy site was healthy, post grafting distal run-off good. Major OM: 1.25 mm, plaquey vessel, arteriotomy site was healthy, post grafting distal run-off good. Distal RCA : 1.5 mm vessel, plaquey arteriotomy site was healthy, post grafting distal run-off good. Pre op TEE-GD LV/RV function, Mild MR/AR, No RWMA

Post op TEE.GD LV/RV function, Mild MR/AR. No New RWMA present, MR1+, AR1+

Sternum normal, Mediastinum Normal,

No cardiomegaly, aorta Normal, PA soft, Good LV contractility, No Scars

LIMA of normal calibre and good flows.

SVG good caliber, harvested from left leg

LAD: 1.5 mm, plaquey vessel, arteriotomy site was healthy, post grafting distal run-off good.

Major OM: 1.25 mm, plaquey vessel, arteriotomy site was healthy, post grafting distal run-off good.

Distal RCA : 1.5 mm vessel, plaquey arteriotomy site was healthy, post grafting distal run-off good.

Pre op TEE-

GD LV/RV function, Mild MR/AR, No RWMA

Post op TEE

GD LV/RV function, Mild MR/AR

No New RWMA present, MR1+, AR1+

CPB DATA & MYOCARDIAL PROTECTION:

Roller pump, membrane oxygenator, crystalloid prime. Heparin -Protamine Protocol

Ao cannula: 24 Fr Edwards, Venous cannula: 34/46 Fr RMI two stage cavo atrial cannula.

CPB time: 74mins, ACC time: 35mins.

Tepid blood antegrade aortic root cardioplegia, topical cooling with ice slush, core cooling to 30 degrees, aortic root vent.

Post procedure fluid: Gain 275 ml, Urine on pump: 525 ml.

PROCEDURE: Standard midline sternotomy. Pericardium incised and opened in inverse T shape and hitched.

LIMA harvested. Saphenous vein harvested.

Heparinised. Aorto-RA bypass instituted. Cooled. Cardioplegia cannula inserted.

Aorta cross clamped.

diastolic arrest of the heart attained with tepid antegrade blood cardioplegia given through the aortic root. Tropical cooling with cold saline.

The distal anastomoses of RSVG to MAJ OM, DISTAL RCA with 7/0 prolene and LIMA anastomosed to LAD using 7-0 prolene. Rewarming started. Aortic cross clamp released, heart picked up in SR. Proximal anastomosis of the RSVG's done to the aorta using 6-0 prolene, with side biting clamp on aorta.

Side clamp released, grafts deaired. Hemostasis achieved.

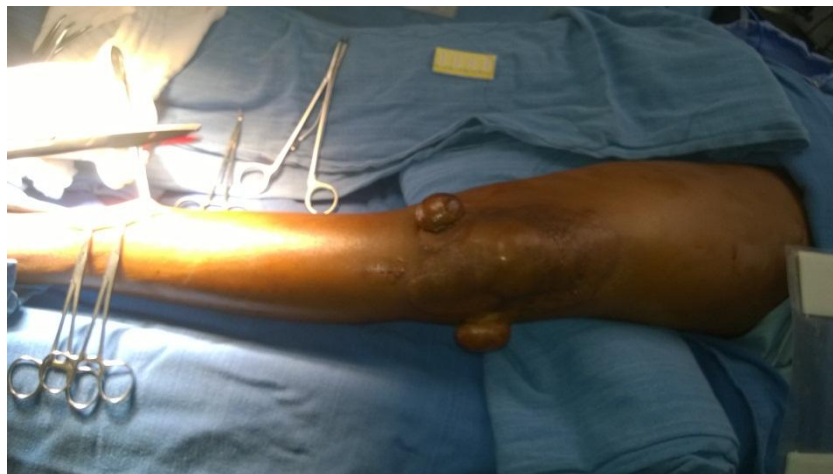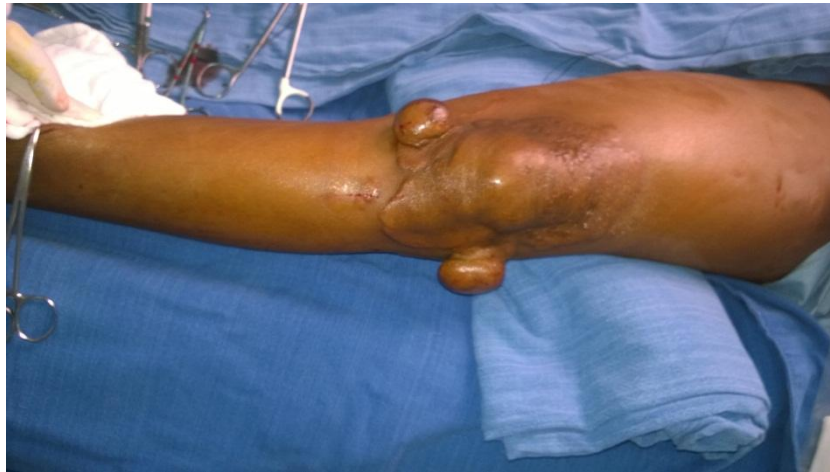INVESTIGATIONS PRIOR TO DISCHARGE

CXR: Normal

ECG: No fresh changes

CAD/LMCA/TVD/GDLV /SR/HYPOTHYROID,

FAMILIAL HYPERCHOLESTEROLEMIA



TRUNCUS ARTERIOSUS REPAIR

DIAGNOSIS: TYPE II TRUNCUS ARTERIOSUS, VSD, SEV PAH, LT ARCH,SR

PROCEDURE: TRUNCUS ARTERIOSUS REPAIR

HISTORY:The second born female child of NCM, by FTND diagnosed to have multiple anomalies at birth. Complete cleft lip + cleft palate +. H/o feeding difficulty +. No h/o breathing difficulty/ cyanosis/ spells. No significant antenatal history or family history .Immunised to age.

PHYSICAL EXAMINATION:

Active, alert, complete cleft palate present.

No pallor, icterus, cyanosis, clubbing

HR-140/min SPO2-97%

CVS: S1S2+, single S2,Precordium normal ,Apex at left 5th ICS in MCL.

PSM@ LLSB +.

Respiratory system Chest clear : P/A Soft, no organomegaly CNS: No FND.

INVESTIGATIONS:

Blood Investigations: Normal

CXR: CTR 0.63, Lung fields congested.

ECG: SR@ 140/min,

ECHO: SS,LC, 3mm OS ASD L-R Turbulence in Right lower PV,

8mm tricuspid Truncal valve, no regurgitation .Both AV valve normal, large subtruncal VSD, left arch, No CoA .Type 2 Truncus.

SURGICAL FINDINGS:

SS, LC, Type II Truncusarteriosus, Tricuspid truncal valve, RA/ RV Normal

PA's of adequate size, 1.5x1.0 cm subtruncal VSD,

27 size pulmonary homograft sized for patient by bicuspidization

CPB DATA & MYOCARDIAL PROTECTION:

Heparin-protamine chemistry.

Roller pump.Antegrade del- Nidocardioplegia to aortic root, topical cooling with cold saline.

Core cooling to 24 deg.

Aortobicavalcannulation.

Aorta: Fr 8 Bio med, SVC:12Fr DLP, IVC:14 Fr DLP

CPB time:227 min. ACC time:170 min.

Vent: LA(RSPV) and aortic root vent.

Urine on pump 25ml, CUF 850 ml MUF 150 ml Total fluid loss 157 ml.

PROCEDURE: Standard midline sternotomy. Patch harvested.

Thymectomydone.Pericardium hitched. Branch PA dissected till hilum

.Heparinised.RPA snugged to minimise coronary steal causing ST segment depression changes, Aorto-RA bypass instituted. (Aortic purse string taken almost at Innominate) converted to bicaval cannulation.LA vent put through RUPV.

Cooled.Aorta cross clamped .Cardioplegia cannula inserted, diastolic arrest of the

heart achieved. Branch PA cuff harvested from Aorta and defect created closed with bovine pericardium patch with 8/0 prolene Branch PA in superior and inferior in orientation created to prevent kinking of LPA. LPA/RPA Augmented with BPP to creat a cuff of tissue to anastomosis with Homograft. SVC and IVC snugged and went on total bypass. RA opened parallel to AV groove and and VSD assessed through TV. PM VSD, closed with gortex patch with continous and interrupted technique sutures with 6/0 prolene.. After taking Stay suture Incision given over RVOT. Homograft placed and proximal end suturing done with 6/0 prolene to LPA and RPA cuff and then distal end of homograft anastomosed with RVOT with 6/0 prolene. RA closed in single layer with 6/0 prolene.Rewarming started.

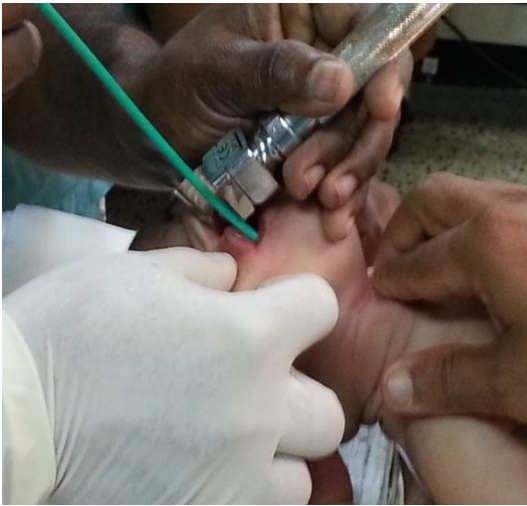2 RA and 2 RV pacing wire taken.PA line placed. Heparin reversed. Decannulated in stages. Heart picked up in SR on Milrinone 0.5 microgm/kg/min and Nor Adr 0.04 mic/kg/min Rt pleural mediastinal and one mediastinal drains inserted. Hemostasis achieved. Coseal Sprayed over heart to minimise adhesions in view of future redo surgery. Chest closed in layers, sternum with 4 No 1 SS wires sternum, 3-0 monocryl for subcutaneous tissue and 4-0 monocryl sutures for skin. Shifted to ICU with stable hemodynamic for elective ventilation with supports of Milrinone 0.5 microgm/kg/min and Nor Adr 0.04 mic/kg/min

INVESTIGATIONS PRIOR TO DISCHARGE

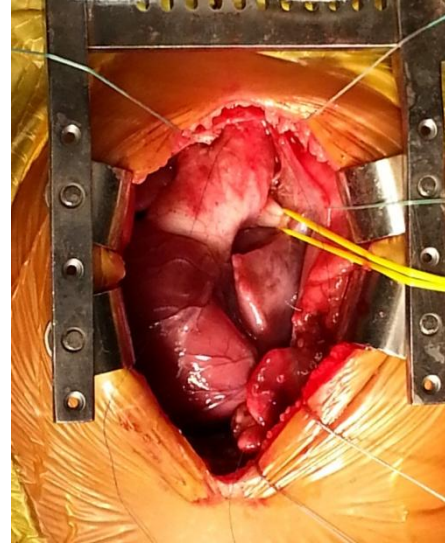
ECG: SR, no fresh changes.

CXR: CTR 49 %, B/L lung fields clear, no pneumotharax, no effusion.

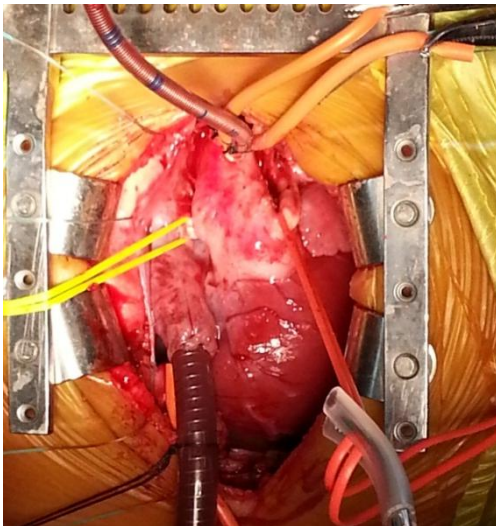
ECHO: No PE, good LV/RV function, no residual ASD/VSD .



CLEFT PALATE INTUBATION

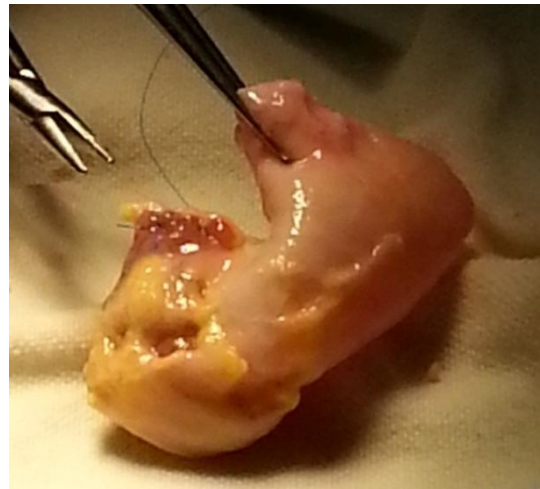

TRUNCUS ARTERIOSUS

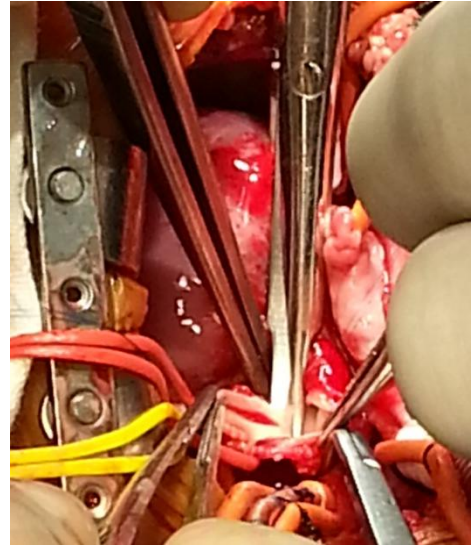
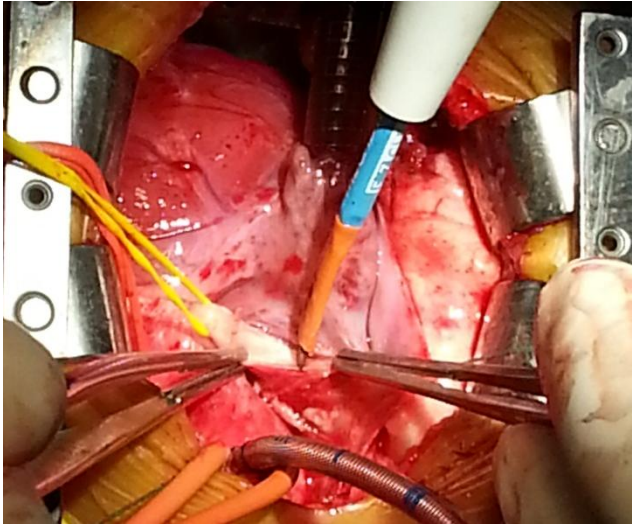


TRUNCUS ARTERIOSUS

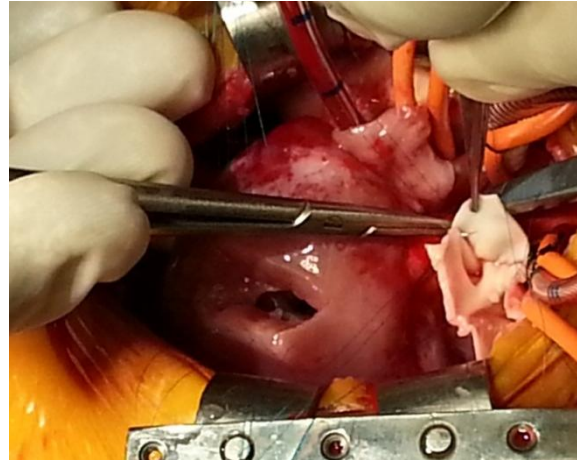
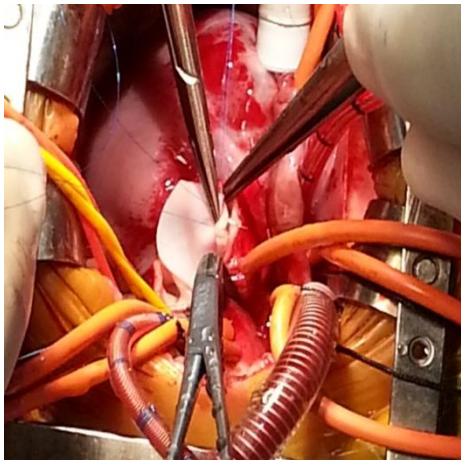
PA LOOPED



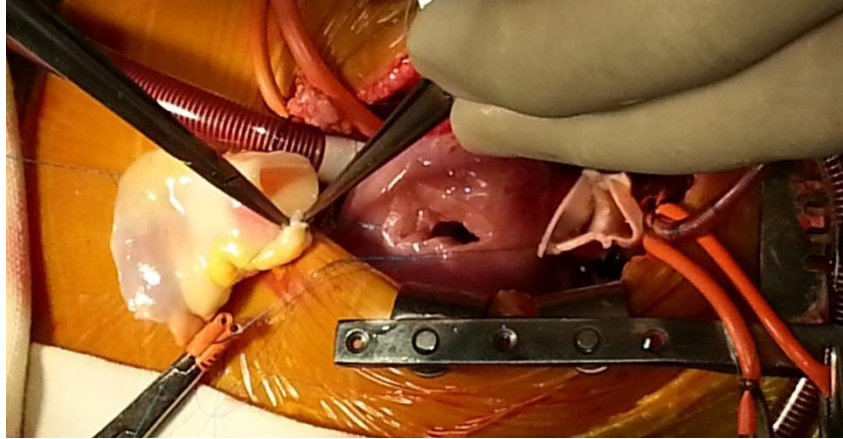
HOMOGRAFT



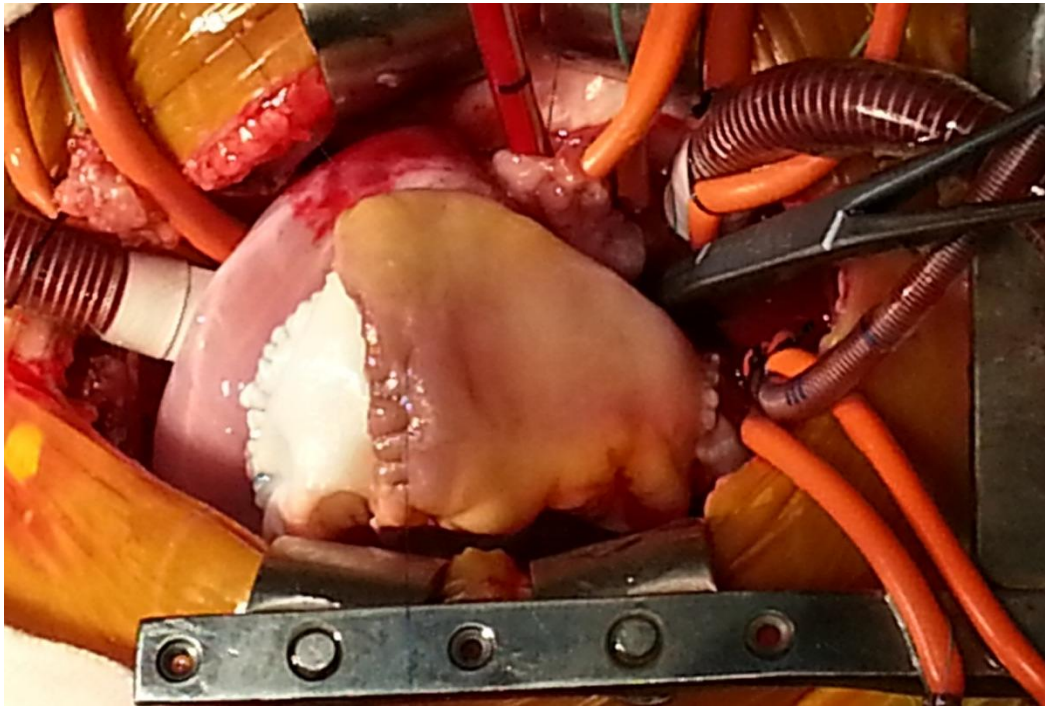
PA HARVEST



PA REANASTOMOSIS



HOMOGRAFT ANASTOMOSIS TO PA AND RV



TRUNCUS REPAIR COMPLETED