

SREE CHITRA TIRUNAL INSTITUTE FOR MEDICAL SCIENCES AND TECHNOLOGY

Thiruvananthapuram – 695011, India



WORK RECORD

Name : Dr.SUJITH D.S

Course : MCh

Discipline : CARDIO VASCULAR AND THORACIC SURGERY

Year of Study : Jan 2013 – Dec 2015

CERTIFICATE

I hereby certify that I have performed / assisted all the procedures listed in the work record.

Place:

Signature:

Date:

Name : Dr.SUJITH D.S.

Forwarded: The above candidate has satisfactorily carried out the minimum required procedures.

Seal

Prof. Jayakumar K,
Head of the Department,
Department of CVTS,
SCTIMST,
Thiruvananthapuram.

PROCEDURES PERFORMED

PROCEDURE	NUMBER OF CASES
OS ASD CLOSURE	3
SINUS VENOSUS ASD CLOSURE + PAPVC REROUTING	2
VSD CLOSURE	1

PROCEDURES ASSISTED

ADULT CARDIAC SURGERY

PROCEDURE	NUMBER OF CASES
CABG/ OPCAB	191
MVR	27
AVR	28
DVR	16
MV REPAIR	4
BENTALL PROCEDURE/ SUPRACORONARY ASCENDING AORTA REPLACEMENT	9
AVR + CABG	16
MVR + CABG	1
ASD CLOSURE + CABG	1
AVR + AORTOPLASTY + CABG	1
REDO MVR	3

REDO AVR	2
MVR + TVA	4
AORTIC ROOT ENLARGEMENT + AVR	2
OMV + TVA	1
MVR + ASD CLOSURE	1
MV REPAIR + ASD CLOSURE	3
VSR REPAIR + CABG	2
SEPTAL MYECTOMY FOR HOCM	3

**PROCEDURES ASSISTED
CONGENITAL HEART SURGERY**

PROCEDURE	NUMBER OF CASES
OSTIUM SECUNDUM ASD CLOSURE	18
SINUS VENOSUS ASD CLOSURE + PAPVC REROUTING	10
VSD CLOSURE	18
ICR for TOF	27
TAPVC REPAIR	6
BDG	16
ASO	5
TCPC	2
COARCTATION/ INTERRUPTED AORTIC ARCH REPAIR	4
MODIFIED BT SHUNT	8
C-AVCD REPAIR	1
P- AVCD REPAIR/TRANSITIONAL	2
PA BAND	3
TAUSSIG BING(ASO+ARCH REPAIR)	3
TOPSY TURVY HEART WITH AP WINDOW	1
PDA INTERRUPTION	2
VSD CLOSURE + AORTIC VALVE REPAIR	2
WARDEN PROCEDURE	2

RASTELLI PROCEDURE	2
RV TO PA HOMOGRAFT CONDUIT REPAIR	4
TRUNCUS ARTERIOSUS REPAIR	1
ASO + VSD CLOSURE	2
INTRACARDIAC TUNNEL REPAIR FOR DORV	3
REDOSTERNOTOMY + ASCENDING AORTIC REPLACEMENT	1
ASD CLOSURE + HAPVC REPAIR	1
TAPVC REPAIR + VSD CLOSURE	1
ARCH REPAIR + VSD CLOSURE	2
ASD CLOSURE + PULMONARY VALVOTOMY	1
SAM EXCISION + SEPTAL MYECTOMY + MVR	1
RMBTS + ATRIAL SEPTECTOMY	1

MISCELLANEOUS

PROCEDURE	NUMBER OF CASES
DELAYED STERNAL CLOSURE	10
WOUND DEBRIDEMENT + SECONDARY SUTURING	5
TRACHEOSTOMY	3
STERNAL WIRE REMOVAL	2
HOMOGRAFT HARVEST AND TRIMMING	7
PERICARDIAL EFFUSION DRAINAGE	4
AVF CREATION	1
SSG	2
LA/ PA LINE REMOVAL	8

CONFERENCES AND PRESENTATIONS

IACTSCON 2014 - The 60th Annual National Conference of the Indian Association of Cardiovascular and Thoracic Surgeons. Hyderabad Topsy-Turvy Heart: A Very Rare Case of cardiac rotation abnormality (E-poster presentation)

**PROCEDURES
PERFORMED**

S. No	H. No	NAME	AGE	SEX	DOS	DIAGNOSIS	PROCEDURE	SUPERVISED BY
1	353045	JOSHWIN J JOSE	4	M	20-08-2015	ACHD, SP-VSD, GOOD LV,SR	DIRECT CLOSURE OF SP-VSD	Dr.SABARINATH MENON
2	357483	RATHEESH	22	F	12-02-2015	ACHD, OS ASD, SR	TPP CLOSURE OF OS ASD	Dr.BINEESH
3	387012	SATHI	32	F	23-03-2015	ACHD, OS ASD, MILD PAH, SR	ASD CLOSURE(TPP)	Dr.BINEESH
4	373817	NAVAMI V.	4	F	11-08-2015	ACHD, MALALIGNED POSTERIOR ASD, GD LV SR	TPP CLOSURE OF ASD (ministernotomy)	Dr.SABARINATH MENON
5	392120	MOHAMMED SHAYAN T.	2	M	21-08-2015	ACHD, SV ASD (SVC TYPE), PAPVC OF RUPV, PFO	SV ASD CLOSURE (DOUBLE PATCH TECHNIQUE) + PFO CLOSURE	Dr.THOMAS MATHEW
6	377823	ANSHAD JEFFIN S	7 7	M	03-08-2015, 18-08-14	ACHD, SV ASD (SVC TYPE), PAPVC OF RUPV	SV ASD CLOSURE (DOUBLE PATCH TECHNIQUE) + PFO CLOSURE	Dr.SABARINATH MENON

PROCEDURES ASSISTED

S.NO	NAME	AGE	SEX	DOS	DIAGNOSIS	PROCEDURE	SURGEON
1	JOHN A.	21	M	31/Jan/2013	ACHD,SP VSD,RCC PROLAPSE,SEVERE AR,GOOD LV FN,MILD MR,NO PAH,PFO,SR	GP CLOSURE OF SP VSD+AVR #27 MHVP+PFO CLOSURE	DR. VIVEK V. PILLAI
2	INDIRA P.K.	38	F	01/Feb/2013	CH TYPE I DISSECTING AORTIC ANEURYSM, MOD AR, GD LV,SR,MARFANOID	BENTALL'S PROCEDURE 25 # CHVP+26 MM ALBOGRAFT UNDER TCA.	DR.VIVEK PILLAI
3	GOPALAKRISHNAN . C . K	63	M	05/Feb/2013	CAD,TVD,GDLV,SR,HTN	OPCABG X 2GR LIMA- LAD, RSVG - DIAG	DR. JAYAKUMAR K
4	CHATHUNNI K.C.	56	M	05/Feb/2013	CAD,LMCA,TVD,GDLV,SR,DM	CABG X 4 GRAFTS LAD MAJ D MAJ OM PDA	DR. VIVEK V. PILLAI
5	SAROJINI N	65	F	06/Feb/2013	SEV CAL AS,CAD,SVD,GDLV,SR,DM,HTN,DLP	AVR+CABGX 1 GR RSVG TO LAD	DR. VIVEK V. PILLAI
6	HUSSAIN .H	43	M	06/Feb/2013	CAD,LMCA,TVD,GDLV,SR,DM	CABG X 5LIMA-LAD, RSVG-D1,D2,MAJ OM,RPDA	DR. JAYAKUMAR K
7	PRASANNAN M D	45	M	07/Feb/2013	CAD,TVD,GDLV,SR,DM,HTN, BULLOUS DISEASE OF LUNG	CABG X 4 GRAFTS , LAD, MAJOM ,MAJ DIAG,RCA	DR. JAYAKUMAR K
8	SULAIMAN V.P	55	M	11/Feb/2013	CAD, TVD, GD LV, SR, DM, HTN, DLP	CABG X 4 GR LIMA TO LAD, RSVG TO MAJ DIAG , RI BOTH BR,RPDA	DR. PRAVEEN VARMA P.K.
9	VIKRAMAN D.	50	M	12/Feb/2013	CAD,TVD,(STEMI SEP12),GD LV, SR HTN,DM	CABGX5G LIMA-,LAD ,RSVG-D1,MAJ OM,RPDA,RPLB	DR. JAYAKUMAR K
10	VIGRAHANADHAN D.	60	M	12/Feb/2013	CAD,TVD,OLD IPWMI(2005),P/PTCA,FAIR LV,SR,HTN, DLP	CABG X5G ,LIMA- LAD,RSVG- MAJ OM, MAJ DIA, RPDA 1ST, 2ND BRANCH	DR. JAYAKUMAR K
11	INDULEKHA B V	18	F	21/Feb/2013	ACHD,SVASD,MOD-SEV PAH,GD LV,SR	ASD CLOSURE WITH PAPVC REROUTING TO LA USING TPP DOUBLE PATCH TECHNIQUE	DR. VIVEK V. PILLAI
12	KURUVILA LUKOSE	68	M	21/Feb/2013	CAD,2VD,GD LV,SR,DM,HTN,DLP	CABG X4 GRAFTS ,LIMA-,LAD,RSVG-RPDA,RPLB,D1	DR. JAYAKUMAR K
13	BARBARA FEMIYAN M	57	F	22/Feb/2013	RHD,SEV MS,MOD PAH,GDLV,SR,NC ,HYPOTHYROIDISM	MVR # 27 SJM +PMLP	DR. VARGHESE T.PANICKER
14	HASHIM C	55	M	22/Feb/2013	CAD,LMCA+TVD,RECENT NSTEMI,SEV LV DYSF,SR,DM,HTN,DLP	CABG X 4G, LAD,TERM OM, MAJ OM, RPDA	DR. JAYAKUMAR K
15	SHAMSUDHEEN V.	45	M	21/Mar/2013	BAV,ANUERYSM OF SINUS OF VALSALVA ,ASC AORTIC DISSECTION ,GD LV,SR,HTN	BENTALL PROCEDURE	DR. JAYAKUMAR K
17	SAMSON P.	22	M	25/Mar/2013	ACHD, OSASD, GD LV, MILD PAH,SR	TPP CLOSURE OF ASD	DR. JAYAKUMAR K
18	MALLIKA THANKAPPAN	48	F	25/Mar/2013	CAD, TVD,OLD IWMI, DIAS DYSF, SR, DM	CABG X 3 GRAFTS LIMA-LAD,RSVG-DIAG, RPDA	DR. PRAVEEN VARMA P.K.
19	MALLIKA THANKAPPAN	48	F	25/Mar/2013	S/P CABG X 3 GRAFTS	RE- EXPLORATION	DR. PRAVEEN VARMA P.K.
20	MADHUSOODHANAN K.S.	57	M	26/Mar/2013	CAD,TVD, S/P PTCA TO PDA SR, DM,HTN DLP	CABG X5GRAFT LIMA- LAD,RSVG- D1, MAJ OM, TERM OM,RPDA	DR. VIVEK V. PILLAI
21	PRABHAKARAN NAIR.K	66	M	27/Mar/2013	CAD,LMCA DISSECTION & TVD(S/P POBA),MOD LVD,MILD MR,SR,HTN	CABG X 6 GRAFTS LIMA-LAD, RSVG-D1,D2, OM,PLB, PDA	DR. JAYAKUMAR K
22	MOHAMED MOOSA D	15	M	02/Apr/2013	BAV,ACHD,SEVERE AS,MODERATE AR,POST COA REPAIR,SR	AVR #17 SJR	DR. PRAVEEN VARMA P.K.
23	MUNYA SAMY.P	33	M	03/Apr/2013	VSD, SUB AORTIC MEMBRANE, AS, AR, PDA,ASC AORTIC ANEURYSM	BENTALL AV#29 CHVP, 30 ALBOGRAFT, VSD CLOSURE, PDA INTERRUPTION	DR. JAYAKUMAR K
24	GEORGE JOHN G	55	M	26/Apr/2013	BAV,SEV AS,MOD AR, SEV MR ,GDLV,SR,NC, DM,HTN	DVR AV #23 CHVP, MV # 29 SJM WITH PMLP	DR. PRAVEEN VARMA P.K.
25	SULAIMAN KUNJU .K	54	M	29/Apr/2013	RHD, SEV CAL MS, MILD MR, MOD PAH, GDLV, AF, NC, LA CLOT	MVR # 25 SJM +PMLP ,LA CLOT REMOVAL+LAEE	DR. VARGHESE T.PANICKER
26	JAYATHAMPI P G	70	M	29/Apr/2013	CAD,TVD, OLD IWMI, FAIR LV, HTN,DLP,SR,VV	CABG X 5GRAFTS ,LIMA -LAD,RSVG-MJ DIAG, OM1,OM3,PDA	DR. JAYAKUMAR K

27	NADESAN M	47	M	30/Apr/2013	CAD,TVD,NSTEMI,GDLV,LBBB,HTN,DM,SR,PVOD,HYPOTHYROIDISM	CABG X 5 GRAFTS LIMA -LAD,RSVG-MAJ D,RPDA,1ST ,2ND BR OF PLB	DR. JAYAKUMAR K
28	ADRIEL V OOMMEN	3	M	06/Jun/2013	CCHD, TOF, FAIR PA, NC, SR	ICR WITH TRANS ANNULAR PATCH WITH MONOCUSP RECONSTRUCTION OF RVOT	DR. SABARINATH MENON
29	MAYA .M	5	F	07/Jun/2013	CCHD,TOF , FAIR PA,NC, FREQUENT SPELLS	TRANS RA -PA ICR	DR. THOMAS MATHEW
30	SHAMSEENA S	7	F	20/Jun/2013	SA VSD, SEV INF STENOSIS,SR	ICR	DR. SABARINATH MENON
31	EBIN RAJESH .	14	M	21/Jun/2013	S/P DP SPVSD CLOSURE WITH DISCHARGING SINUS CHEST WALL	WOUND EXPLORATION AND REMOVAL OF PACING WIRES	DR. THOMAS MATHEW
32	KANNAN.B.	17	M	25/Jun/2013	DC,SI,SV,UNBALANCED AV CD, POST B/L BDG+ PA PLASTY, RPA STEN	RPA PLASTY WITH BPP+ TCPC WITH FENESTRATED #22 PTFE TUBE GRAFT	DR. BAIJU S.DHARAN
33	SANTHANA KUMAR K.	29	M	26/Jun/2013	ACHD, SA VSD, SEV INF STENOSIS, TRIVAL AR	TRANS RA PA ICR(GP CLOSURE OF VSD+INF RESECTION)+ AORTIC VALVE INSPECTION	DR. THOMAS MATHEW
34	B/O PUSHPA	0	M	08/Jul/2013	D TGA,MUSC VSD,LARGE AP WINDOW,NC,SR	ASO+AP WINDOW DIVISION	DR. BAIJU S.DHARAN
35	MUHAMMEDSIJIN P	2	M	22/Jul/2013	CCHD,TOF,GOOD PA, PDA,SR	TRANS RA-PA ICR+PULM VALVOTOMY,PA PATCH CLOSURE	DR. SABARINATH MENON
36	ASHARUDHIN M	15	M	19/Aug/2013	RHD, SEV AR, MOD MR, SEV PAH, GD LV, SR	DVR, MV# 29 CHVP+PMLP,AV #21 CHVP	DR. PRAVEEN VARMA P.K.
37	SIVASWAMY S.	57	M	19/Aug/2013	MVP, SEV MR, MILD PAH, DIL LV, GD LV, SR, NC	MVR#27 SJM +PMLP	DR. VARGHESE T.PANICKER
38	VIJAYA KUMAR.N.	51	M	20/Aug/2013	RHD, P/ AVR, SEV CAL MS, MILD MR, SEV PAH	MVR #27 SJM+PMLP	DR. PRAVEEN VARMA P.K.
39	LEELAVATHI .P	36	F	05/Sep/2013	RHD,SEV MS,SEV MR,MILD PAH, GOOD LV,AR,RHEUMAITOID ARTHRITISRHD,SEV MS,SEV MR,MILD PAH, GOOD LV,AR,RHEUMAITOID ARTHRITIS	MVR#25 SJM	DR. PRAVEEN VARMA P.K.
40	JOISE JOHN	25	M	06/Sep/2013	BAV, SEV AS, P/ COA REPAIR + PDA LIGATION, GD LV, SR	AVR #19CHVP	DR. VARGHESE T.PANICKER
41	AJESH P.K.	30	M	10/Sep/2013	RHD, SEV AR, MOD MS, DIL LV, MILD TR, MILD PAH, GDLV ? VEG	DVR, MV #25 CHVP,AV#19 CHVP	DR. VIVEK V. PILLAI
42	DARSAN .C	52	M	10/Sep/2013	SEV AS, MILD MR, GDLV, SR, NC	AVR #23 CHVP	DR. VARGHESE T.PANICKER
43	SHAHITHA P M	42	F	11/Sep/2013	RHD, SEV MR, CAL MITRAL ANNULUS, FAIR LV, AF, NC, DM, HYPOTH	MVR#25SJM	DR. VIVEK V. PILLAI
44	MUKESH M	17	M	11/Sep/2013	RHD, SEV MS, SEV MR, MOD PAH, GOOD LV, SR	MVR#25 SJM + PMLP	DR. VARGHESE T.PANICKER
45	GEORGE T	63	M	11/Oct/2013	CAD,DVD,GD LV,SR,HTN,DLP	CABGX 4 GRAFTS,LIMA-LAD,RSVG-LAT BR OF DIAG,OM1,OM2	DR. JAYAKUMAR K
46	MARIYUMMA KUNJU K	66	F	15/Oct/2013	CAD,TVD,GDLV,SR,DM,HTN, POLIO OF LT LL	CABGX 4 GRAFTS,LIMA-LAD,RSVG-D1,MAJ OM,RPDA	DR. JAYAKUMAR K
47	SUKUMARAN V.	65	M	31/Oct/2013	CALCIFIC AV, ASCENDING AORTIC ANEURYSM, SEV AR, DILATED LV, FAIR LV, SR, NC	BENTALL (AVR # 23 PM; #26MM ALBOGRAFT)	DR. JAYAKUMAR K
48	BALAMURUGAN M	19	M	04/Nov/2013	SA VSD, SEV AR(RSOV ANEURYSM) GD LV, SR	GP CLOSURE OF VSD+AVR #25 CHVP +RSOV REPAIR	DR. VARGHESE T.PANICKER
49	SOJAN CHACKO	42	M	05/Nov/2013	BAV,SEV CAL AS,MOD AR, GDLV, SR ,HTN,NC	AVR#25 CHVP	DR. PRAVEEN VARMA P.K.
50	VIJAYAN S	66	M	25/Nov/2013	CAD,TVD,GDLV,MILD MR,SR,DM,DLP	CABGX 4 GRAFT,LIMA-LAD,RSVG-RI,MAJ OM,PDA	DR. JAYAKUMAR K
51	PRAVADA C K	56	F	26/Nov/2013	CAD, TVD, GDLV, SR, HTN, DLP	CABG X 3 GRAFTS,LIMA-LAD, RSVG-MAJ OM,RPDA	DR. JAYAKUMAR K

52	SAMDEV S.P	0	M	24/Jan/2014	LARGE SA VSD,SEV PAH, SMALL SA MEMBRANE, MILD MR,GD LV FUNC., SR	GP CLOSUR OF SAVSD	DR. THOMAS MATHEW
53	ARJUN C A	0	M	29/Jan/2014	ACHD,DISCRETE POST SCA SEV COA,GD BV FUNCTION,SR	RESECTION AND END TO END ANASTAMOSIS	DR. BAIJU S.DHARAN
54	GOKUL.S.M	3	M	04/Feb/2014	SS LC OS ASD, GD LV, SR	TPP CLOSURE OF ASD	DR. SABARINATH MENON
55	FATHIMA SHAHANAS P	17	F	18/Feb/2014	CCHD, TOF, CONFL PA, NORM CORONARIES, S/P MAPCA COILING, SR	ICR+RVOTPATCH + RT SUBCLAVIAN ARTERY REPAIR	DR. BAIJU S.DHARAN
56	NIKHIL RAJ.T	6	M	03/Mar/2014	ACHD, LARGE OS ASD NO PAH, SR	TPP CLOSURE OF OS ASD	DR. THOMAS MATHEW
57	ADARSH . P	0	M	06/Mar/2014	ACHD, SP VSD, NO PAH, SR	TPP CLOSURE OF SP VSD	DR. THOMAS MATHEW
58	ANAS C P	4	M	07/Mar/2014	ACHD, MALALIGNED SA VSD, SEV PAH, MILD INF PS, MOD TR, GD LV, SR	TPP CLOSURE OF SA VSD + INFUNDIBULAR RESECTION + TV REPAIR (AS COMMISSUROPLASTY)	DR. THOMAS MATHEW
59	ANAKHA A	3	F	10/Mar/2014	ACHD,SEV VALVAR PS,GD LV,SR	ICR+TAP	DR. SABARINATH MENON
60	RAMAN T	64	M	12/Mar/2014	CAD,DVD,RECENT ACS,MILD LVD,SR,DM,DLP,REFORMED SMOKER	CABGX3 GRAFTS,LIMA-LAD,RSVG-DIAG,DISTAL RCA	DR. PRAVEEN VARMA P.K.
61	VASUDEVAN M	68	M	21/Mar/2014	CAD,TVD,GD LV,SR,HTN	CABGX 5 GRAFTS,LIMA-LAD,RSVG-D1,D3,MAJ OM,RPDA	DR. JAYAKUMAR K
62	MOHANAN B	45	M	27/Mar/2014	CAD,TVD,GD LV,SR,DM,HTN	CABG X5 GRAFTS,LIMA-LAD,RSVG-OM1,OM2,PDA,MAJ DIAG	DR. PRAVEEN VARMA P.K.
63	RATHEESH K.	24	M	01/Apr/2014	S/P DVR,IE OF PV(MITRAL VALVE),MILD LVD,SR,SEPSIS	REDO MVR#26SEP	DR. PRAVEEN VARMA P.K.
64	WILSON P J	54	M	03/Apr/2014	MVP, SEV MR, CAD, TVD, GD LV, SR, HTN, DLP	CABGX 4 GRAFTS, LIMA-LAD,RSVG-D1,OM1,OM2,MVR#27 CHVP	DR. PRAVEEN VARMA P.K.
65	RAMACHANDRAN R.	67	M	04/Apr/2014	CAD, REC NSTEMI, LMCA TVD, MILD LVD, 1ST DEG HB,SR, DM, HTN, DLP	CABGX 6 GRAFTS LIMA-LAD,RSVG-D1,OM1,OM2,PDA,PLB	DR. JAYAKUMAR K
66	BALAKRISHNAN THAMPIL R.	62	M	07/Apr/2014	CAD ,TVD, FAIR LV, SR,DM, HTN	CABGX 5GRAFTS,LIMA-LAD,RSVG-D1,BOTH BR OF MAJ OM,DISTAL RCA	DR. JAYAKUMAR K
67	MOHAMMED SHAFEEQ M.	38	M	09/Apr/2014	CLEFT AML,SEV MR,SEV PAH,FAIR LV, SR,HYPOTHYROIDISM	MV REPAIR(A1 CLEFTCLOSURE, ATRIFICIAL CHORDAE TO NEO COMMISURE+ANNULOPLASTY #28 SADDLE RING	DR. VARGHESE T.PANICKER
68	ULAGAMMAL.S.	59	F	14/Apr/2014	RHD,SEV CAL AS,MOD AR,SEV -MOD LVD,SEV PAH,MILD MR,SR,NC	AVR#21 PM	DR. VARGHESE T.PANICKER
69	PACHIAPPAN P	49	M	16/Apr/2014	CAD,TVD,REC NSTEMI,OLD IPWMI.,GD LV,SR	CABGX 4 GRAFTS,LIMA-LAD,RSVG-D1,MAJ OM,RPDA	DR. JAYAKUMAR K
70	SAFEER .S	43	M	21/Apr/2014	RHD,SEV MR,SEV AR,SEV PAH,SR,FAIR LV, NC	DVR AV#25 CHVP,MV#29CHVP	
71	BENNYMON P.K.	50	M	22/Apr/2014	CAD,LMCA,TVD,SLVD,SR,HTN,DM,DLP,NEPHROPATHY	CABGX 5 GRAFTS,LIMA-LAD,RSVG-D1,MAJ OM,RI,RPDA	DR. JAYAKUMAR K
72	PADMASUNDHARAN K	57	M	24/Apr/2014	CAD,TVD,GDLV,DM,HTN,SR,DLP	CABGX4GR,LIMA-LAD,RSVG-D1,OM,RPDA	DR. JAYAKUMAR K
73	RAJAPPAN.G.	64	M	25/Apr/2014	CAD,TVD,CHR.STABLE ANGINA,DM,HTN,SR	CABGX 5 GRAFTS,LIMA-LAD,RSVG-D1,MAJ OM, PDA, PLB	DR. VIVEK V. PILLAI
74	KARUPAI.K	56	F	25/Apr/2014	RHD, SEVERE MS, MILD MR, MILD TR, MILD PAH, GOOD LV, AF, NC	MVR # 23 CHVP + PMLP	DR. BINEESH K.R.
75	SINDHU T	28	F	29/Apr/2014	OSASD,SEV PAH,BIDIRECTIONAL SHUNT,GDLV,SR	TPP CLOSURE OF ASD+PULMONARY VALVE INSPECTION	DR. BINEESH K.R.
76	RAVEENDRAN PILLAI G	70	M	29/Apr/2014	CAD,TVD,GDLV,SR,HTN,COPD	CABGX 3 GRAFTS,LIMA-LAD,RSVG-RI,DISTAL RCA	DR. PRAVEEN VARMA P.K.
77	ILLYAS ENTHIYAMMADINTE	48	M	30/Apr/2014	CAD,OLD IWMI,TVD,SEV LV DYSF,DM,HTN,DLP,SR	CABGX 4 GRAFTS,LIMA-LAD,RSVG-DIAG,PDA,RI	DR. PRAVEEN VARMA P.K.

78	STELLA K	43	F	1/May/2014	RHD,SEV CAL MS,MILD MR,MOD TR,ORG TVD,RVD,MOD PAH,GDLV,SR,NC	MVR#27CHVP+PMLP	DR. PRAVEEN VARMA P.K.
79	SUDHANANDAN K V	55	M	2/May/2014	CAD,OLD MI,TVD,GD LV,SR,DM,HTN,DLP	CABGX6 GRAFTS,LIMA-LAD,RSVG-D1,OM1,MAJ OM,PDA,PLB	DR. JAYAKUMAR K
80	THAMBI D. S. C	61	M	3/May/2014	CAD,TVD,FAIR LV,SR,DM,HTN,DLP	CABGX5 GRAFTS,LIMA-LAD,RSVG-PDA,PLB,MAJ OM,MAJ DIAG	DR. JAYAKUMAR K
81	VIJAYAN S	57	M	4/May/2014	SEV CAL AS,CAD,MILD LMCA,TVD,GDLV,SR,DM,HTN	AVR#21 PM,CABGX3 GRAFTS ,RSVG-LAD,	DR. VIVEK V. PILLAI
82	CHANDRA SEKHARAN U	55	M	5/May/2014	CAD,TVD,IWMI,SP/PCI (RCA),GDLV,CHB,DM,EXSMOKER	CABG X 5 GRAFTS(LIMA-->LAD,RSVG->D1,DIST RCA,OM1,AM,PDA,)	DR. JAYAKUMAR K
83	KASSIM.K.K	65	M	6/May/2014	CAD,DVD,LMCA,SEV CAL AS,FAIR LV FUNC,HTN,COPD	AVR#21PM,CABGX2 GRAFTS,RSVG-LAD,PDA	DR. VIVEK V. PILLAI
84	VIJAYADEVAN G	74	M	4/May/2014	CAD,REC AAWMI,,NSTEMI,LMCA+TVD,CHF(TREATED)FAIR LV,SR,DM,HTN,	CABGX 4 GRAFTS, RSVG-LAD,D1,MAJ OM,PDA	DR. VIVEK V. PILLAI
85	DHARMAR .P	68	M	5/May/2014	CAD,REC IWMI,TVD,GDLV,DM,HTN,DLP,SR	CABGX4 GRAFTS,LIMA-LAD,RSVG-D1,PDA,MAJ OM	DR. PRAVEEN VARMA P.K.
86	RAMACHANDRAN NAIR P	67	M	6/May/2014	CAD,OLD AAWMI,LMCA,TVD,MOD LV DYSFUNCTION,DM,HTN,DLP,SR	CABG X 5 GRAFTS,LIMA-LAD,RSVG-DISTAL RCA,RI,OM2, TERM OM	DR. VIVEK V. PILLAI
87	ABDUL LATHEEF A M	50	M	7/May/2014	CAD,TVD,GDLV,SR,HTN	CABG X 3 GRAFTS,LIMA-LAD,RSVG-RI,PDA	DR. JAYAKUMAR K
88	PRADEEP G	44	M	8/May/2014	CAD,TVD,OLD AAWMI,MOD-SEV MR,MOD LV DYSFUN,SR,HBSAG+	CABG X 4 + MV REPAIR(# 28 ANNULOPLASTY RING)	DR. JAYAKUMAR K
89	VASU K	61	M	9/May/2014	BICUSPID AO VALVE SEV AS SEV LVD SR	AVR #19 PERIMOUNT	DR. BINEESH K.R.
90	ARAVINDAKSHAN V	60	M	10/May/2014	CAD,TVD,FAIR LV,MILD PAH,MILD MR,SR,DM	CABG X 5 GRAFTS,LIMA-LAD,RSVG-D1,OM1,POST CRUX RCA,PDA	DR. JAYAKUMAR K
91	PATHROSE PHILIPPOSE	67	M	11/May/2014	CAD TVD GDLV SR DM HTN DLP	CABGX 4GRAFTS,LIMA-LAD,RSVG-RI,MAJ OM,PDA	DR. PRAVEEN VARMA P.K.
92	SREEKUMARI K	54	F	13/May/2014	CAD TVD LEFT SCA STENOSIS B/L RENAL ART STENOSIS GDLV SR	CABGX 5 GRAFTS,LIM-LAD,RSVG-D2,RI,TERM OM,RPDA	DR. VIVEK V. PILLAI
93	JJI K V	44	M	14/may/2014	CAD,TVD,GDLV,SR,HTN	CABGX 4 GRAFTS,LIMA-LAD,RSVG-MAJ DIAG,RI,RPDA	DR. VIVEK V. PILLAI
94	THAMPI N	65	M	15/may/2014	CAD,TVD,REC AAWMI,MILD MR,MILD LVD,SR,DM,HTN,DLP	CABGX5 GRAFTS,LIMA-LAD,RSVG-DISTAL LAD,D1,OM,PDA	DR. JAYAKUMAR K
95	ACHAMMA SUNNY VARGHESE	53	F	16/May/2014	CAD,TVD,NSTEMI OF AW,MOD LV,SR,HTN,DM,DLP	CABGX 5 GRAFTS,LIMA-LAD,RSVG-OM1,OM2,OM3,PRE CRUX RCA	DR. JAYAKUMAR K
96	VIJAYAKUMARA KURUP C	58	M	17/May/2014	CAD,TVD,OLD AW&IWMI,SEV LVD,MILD MR,DM,SR	CBGX5 GRFTS,LIMA-LAD,RSVG-OM1,TERM OM,DISTL RCA,RI+LV PLICATION	DR. JAYAKUMAR K
97	RAMA PANICKER.J.	65	M	18/May/2014	CAD,ACS,AAWMI,TVD,CRITICAL LMCA,GDLV,SR,LT.PVOD	CABGX5 GRAFTS,LIMA-LAD,RSVG-DIAG,2ND BRANCH OF OM,TERM OM,PDA,DIG ENDAECTOMY DONE	DR. JAYAKUMAR K
98	HARIDASAN S (S.C)	76	M	19/May/2014	CAD,TVD,GDLV,S/P PCI TO RCA WITH DISSECTION ,LMCA,DM,SR	CABGX 7 GRAFTS,LIMA-LAD,RSVG-DISTAL LAD,D1,RI,OM1,OM3,RPDA	DR. JAYAKUMAR K
99	BALACHANDRAN N (DR)	61	M	02/Jun/2014	CAD,REC AAWMI,TVD,GDLV,SR	CABGX 5 GRAFTS LIMA-LAD, RSVG-D1,OM1,OM2,PDA	DR. JAYAKUMAR K
100	ALAGAPPAN S	62	M	03/Jun/2014	CAD,TVD,OLD IWMI,GDLV,HTN,SR,DLP	CABGX 7 GRAFTSLIMA-LAD,RSVG-LAD,D1,D3,RPDA,MAJ OM,RPLB	DR. VIVEK V. PILLAI
101	SHAMSUDEEN M.	59	M	04/Jun/2014	CAD,REC MI,TVD,MOD LVD,SR,DLP,SMOKER	CABGX 6 GRAFTS,LIMA-LAD,RSVG-OM1,OM2,DIAG,PDA,PLB	DR. JAYAKUMAR K
102	SAJITHA K M	34	F	04/Jun/2014	ACHD,LARGE OS ASD,MOD PAH,SR	TPP CLOSURE OF OS ASD	DR. SIVAPRASAD V.
103	SANAL KUMAR C	60	M	05/Jun/2014	CAD,REC MI,REC ANGINA,TVD,MOD LVD,SR	CABGX 5GRAFTS,LIMA-LAD,RSVG-D2,MAJ OM,TERM OM,RPDA	DR. PRAVEEN VARMA P.K.

104	RAJESWARI S	66	F	09/Jun/2014	CAD,TVD,GDLV,,SR,DM	CABG X4 GRAFTS LIMA-LAD,RSVG-PDA,OM2,OM3	DR. JAYAKUMAR K
105	OMANA K	58	F	09/Jun/2014	HCV(+),CAD,LMCA(30-40%),DVD,LBBB,MILD LVD,HTN,DLP,SR	OPCABG X2 GRAFTS,LIMA-LAD,RSVG-D1	DR. JAYAKUMAR K
106	NALINI K.K.	65	F	10/Jun/2014	MVP OF AML &PML,SEV MR,TVP,MOD TR,GDLV,AF,NC	MVR#25 PM WITH TOTAL CHORDAL PRESERVATION+TVA #30 MC3 RING	DR. VARGHESE T.PANICKER
107	BABU R	46	M	10/Jun/2014	CAD,MILD LVD,LMCA,TVD,DM,SR	CABGX 4 GRAFTS,LIMA-LAD,RSVG-D1,OM1,PDA	DR. JAYAKUMAR K
108	SIMON CHAKO K.	69	M	11/Jun/2014	CAD,TVD,GDLV,SR,DM,HTN	CABGX 5 GRAFTS,LIMA-LAD,RSVG-RI,UPPER BR OF MJ OM, LOW BR OF MJ OM,PDA	DR. JAYAKUMAR K
109	NABEESA BEGUM M.	68	F	12/Jun/2014	SEV CAL AS,GDLV,SR,NC	AVR#19PM	DR. VARGHESE T.PANICKER
110	NAGENDRAN K	40	M	12/Jun/2014	LA MYXOMA,SEV PAH,MOD-SEV RV DYSFUNCTION	LA MYXOMA EXCISION AND TPP CLOSURE OF ASD	DR. VARGHESE T.PANICKER
111	JOHN NETTO. G.	53	M	13/Jun/2014	BAV,SEV AR,DIL ASC AORTA,SR.	BENTALLS PROCEDURE (#28 ALBOGRAFT +AVR# 27 CHVP)	DR. JAYAKUMAR K
112	RAJU M	55	M	16/Jun/2014	BAV,RSOV,SEV AR,MOD AS,MOD PAH,MOD LVD,AF	BENTALLS USING 26 #ALBOGRAFT	DR. JAYAKUMAR K
113	RATHEESH K S.	32	M	17/Jun/2014	OS ASD,L-R SHUNT,SEV PAH,GDLV,SR	TPP CLOSURE OF ASD+ PFO MADE OPEN	DR. BINEESH K.R.
114	LEELAMMA P.	62	F	17/Jun/2014	CAD,TVD,GDLV,SR,HTN,DM	CABGX 4 GRAFTS,LIMA-LAD,RSVG-RI,OM,DISTAL RCA	DR. JAYAKUMAR K
115	REBECCAMMA JOHN	65	F	18/Jun/2014	CAD,TVD,GDLV,SR,DM,HTN	CABGX 5 GRAFTS,LIMA-LAD,RSVG-D1,OM,DISTAL RCA BOTH BRANCHES	DR. JAYAKUMAR K
116	LYSAMMA ROCKY	49	F	18/Jun/2014	RHD,SEV MS,MOD MR,MILD PAH,GDLV,AF,NC.	MVR#27 CHVP+PARTIAL PMLP	DR. VIVEK V. PILLAI
117	GANGADHARAN NAIR C	73	M	19/Jun/2014	SEV CAL AS,MOD -SEV AR MOD LVD,PAROXYSMAL AF,NC	AVR#21PM	DR. BINEESH K.R.
118	SREEKUMARAN NAIR J P	63	M	19/Jun/2014	CAD,DVD,GDLV,SR,DM	CABGX 5 GRAFTS,LIMA-LAD,RSVG-D1,OM,PDA,PLB	DR. JAYAKUMAR K
119	VASUDEVAN P.	55	M	20/Jun/2014	CAD,TVD,LVD,SR,DM,HTN,POLIO RT LL,B/L MILD POVD	CABGX 4 GRAFTS,LIMA-LAD,RSVG-D1,OM1,PDA	DR. JAYAKUMAR K
120	SATHYABALAN P.K.	50	M	23/Jun/2014	CAD,TVD,REC AMI,GDLV,SR,DM	CABGX 6 GRAFTS LIMA-LAD,RSVG-D1,MAJ OM,TERM OM,RCA,RPDA	DR. JAYAKUMAR K
121	RAJEEVAN N	54	M	23/Jun/2014	CAD,TVD,GDLV,SR,DM	CABGX 4 GRAFTS,LIMA-LAD,RSVG-OM1,TERM OM,RPDA	DR. VIVEK V. PILLAI
122	DANAMMA T	53	F	27/Jun/2014	CAD,TVD,MILD LVD,SR,DM,DLP,	CABGX5 GRAFTS,LIMA-LAD,RSVG-D2,OM2,RPDA,DISTAL RCA PIGGY BACKED TO RPDA	DR. VIVEK V. PILLAI
123	PANICKER N.G.S	61	M	03/Jul/2014	CAD,TVD,LMCA,FAIR LV,FAIR RV,LBBB,DM,	CABGX4 GRAFTS LIMA-LAD,RSVG-D1,RPDA,RI	DR. JAYAKUMAR K
124	RAJAMMA J	65	F	05/Jul/2014	CAD,TVD,VSR,MOD LVD,MILD MR,SR,DLP	CABGX 2GRAFTS,RSVG-LAD,D+PTFE CLOSURE OF VSR	DR. JAYAKUMAR K
125	RAJAGOPALA PILLAI D	72	M	07/Jul/2014	SEV AS,MOD AR,GDLV,,MILD CAD,SR,DM	AVR#21PM	DR. BINEESH K.R.
126	HAMSA P P	63	M	07/Jul/2014	CAD,LMCA,TVD,MILD LVD,SR	CABGX5 GRAFTS,LIMA-LAD,RSVG-D1,TERM OM,RPDA,RI	DR. JAYAKUMAR K
127	KANNAPPAN K	61	M	08/Jul/2014	CAD,TVD,REC NSTEMI,GDLV,SR,DM,HT	CABGX4 GRAFTS LIMA-LAD,RSVG-D1,RI,PDA+ DIAG ENDARTECTOMY DONE	DR. JAYAKUMAR K
128	ARAVIND .R	14	M	08/Jul/2014	RHD,SEV MR,MOD AR,SEV TR,SEV PH,WPWS,S/P RFA,GDLV	DVR(MVR#25CHVP,AVR#19 CHVP)+BICUSPIDIZATION OF TV, ABALATION OF ACCESSORYPATHWAY	DR. VARGHESE T.PANICKER

129	GOPALA PILLAI N	65	M	09/Jul/2014	CD,TVD,MILD AS,GDLV,SR	CABGX 4 GRAFTS,RSVG-DISTAL LAD,OM1,OM3,RPLB	DR. VIVEK V. PILLAI
130	RAJASEKHARAN NAIR G	42	M	10/Jul/2014	CAD,TVD,GDLV,SR,DLP	CABGX 5 GRAFTS,LIMA-LAD,RSVG-MAJ DIAG,OM1,TERM OM, RPDA	DR. JAYAKUMAR K
131	SAITHALAVI C C	48	M	11/Jul/2014	CAD,TVD,GDLV,SR,DM.	CABGX 4 GRAFTS,LIMA-LAD,RSVG-D1, MAJ OM,PDA	DR. VIVEK V. PILLAI
132	CICILY P.J.	60	F	11/Jul/2014	CAD,LMCA+TVD,MOD LVD,SR,DM,HTN	CABGX 4 GRAFTS LIMA-LAD,RSVG-D1,OM,PDA	DR. JAYAKUMAR K
133	JANCY HARRIS T.	46	F	12/Jul/2014	S/P SUPRA CORONARY ACS AO REPLACEMENT FOR TYPE A AO DISSECTION,REDUCED RT LL DISTAL PULSE	RT FEMORAL CANNULATION SITE REEXPLORATION WITH FEMORAL AETERY EMBOLLECTOMY DONE	DR. BINEESH K.R.
134	SEETHAMMAL.M	20	F	14/Jul/2014	SEV CAL AS, MOD AR, MOD MR, GOOD LV, SR, SEIZURE DISORDER	KONNO RASTON PROCEDURE .AVR #17 CHVP	DR. JAYAKUMAR K
135	RAJUKUTTY G (DR)	61	M	14/Jul/2014	CADTVD,GDLV,SR,DM,HTN,HYPOTHYROIDISM	CABGX 5 GRAFTS,LIMA-LAD,RSVG-MAJ OM,AM,PLB,OM2	DR. JAYAKUMAR K
136	MARAKKAR K.N.	57	M	15/Jul/2014	CAD,TVD,MILD MR,MILD LVD,HTN,SR	CABGX 5 GRAFTS,LIMA- MID LAD,RSVG-D1,OM1,TERM OM.,RPDA	DR. VIVEK V. PILLAI
137	SREEDHARAN P.	71	M	16/Jul/2014	CAD,LMCA,TVD,GDLV,HTN,SR	CABGX 4 GRAFTS,LIMA-LAD,RSVG-RI,MAJ OM,RPDA	DR. JAYAKUMAR K
138	ABDUL AZEEZ	58	M	17/Jul/2014	CAD,TVD,GDLV,DM,HTN,SR	CABGXLIMA-LAD,RSVG-MAJ D,OM1,PDA,PLB(PDA PIGGY BACKED TO PLB)	DR. JAYAKUMAR K
139	CHANDRASEKHARAN P	69	M	17/Jul/2014	CAD,LMCA,DVD,GDLV,DM,HTN	CABGX5 GRAFTS,LIMA-LAD,RSVG-MAJ DIAG,RI,MAJ OM,RPDA	DR. JAYAKUMAR K
140	RAHIM D	54	M	18/Jul/2014	CAD,TVD,GDLV,HTN,SR,DLP	CABGX 4 GRAFTS,LIMA-LAD,RSVG-MAJ D,TERM OM,AM	DR. JAYAKUMAR K
141	JANARDHANAN K	57	M	21/Jul/2014	CAD,TVD,SEV LVD,MILD MR,MOD PAH,SR,DM,HTN	CABGX4 GRAFTS,LIMA-LAD,RSVG-D1,MAJ OM,DISTAL RCA,+LV PLICATION	DR. JAYAKUMAR K
142	VELAYUDHAN P C	56	M	22/Jul/2014	CAD,TVD,GDLV,SR,DM	CABGX 6 GRAFTS,LIMA-LAD,RSVG-DISTALLAD, D1,PDA,PLB,MAJ OM,(DISTAL LAD PIGGYBACKED TO D1)+PDA ENDARTECTOMY DONE	DR. VIVEK V. PILLAI
143	ROJI .V	28	F	23/Jul/2014	OS ASD,MOD PAH,GD LV,SR	TPP CLOSURE OF OSASD	DR. SIVAPRASAD V.
144	PARAMESWARAN PILLAI R	63	M	23/Jul/2014	CAD,TVD,MOD LVD,SR	CABGX 3 GRAFTS,LIMA-LAD,RSVG-D, RI	DR. PRAVEEN VARMA P.K.
145	KANAKAMMA L	56	F	24/Jul/2014	CAD,LMCA(20-30%),TVD,GDLV,SR,DM,HTN,DLP	CABGX 4 GRAFTS,LIMA-LA,RSVG-D1,PDA,OM	DR. PRAVEEN VARMA P.K.
146	PADMARAJAN P K.	50	M	29/Jul/2014	CAD,TVD,GDLV,SR,DM.	CABGX 6 GRAFTS,LIMA-LAD,RSVG-DISTAL LAD,D1,OM1,OM2,RPDA(D1 PIGGYBACKED TO DISTAL LAD)	DR. VIVEK V. PILLAI
147	KUPPUSWAMY A.	64	M	30/Jul/2014	CAD,TVD.S/P PCI LAD,SEV LVD,SR	CABGX 4 GRAFTS+DORS PROCEDURE(LIMA-LAD,RSVG-RI,MAJ OM,DISTAL RCA)	DR. JAYAKUMAR K
148	SANKARAN K	61	M	31/Jul/2014	CAD,DVD,GDLV,SR,HTN	CABGX 3 GRAFTS,LIMA-LAD,RSVG-D1,RI	DR. VIVEK V. PILLAI
149	SIYA S.	1	F	04/Aug/2014	CCHD,TOF,GOOD PA,PFO,GD LV,SR,NC	ICR+ MPA PLASTY	DR. SABARINATH MENON
150	RANA MEHARIN	2	F	05/Aug/2014	LARGE INFLOW VSD,SEV PS(INFUNDIBULAR),GOOD LV,SR,NC	BDG+ATRIAL SEPTECTOMY	DR. THOMAS MATHEW
151	ALTHAF HARIZ H.	10	M	12/Aug/2014	S/P BDG,WITH PA PLASTY, SOR SV(RV), CONT PA,MILD AVVR, GOOD VENT FUNCTION, SR	TCPC WITHEXTRA CARDIAC FENESTRATED FONTAN,WITH 20 MM PTFE WITH 4 MM FENESTRATION.	DR. BAIJU S.DHARAN

152	SANUSHA KOONARI	0	F	13/Aug/2014	SI,DC,DORV,CA, SV(RV)PA, ASD,VSD,PDA,LSVC,SR	B/L BDG+ PA PLASTY	DR. SABARINATH MENON
153	B/O MELVIN	0	F	14/Aug/2014	SS,DC,L-TGA,PA, VAD, LPA ORGIN STENOSIS,PDA,GOOD VENT FUNCTON ,SR	RMBTS#3.5 MM PTFE GRATFT,+LPA PLASTY USING BPP	DR. BAIJU S.DHARAN
154	MISRIFA G	3	F	18/Aug/2014	TOF,SEV INF PS,MAL ALLIGNED SA VSD,NC,SR (RACHS 2)	ICR	DR. BAIJU S.DHARAN
155	JEFFIN S	7	M	18/Aug/2014	ACHD,SV ASD,NO PAH,SR	TPP CLOSURE OF ASD BY DOUBLE PATCH TECHNIQUE	DR. SABARINATH MENON
156	SOORYA NANDAN	2	M	19/Aug/2014	TOF,GD PA ANATOMY,SR,NC	ICR+TAP+MONOCUSP RECONSTRUCTION OF RVOT	DR. SABARINATH MENON
157	NOOR JAMAL HUQUE	2	M	20/Aug/2014	CCHJD,TOF,LAD CROSSING RVOT,RT ARCH,SPELLS +,GDLV,S	ICR+MPA PLASTY	DR. THOMAS MATHEW
158	MUHAMMED SUFYAN S.	8	M	22/Aug/2014	S/P ICR FOR TOF, SEV INF PS,GD LV, MOD RVD,SR	REDO ICR WITH MPA PLASTY	DR. THOMAS MATHEW
159	RAM PRAMODH S.J.	1	M	26/Aug/2014	ACHD, SA VSD, SEPTAL ANEURYSM, OS ASD, SEV PAH	TPP CLOSURE OF VSD AND ASD CLOSURE.	DR. THOMAS MATHEW
160	FATHIMA	15	F	28/Aug/2014	SS,LC,PA,LARGE INLET VSD,SV,ASD,PDA,B/L SVC,S/P BDG,SMALL PA	TCPC	DR. THOMAS MATHEW
161	SANKARANKUTTY K	42	M	01/Sep/2014	CAD,TVD,LMCA(80%),DLP,GDLV,SR,	CABGX 4 GRAFTS,LIMA-LAD,RSVG-OM1,OM2,PDA	DR. VIVEK V. PILLAI
162	OMANA CHACKO	69	F	03/Sep/2014	CAD,LMCA,DVD,GDLV,HTN,DM,SR	CABGX 3 GRAFTS,LIMA-LAD,RSVG-D1,MAJ OM	DR. JAYAKUMAR K
163	NIKITHA P S	25	F	03/Sep/2014	ACHD, OSASD, SEVERE PAH, SR	TANNED PERICARDIAL PATCH CLOSURE ASD	DR. SUDIP DUTTA BARUAH
164	PHILOPOSE L.	67	M	04/Sep/2014	CAD,TVDGD LV,SR,DM,DLP,VV	CABGX 6 GRAFTS,LIMA-LAD,RSVG-D1,D2,OM3,PDA,PLB,PDA PIGGYBACKED TO PLB	DR. JAYAKUMAR K
165	SUDHA R.	67	F	05/Sep/2014	RHD,SEV MR,MOD TR,MOD PAH,NC,AF	MVR#25PM WITH TOTAL CHORDAL PRESERVATION	DR. VIVEK V. PILLAI
166	NELSON E.	72	M	22/Sep/2014	CAD,TVD,GDLV,HTN,DLP	CABGX 4 GRAFTS,LIMA-LAD,RSVG-,MAJ OM,RI,DISTAL RCA	DR. VIVEK V. PILLAI
167	ABDUL RASHEED.S	62	M	23/Sep/2014	CAD TVD MOD AS, GD LV,SR,DM, HTN,COPD	CABGX 3 GRAFTS RSVG-LAD,MAJ OM, PDA,+AVR#23PM	DR. VIVEK V. PILLAI
168	JOSE KUMAR V.	48	M	24/Sep/2014	CAD,DVD,REC ACS, NSTEMI,GDLV, SR,HTN	CABGX4 GRAFTS,LIMA-LAD,RSVG-RV BRANCH,OM1,D1	DR. VIVEK V. PILLAI
169	JOSE KUMAR V.	48	M	25/Sep/2014	S/P CABG WITH MEDIASTINAL BLEED	RE-EXPLORATION	DR. BINEESH K.R.
170	GEETHA P	53	F	25/Sep/2014	BAV,SEV CAL AS, GD LV, SR,DLP,HTN	AVR#17 CHVP	DR. BINEESH K.R.
171	CHELLAMMA N	65	F	26/Sep/2014	CAD,LMCA,TVD,MILD MR,GDLV,SR,HTN	CABGX4GRAFTS,LIMA-DIAG,RSVG-LAD,OM1,PDA	DR. VIVEK V. PILLAI
172	RAVI KUMAR M.	64	M	29/Sep/2014	CAD,TVD,GDLV,SR,HTN	CABG X4 GRAFTS (LIMA-->LAD, RSVG-->D.RI,DISTAL RCA)	DR. JAYAKUMAR K
173	RIVKA PRAVEEN	0	F	07/Oct/2014	TRANSITIONAL AVCD,SEV B/L AVVR,MOD PAH,SR	AVCD REPAIR BY SINGLE PATCH TECHNIQUE	DR. SABARINATH MENON
174	DIVYA T	6	F	08/Oct/2014	ACHD, LARGE OS ASD, TRIVIAL MR, SR	TANNED PERICARDIAL PATCH CLOSURE OF ASD	DR. ASHOK KUMAR C J
175	FATHIMA RIDHA .A	2	F	09/Oct/2014	CCHD,TOF,GD PA, GD LV, SR, NC	ICR+RVOT PATCH	DR. SABARINATH MENON
176	SREYAS S	10	M	13/Oct/2014	ACHD, SV ASD, PAPVC OF RUPV, MILD PAH, SR	SV ASD CLOSURE + PAPVC REROUTING (DOUBLE PATCH TECHNIQUE)	DR. ASHOK KUMAR C J
177	HIMA RAJESH	2	F	15/Oct/2014	CCHD,TOF,ABSENT PULM VALVE,CONFLUENT PA,GD LV,SR	ICR+TAP+BICUSPID RECONSTRUCTION OF RVOT	DR. SABARINATH MENON
178	ANNA. S.K	3	F	17/Oct/2014	CCHD,SV(LV),DILV,DTGA,SEV LVOTO,MILD RT AVVR,MILD PAH,S/P PA BANDING(2011),SR	LVOTO RESECTION AND B/L BDG	DR. BAIJU S.DHARAN

179	ANSIF RASILY	3	M	27/Oct/2014	CCHD,TOF,CONF PA,PDA,SR	TRANS RA-RVOT ICR+RVOT PATCH PLASTY+PFO OPEN	DR. SABARINATH MENON
180	HAMDAN A.N.	0	M	27/Oct/2014	SICK SINUS SYNDROME, GOOD BI VENTRICULAR FUNCTION	TEMPORARY VENTIRUCULAR PACING WIRE IMPLATATION	DR. MOHAMMED IDHREES A.
181	DRISYA T.P.	19	F	28/Oct/2014	CCHD DORV, SPVSD, SEV PS,PDA , FAIR RV FUNCTION, CYANOTIC SPELL,SR	BDG+ATRIAL SEPTECTOMY DONE	DR. SABARINATH MENON
182	KARTHIKEYAN O S.	0	M	30/Oct/2014	SA VSD,PDA,SEV PAH, PDA,GD LV, SR, DOWN'S SYND,HYPOTHYROIDISM	VSD CLOSURE(GP CLOSURE OF VSD+PDA INTERRUPTION)	DR. SABARINATH MENON
183	RAMACHANDRAN T	64	M	03/Nov/2014	CAD,TVD,GDLV,SR, DM,HTN, URETHRAL STRICTURE	CABGX 4 GRAFTS(LIMA-LAD,RSVG-D1,OM1,AM)	DR. VIVEK V. PILLAI
184	YASODA A.P.	63	F	04/Nov/2014	SEV CAL AS, MILD AR, CAD, SVD, GDLV,SR,DM	AVR(#21 PM)+ CABG X 1 GRAFTS (RSVG-PDA)	DR. VIVEK V. PILLAI
185	PRABHAKARAN R.	75	M	04/Nov/2014	CAD,TVD,GD LVV, SR,DM,HTN,DLP	CABG X 5 GRAFTS (RSVG-LAD,D1,OM1,OM3,PDA)	DR. VIVEK V. PILLAI
186	SATHEESAN S	56	M	05/Nov/2014	CAD,TVD,GOOD LV, SR,DM, HTN,DLP	CABGX 6 GRAFTS, LIMA-LAD,RSVG-MAJ DIAG, OM1,OM2,PDA,PLB (PDA PIGGYBACKED TO PLB)	DR. JAYAKUMAR K
187	PRASANNAN K.	61	M	06/Nov/2014	CAD,TVD,GDLV,SR,DM,HTN	CABGX 5 GRAFTS,(LIMA-LAD,RSVG-D1,MAJ OM,RPDA,RPLB)	DR. VIVEK V. PILLAI
188	SUNJA.A	36	F	07/Nov/2014	ACHD,SP VSD,RCC PROLAPSE,SEV AR,GDLV,SR	VSD CLOSURE (USING DACRON PATCH)+AVR# 23 CHVP	DR. VIVEK V. PILLAI
189	RAMAKRISHNAN K.N	63	M	07/Nov/2014	CAD,TVD,SEV LVD,SR,HTN	CABGX 4 GRAFTS (LIMA-LAD,RSVG-D1, MAJ OM,RPDA)	DR. VIVEK V. PILLAI
190	MADHUSOODHANAN NAIR V.	61	M	10/Nov/2014	CAD,TVD,S/P PCI-CA,POBA-PDA,GDLV,SR,DM,HTN,RENAL DYSFUNCTION	CABGX7 GRAFTS,LIMA-LAD,RSVG-DISTAL LAD,D1,OM1,OM2,AM,RPDA	DR. VIVEK V. PILLAI
191	VIJAYAN S.	49	M	11/Nov/2014	CAD,TVD,GDLVHTN,DLP,DM	CABGX 5GRAFTS _LIMA-(LAD,RSVG-D1,OM1,RPDA,RPLB)	DR. VIVEK V. PILLAI
192	RASHEED P	41	M	13/Nov/2014	BAV,SEV CAL AS,MILD AR,GOOD LV,SR	AVR#23 CHVP	DR. BINEESH K.R.
193	ABDUL VAHID A	53	M	13/Nov/2014	CAD,TVD,GDLV,SR,HTN	CABGX 4 GRAFTS(LIMA-LAD,RSVG-MAJ DIAG,MAJ OM,DISTAL RCA.	DR. VIVEK V. PILLAI
194	SAILA RAJAN	71	M	14/Nov/2014	CAD,TVD,MOD LVD,SR,HTN,DLP	CABGX 6 GRAFTS,LIMA-LAD,RSVG-D2,OM1,OM2,PLB,DISTAL LAD	DR. JAYAKUMAR K
195	SASIDHARAN PILLA B	65	M	17/Nov/2014	CAD,TVD, MILD LVD,SR, DM, HTN	CABGX4 GRAFTS(RSVG-D1,MAJ OM,PDA,LAD)LAD SIDE TO SIDE TO OM,PDA END TO END TO LAD,D1 PIGGY BACKED TO OM	DR. JAYAKUMAR K
196	BENNY K A	38	M	19/Nov/2014	ACHD, OSASD, SEV MR, AML-PML PROLAPSE,SEV TR,MILD RVD, GDLV, AF	MV REPAIR(29 TAILOR RING+TV REPAIR+TPPCLOSURE OF ASD	DR. VARGHESE T.PANICKER
197	CELINE SHANTHA MARY G	33	F	19/Nov/2014	ACHD, OSASD, MILD MR, SEV PAH, SR	TPP CLOSURE OF ASD + FENESTRATION DONE IN TPP	DR. VARGHESE T.PANICKER
198	VIJAYAKUMARAN NAIR.S.	60	M	21/Nov/2014	SEV MR,MILD TR,MILD PAH, PAROX AF, NC	MV REPAIR(TRIANGULAR RESECTION OF P2_#23TAILOR RING ANNULOPLASTY)	DR. VARGHESE T.PANICKER
199	MARESWARY S	38	F	21/Nov/2014	RHD SEV MS, MOD MR, GDLV ,SR ,NC, H/O CVA	MVR#23CHVP+PMLP	DR. BINEESH K.R.
200	RADHAKRISHNAN T.A	56	M	24/Nov/2014	CAD TVD GDLV SR DM HTN DLP SMOKER	CABGX 4 GRAFTS (LIMA-LAD,RSVG-MAJ OM,PLB,RI)	DR. JAYAKUMAR K
201	DOMINIC O. XAVIO	70	M	24/Nov/2014	CAD,TVD,GDLV,SR,MILD AS,LT CAROTID STENOSIS,DM,HTN	CABG X 5 (LIMA - LAD ,RSVG - MAJ DIAGONAL , OM ,OM 2 , PDA)	DR. JAYAKUMAR K
202	APPUNNI K P	58	M	25/Nov/2014	CAD,TVD,GDLV,SR,DM,HTN	CABG X 4 GRAFTS (LIMA-LAD,RSVG-MAJ DIAG , MAJ OM , PDA)	DR. VIVEK V. PILLAI
203	JESSY JOSEPH	54	F	25/Nov/2014	CAD LMCA TVD GDLV SR DM HTN DLP	CABGX 5 GRAFTS (LIMA-LAD,RSVG-OM1,OM2,PDA,PLB)	DR. JAYAKUMAR K

204	RETNADEEPAM J.	74	F	26/Nov/2014	CAD TVD LMCA DVD GDLV SR	CABG X2 GRAFTS(RSVG-RI,LAD)	DR. JAYAKUMAR K
205	THANKAMONY NAIR K	69	M	27/Nov/2014	CAD TVD SEVLVD SR DM HTN DLP	CABG 4 GRAFTS LIMA-LAD,RSVG-MAJ DIAG,PDA,PLB	DR. JAYAKUMAR K
206	DEVAN .P.M	41	M	27/Nov/2014	ACHD OS ASD PAPVC OF RUPV	REROUTING OF RUPV TO LA THROUGH EXTENSION OF OS ASD, WITH TPP.	DR. BINEESH K.R.
207	SAVITHA C	36	F	28/Nov/2014	ACHD,OP ASD,AML CLEFT,MOD-SEV MR,MOD PAH,GOOD B/V FUNCTION,SR	TPP CLOSURE OF OP ASD+ MV ANNULOPLASTY USING #27 TAILOR RING	DR. VIVEK V. PILLAI
208	MINNU P.	7	F	29/Nov.2014	SS,LC,SA VSD,SEV INFUN PS,GOOD PA,GOOD LV,SR	ICR(TRANS RA-RV(RVOT PATCH)	DR. BAIJU S.DHARAN
209	MIDHUN.M.S	10	M	30/Nov/2014	SV (LV),L-POSED AO,SEV PAH,S/P PA BAND (2004) , SR	BDG+MPA INTERRUPTION+MAPCA LIGATION	DR. THOMAS MATHEW
210	LIMA ANUPAM	27	F	1/Dec/2014	CCHD,TOF,CONF PA,SR,HYPOTHYROID	ICR(TRANS RA-RV WITH RVOT PATCH)	DR. SABARINATH MENON
211	DOWLATH A. A.	0	F	2/Dec/2014	TOF,CONF PA,GDLV,,SR, WITH SPELL	ICR(TRANS RA-PA+TAP +MONOCUSP RECONSTRUCTION OF RVOT	DR. THOMAS MATHEW
212	HARIGOVIND K KARTHA	4	M	3/Dec/2014	ACHD,OS ASD,GDLV,SR	TPP CLOSURE OF ASD BY MINISTERNOTOMY	DR. BINEESH K.R.
213	B/O SHELLYMOL	0	F	4/Dec/2014	ACHD, CHB,PDA, OS ASD,GD LV, SR	PDA CLIPPING+PPI IMPLANTATION	DR. THOMAS MATHEW
214	ANARIKA RAJEEV	2	F	17/Dec2014	ACHD,OS ASD,B/L SVC,GD LV,SR	TPP CLOSURE OF ASD BY MINISTERNOTOMY	DR. SABARINATH MENON
215	B/O SHEEJA	0	F	18/Dec/2015	ACHD,TYPE II AP WINDOW,SEV PAH,TOPSY TURVY HEART,AASD,GD LV,SR	AP WINDOW REPAIR, DC OF ASD	DR. BAIJU S.DHARAN
216	NIHAS.K	14	M	19/Dec/2015	ACHD, DC VSD,RCC PROLAPSE,MILD AR,MILD INF PS,PFO,GD LV,SR	ICR(GP CLOSURE OF VSD+INFUNDIBULAR RESECTION)	DR. SABARINATH MENON
217	MATHIRAM .I.	4	M	20/Dec/2015	S/P ATRIAL SEPTATION + MV REPAIR (2012),SEV MS,SEV PAH,SR	MV REPAIR(SUPRA MITRAL MEMBRANE EXCISION+COMMISUROTOMY+TV REPAIR)	DR. THOMAS MATHEW
218	FAVAS S	7	M	21/Dec/2015	TOF,CONF PA,ASD,PDA,GD LV,SR	ICR(TRANS RA-RV)+RVOT PATCH+MPA PLASTY+PDA LIGATION	DR. THOMAS MATHEW
219	SACHIN V S	2	M	27/Dec/2015	CCHD,TOF,(RESTRICTIVE VSD CLOSED BY A MEMBRANE) CONF PA,GDLV,SR,NC	ICR(TRANS RA-RV)+RVOT PATCH+MPA PLASTY+DC OF TWO ADDITIONAL VSD	DR. THOMAS MATHEW
220	ANEESH A.	24	M	28/Dec/2015	S/P ROSS KONNO PROCEDURE FOR AS,AR,P/ MVR, FOR SEV MS(2005)SEV PR,TR,SEV RVD,SR	PULMONARY HOMOGRAFT CHANGE USING 27# AORTIC +TV REPAIR	DR. THOMAS MATHEW
221	RAIHANA	2	F	29/Dec/2015	ACHD,TRANSITIONAL AVCD,MILD-MOD MR,MILD TRGD LV SR	ICR(MODIFIED SINGLE PATCH TECHNIQUE)	DR. BAIJU S.DHARAN
222	MUHAMMED SAHAD P.S.	1	M	30/Dec/2015	SA VSD,(BDS),SEV PAH,GD LV/RV FUNCTION,SR	GP CLOSURE OF VSD +ASD CLOSED BY FLAP VALVE TECHNIQUE	DR. SABARINATH MENON
223	SRUTHI T S	11	F	31/Dec/2015	ACHD,OS ASD, SR	TPP CLOSURE OSASD	DR. SUDIP DUTTA BARUAH
224	MUTHU MADHU	2	F	01/Jan/2015	ACHD,PDA,SEV PAH,GD LV,SR	PDA INTERRUPRION	DR. SABARINATH MENON
225	GOURI S LAL	8	F	01/Jan/2015	ACHD,OS ASD,GDLV,NO PAH,SR	TPP CLOSURE OF ASD	DR. SABARINATH MENON
226	ABDURAHIMAN P.K.	0	M	02/Jan/2015	DORV,SP VSD,ASD,PDA,ARCH HYPOPLASIA,MOD COA,SR	ASO+AORTIC ARCH ADVANCEMENT+VSD CLOSURE	DR. THOMAS MATHEW
227	MUHAMMED A	3	M	05/Jan/2015	ACHD,OS ASD,MVP OF AML,MILD PAH,SR	MV REPAIR(POSTERIOR ANNULOPLASTY USING TPP)+ TPP CLOSURE OF ASD	DR. THOMAS MATHEW

228	SATVIK KRISHNA S.	0	M	07/Jan/2015	ACHD,SA VSD,SEVERE PAH,SR	GP CLOSURE OF VSD	DR. BAIJU S.DHARAN
229	PARVANA N.S.	3	F	08/Jan/2015	CCHD,TOF,SUB VALVULAR PS,GDLV,SR	ICR(TRANS RA-RV)+RVOT PATCH	DR. SABARINATH MENON
230	ARATHI KRISHNA	1	F	12/Jan/2015	SI,DC,DORV,CAVCD(UNBALANCED),SCTAPVC,RT ATRIAL ISOMERISM, MILD AVVR,MILD PAH,GD LV,SR.	TAPVC REPAIR(PRIMARY SUTURELESS REPAIR),+BDG	DR. BAIJU S.DHARAN
231	SALMAN FARIS K	3	M	13/Jan/2015	CCHD,TOF, ADDITIONAL ANTERIOR MUSCULAR VSD,GD LV,SR	ICR(TRANS RA-RV)+RVOT PATCH+DC OF ADDITIONAL VSD (MINISTERNOTOMY)	DR. SABARINATH MENON
232	B/O FASILA	0	F	19/Jan/2015	SI,DC,DORV,SAVSD,SEV PAH,GD LV, SR	ICR(VSD ROUTED TO AO USING GOETEX PATCH)	DR. BAIJU S.DHARAN
233	ANSHA K SHAJI	7	F	20/Jan/2015	ACHD,OS ASD,NO PAH,GDLV,SR	DC OF ASD BY LIMITED POSTERIOR THORACOTOMY	DR. THOMAS MATHEW
234	MANYA M.R.	12	F	22/Jan/2015	S/P TCPC FOR D-TGA,SEV PS NOW WITH CHB,SEV LVOTO,GD LV,	VSD ENLARGEMENT+PPI	DR. BAIJU S.DHARAN
235	B/O RAJANI	0	M	23/Jan/2015	ACHD,TYPE II AP WINDOW,SEV PAH, GD LV ,SR	BOVINE PERICARDIAL CLOSURE OF AP WINDOW	DR. BAIJU S.DHARAN
236	B/O SABIRA	0	M	26/Jan/2015	DTGA, IVS, PDA,SMALL ASD, SEVERE LVOTO, S/P BAS,SR,1 LCX 2 R	RMBTS # 3.5 MM GORTEX SHUNT	DR. SABARINATH MENON
237	PAVITHRA K.	12	F	27/Jan/2015	S/P BDGFOR PA,SAVSD,PULMOVARY AV MALFORMATIONS,MAPCAS,GD LV, SR	REDOSTERNOTOMY+ICR WITH PULMONARY CONDUIT(#23 PULMONARY CONDUIT)	DR. BAIJU S.DHARAN
238	NAZRINA S.N,	3	F	28/Jan/2015	ACHD,OSASD,PAPVC,GD LV, SR	WARDENS PROCEDURE	DR. SABARINATH MENON
239	B/O PACKIA LAKSHMI	0	M	29/Jan/2015	CCHD,D-TGA,MID MUSCULAR VSD,MOD -SEV PAH,PFO,PRESERVED LV,NORMAL CORONARIES,SR	ASO+VSD CLOSURE	DR. BAIJU S.DHARAN
240	SABARINATH AJEESH	0	M	30/Jan/2015	CCHD,MIXED TAPVC, RESTRICTIVE ASD, SEV PAH, GD LV, SR	TAPVC REPAIR BY CS CUTBACK TECHNIQUE+LUPV ANASTOMOSED TO LA	DR. THOMAS MATHEW
241	HAMZA M	55	M	02/Feb/2015	SV ASD, PAPVC OF RUPV & RMPV , LSVC, MOD PAH, GOOD BIVENTRICULAR FUNCTION, SR, NC	SV ASD CLOSURE +PAPVC REROUTING BY DOUBLE PATCH REPAIR (TPP, BPP)	DR. BINEESH K.R.
242	SHOUKATH M.K.	54	M	02/Feb/2015	CAD/TVD/GDLV/SR/HTN/DLP/DM	CABGX5 GRAFTS,LIMA-LAD,RSVG-D1,EARLY PDA,OM1,OM2	DR. JAYAKUMAR K
243	RAMACHANDRAN NAIR G.	66	M	03/Feb/2015	CAD/TVD/OLD MI/GDLV/SR/HTN/DLP/BRONCHIAL ASTHMA	CABGX 5 GRAFTS,LIMA-LAD,RSVG-OM1,TERM OM,RPDA,RPLB	DR. JAYAKUMAR K
244	SARA T.S.	55	F	03/Feb/2015	SEV CAL AS, GDLV SR DM DLP	AVR # 19 SJR	DR. BINEESH K.R.
245	ANNA MARY.F	52	F	04/Feb/2015	CAD/TVD/LMCA/GDLV/SR/HTN/DM/DLP,LT HEMEPARESIS.	CABGX 6 GRAFTS LIMA-LAD,RSVG-RI,D1,OM2,TERMOM,PDA	DR. JAYAKUMAR K
246	SABARI V.	22	M	05/Feb/2015	RHD, SEV MS, SEV MR, SEV AR, MILD LVD, SR, NC	DVR (MVE # 27CHVP + AVR #23 CHVP)	DR. VARGHESE T.PANICKER
247	RADHAMMA. S	58	F	05/Feb/2015	CAD,TVD.FAIR LV, MILD MR, SR, DM,HTN	CABG X 4 GRAFTS (LIMA-->LAD, RSVG--> RI, MAJ OM, PRECRUX RCA)	DR. JAYAKUMAR K
248	REMESAN R.	58	M	06/Feb/2015	CAD LMCA NSTEMI TVD GDLV DM HTN DLP	CABGX 5 GRAFTS,LIMA-LAD,RSVG-RI,MAJ DIAG,MAJ OM,PDA	DR. JAYAKUMAR K
249	PADMAKUMARAN THAMPY V.	54	M	09/Feb/2015	CAD LMCA TVD FAIR LV SR DM DLP	CABG-5 GRAFTS,LIMA-LAD,RSVG-RI,OM1,OM2,DISTAL RCA	DR. JAYAKUMAR K
250	KRISHNAN NAIR P.	69	M	10/Feb/2015	CAD TVD GDLV SR HTN BA HBSAG+	CABGX 4 GRAFTS,LIMA-LAD,RSVG-D1,INFERIOR AND SUPERIOR BRANCH OF RI	DR. JAYAKUMAR K
251	MURALI G.	49	M	11/Feb/2015	CAD, TVD, GDLV,SR, DM, DLP	CABG X 5 GRAFTS (RSVG--> MAJ DIAGONAL, OM1,OM2, RPDA)	DR. JAYAKUMAR K
252	NALINAKSHAN B.	65	M	11/Feb/2015	CAD TVD GDLV SR HTN DLP	CABGX5 GRAFTS,LIMA-LAD,RSVG-D1,OM1,PDA,LPLB	DR. JAYAKUMAR K

253	UGIN BABY	52	F	12/Feb/2015	CAD TVD S/P PTCA(LAD)GDLV DM HTN HYPOTHYROID HBSAG+	CABGX4 GRAFTS,LIMA-LAD RSVG-D1,OM3,PDA	DR. JAYAKUMAR K
254	RATHEESH.S	33	M	12/Feb/2015	ACHD, OSASD(MULTIPLE), GDLV. MILD PAH. SR	ASD CLOSURE WITH TPP	DR. BINEESH K.R.
255	SASIKUMAR B.	68	M	13/Feb/2015	CAD,TVD,LMCA,GDLV,DM,HTN,DLP,B/L PVOD (S/P PTA ON 2/1/14)	CABGX LIMA-LAD,RSVG-D1,MAJ OM,TERM OM,PDA	DR. JAYAKUMAR K
256	RAJAGOPAL R.	51	M	16/Feb/2015	CAD,LMCA,TVD,GDLV,SR,HTN,DLP	CABGX 5 GRAFTS(LIMA-LAD,RSVG-D1,RI,PDA,PLB)	DR. JAYAKUMAR K
257	MURALEEDHARAN K.	60	M	23/Feb/2015	CAD TVD OLD IWMI MOD LVD LV ANEURYSM SR DM HTN	CABGX4GR(LIMA-LAD,RSVG-D1,TERM OM,DISTAL RCA)	DR. JAYAKUMAR K
258	SAROJINI R.	70	F	24/Feb/2015	SEVERE AS MILD AR CAD SVD GDLV SR HTN	AVR#19 PM WITH POSTERIOR ROOT ENLARGEMENT WITH BOVINE PERICARDIAL PATCH+ CABGX 1 GRAFT OM2	DR. VARGHESE T.PANICKER
259	DIVAKARAN SALIM	61	M	24/Feb/2015	CAD ACS(2009) DVD GDLV SR DM HTN	CABGX5 GR(LIMA-LAD,RSVG-OM1,OM2,TERM OM PIGGY BACKED TO OM2,DIAGONAL PIGGYBACKED TO OM1)	DR. JAYAKUMAR K
260	SIVASANKARAN NAIR K	82	M	25/Feb/2015	CAD,LMCA ,DVIDM, GDLV SR DM HTN DLP,H/O TIA	OPCABGX 1GRAFT ,LIMA-LAD	DR. JAYAKUMAR K
261	NARAYANA PILLAY A.	67	M	25/Feb/2015	CAD, TVD, TRIVIAL MR ,SEV LVD ,SR ,DM,HTN, DLP, BIPOLAR DISORDER	CABGX5 GRAFTS,LIMA-LAD,RSVG-D1,OM1,OM2,PDA	DR. JAYAKUMAR K
262	ANILKUMAR A.	44	M	26/Feb/2015	CAD TVD, MILD LVD, SR, DM HTN DLP	CABGX 4 GRAFTS,LIMA-LAD RSVG-RI,OM1,DISTAL RCA	DR. JAYAKUMAR K
263	MYNUDHEEN M.	39	M	27/Feb/2015	CAD,TVD,SEV LVD,SR,DM,HTN	CABGX 5 GRAFTS,LIMA-LAD,RSVG-AM,D1,OM1,PDA	DR. JAYAKUMAR K
264	MANOHARAN P.	54	M	28/Feb/2015	MVP OF AML+PML,SEV MR,MOD PAH,SR,GDLV,H/O CVA,NC,DM	MVR#31CHVP+PARTIAL PMLP	DR. BINEESH K.R.
265	MOHAMED RAFI A.	53	M	02/Mar/2015	CAD,S/P PCI TO RCA,TVD,MILD MR,MOD LVD,SR,DM,DLP	CABG X 4 GRAFTS(LIMA--LAD, RSVG-> D1, MAJ OM, RPDA)	DR. VIVEK V. PILLAI
266	HAJA H	49	M	03/Mar/2015	CAD,TVD,ACS(2/7/14),GDLV,SR,DM	CABGX 4 GRAFTS(LIMA-->LAD, RSVG-->D1, TERMINAL OM, RPDA)	DR. VIVEK V. PILLAI
267	MINI G NAIR	49	F	04/Mar/2015	RHD,SEV AS,MOD AR,SEV MS, MOD PAH,BA,SEIZURE DIS,GDLV,NC	DVR(MV#25CHVP,AV#25CHVP)	DR. VARGHESE T.PANICKER
268	BYJU KUMAR S.	41	M	06/Mar/2015	CAD,DVD,GD,LV SRDM,HTN	CABGX 4 GRFATS LIMA-LAD,RSVG-OM2,TERM OM, RI	DR. JAYAKUMAR K
269	ASOKAN V.	68	M	09/Mar/2015	CAD,TVD,GD LV, SR HTN,DLP,DM	CABGX 6 GRAFTS,LIMA-LAD,RSVG-D1,OM2,OM3,PDA,PLB	DR. JAYAKUMAR K
270	SULOCHANA K.	62	F	09/Mar/2015	SEV CAL AS,CALCIFIC CORONARIES,PROX LAD DISEASED,GDLV,SR,DM	AVR#19PM+CABGX1 GRAFT(RSVG-LAD)	DR. VARGHESE T.PANICKER
271	JOHN A V	67	M	10/Mar/2015	CAD TVD, GD LV, SR, HTN, DM	CABGX 5 GRAFTS,LIMA-LAD,RSVG-OM1,OM2,OM3,PDA	DR. JAYAKUMAR K
272	PUSHPANGADAN B.	52	M	11/Mar/2015	CAD,TVD,GD LV,SR,HTN,DLP	CABGX7 GRAFTS,LIMA-LAD,RSVG-BOTH BRANCHES OF RI,MAJ OM,TERM OM,AM,PDA	DR. JAYAKUMAR K
273	SAROJAM T	52	F	11/Mar/2015	BAV, SEV CAL AS, MILD,AR,GD LV,SR, NC,BA	AVR#17SJM	DR. BINEESH K.R.
274	MADHAVAN K K.	58	M	12/Mar/2015	CAD,TVD,,MOD MR, SEV LVD,SR, DM,HTN, SMOKER	CABGX 5GRAFTS LIMA-LAD,RSVG-D1,MAJ OM,PDA,RI	DR. JAYAKUMAR K
275	KRISHNANKUTTY NAIR .M.	64	M	13/Mar/2015	BAV,SEV CAL AS,MILD AR,MILD LVD,SR,NC,HTN	AVR#23PM	DR. BINEESH K.R.
276	GANGADHARAN NAIR C.V.	78	M	13/Mar/2015	CAD,TVD, TVD,MOD LVD, MILD MR,SR,DM,HTN,DLP	CABGX GRAFTS ,LIMA-LAD,RSVG-D1,RI,MAJ OM,PDA	DR. JAYAKUMAR K
277	RAJENDRAN UNNITHAN R.	74	M	16/Mar/2015	CAD,TVD,SP/PTCA TO LAD, POBA TO LCX, GDLV,SR,DM,HTN,DLP,	CABGX 5 GRAFTS,LIMA-LAD,RSVG-DIAG,OM1,OM2,PDA	DR. JAYAKUMAR K

278	NASARUDEEN P.	49	M	17/Mar/2015	CAD, TVD, GDLV, SR, DM, HTN	CABGX 5 GRAFTS,LIMA-LAD,RSVG-D2,BOTH BRANCHES OF MAJ OM, PRE CRUX RCA	DR. JAYAKUMAR K
279	SIVAKUMAR M.	17	M	17/Mar/2015	SA VSD, SEV AR, GDLV, NO PAH/PS	AVR#27CHVP+DACRON PATCH CLOSURE OF SA VSD	DR. VARGHESE T.PANICKER
280	RAVEENDRAN V.	65	M	18/Mar/2015	CD,TVD,MILD MR,GDLV, HTN	CABGX 6 GRAFTS,LIMA-LAD,RSVG-D1,OM1,OM2,OM3,PDA	DR. JAYAKUMAR K
281	RAVEENDRAN M.	62	M	19/Mar/2015	CAD, TVD,GDLV, SR, DM, HTN, DLP	CADBGX 5 GRAFTS LIMA-LAD,RSVG-MEDIAL AND LATERAL BR OF RI, TERM OM, PDA	DR. JAYAKUMAR K
282	LALITHAMMA P.J.	69	F	20/Mar/2015	CAD, TVD, RECENT UA,GDLV,SR, DM, HTN	CABGX3 GRAFTS ,LIMA-LAD,RSVG-MAJ OM, PDA	DR. JAYAKUMAR K
283	RAJAN B.	63	M	23/Mar/2015	RHD,SEV CAL MS, MOD MR,FAIR LV,MOD TR,MILD AR,MOD PAH, AF,NC	MVR # 25 PM, PPMLP	DR. VIVEK V. PILLAI
284	SALAM P T.	48	M	23/Mar/2015	CAD,TVD,CSA,SP/PTCA TO LAD,RCA,POBA TO LPDA, SR, GDLV, DLP	CABG X 4 GRAFTS(LIMA-->LAD, RSVG--> OM1/OM2/RPDA) ENDARTERECTOMY OF OM2	DR. VIVEK V. PILLAI
285	RAMAN KUTTY T P.	61	M	24/Mar/2015	SEV CAL AS,CAD,DVD,MILD LVD,HTN,DLP	AVR # 21 PM + CABG (RSVG-LAD,D1,OM1)	DR. VIVEK V. PILLAI
286	IRFAN MOHAMMED THAHA	10	M	25/Mar/2015	ACHD, OS ASD, NO PAH, SR	TPP CLOSURE OF ASD	DR. BINEESH K.R.
287	VIJAYAN PILLAI	57	M	25/Mar/2015	CAD, TVD, GD LV, SR, HTN	CABG X 4 GRAFTS(LIMA-->LAD, RSVG--> DIST LAD, OM, RPDA)	DR. VIVEK V. PILLAI
288	MANI.D.	46	M	26/Mar/2015	SEV CALCIFIC AS, MOD-SEV AR, MILD MR, SR, GD LV, NC	AVR (# 21 CHVP)	DR. VARGHESE T.PANICKER
289	KRISHNAN N.	59	M	27/Mar/2015	HOCM, SAM, SEV LVOTO, MOD MR, GDLV, SR, NC, DM	SEPTAL MYECTOMY + MVR # 23 CHVP	DR. VIVEK V. PILLAI
290	THASIAH S.	66	M	27/Mar/2015	SEV CAL AS, MOD AR,MILD MR, LVH, GDLV, SR,CAD,SVD	AVR # 23 PM, CABGX 1 GRAFT(RSVG-->RPDA)	DR. VARGHESE T.PANICKER
291	GOPALAKRISHNAN NAIR E.R.	64	M	30/Mar/2015	CAD,TVD,IWMI, GDLV, SR, DM,HTN,DLP	CABG X 5 GRAFTS (LIMA-LAD , RSVG - D1 ,RI , TERM OM , PDA)	DR. JAYAKUMAR K
292	PODIYAN L.	62	M	31/Mar/2015	SEV. CAL. AS,MILD AR,GDLV,SR	AVR # 19 PM	DR. BINEESH K.R.
293	SUKESANANDANAN UNNITHAN C.	66	M	31/Mar/2015	CAD,TVD,GDLV,SR,DM,HTN	CABGX 7 GRAFTS,LIMA-LAD,RSVG-D1,D3,OM1,TERM OM,PDA,PLB	DR. JAYAKUMAR K
294	KRISHNA PILLAI P.	71	M	01/Apr/2015	CAD,TVD,MILD MR,GDLV,SR	CABGX 3 GRAFT(LIMA-LAD,RSVG-D1,OM1)	DR. JAYAKUMAR K
295	PREETHA KUMARI I.	35	F	06/Apr/2015	RHD,SEV MS, MOD-SEV MR, MILD AR, MILD LVD, MOD PAH, AF,NC	MVR # 23 CHVP + PMLP	DR. VARGHESE T.PANICKER
296	JAGANNATHAN C.	68	M	06/Apr/2015	CAD, TVD, GD LV, SR,DM,HTN,DLP	CABG X 6 GRAFTS (LIMA-LAD, RSVG - DISTAL LAD , DIAG 1 ,RAMUS ,OM2 , PLB)	DR. JAYAKUMAR K
297	VINOD CHANDRAN	39	M	07/Apr/2015	CAD,TVD,GD LV,SR,DM,HTN,DLP,SMOKER	CABG X 5 GRAFTS(LIMA-LAD,RA-OM1,RSVG-D1,TERM OM &RPDA)	DR. JAYAKUMAR K
298	AMAL NATH G.	25	M	07/Apr/2015	LARGE OS ASD, MVP OF AML, SEV PAH, GD LV.SR	TPP CLOSURE OF OS ASD	DR. BINEESH K.R.
299	RAJENDRA BABU K.	53	M	08/Apr/2015	CAD,TVD,MILD MR, SEV LVD, SR, DM, DLP	CABGX 5 GRAFTS,LIMA-LAD,RSVG-D1,BOTH BR OF RI,RCA	DR. JAYAKUMAR K
300	SASIDHARAN.C.	64	M	09/Apr/2015	CAD,TVD,GD LV,S/P PTCA, SR	CABG X 3 GRAFTS(LIMA-LAD,RSVG-DISTAL RCA,LPLB)	DR. JAYAKUMAR K
301	KALAVATHY M.	37	F	09/Apr/2015	RHD,SEV MS, MOD MR, MOD AS,MOD AR,GD LV, SR	DVR (MVR # 23 CHVP WITH MINIMAL PMLP + AVR # 17 CHVP)	DR. VARGHESE T.PANICKER
302	PRASANNAN M.	55	M	10/Apr/2015	CAD,LMCA+TVD,FAIR LV,DM,SMOKER, RECENT MI	CABGX4GR(LIMA-LAD,RSVG-C)	DR. JAYAKUMAR K
30304	JOSH KUMAR	50	M	20/Apr/2015	CAD,TVD,GDLV,LCX FROM RCA,SR	CABG X 6 GRAFTS (LIMA-LAD,RSVG-	DR. JAYAKUMAR K

3						BOTH BRANCH OF MAJ DIAGONAL,DIAG 1,PLB,DISTAL PLB)(DISTAL PLB PIGGY BACK TO PLB)	
305	HARIDAS P.	67	M	21/Apr/2015	CAD,DVD,GD LV, REC ACS, SR, DM, GLAUCOMA	CABG X 5 GRAFTS(LIMA-LAD,RSVG-MAJ DIAGONAL,RI,PDA,PLB)	DR. JAYAKUMAR K
306	DHARMAJAN.B.	55	M	22/Apr/2015	CAD,TVD,REC ACS, S/P PTCA-LAD (2004), SR, FAIR LV FUNCTUION, DM, HTN	CABG X 5 GRAFTS (LIMA-LAD , RSVG - DISTAL LAD,DIAG 2,RAMUS,PDA)(DISTAL LAD PIGGY BACK TO DIAG 2)	DR. JAYAKUMAR K
307	ROYCHEN M C.	43	M	22/Apr/2015	SEV CALC AS, CONC LVH, GD LV, SR, NC	AVR # 23 SJM	DR. BINEESH K.R.
308	SUGUNAKUMAR J	45	M	23/Apr/2015	CAD,TVD,OLD MI, SEV LVD,HTN,DM,DLP,SR	CABG X4 GRAFTS(LIMA-LAD,RSVG - BOTH BRANCHES OF RI,RPLB) +LV PLICATION	DR. JAYAKUMAR K
309	DEVAMMA P.	60	F	24/Apr/2015	SEV CALCIFIC AS,GDLV,SR,NC,DM,HTN,DLP	AVR# 19 PM	DR. BINEESH K.R.
310	BABU S.	53	M	27/Apr/2015	CAD,TVD,GDLV,SR,HTN,DLP.	CABG X 4 GRAFTS(LIMA-LAD,RSG-DISTAL LAD,OM I,PDA)	DR. VIVEK V. PILLAI
311	SARASWATHY AMMA P.	65	F	28/Apr/2015	CAD,TVD,FAIR LV,SR,HTN,DM	CABG X 4 GRAFTS (LIMA- MAJ DIAG , RSVG - DISTAL LAD,MAJ OM,RPDA)	DR. VIVEK V. PILLAI
312	JAYAKUMAR K.	53	M	29/Apr/2015	CAD,TVD,GDLV,SR,HTN	CABG X 4 GRAFTS(LIMA-LAD,RSVG-D2,OM2,RPDA)	DR. VIVEK V. PILLAI
313	BINTU SCARIA	45	M	30/Apr/2015	BAV,SEV AR,MILD MR,MILD PAH,MILD LVD,SR,NC	AVR # 25 CHVP	DR. BINEESH K. R.
314	SATHYABHAMA AMMA G.	67	F	31/Apr/2015	CAD TVD GDLV SR DM DLP PVOD	CABG X 4 GRAFTS (LIMA - LAD, RSVG - MAJ D, MAJ OM, AM-PDA)	DR. VIVEK V. PILLAI
315	NAVAS H.	36	M	1/Apr/2015	CONSTRICTIVE PERICARDITIS,CAD,DVD,GDLV,NO PAH,SR	PERICARDECTOMY+OPCABG (LIMA-LAD)	DR. JAYAKUMAR K
316	JAIN BABY	65	F	2/Apr/2015	CAD,LMCA,TVD,GDLV,SR,DM,HTN,DLP	CABG X 5 GRAFTS (LIMA-LAD , RSVG - DIAG 1 , OM1 , RPDA , DISTAL RCA AT CRUX)	DR. VIVEK V. PILLAI
317	RAMAKRISHNAN M	56	M	3/Apr/2015	CAD,TVD,GDLV,SR,DM,HTN	CABGX 5 GR(LIMA-LAD,RSVG-D1,TERM OM,RPDA,AM)	DR. VIVEK V. PILLAI
318	GURUVAMMAL T.	25	F	4/Apr/2015	OSASD,GDLV,NO PAH,SR	TPP CLOSURE OF ASD	DR. BINEESH K. R.
319	THAINESMARY T	59	F	5/Apr/2015	CAD DVD SEV CAL AS GDLV SR PARTIAL APVD B/L SVC	CABGX 2 GRAFTS(RSVG-D1,LAD)+AVR#17CHVP+INTERRUPTION OF VERTICAL VEIN(LSVC)	DR. VARGHESE T.PANICKER
320	JUSTIN VIJAYAKUMAR	43	M	6/Apr/2015	RHD SEV MS, MOD MR, MOD PAH, LA CLOT, GDLV, AF, NC	# 31 CHVP MVR + LA CLOT EXTRACTION + LAA EXCLUSION + PARTIAL PMLP	DR. BINEESH K. R.
321	FAISAL K.	30	M	7/Apr/2015	ACHD, MOD MR (MVP OF PML (P2)), OS ASD, GDLV, NO PAH, SR, NC	MV REPAIR (TRIANGULAR RESECTION AND #27 DURAN ANOCORE RING ANNULOPLASY) + DIRECT CLOSURE OF ASD	DR. BINEESH K. R.
322	RAMADAS T. R.	56	M	8/Apr/2015	CAD TVD RECENT ACS GDLV SR DM HTN	CABGX4GR(LIMA-LAD,RSVG-RAMUS,TERM OM,RPDA)	DR. JAYAKUMAR K
323	ILAYARAJA K.	8	M	9/Apr/2015	RHD SEV MR FLAIL AML GDLV SR	MVREPAIR WITH #27 DURAN ANCOR ANUULOPLASTY RING+NEO CHORDAE RECONSTRUCTION	DR. VARGHESE T.PANICKER
324	SASIDHARAN NAIR.P.	61	M	10/Apr/2015	CAD TVD P/PTCA TO RCA, GDLV, SR DM, HTN, L WALLEBERGERS SYNDROME	CABG X 6 GRAFTS (LIMA - LAD, RSVG - D1, D2, OM, PDA, PLB)	DR. JAYAKUMAR K
325	ABDUL RASHEED A.	63	M	11/Apr/2015	CAD TVD GDLV, DLP, HBSAG +VE	CABG X 4GRAFTS: (LIMA - LAD, RSVG - RAMUS, D1, PDA)	DR. JAYAKUMAR K

326	PANDARAM K.	24	M	12/Apr/2015	RHD SEV MR ,MILD PAH, FAIR LV,AF, HBSAG+	MVR#25/33 ONX+TOTAL CHORDAL PRESERVATION	DR. VIVEK V. PILLAI
327	HAMSAKOYA A.	48	M	13/Apr/2015	CAD TVD GDLV SR DM HTN DLP	CABG X 5 GRAFTS (LIMA-LAD ,RSVG-DIAG 1,OM1,OM2,AM)	DR. JAYAKUMAR K
328	VASUDEVAN B.	66	M	14/Apr/2015	CAD TVDN OLD IWMI GDLV SR DLP HTN	CABG X 4GRAFTS: (LIMA - LAD, RSVG - RAMUS, D1, PDA)	DR. JAYAKUMAR K
329	SANTHAKUMARI D.	69	F	15/Apr/2015	CAD,LMCA,TVD,GDLV,SR,DM,HTN,DLP	CABGX4GRAFTS,LIMA-LAD,RSVG-MAJ OM,PDA,PLB	DR. JAYAKUMAR K
330	RAJASEKHARAN NAIR K.	62	M	15/Apr/2015	CAD,OLD NSTEMI,P/PTC-LAD/OM1/LCX,MILD LVD,SR	CABGX5 GR(LIMA-LAD,RSVG-D1,OM1,TERM OM,RPDA	DR. JAYAKUMAR K
331	SAMUTHRAM S.	45	M	16/Apr/2015	RHD,SEV MS,MILD MR,MILD MR,MILD AR, MILD PAH,AF,GDLV	MVR#25CHVP+PMLP	DR. BINEESH K. R.
332	SANKARAN KUTTY K.	62	M	17/Apr/2015	CAD,DVD,MILD LVD, SR,HTN,DLP	CABG X 5 GRAFTS (LIMA-LAD , RSVG - DISTAL LAD , D1 , D2 , RPDA)	DR. JAYAKUMAR K
333	SAJEEV U.	39	M	19/Apr/2015	CAD, DVD, P/PTCA - RCA, GDLV, SR DM, HTN	CABG	DR. JAYAKUMAR K
334	ROSHAN K	18	M	20/Apr/2015	RHD SEV AR MOD MR MILD PAH GDLV DILATED LV SR	AVR # 23 CHVP + MV REPAIR (A3P3 COMMISUROPLASTY WITH # 29 DURAN ANCORE INCOMPLETE RING REPAIR)	DR. VARGHESE T.PANICKER
335	SREEKUMAR P.U.	51	M	21/Apr/2015	CAD,TVD,SEV LVD,SR,DLP,HTN	CABGX6GRAFTS,LIMA-LADRSVG-,D1,D3,MAJ OM,TERM OM,PDA	DR. JAYAKUMAR K
336	SULFATHUL NIZA A.S.	21	F	22Apr/2015	ACHD, OSASD, MILD PAH, SR	TPP CLOSURE OF OSASD.	DR. VIVEK V. PILLAI
337	BISHNU CHARAN SADANGI	68	M	23/Apr/2015	CAD,TVD,LMCA ,GDLV,SR ,DM HTN, DLP	CABGX5 GRAFTS,LIMA-LAD,RSVG-D1,RI,PDA,PLB	DR. JAYAKUMAR K
338	SOBHANA S.	56	F	24/Apr/2015	BAV SEV AR, SEV MR, MOD MS, SEV TR, MOD PAH, FAIR LV, SR, NC, DM	AVR # 21 CHVP + MV RING ANNULOPLASTY WITH # 25 TAILOR RING	DR. VARGHESE T.PANICKER
339	JOHN A.S	67	M	25/Apr/2015	CAD,TVD,GDLV,SR,DM,DLP	CABGX3 GRAFTS,LIMA-LAD,RSVG-MAJ OM,PRE CRUX RCA	DR. JAYAKUMAR K
340	VINAYAK R.	20	M	26/Apr/2015	RHD,SEV AR,MOD MR,FAIR LV,SR	AVR#23 ON-X+MV REPAIR #29 DURAN ANCOR RING	DR. VARGHESE T.PANICKER
341	THAMPY G GEORGE	53	M	29/Apr/2015	CAD, TVD, GDLV, SR, DLP, HTN.	CABG X 6 GRAFTS (LIMA -LAD, RSVG - D1, OM1, OM2, AM, RPDA)	DR. JAYAKUMAR K
342	MARIYAM BEEVI	58	F	01/Jun/2015	CAD, LMCA, TVD, GDLV, SR, DM, HTN, DLP, OA B/L KNEE	CABG X 4 GRAFTS (LIMA- LAD, RSVG - D1, OM2, RPDA)	DR. JAYAKUMAR K
343	MUTHU RAMAN R.	45	M	01/Jun/2015	RHD SEV MR S/P FAILED BMV (FOR SEV CAL MS) MOD PAH, GDLV SR, NC	MVR # 23 CHVP + PMLP	DR. BINEESH K. R.
344	SHAHIDA	43	F	02/Jun/2015	RHD,SEVMR,MODAR,MILD PAH,FAIR LV,SR,NC	DVR (MVR # 23 CHVP +PMLP , AVR # 19 CHVP)	DR. VARGHESE T.PANICKER
345	RAJAYYAN N	69	M	02/Jun/2015	CAD/TVD/P/PCI-RCA,GDLV/SR/DM/HTN	CABG X 6 GRAFTS(LIMA-->LAD, RSVG-->D1,OM2,RPDA,RPLB) & D2 PIGGY BACKED TO OM2	DR. JAYAKUMAR K
346	SANTHA V.	61	F	03/Jun/2015	RHD,SEV AS,MILD AR,P/CMV, MILD RE MS,FAIR LV,SR,NC,DM,HTN,CKD	AVR #1 PM	DR. VARGHESE T.PANICKER
347	SREEKUMARAN NAIR K.	57	M	03/Jun/2015	CAD,TVD,FAIR LV,SR,DM,HTN,BA	CABG X 4 GRAFTS(LIMA-->LAD, RSVG-->D1, TERM OM, MAJ OM, RPDA)	DR. JAYAKUMAR K
348	MUHAMMED MUSALIAR K.	60	M	04/Jun/2015	ASC.AO ANEURYSM,P/AVR(31SJM),SEV AR,MILD LVD,SR	REDOSTERNOTOMY+ SUPRACORONARY AORTOPLASTY WITH 30 # ALBOGRAFT	DR. JAYAKUMAR K
349	VIJAYA KUMARI.V.	52	F	05/Jun/2015	P/ASD CLOSURE WITH STERNAL SINUS	STERNAL WIRE REMOVAL	DR. BINEESH K. R.
350	LAKSHMANAN S.	55	M	05/Jun/2015	CAD,TVD,OLD AWMI,GDLV,SR,DLP	CABGX3 GRAFTS,LIMA-LAD,RSVG-	DR. JAYAKUMAR K

						D1,MAJ OM	
351	VASUDEVAN B.	66	M	06/Jun/2015	CAD,S/P CABG WITH DEEP SSI	STERNAL REWIRING	DR. BINEESH K. R.
352	SUBBIAH S.	67	M	08/Jun/2015	CAD TVD MILD LVD, MOD MR, MOD PAH, LV APICAL ANEURYSM, SR, DM, HTN.	CABG X 4 GRAFTS (LIMA - LAD, RSVG - D1, OM1, PDA) + LV APICAL ANEURYSM PLICATION	DR. VIVEK V. PILLAI
353	BHASKARAN NAIR R	61	M	08/Jun/2015	BAV, SEV CAL AS,MOD AR,GDLV,NC,SR	AVR#21 PM	DR. BINEESH K. R.
354	MATHEW LOUIS	63	M	09/Jun/2015	BAV, CAL AO VALVE, SEV AS,MILD AR, ,GDLV,SR,DM,HTN,DLP,NC	AVR # 21 PM	DR. BINEESH K. R.
355	LEONALBERT A.	59	M	09/Jun/2015	CAD,TVD,GDLV,SR,HTN,DLP	CABG X 5 GRAFTS (LIMA-LAD ,RSVG - DISTAL LAD , DIAG 1 , RAMUS , RPDA)	DR. VIVEK V. PILLAI
356	ARIFA BEEVI S.	53	F	10/Jun/2015	CAD,TVD,PCI-LAD,MILD MR,GDLV,SR,DM,HTN,DLP	CAVBG X 5 GRAFTS (LIMA-LAD , RSVG -D1 , RAMUS , OM ,RPLB)	DR. VIVEK V. PILLAI
357	SWAPNA JOY	34	F	10/Jun/2015	RHD,SEV MS,MOD MR,SEV AS WITH SMALL AORTIC ANNULUS,MOD AR,GDLV,SR	DVR (MVR # 23 CHVP + AVR # 19 CHVP) + KONO PROCEDURE	DR. VARGHESE T.PANICKER
358	SAIDU KUNJU J.	65	M	11/Jun/2015	CAD,DVD,MILD LVD,SR,HTN,DM,HCV +VE	CABG X 4 GRAFTS(LIMA-->LAD, RSVG-->DIST. LAD, D1, OM2)	DR. VIVEK V. PILLAI
359	ALEYAMMA E.J.	59	F	12/Jun/2015	ACHD, AVCD OPASD, ADDITIONAL OS ASD & MOD MR, MOD TR, MILD PAH, CHB GDLV NC	BPP CLOSURE OF OPASD, DIRECT CLOSURE OF OSASD, BICUSPIDISATION OF RT. AV VALVE, LT. AV VALVE POSTERIOR ANNULOPLASTY# 31 TAYLOR RING	DR. VIVEK V. PILLAI
360	MURUGAN G.	47	M	12/Jun/2015	RHD MVP (AMPL) SEV MR MOD LVD AF NC	MVR # 31 MEDTRONIC WITH TOTAL CHORDAL PRESERVATION(MIKIE'S)	DR. BINEESH K. R.
361	CHITHIRAVEL S.	50	M	15/Jun/2015	ACHD OSASD MOD MR MILD PAH GDLV AF NC	TPP CLOSURE OF ASD + MV REPAIR (TRIANGULAR RESECTION OF P2 SEGMENT WITH # 31 DURAN ANCORE INCOMPLETE RING ANNULOPLASTY)	DR. VARGHESE T.PANICKER
362	RAJENDRAN.K.	45	M	15/Jun/2015	CAD TVD GDLV SR DM DLP	CABG X 3 GRAFTS (LIMA-LAD , RSVG-DIAGONAL BR.,MAJ OM)	DR. JAYAKUMAR K
363	SENGAMALAKANNAN M.	39	M	16/Jun/2015	RHD SEV AS, SEV AR, MOD MR, MILD MS, MILD PAH, SR, NC	DVR (MVR # 25 CHVP, AVR # 21 CHVP)	DR. VARGHESE T.PANICKER
364	REGHUNATHAN N.	57	M	16/Jun/2015	CAD TVD CSA GDLV SR DM	CABG X 5 GRAFTS(LIMA-->LAD, RSVG-->D1,MAJ OM, RPDA,RPLB)	DR. JAYAKUMAR K
365	VASANTHAKUMARIAMM A L	51	F	17/Jun/2015	RHD SEV CAL MS MOD MR SEV PAH AF NC HBSAG+	MVR#25 CHVP+PARTIAL PRESERVATION OF PML	DR. VARGHESE T.PANICKER
366	RUGMINI K.	41	F	18/Jun/2015	RHD SEV MR MOD MS MOD TR,MILD-MOD PAH GDLV AF,NC	MVR#29CHVP	DR. BINEESH K. R.
367	PRASANNA N.	61	F	19/Jun/2015	RHD,SEV AS,MOD AR,MOD MR. GDLV,SR,NC	AVR # 21 PM	DR. BINEESH K. R.
368	JAICY RAJU	24	F	22/Jun/2015	ACHD, SV ASD, PAPVC OF RUPV, GDLV, SR, BA	REROUTING OF PAPVC TO RA VIA ASD + SVC RA JUNCTION AUGMENTATION + PFO CLOSURE	DR. BINEESH K. R.
369	RAVEENDRAN K.	61	M	22/Jun/2015	CAD TVD, GDLV, SR, DM, HTN, DLP,	CABG X 4 GRAFTS (LIMA - D2, RSVG - LAD, PDA, PLB)	DR. VIVEK V. PILLAI
370	SUHARA C.K.	44	F	23/Jun/2015	.RHD,P/BMV,SEV RE MS,MOD-SEV MR,OSASD,GDLV,SEV PAH,SR,NC	MVR # 25 CHVP + PARTIAL PMLP +DC OF ASD	DR. VARGHESE T.PANICKER
371	MOHANAN ASARI N.	56	M	23/Jun/2015	CAD DVD RHD SEV CAL MS, MOD PAH, GDLV, LA CLOT, AF, COPD	MVR # 27 CHVP + PMLP + CABG X 2 GRAFTS (RSVG - OM1, PDA) + LA CLOT EXTRACTION	DR. VIVEK V. PILLAI
372	HAMEED HUSSAIN S.	75	M	24/Jun/2015	CAD,LMCA,TVD,RT ICA STENOSIS,GDLV,SR,HTN,H/O STROKE, CKD.	RT,ICA CEA, CABG X5 GRAFTS(LIMA-->LAD, RSVG-->OM1, OM2, OM3, RPDA)	DR. JAYAKUMAR K
373	MOHANAN NAIR C.	59	M	25/Jun/2015	CAD TVD GDLV SR HTN	CABG X 4 GRAFTS (LIMA-LAD , RSVG - DIAGONAL 1 , RI , PROXIMAL RCA)	DR. JAYAKUMAR K

374	DEVADAS N K.	63	M	26/Jun/2015	ACHD, SVASD, PAPVC OF RUPV, MOD MR, SEV TR, AF	MV RING ANNULOPLASTY # 25 (P2 TRIANGULAR RESECTION)+ TV RING ANNULOPLASTY # 32 + PAPVC REROUTING + ASD CLOSURE(DOUBLE PATCH REPAIR)	DR. VARGHESE T.PANICKER
375	ABDUL SALAM E.	63	M	26/Jun/2015	CAD TVD GDLV SR DM HTN DLP	CABG X 4 GRAFTS (LIMA - LAD, RSVG - D1, MAJ OM, RPLB)	DR. JAYAKUMAR K
376	PRIYA P.K.	26	F	29/Jun/2015	RHD SEV MSMOD AS MOD PAH GDLV SR NC	DVR,MV#27CHVP,(PMLP), AV#19CHVP	DR. VARGHESE T.PANICKER
377	PANICKER P.R.M.	72	M	29/Jun/2015	CAD DVD GDLV SR HTN DLP HYPOTHYROIDISM	CABGX 3 GRAFTS,LIMA-LAD,RSVG-AM,MAJ OM	DR. JAYAKUMAR K
378	SREEKANDAN NAIR K.	61	M	30/Jun/2015	CAD,LMCA,TVD,GDLV,SR,DLP,HTN	CABGX6 GRAFTS LIMA-LAD,RSVG-D1,MAJ OM,PLB,DISTAL RCA,DISTAL LAD,+RCA ENDARTECTOMY	DR. JAYAKUMAR K
379	RAMESAN P.V.	55	M	01/Jul/2015	CAD LMCA ,TVD,GD LV, SR, HTN, DLP,DM	CABGX 5 GRAFTS LIMA-LAD,RSVG-D1,D2,MAJ OM,LPDA	DR. JAYAKUMAR K
380	KISHORE KUMAR T.	41	M	01/Jul/2015	RHD P/CMV (2000) RE SEV MS, MOD MR,MOD TR,MILD-MOD PAH,GDLV,PAROXYSMAL AF NC	MVR#25CHVP+PMLP	DR. BINEESH K. R.
381	JAYANTHAKUMAR SHETTY K.	53	M	02/Jul/2015	CAD TVD GDLV SR DM,HTN,DLP	CABGX 5 GRAFTS LIMA-LAD,RSVG-D1,D2,MAJ OM,DISTAL RCA	DR. JAYAKUMAR K
382	ASUMABEEVI A.	55	F	02/Jul/2015	MVP OF PML(P2 PROLAPSE) SEV MR MOD PAH GDLV SR NC	MV REPAIR(#ANNULOPLASTY #25 TAILOR RING+P2 TRIANGULAR RESECTION)	DR. VARGHESE T.PANICKER
383	ABHIJITH A.	11	M	06/Jul/2015	PA,SA VSD,CONFLUENT PA,S/P BDG WITH CONFLUENT PLASTY,SR	ASD,VSD CLOSURE + RV-PA CONDUIT (#23 HOMOPGRAFT)	DR. BAIJU S.DHARAN
384	B/O SHABNA	0	F	07/Jul/2015	RT. HETEROTAXY, SA,LC,TGAS LIKE DORV, SV-RV MORPHOLOGY, UNBALANCED COMPLETE AVCD,MOD PS, SUPRACARDIAC TAPVC,SR	PRIMARY SUTURELESS REPAIR OF TAPVC, BDG, PARTIAL MPA INTERRUPTION, STENTED STERNUM	DR. THOMAS MATHEW
385	HUSNA K.V.	1	F	08/Jul/2015	ACHD,MULTI APICAL VSD,LA/LV DILATED, SEV HYPERKINETIC PAH,SR	BPP CLOSURE OF VSD	DR. BAIJU S.DHARAN
386	ADWAITH A	0	M	09/Jul/2015	S/P RMBTS FOR WITH BLEEDING, SAVSD,PA,PDA STENT INSITU,NON CONFLUENT PA,LP A ORIGIN STENOSIS	REVISION OF PROXIMAL ANASTAMOSIS	DR. THOMAS MATHEW
387	FATHIMA SANHA	1	F	10/Jul/2015	ACHD, INFLOW VSD,SEV PAH,CLEFT AML MILD MR,MOD TR,LA/LV DILATED,GD LV, SR	VSD CLOSURE+MITRAL CLEFT REPAIR	DR. SABARINATH MENON
388	B/O LEKHA	0	F	13/Jul/2015	RPA FROM ASC AORTA PDA SEV PAH	RPA REIMPLANTATION TO PA+PDA INTERRUPTION+TV REPAIR+DIRECT CLOSURE OF PFO WITH FENESTRATION	DR. BAIJU S.DHARAN
389	FAHMIDHA FARHATH K.	0	F	14/Jul/2015	CCHD TA TYPE 2, MILD TV STENOSIS,MILD TVR, SEV PAH GDLV SR	TRUNCUS REPAIR(RV-PA CONDUIT)# BICUSPIDIZED PULMONARY HOMOGRAFT	DR. BAIJU S.DHARAN
390	B/O NISHA	0	M	15/Jul/2015	SAVSD,ASD,HYPERKINETIC PAH,MOD TR,SR	TPP CLOSURE OF VSD	DR. THOMAS MATHEW
391	NEHA B	3	F	16/Jul/2015	MA, DORV, SA, CA, SV(RV MORPHOLOGY), SP/ PA BANDING(2012), LSVC, RT. AORTIC ARCH	B/L BDG	DR. BAIJU S.DHARAN
392	MUHAMMED RAIHAN	0	M	17/Jul/2015	PARTIALLY OBST.SC TAPVC,SEV PAH,GDLV,SR	TAPVC REPAIR	DR. SABARINATH MENON
393	PRAJISHA PRASAD C	2	F	20/Jul/2015	TOF,GOOD PA, NO PAH, GDLV,NC,SR	ICR(TAP+MONOCUSP RECONSTRUCTION)	DR. THOMAS MATHEW
394	JOSHWIN J JOSE	4	M	20/Jul/2015	ACHD SPVSD NO PAH MILD AR	VSD CLOSURE(DC)	DR. SABARINATH MENON
395	MEGHA MOHAN	7	F	21/Jul/2015	TOF,CONFLUENT PA,GDLV,PDA, NC,SR	ICR WITH RVOT PATCH & PDA INTERRUPTION	DR. THOMAS MATHEW
396	ANUSHYA.M.	2	F	22/Jul/2015	TOF,CONFLUENT PA,GDLV,PDA, NC,SR	ICR	DR. SABARINATH

							MENON
397	NEHA A S	2	F	23/Jul/2015	ACHD SPVSD NO PAH	DC OF VSD	DR. BAIJU S.DHARAN
398	AMIN SAJAL K.	3	M	23/Jul/2015	SAVSD INFUNDIBULAR PS . CONFLUENT PA, LAD CROSSING RVOT, SR GDLV NC	ICR	DR. THOMAS MATHEW
399	NIRANJANA P.	1	F	24/Jul/2015	TOF VALVULAR PS CONFLUENT PA NC SR	ICR(TAP+MONOCUSP RECONSTRUCTION)	DR. SABARINATH MENON
400	B/O PUSHPA P.	0	F	27/Jul/2015	TA LARGE ASD VSD SEV PAH SR	PA BANDING(#23 BAND)	DR. SABARINATH MENON
401	AYAAZ AHAMED P.K.	0	M	27/Jul/2015	P/PNEUMOCOCCAL IE SEV MR CCF SEV PAH	MV REPAIR(ANNULOPLASTY)	DR. THOMAS MATHEW
402	SUMAN RAJA.R.R.	2	M	28/Jul/2015	DORV,NONCOMMITTED VSD,SEV PAH,MILD LVOTO,SR	PA BANDING(#30 MM PTFE)	DR. BAIJU S.DHARAN
403	SAIRA JOSEPH	5	F	29/Jul/2015	ACHD OSASD GDLV SR	ASD CLOSURE BY MINI STERNOTOMY	DR. THOMAS MATHEW
404	B/O SUMIJA N.	0	F	30/Jul/2015	DTGA,IVS,PDA,P/BAS,2LCXR, GDLV, SR	ASO +ASD CLOSURE	DR. BAIJU S.DHARAN
405	KALAI SELVI S.	9	F	31/Jul/2015	TA,VSD,SEV INFUND PS, ASD,P/BDG,GOOD PA,DTGA, GDLV,SR	TCPC WITH 4 MM FENESTRATION	DR. THOMAS MATHEW
406	ANSHAD M	13	M	03/Aug/2015	ACHD SVASD PAPVC NO PAH SR	TPP CLOSURE OF ASD-PAPVC REROUTING USING DOUBLE PATCH TECHNIQUE	DR. SABARINATH MENON
407	B/O HASEENA	1	F	05/Aug/2015	CCHD TOF GOOD PA NC GDLV SR	ICR+TRANSANNULAR PATCH WITH MONOCUSP REPAIR	DR. BAIJU S.DHARAN
408	SHAMNA SHERIN	2	F	10/Aug/2015	DOUBLY COMMITTED VSD,SEV PAH, TRIVIAL AR, LA/LV VOL OVERLOAD	VSD CLOSURE WITH GORTX PATCH	DR. SABARINATH MENON
409	NAVAMI V.	4	F	11/Aug/2015	OSASD, IAS ANEURYSM, NO PAH,GDLV,SR	ASD CLOSURE (MINISTERNOTOMY)	DR. SABARINATH MENON
410	VAIGHA BIJU	3	F	12/Aug/2015	CCHD, LONG SEGMENT PA, SAVSD, ABBERRANT RT SCA, MAPCA'S, POOR PA ANATOMY, GDLV, SR	MODIFIED MELBOURNE SHUNT WITH 4 MM PTFE GRAFT + B/L PA AUGMENTATION PLASTY + UNIFOCALISATION OF MAPCA FROM ABBERRANT RT SCA + REDO MODIFIED MELBOURNE SHUNT WITH 5 MM PTFE GRAFT	DR. THOMAS MATHEW
411	ANANJAY T.	0	M	13/Aug/2015	DTGA, VSD, HYPOPLASTIC ARCH, PAH, ASD, GDLV, SR	ASO+ARCH REPAIR +VSD CLOSURE	DR. BAIJU S.DHARAN
412	MUHAMMAD SHAHZAD VILLAN	0	M	14/Aug/2015	ACHD, SP VSD, HYPOLASTIC AORTIC ARCH, PFO, SEV PAH, MILD MR, GDLV, SR	AORTIC ARCH ADVANCEMENT WITH SP VSD CLOSURE. (PFO OPEN)	DR. SABARINATH MENON
413	KAJOL V	0	F	17/Aug/2015	OBSTRUCTED IC TAPVC SEV PAH, PDA, SR	PRIMARY SUTURELESS REPAIR OF IC TAPVC+ASD CLOSURE WITH 2 MM FENESTRATION	DR. BAIJU S.DHARAN
414	JABIR.T.P	24	M	18/Aug/2015	PA VSD CONFLUENT PAP/ CLASSICAL BTS(95) P/MAPCA COILING	ICR WITH (RV -PA CONDUIT)#23 AORTIC HOMOGRAFT	DR. SABARINATH MENON
415	THEJAS M.D.	1	M	19/Aug/2015	TRANSIENT AVCD MOD LEFT AVVR, MOD RT. AVVR, SEVERE PAH, GDBV FUNCTION, SR	AVCD REPAIR, REPAIR OF CLEFT AML, TV REPAIR, WARDENS PROCEDURE WITH 4MM FENESTRATED ASD PATCH	DR. SABARINATH MENON
416	REJITHA.P.S.	27	F	20/Aug/2015	TOF P/CLASSICAL BTS(91) P/ICR(96) IE (PSEUDOMONAS) CHB P/TPI	EPICARDIAL PPI PLACEMENT	DR. THOMAS MATHEW
417	MOHAMMED SHAYAN T.	2	M	21/Aug/2015	ACHD SVASD OVERRIDING RUPV B/L SVC SR NC	ASD CLOSURE WITH DOUBLE PATCH REPAIR	DR. SUJITH D.S.
418	B/O BUSHRA	0	M	24/Aug/2015	DTGA, IVS, SP/BAS, PRESERVED LV, ILCX2R, SR	ASO+ASD CLOSURE	DR. SABARINATH MENON
419	FAHEEMA K.A.	4	F	25/Aug/2015	TOF OSASD (PENTOLOGY) ADDTIOINAL MUSCULAR VSD LARGE PDA CONFLUENT PA SR NC	ICR (VSD CLOSURE + INFUNDIBULAR RESECTION) + TAP WITH MONOCUSP	DR. SABARINATH MENON

						RECONSTRUCTION + DC OF ADDITIONAL MUSCULAR VSD + ASD MADE RESTRICTIVE + DA INTERRUPTION	
420	MUHAMMED ADHIL	5	M	26/Aug/2015	SAVSD SEV INF PS GDLV SR NC	ICR(INFUNDIBULAR RESECTION+GORTX PATCH VSD CLOSURE)	DR. BAIJU S.DHARAN
421	B/O AFRIN	0	M	27/Aug/2015	TOF, DIGEORGE SYNDROME,MAPCA,GDBIV FUNCTIONS,SR	MODIFIED MELBOURNE SHUNT(PTFE#3.5MM)	DR. SABARINATH MENON
422	DIYA LAKSHMI	0	F	31/Aug/2015	SC TAPVC,LARGE ASD, PAH,SR	PRIMARY SUTURELESS REPAIR OF SC TAPVC	DR. SABARINATH MENON
423	KRISHNA PATHY K.	37	F	01/Sep/2015	RHD,SEV MS,SEV AS,MILD MR,MILD AR,MILD TR,PAROX AF	DVR(MVR#23CHVP +PARTIAL PRESERVATION OF PML& AVR#19CHVP)	DR. VARGHESE T.PANICKER
424	RAJAN R.	65	M	02/Sep/2015	CAD TVD GDLV SR HTN DLP	CABGX5GR(LIMA-PROX LAD,RSVG- DISTAL LAD,OM3,MAJ DIAGONAL AND RPLB)	DR. VIVEK V. PILLAI
425	BHARGAVAN KANI K.	75	M	03/Sep/2015	SEV CAL AS MILD AR MILD LVD ,AF,NC, RT LL FILARIASIS	AVR # 23 PM	DR. VARGHESE T.PANICKER
426	JOSE J.	55	M	03/Sep/2015	CAD, TVD, MOD LVD, SR ,DM, HTN, DLP, RENAL DYSFUNCTION, SR.	CABG X 4 GRAFTS(LIMA-LAD,RSVG- MAJOR DIAGONAL,MAJOR OM,DISTAL RCA)	DR. JAYAKUMAR K
427	RAMESH SUNDAR S.	33	M	04/Sep/2015	RHD SEV MS SEV AS SEV AR GDLV SR	DVR(MVR # 25 CHVP+ AVR # 23 CHVP)	DR. VARGHESE T.PANICKER
428	ISMAILKUNJU.M	68	M	04/Sep/2015	CAD,DVD,GDL V,SR,DM,HTN	CABG X 4 GRFTS (LIMA-LAD,RSVG- MAJOR DIAGONAL,MAJOR OM,RI)	DR. JAYAKUMAR K
429	PREMALATHA S.	52	F	07/Sep/2015	CAD TVD GDLV SR HTN	CABG X 4 GRAFTS. LIMA TO LAD. RSVG TO OM1,OM2,DISTAL RCA.	DR. JAYAKUMAR K
430	ZAKKARIA S.	49	M	08/Sep/2015	CAD CSA TVD GDLV SR HTN DLP	CABG X 4 GRAFTS 9LIMA-LAD,RSVG- MAJOR OM,RPDA,ACUTE MARGINAL)	DR. JAYAKUMAR K

INTERESTING CASES

INTERESTING CASES

- TOPSY-TURVY HEART WITH AP WINDOW
- BENTALLS PROCEDURE
- ANOMALOUS ORIGIN OF RPA FROM ASCENDING AORTA
- TRUNCUS ARTERIOSUS REPAIR
- ASO +ARCH REPAIR FOR TAUSSIGBING ANOMALY
- PERICARDECTOMY+OPBABG
- KONNO RASTAN
- TAVI EXPLANTATION +BENTALLS PROCEDURE
- RSTELLI PROCEDURE
- SEPTAL MYECTOMY

TOPSY TURVY HEART WITH AP WINDOW

DIAGNOSIS:TOPSY TURVY HEART,TYPE II AP WINDOW,ASD,SEV PAH,GD LV,SR

PROCEDURE:AP WINDOW REPAIR, DC OF ASD

HISTORY:2nd born female child of NCM of birth weight 2.5 Kg, delivered by vacuum delivery was detected to have CHD when evaluated with Fetal ECHO. H/o Feeding difficulty (+). No H/o cyanotic spells/Recurrent Respiratory tract infections/Seizures/TIA/FTT. Immunized till age.

PHYSICAL EXAMINATION:

Child active Nopallor/icterus/clubbing/oedema. PR: 120/min,regular. Chest: clear, AEBE. Apex beat in 5th ICS in MCL, S1S2 (+), Continuous Murmur. P/A: WNL

INVESTIGATIONS:

BLOOD: WNL

X Ray: SS, LC, CTR: 0.55, RT Lung hyper inflated, LT lung hypoplasia Present

ECG: SR at 130 bpm, Axis: 120°.

ECHO: LVIDD 17, Ao Valve Annulus 8.5, MPA 13, RPA 7, LPA: 4mm. SS, LC, Superoinferior ventricles - RV superior. Normal venous drainage. 7mm ASD (L->R). AV-VA concordance, no VSD, 9mm AP window BDS. Aortic arch give rise to neck vessels. MR 1+, AR 1+, TR 3+, PR 2+, RVSP=80+RA.

CT PULMONARY ANGIOGRAM: SS, LC with superoinferior ventricular orientation (TOPSY TURVY HEART). Large aortopulmonary communication. Caudal origin of Aorta and Aortic arch with abnormal branching. Hypoplastic left pulmonary artery. Hypoplastic left upper lobe. Significant narrowing of left bronchus.

SURGICAL FINDINGS

SS, LC, cardiac mass found rotated 90 degree along its long axis, right ventricle superior and left ventricle inferior, great vessels arising caudally, very short ascending aorta immediately continues as arch and gives rise to DTA, four independent neck vessels with long course arise from that short arch below the level of carina at (D8) level. normal systemic and pulmonary venous drainage, PA arises at the level of diaphragm, with narrow left pulmonary artery, Type II AP window of size 1.2 cm x 1.5 cm, ASD size of 1.5 x 0.7 cm,

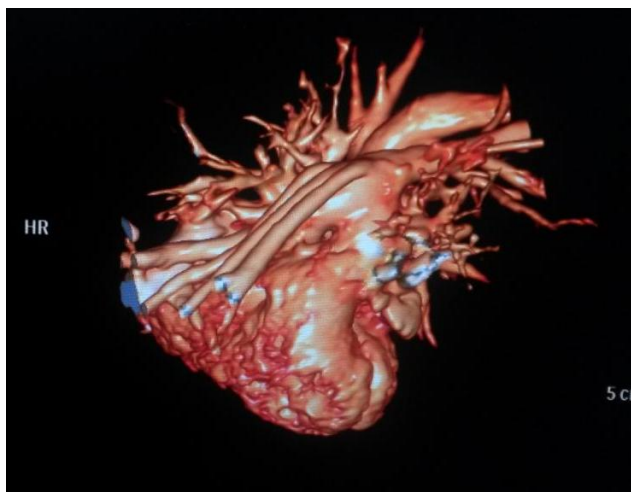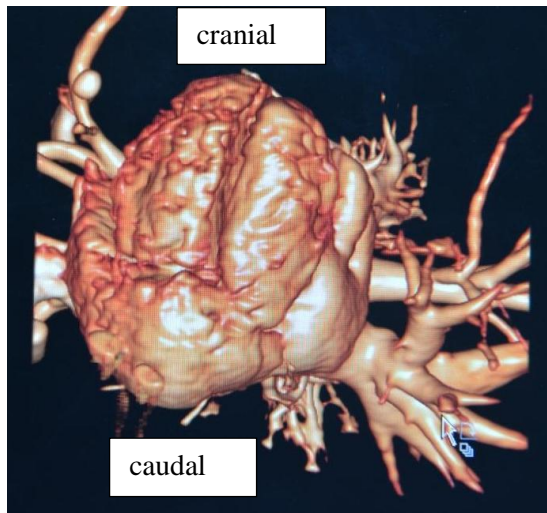
STEPS

Standard midline sternotomy. Thymus excised. Heparinised, Aorto RA bypass instituted. while dissecting between AO and PA, AP window opened so went on TCA, Cardioplegia cannula inserted, cardioplegia given, heart arrested in diastole, AP window repaired using BPP, RA opened DC of ASD done, rewarming started, deairing done cross clamp released, heart picked up in sinus rhythm, came off by pass in stages, de-cannulation done, 2x RA, RV wire placed, Mediastinal drain inserted. Hemostasis achieved. Chest closed in

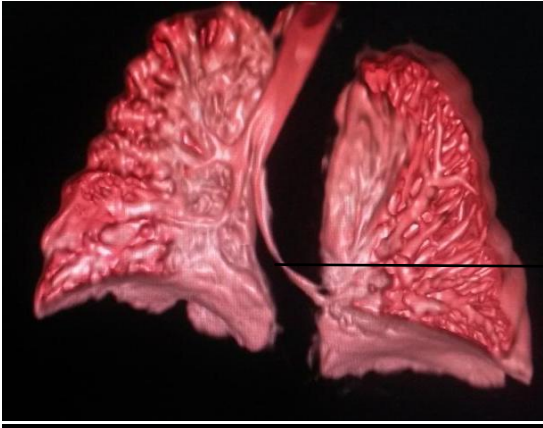
layers, sternum with SS wires, 3-0 monocryl for subcutaneous tissue and 4-0 monocryl sutures for skin.

CPB time:126,ACC:36,TC

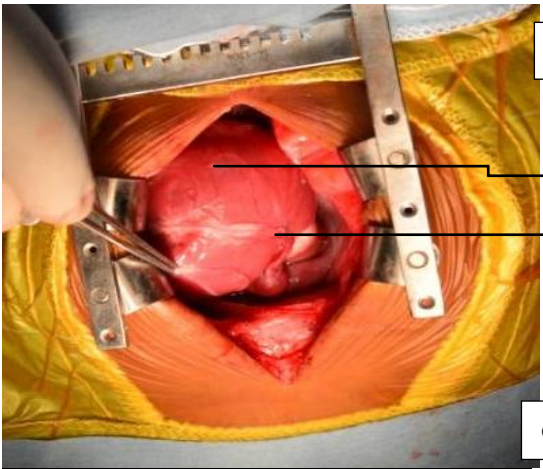
PICTURES



**Four independent long
Neck vessels arising from
short arch**



Bronchial compression



cranial

Right ventricle

Pulmonary artery

caudal

BENTALL PROCEDURE

DIAGNOSIS: ASCENDING AORTIC ANEURYSM, SEVERE AR, DILATED LV, HTN, NC.

PROCEDURE: BENTALL PROCEDURE

HISTORY: 44 year old female presented with h/o DOE, FC- II x 2 years, associated with h/o AOE FC- II, pre-syncope, palpitation.. HTN (+), DM (-), DLP (-).

PHYSICAL EXAMINATION: No pallor/icterus/pedal edema. HR: 88/min. BP: 150/40mm Of Hg. CVS- precordium normal. S1 S2 (+) 3/6 early diastolic murmur (+) in aortic area. RS: AEBE, clear. P/A- WNL CNS-WNL.

BLOOD INVESTIGATIONS: WNL

CXR: CTR- 0.65, LV apex, dilated ascending aorta.

ECG: SR, axis + 100', LVH with strain.

ECHO: LV- 65/50, EF: 45%, LA- 34, ASCENDING AO-56 mm, STJ- 42mn, No dissection flap. AR-4 +, AV- tri-leaflet, Fair LV function

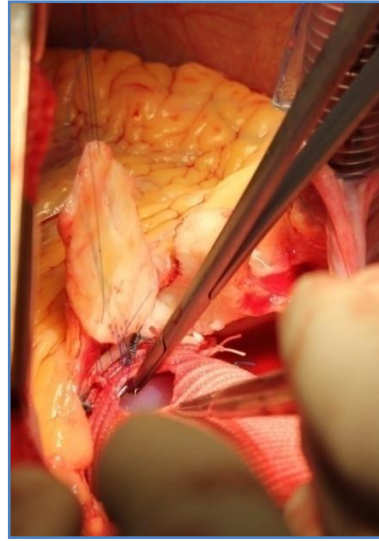
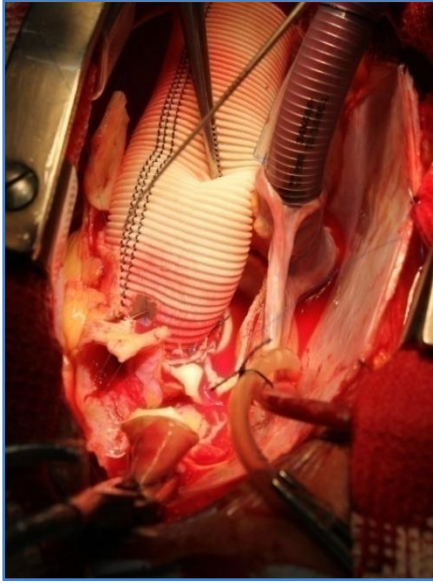CAG: LMCA- normal, LAD- normal. LCX- ND,normal. RCA- Dominant, normal.

SURGICAL FINDINGS: Ascending aortic aneurysm size 5x6 cm+ extending upto the arch. Arch vessels normal. No e/o intimal tear. Sev AR+. Coronary ostium normal, LV dilated.

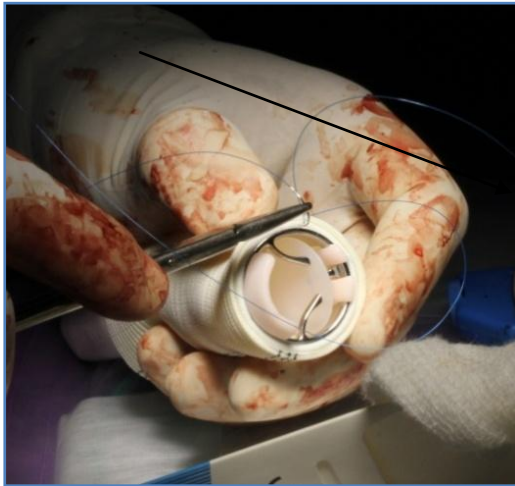STEPS:

Median sternotomy. Vertical pericardiotomy, pericardial stays. Heparinization. Aorto – RA CPB instituted. Left heart vented via the RUPV. Core cooling started. Aorta cross clamped. Aneurysm opened. Antegrade ostial cold blood cardioplegia given. Heart arrested in diastole. Coronary buttons harvested. Aneurysm excised. Aortic valve excised. A composite graft created with # 25 CHVP and #28 ALBO graft. Proximal end of the composite graft sutured to the Aortic annulus with 2-0 Tycron sutures in Aorta to LV fashion. Coronary buttons anastomosed with the graft with 6-0 prolene. Distal end of the graft sutured to the distal end of the ascending aorta. De-airing done. Aortic cross clamp removed. Heart picked up in sinu rhythm. 1 RA and 1 RV pacing wire placed. Came off bypass with stable hemodynamics. Protamine given, decannulation done, Hemostasis secured. 2 Mediastinal drains placed. Sternotomy wound closed in layers.

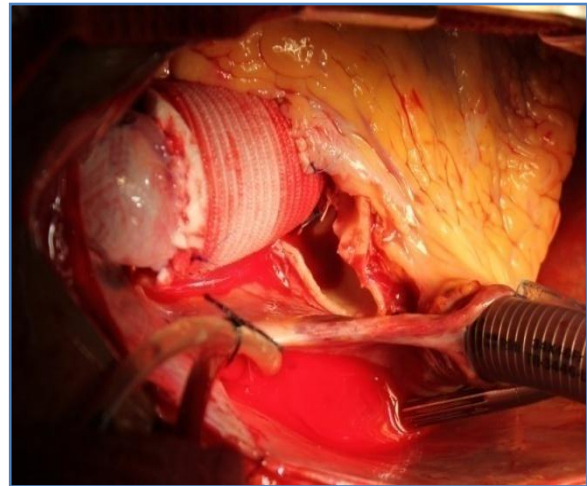
CPB : 90 minutes **ACC**: 60 minutes.



CORONARY BUTTON ANASTOMOSES



PREPARATION OF VALVED CONDUIT



COMPLETED BENTALL'S PROCEDURE

ANOMALOUS ORIGIN OF RPA FROM ASCENDING

AORTA

DIAGNOSIS:CCHD,RPA FROM ASCENDING AORTA,PDA,SEV PAH,
MOD RVD,SR

PROCEDURE: RPA REIMPLANTATION TO PA+PDA
INTERRUPTION+TV REPAIR+DIRECT CLOSURE OF PFO WITH
FENESTRATION

HISTORY:1month old child 2nd in order born out of NM, at term by FTND
with birthweight of 3kg, child cried immediately. Bluish discolorations of lips
was noted on crying& was referred to SAT hospital and was evaluated. She
was diagnosed with CHD. Growth normal for this age, not immunized. No h/o
spells/ surgery/ loc/ feeding difficulties.

PHYSICAL EXAMINATION: Active child, No pallor, icterus, cyanosis,
clubbing/edema. P-136/min, SPO2- 86%, rr- 38/min. CVS: precordium
normal, apex felt @ 4th ICS @ MCL. S1,S2+, S1 Soft, systolic murmur
RUSB. RS: NAD.CNS: No FND,P/A: NAD

INVESTIGATIONS:

BLOOD:WNL

CXR: CTR 0.5, B/L PA Dilated, b/l plethoric lung fields

ECHO:LV-16/9, LA/AO 12/12. RVH-15 RPA-6.7mm, LPA-7.2mm
6.5mm ASD, PDA R-L 20/7. RPA arising from left and most apart of

ascending AO. LPA from MPA. , RA/LV dilated. RVSP-70+RA. SS, LC, PV-LA, NC. MR1+, AR 1+, TR 3+, PR2+.

SURGICAL FINDINGS:

Sternum Normal, Mediastinum Normal, SS, LC, normal systemic and pulmonary venous drainage, RPA FROM ASC AORTA,4 mm PDA,8 mm ASD,Severe TR,RV hypertrophied PA's of adequate size

STEPSO: Standard midline sternotomy. Thymectomy done.Pericardium hitched. Rt. PA dissected till hilum. Heparinized, Aorto-RA bypass instituted.(Aortic purse string taken almost at Innominate) converted to bicaval cannulation.LA vent put through RUPV. Cooled, Aorta cross clamped .Cardioplegia cannula inserted, diastolic arrest of the heart achieved.RPA detached from Aorta and aortic end direct sutures taken in two layers.RPA re-implanted over PA on RT side with 6-0 proline. SVC and IVC snugged and went on total bypass. RA opened, Tricuspid valve repaired.Direct closure of ASD done with 6-0 prolene leaving behind 2 mm fenestration. RA closed in single layer with 5/0 proline.Rewarming started. 2 RA and 2 RV pacing wire taken.PA line placed. Heparin reversed. De-cannulated in stages Heart picked up in SR on Milrinone 0.5 micro/kg/min Rt pleural mediastinal and one mediastinal drains inserted. Hemostasis achieved. Chest closed in layers, sternum with 4 No 1 SS wires sternum, 3-0 monocryl for subcutaneous tissue and 4-0 monocryl sutures for skin. Shifted to ICU with stable hemodynamics for elective ventilation with supports of Milrinone 0.5 microgm/kg/min.

CPB:150+8, ACC :74

TRUNCUS ARTERIOSUS REPAIR

DIAGNOSIS:TRUNCUS ARTERIOSUS (TYPE-II), MILD TRUNCAL VALVE STENOSIS,GOOD LV ,SR

PROCEDURE: TRUNCUS ARTERIOSUS REPAIR (# 19 PA CONDUIT) + ARCH REPAIR

HISTORY: 10 days old male child, birth weight - 2.4 kg, 1st born was diagnosed to have CHD while evaluating for respiratory distress. H/o cyanosis on birth, Patient was intubated at local hospital & referred for further evaluation & management.

PHYSICAL EXAMINATION: HR: 150/min-regular. SPO2: 76%. CVS - precordium (N), apex in (R) 5th ICS in MCL. S1 (+). S2 single. 2/6 SM+. RS - WNL. P/A -WNL. CNS -WNL.

BLOOD INVESTIGATIONS: WNL

CXR: CTR > 0.5, BSTS normal. B/L lung fields clear.

ECG: SR HR 150/ min, RAD, RAE, RVH

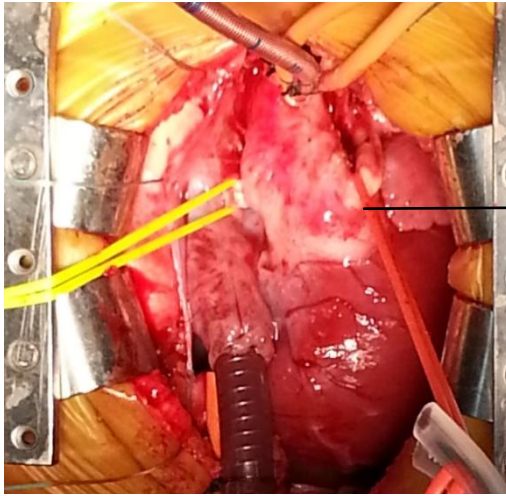
ECHO:SS,LC, 2.5 mm ASD.TypeII truncus arteriosus large subtruncal VSD. Tricuspid truncal valve. Truncal valve gradient 33/18. No truncal regurgitation, left arch no COA.

SURGICAL FINDINGS: SS, LC, Type II truncus arteriosus, Bicuspid truncal valve-thickened,coronaries normal normal systemic and pulmonary venous drainage, biventricular hypertrophy present, PA's of adequate size,2x1.5 cm sub truncal VSD present

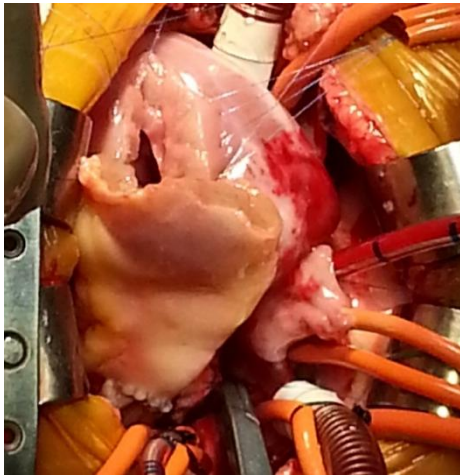
STEPS: Standard midline sternotomy. Patch harvested. Thymectomy done. Pericardium hitched. Branch PA dissected till hilum .patient had SVT and ST depression and low pressures so RPA snugged. Aorto-RA bypass instituted converted to bicaval cannulation. Rest of the dissection completed on pump, LA vent put through RUPV. Cooled. Aorta cross clamped .Cardioplegia cannula inserted, diastolic arrest of the heart achieved. Branch PA cuff harvested from Aorta and augmented with patch from homograft ,LPA/RPA Augmented with homograft patch to create a cuff of tissue to anastomosis with homograft.SVC and IVC snugged and went on total bypass. RA opened parallel to AV groove and and VSD assessed through TV. VSD, closed with gortex patch with continuous and interrupted technique sutures with 6/0 proline.. After taking Stay suture Incision given over RVOT. Homograft placed and proximal end suturing done with 6/0 proline to LPA and RPA cuff and then distal end of homograft anastomosed with RVOT with 6/0 proline. RA closed in single layer with 5/0 proline. Rewarming started, 2 RA and 2 RV pacing wire taken.PA line placed. Heparin reversed. De- cannulated in stages. Heart picked up in SR on Milrinone 0.5 micro gm/kg/min, Rt pleural mediastinal and one mediastinal drains inserted. Hemostasis achieved. Coseal Sprayed over heart to minimize adhesions in view of future redo surgey.Chest closed in layers, sternum with 4 No 1 SS wires sternum, 3-0 monocryl for subcutaneous tissue and 4-0 monocryl sutures for skin. Shifted to ICU with stable hemodynamics for elective ventilation with supports of Milrinone 0.5 microgm/kg/min

CPB: 317 minutes.**ACC:** 210 minutes. **SCP:** 65 minutes.

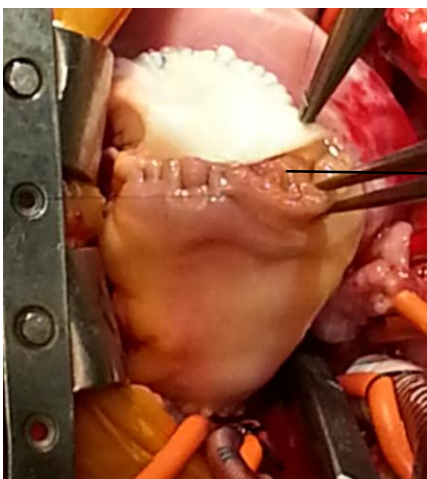
PICTURES



TRUNCUS TYPE II



COMPLETED DISTAL
HOMOGRAFT SUTURING



COMPLETED RVOT
ANASTOMOSES WITH
BOVINE PERICARDIAL PATCH
AUGMENTATION

ASO+ARCH REPAIR+VSD CLOSURE

(TAUSSIG BING ANOMALY)

DIAGNOSIS:DORV,SP VSD(TAUSSIG BING ANOMALY)ARCH
HYPOPLASIA,SEV PAH, GD LV,SR

PROCEDURE: ASO+ARCH REPAIR +VSD CLOSURE on 13/08/2015

HISTORY58 day's old male child born to a NCM parents delivered at term by LSCS (obstetric history) had a birth weight of 3.25kg. Child cried immediately after birth and was initiated to breast feeding. Parents noticed bluish discoloration at birth. Child was diagnosed with CHD at the age of 1 1/2 month on evaluation for LRTI. Growth and development normal. Immunized for this age.

PHYSICAL EXAMINATION:

Alert, No pallor, icterus, clubbing, edema, cyanosis+, PR 136/min. SPO2- RVL 77%, RLC -85%. **CVS:** Precordium normal. Apex at 4th ICS left MCL. S1S2+, no murmur. **RS:** AEBE, NVBS. **CNS:** No FND. **P/A:** soft, no organomegaly.

BLOOD INVESTIGATIONS: WNL

ECHO LV 30/14 RV 10 EF 85 LA/AO 14/8, MPA- 14mm.normal venous drainage. DOR, side by side great vessels, normal coronaries,DSc.AO-7 mm, Arch -4.5mm, arch hypoplasia. Archafter left carotid 4mm, narrowest aorta-2m at isthmus. 2mm stretched open PFO. Large SPVSD.1x1cm, MR 1-2+.

SURGICAL FINDINGS: Sternum normal, thymus+, Innominate vein+. SS,LC, Normal systemic and pulmonary venous drainage. AO from RV, PA from LV AO anterior PA posterior, ascending aorta mildly hypo plastic, transverse arch moderate hypoplasia,distal arch severe hypoplasia,arch vessels normal, PDA dependent systemic circulation,Coronary pattern- normal coronaries,Branch PA's of adequate size. Sub pulmonic VSD (1cmx1cm), Preserved LV.

STEPS: Median sternotomy. Thymus excised. Innominate vein+. Pericardial patch harvested and tanned. Pericardial stays. Aorta dissected away from the PA up to the Pericardial reflection. PA's dissected up to the first branch. PDA identified and dissected. Heparinization. Selectivecerebral perfusion done by cannulating innominate -RA cannulation. Went on partial bypass. Branch PA's clipped. Left heart vented via the RUPV. changed to SVC ,IVC cannulation, SVC ,IVC looped. Core cooling started, DTA cannulated and connected to CPB circuit, Cardioplegia cannula inserted in the aortic root. Ante grade cold blood cardioplegia given. Heart arrested in diastole. arch repair done using BPP, DTA cannula removed, and converted to single circulation, PA opened SP VSD closed using BPP, Aorta transected. Commissural stays taken. Coronary buttons harvested. Neo PA trunk created from the Aortic root with autologous pericardium to bridge the coronary button harvest sites. MPA transected. Lecompte menouvere done. Trap door created in the proximal MPA trunk. Coronary anastomoses done to the trap door in PA trunk with 8-0 prolene. Neo proximal aorta created. Distal aorta anastomosed with proximal

neo aorta with 7-0 prolene. ASD made restrictive, RA closed in single layer Deairing. Aortic cross clamp released and root vented. Heart picked up in sinus rhythm. Distal MPA anastomosed with Neo MPA with 8-0 prolene. 2 RA and 2 RV pacing wires placed. RA pacing started at 140/min Came off Bypass in stable hemodynamics. RSPV vent removed and LA line inserted. Hemostasis secured and checked. One Right pleuromediastinal drain and one Mediastinal drain placed. MUF done. Protamine. Decannulation. Hemostais secured. Sternum stented. Wound closed by sized sterile blood bag sutured to the wound margins. Patient shifted to CHICU with stable hemodynamics with inotropic support of Milrinone at 0.5mics/kg/min.

CPB:329 ACC:219

PERICARDECTOMY+OP CABG

DIAGNOSIS: CONSTRICTIVE PERICARDITIS, CAD, DVD, GOOD LV, SR, DM, HTN, DLP

PROCEDURE: PERICARDECTOMY+OP CABG (LIMA- LAD)

HISTORY: 36 years old male, working as a sales man in a shop in middle east was apparently normal 5 months back when he had an episode of giddiness. No h/o chest pain/ excessive sweating. He gives h/o abdominal distension & generalized edema. This was insidious in onset & progressing. H/o orthopnea & PND present. No h/o AOE / DOE. No h/o syncope on exertion/ palpitation on exertion/seizures. H/o Chronic cough present. No h/o weight loss/ altered bowel habits.

Past history- No relevant surgical history. He was evaluated for chronic cough & was diagnosed with TB & is on ATT. Risk factors- No DM / HTN / DLP. No h/o CVA/TIA/LOC/seizures. Family history of CAD absent.

PHYSICAL EXAMINATION: conscious, oriented, comfortable at rest, pallor(-)/icterus(-)/cyanosis(-)/clubbing(-)/pedal edema(-).

HR: 90/min. RR: 18/min. BP: 118/64mmHg. CVS - precordium (N). Apex in (L) 5th ICS 1cm med to MCL. S1 S2 (+). No murmur. JVP: Not raised. RS - NAD. P/A - NAD. CNS - NAD. Allen's test (-). Carotid bruit (-). PVD (-). Varicose vein (-).

INVESTIGATIONS:

BLOOD: WNL

CHEST XRAY:CTR-60%,b/l lung fields clear

ECG:SR,Rate-100/min, QRS axis-+30,

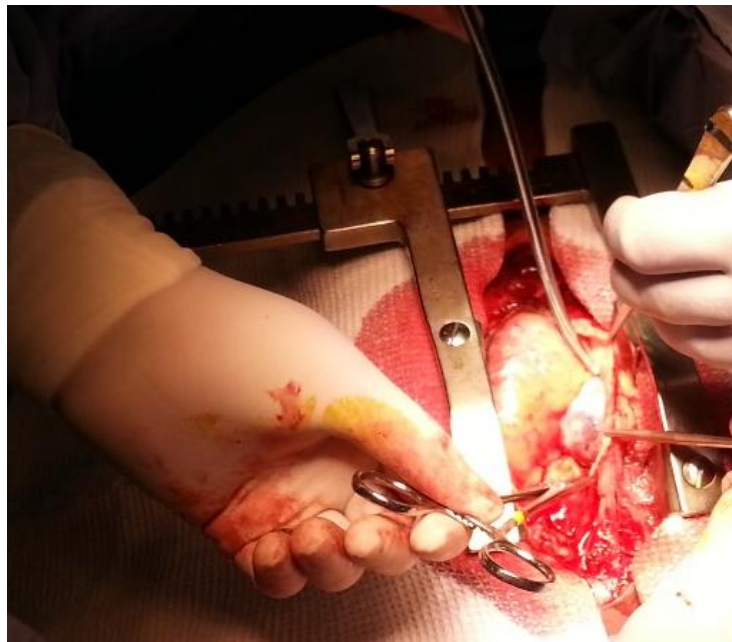ECHO:LV-34/26,EF-56%,LA28,AO-19,Tricuspid valve e wave inspiration-0.68,e wave expiration-0.36,mitral inflow respiratory variation >45%, features suggestive of constrictive pericarditis, good LV function, no RWMA.

SURGICAL FINDINGS: Thick Pericardium surrounding all chambers of heart with minimal calcifications. Dense adhesion present with Myocardium.(Post Pericardectomy) No cardiomegaly, No PE, Good LV contractility, Aorta normal ,Myocardium area LIMA of normal caliber and good flows. LAD: 1.5mm vessel, arteriotomy site was healthy, post grafting distal run-off good.

STEPS: Standard midline sternotomy. Pericardium dissected around aorta first with great precautions avoiding injury to aorta.LIMA harvested. Then pericardium was incised in midline with help of dissecting scissor, electro cautery. Rt Pericardium was dissected from inferior surface with help of harmonic scalpel on Rt side with dissection extended up to removal of pericardial adhesions of RA and RV completely and thick calcified pericardium excised and similarly dissection on Lt side carried out till removal of pericardial adhesions of LV completely including inferior adhesions with diaphragm and thick calcified pericardium excised.Lt pleural drain inserted.Heparinised. Heart stabilized with Medtronicstabilizer with negative suction of 300mmHg.The distal anastomoses of LIMA anastomosed to LAD using 7-0 prolene, graft de- aired. Hemostasis achieved. Heparin reversed. Two

mediastinal drains inserted, hemostasis confirmed. Chest closed in layers. Sternum closed with 6 no 6 SS wires, subcutaneous tissue with 2-0 vycril and skin with 3-0 monocryl-subcuticular. Patient shifted to the ICU with stable hemodynamics for elective ventilation.

COMPLETEDPERICARDECTOMY



KONNO RASTAN

DIAGNOSIS: SEV CAL AORTIC STENOSIS, SEV AR, MOD MR, LVOTO OBSTRUCTION, GOOD LV FUNCTION, SR

PROCEDURE: KONNO RASTAN PROCEDURE (AVR #17 CHVP)

HISTORY: A 20 year old female, presented with c/o DOE/FC-II-III (progressively increased now). Diagnosed case of valvar heart disease and on follow-up at SCTIMST x 1/2 years. H/o multiple syncopal episodes in last 1 1/2 years associated with seizures features so on anti-epileptics as neurology guidance. No h/o AOE/palpitations/orthopnea. No significant family history. No h/o drug allergy. No h/o surgery in the past.

PHYSICAL EXAMINATION: Conscious/oriented and afebrile. Short stature facial dysmorphic features. Hypo pigmented patches over both hands and feet. PR: 78/min. BP: 90/60mmHg. CVS - S1,S2(+). ESM (+) AA, EDM (+) LVS. RS-AE+BS, clear. PA: No organomegaly, No free fluid. CNS - No focal neurological deficits.

INVESTIGATIONS:

BLOOD: WNL, **CXR:** No CE/PVH, **ECG:** SR, Left axis deviation

ECHO: LV- 40/27, EF- 61.5%, LA/Ao- 31/18, Septum- 6.5/10, MR- 2+, Normal calcific nodule in AML, No AR Jet- 0.97cm, LVOT- 1.3, AA (above STJ)- 25mm, AS- 109/67, AR- 4+, A. Annulus- 12mm, calcific, TR- 1+, No good TR jet, Good LV/RV function, PV- normal

Cardiac CT: Calcium in LVOT and ventricular surface of thickened AML with LVH and AA dilatation, coronaries normal, LV- 9mm (PW), IVS- 12mm, AA- 17mm, AA- 30mm, Aortic arch- 21.5, DTA- 15mm.

FINDINGS: Cardiomegaly present, mild pericardial effusion. Hypertrophic LV, Good contractility of LV and RV Post stenotic dilatation of aorta present present, wall thinned out. Rest of Aorta was normal. Aortic valve : Trileaflet. Severely calcific leaflets. Commissural fusion. Small aortic annulus. Annulus free of calcium. Fixed orifice of the leaflets causing moderate AR. Normal coronary pattern. Mild calcification of the LVOTO and the mitral leaflets present

PROCEDURE: Primary midline sternotomy. Minimal thymus dissection. Pericardium opened and well created. Patient heparinized. Aortic purse strings taken for cannulation, followed by RAA purse string. RSPV purse string taken for placing vent. Proximal portion of aortic arch cannulated; venous cannula placed and went on CPB.LA vented via RSPV. Cooled to 30 degrees. Cold ice slush placed. Aorta cross clamped. Vertical aortotomy made and ostial plegia given. Heart arrested in diastole. Aortic valve excised. Aortotomy extended down across the annulus on the left side of origin of RCA across the IVS and the RV. Patch taken from the Albograft shaped in a spindle manner with maximum diameter for the annulus and the inferior part for VSD and superior part for aorta. VSD closed using 4-0 prolene continuous sutures. Thus the new aortic annulus was formed with 1/3rd of the circumference with albograft. 13 Pledged non- everting 2-0 Ti-cron sutures on 1/2 circle 12 mm tapering

needle taken from native aortic annulus. At the site of the graft sutures were taken from outside in. RVOT patch was fashioned in a triangular manner. Valve sutures taken from outside in, fixing the RVOT patch (triangular patch) to the previous spindle shaped patch. #17 sized CHVP valve was sized and placed and fixed with sutures. Now the triangular RVOT patch which was fixed to the outside of the neo annulus was used to close the RVOT using 4-0 prolene. Now the upper part of the spindle shaped patch was used to reconstruct the aorta with 4-0 prolene. Heart deaired and cross clamp removed. Root vented. Heart picked up in sinus rhythm. Came off CPB in stages with optimal filling pressures. Protamine given. Decannulated. Hemostasis secured. Pericardium over the aorta approximated. Drains placed, pacing wire taken and sternum closed in layers. Shifted to ICU for elective ventilation and monitoring with supports.

CPB: 128 ACC:68

TAVI EXPLANT+BENTALLS PROCEDURE

DIAGNOSIS:S/P TAVI(29 ES),SEV PARAVALVAR AR,VSD,GOOD LV, SR

PROCEDURE: EDWARDS VALVE EXPLANTATION+ANNULAR TEAR REPAIR+BENTALLS PROCEDURE (25 CHVP +28 ALBOGRAFT)

HISTORY: A 51 year old male, Pt. was diagnose case of severe AS and was on medical follow-up in view of less severity of disease. H/o underwent TAVI with Edwards valve at Dubai . H/o post procedure severe AR for which Pt. came to SCTIMST.

PHYSICAL EXAMINATION: Conscious/oriented and afebrile. No pallor/icterus/cyanosis/clubbing/pedal edema. PR: 96/min. BP: 140/90mmHg. CVS - S1 S2(+). 4/6 EDM (+) at RUSB, RS-AE+BS, clear. PA: NAD, CNS - No neurological deficit.

INVESTIGATIONS:

BLOOD:WNL

CXR: CTR- 56%, prosthesis (+) at AV area

ECG: 80/min, SR, PR- 170ms, No ST-T changes, No Q waves

ECHO: LV- 49/34, EF- 54%, LA/Ao- 41/36, Septum- 14/13, AR- 3+, A.Annulus- 35, TR- 2+, Continuous flow in RVOT region, Post TAVI, Severe AR, paravalvular, ruptured annulus

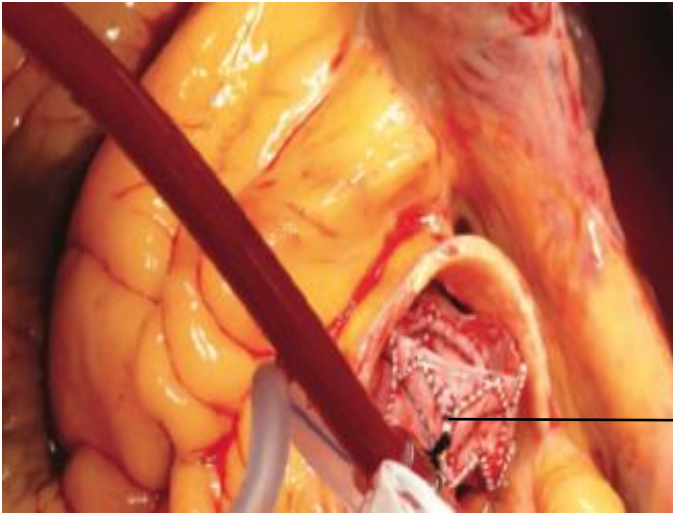
CAG: LMCA- Coronaries normal. RSOV from RCC to RV. LCx- AR mod-paravalvular. RCA- Saturation SVC- 72%/IVC- 78%/RA- 764/RV- 86.

SURGICAL FINDINGS: Minimal pericardial fluid, Aorta appears normal. On palpation-Ascending Aorta and arch normal.Root -sapiens valve strut felt. Thrill in RVOT felt on Aortotomy -Coronaries were above sapiens valve and normal. Paravalvular regurgitation space in RCC-LCC commissure area with Annular tear in RCC-LCC commissure.The paravalvular leak has communication to RVOT(VSD-5mm).another Supra annular connection on the Rt side of Rt coronary artery to RV-2mm.Valve Densely adherent to LVOT,Aorta,Aortic annulus in the rest of the region.Sepiens valve leaflets were normal.Good LV/RV function.no evidence of IE.Aortic wall thickened. good LV contractility.PA soft. Aorta mildly dilated.

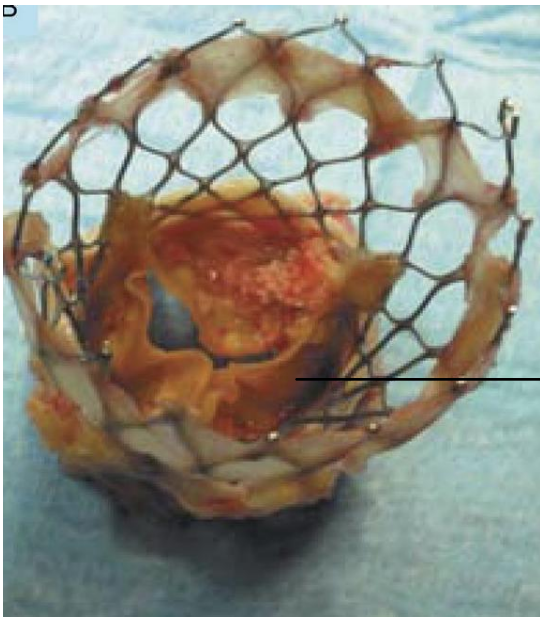PROCEDURE: Standard midline sternotomy. Pericardium incised and opened in inverse T shaped incision. Pericardial well created. Aortobicaval cannulation and the patient was placed on CPB. RSPV vent inserted. Cooled to 28 degrees. Aorta cross clamped and opened. Complete diastolic arrest of the heart attained with tepid blood cardioplegia given through the coronary ostia. Myocardium protected with ice slush.Ascending aorta transected 1cm beyond STJ. Aortic root excised. Both Coronary buttons harvested and stay sutures taken. sapiens valve explanted. Supra annular connection to RV was closed using 4-0 prolene,and a 1x1 cm at RCC region (VSD) was closed with 4-0 prolene,aortic annular sutures taken with 16 pledgtd 2-0 Ethibond sutures , Composite valve graft conduit created with 25 CHVP and 28 mm albograft was prepared. Composite Valve - graft conduit seated and tied. Valve movements checked. Left and Right coronary buttons anastomosed to the graft conduit using 5-0

Prolene continuous sutures. Distal anastomosis of the composite graft to the Aorta performed with 3-0 prolene sutures. Aorta de-aired through the graft and Aortic cross clamp released. RV and skin pacing wire taken and paced at 90 per min. Heart picked up in SR with pacing. Came off bypass on pacing with Adrenaline support at 0.05 mics/kg/min. Hemostasis achieved. Pericardium loosely closed. Drains placed. Sternum closed with Six No.6 Stainless steel Wound closed in layers -Subcutaneous : 2 layer of Vicryl 2-0, Skin : Monocryl 3-0 for subcuticular. Shifted to CSICU with pacing(pacing dependent) for elective ventilation and monitoring. post procedure on day 4 patient was shifted to cardiology for PPI

PICTURES



EDWARD'S VALVE



EXPLANTED VALVE

RASTELLI PROCEDURE

DIAGNOSIS:CCHD,DTGA, VSD, SEVERE PS,ASD,CONFLUENT PA's, SR,NC

PROCEDURE:RASTELLI PROCEDURE (# 19 PA HOMOGRAFT),PFO OPEN.

HISTORY: A 2 year old male child, 2nd in birth order born to non-consanguineous couple was brought with history of cyanosis since 4 months of age. No h/o cyanotic spell.

PHYSICAL EXAMINATION: Central cyanosis (+). HR: 111bpm. SpO2- 71%. **CVS:** Precordium – normal. AI 5th ICS Left lat to MCL. S1 S2- (+) 4/6, ESM in para-sternal area. **RS: WNLP/A: WNL. CNS: WNL.**

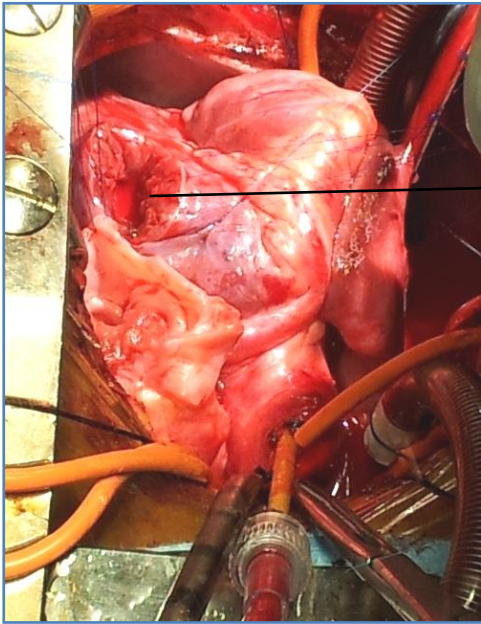
BLOOD INVESTIGATIONS: WNL

ECHO: LV- 27/15, EF- 79%, PW- 7/9, Septum- 7/10, FS- 42, Confluent PAs, RPA- 5.4, LPA- 5.2, SS. LC, OS ASD (B/D), AV concordance, VA discordance, LVOTO gradient 100mmHg (SV level), SP VSD, No PDA, Left arch.

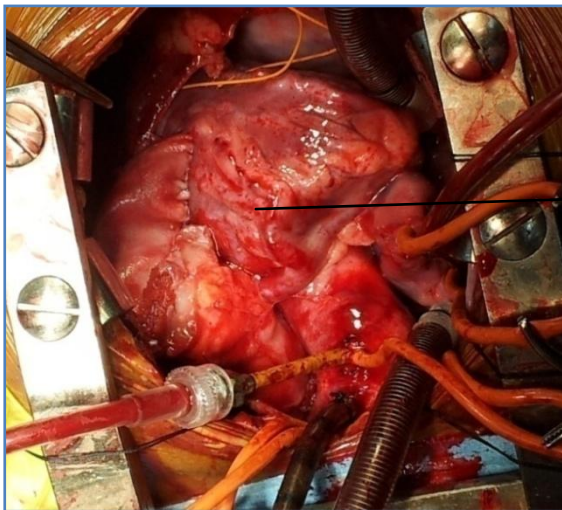
SURGICAL FINDINGS: SS, LC, normal PV and systemic venous drainage, AV concordance,VA discordance. Aorta arising from RV and anterior to PA. PA arising from LV. PDA +, MPA and branch PA's are of adequate size, Subvalvar PS+, coronaries normal (1LCx, 2R), OS ASD (~9mm x 5mm), large subpulmonic VSD. Straddling MV with papillary muscle attached to RV side of septum.TV normal. A large conal branch crossingRVOT.

PROCEDURE: Median sternotomy. Thymus excised. Pericardial patch harvested and tanned. Branch PAs dissected upto hilum on both sides. Aorto – bicaval CPB instituted. PDA ligated and clipped. Left Heart vent put via RVSP. Core Cooling started. Cardioplegia cannula inserted, Aorta cross clamped. Cardioplegic arrest achieved. RA opened parallel to the AV groove. RVOT opened lateral to conal artery and anatomy assessed, Accessory chordae of MV from IVS excised. Hypertrophied conal septum excised. Goretex patch fashioned. Sub pulmonic VSD rerouted to aorta with goretex patch through RV incision. Intermittent pledgetted sutures used to suture the patch under tricuspid annulus and near aortic annulus. PA divided at confluence, cardiac end sutured in 2 layers.#21 Pulmonary valve conduit sized and fashioned as RV-PA conduit. Posterior layer of anastomosis of conduit to RV done with 5-0 prolene. Anterior layer augmented with BPP. Rewarming started. ASD closed with tanned pericardial patch.PFO left open. RA closed in single layer. De- airing done. Aortic cross clamp removed. Heart picked up in sinus rhythm. 2 atrial and 2 ventricular pacing wires taken and atrial pacing started. Came off CPB with stable hemodynamics. Protamine. Decannulation. Hemostasis achieved. Sternotomy wound closed in layers.

CPB : 245minutes**ACC:**220 minutes.



RVOT INCISION



COMPLETED HOMOGRAFT ANASTOMOSES

SEPTAL MYECTOMY

DIAGNOSIS:HOCM,SEV LVOTO,MOD MR,MOD PAH,GOOD LV, SR, CAD, SVD

PROCEDURE: SEPTAL MYECTOMY + MVR # 23 CHVP

HISTORY: 59 years old male, retired OT assistant, from Palakkad presenting with h/o exertional dyspnea progressing from FC II to FC III over last 3 years, Post prandial angina. No PND, orthopnea, syncope on exertion, palpitation on exertion. Diagnosed as HOCM with severe LVOTO mod MR, mod PAH, LAD-myocardial bridge. Alcohol septal ablation was done on 23/5/14. Symptoms subsided initially, re appeared over few months. No h/o similar complaints in the past. No h/o RF in past. Diabetes since 2003. No h/o of dyslipidemia and hypertension. Nonsmoker. No h/o CVA/TIA/LoC/seizures. No other medical / surgical illness.

Family history - No h/o similar complaints among other family members. H/o CAD for brother.

PHYSICAL EXAMINATION: Conscious, oriented. Moderately built. No pallor/icterus/cyanosis/clubbing /pedal edema/ raised JVP.

Bp-100/70mmhg in right arm supine position, Pulse- 70/min regular, slow rising, All peripheral pulses felt normally, no radio radial no radio femoral delay. Allen's test -Normal, No Varicose veins, No Carotid Bruit, Dorsalis Pedis Palpable , Cardiovascular system: Precordium Normal, AI:5th ICS @MCL, hyper dynamic,No Thrill, S1,S2 +, 3/6 ESM @ LUSB, PSM at Apex

Respiratory system: B/l air entry equally present ,no added sounds.

Abdomen: Soft, non-tender no organomegaly, CNS: No focal neurological deficits.

INVESTIGATIONS:

BLOOD:WNL

CXR: CTR 0.54, lung fields clear. ECG: SR @ 72bpm, QRS axis -32, PR intv 195ms.

ECHO: LV - 38/21, EF 70%, LA/AO - 41/28, mild MR, SAM +, sev LVOTO with gradient 119 mm Hg.

CAG: LMCA - normal. LAD - mid to distal myocardial bridge +, no flow limiting lesion, diagonals normal, S2 fair sized, S1 occluded proximally. LCX - Co dominant and minor plaques in distal LCX and proximal part of terminal OM. RCA - Co dominant , mid 30% lesion. PDA has a myocardial bridge. LV angio- no RWMA, Good LV function, SAM+, mild MR, Severe LVOTO

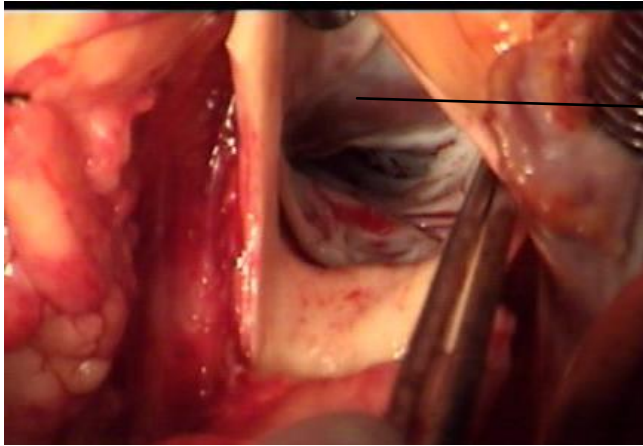
SURGICAL FINDINGS: No Cardiomegaly, Aorta (N). Aortic Valve: tricuspid with normal leaflets.MV leaflets elongated, AML is larger than PML , asymmetric septal hypertrophy more in basal & mid cavity level causing SAM & LVOTO. No evidence of abnormal papillary mussels/chordae.

STEPS: Midline sternotomy. Pericardium incised in inverted T shape and hitched. Aorto-bicaval bypass instituted. Antegrade CBC Cardioplegia cannula inserted and antegrade followed by retrograde cardioplegia given, prompt diastolic arrest achieved. Aortotomy made & stays taken. Aorta cross clamped,

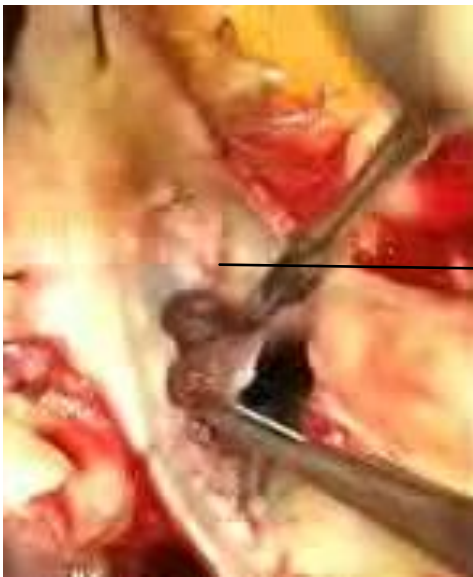aortotomy done and ostial cardioplegia given. Aortic leaflets retracted .Septal myectomy to the level below AML done & abnormal band excised. Aortotomy closed with 4-0 prolene in two layers, Retrograde cardioplegia cannula & RSPV root removed and heart vented through the root. LA opened. AML excised with partial preservation of PML. 14 plegetted No. 2-0 Ethibond sutures taken at the mitral annulus. Annulus sized to No. 23 CHVP prosthesis. # 23 CHVP seated and tied. Leaflet movements checked. LA closed in 2 layers using 3-0 prolene. RA opened. Rewarming started. RA closed in two layers with 3-0 prolene. Left heart deairing done. Aortic crossclamp removed with root on suction. Heart picked up in SR. (1 RA &1 RV pacing wires placed)RV paced @ 80 per minute. Came off bypass in stages, once full rewarming is attained, with adequate filling pressures, Aorta declamped. Patient came off bypass with adequate filling pressures with NA of 0.1 mics/kg/min. Protamine started. Decannulated in stages. Two mediastinal & 1 Rt. Pleural drains kept. Hemostasis achieved and confirmed.Incision closed in layers, sternum closed with 6 no 6 SS wires, subcutaneous with 2-0 vicryl and skin with 3-0 moncryl subcuticular. Shifted to ICU for elective ventilation with Iontropic support of Noradrenaline 0.05 mic/kg/min.

CPB:120 ACC:68

PICTURES



Hypertrophied



Myectomy done