

**USE OF VIDEO LARYNGOSCOPE TO REDUCE
COMPLICATIONS OF TRANSESOPHAGEAL
ECHOCARDIOGRAPHY PROBE INSERTION:
A MULTICENTRE RANDOMISED STUDY;
RESULTS FROM THE SCTIMST ARM**

Dr Vipin Raj V

DM CARDIOTHORACIC AND VASCULAR ANAESTHESIA THESIS

YEAR: 2021-2023



**SREE CHITRA TIRUNAL INSTITUTE FOR MEDICAL
SCIENCES AND TECHNOLOGY, TRIVANDRUM**

An Institution of National Importance established by an
Act of the Indian Parliament (Act No.52 of 1980)

Dept. of Science and Technology,
Govt. of India
www.sctimst.ac.in

**USE OF VIDEO LARYNGOSCOPE TO REDUCE
COMPLICATIONS OF TRANSESOPHAGEAL
ECHOCARDIOGRAPHY PROBE INSERTION:
A MULTICENTRE RANDOMISED STUDY;
RESULTS FROM THE SCTIMST ARM**

A THESIS SUBMITTED BY

Dr Vipin Raj V

TO

**SREE CHITRA TIRUNAL INSTITUTE FOR MEDICAL
SCIENCES AND TECHNOLOGY, TRIVANDRUM**

IN PARTIAL FULFILMENT OF THE REQUIREMENTS FOR
THE AWARD OF

**DM CARDIOTHORACIC AND VASCULAR
ANAESTHESIA**

YEAR: 2021 - 2023

DECLARATION BY THE STUDENT

I **Dr Vipin Raj V** hereby certify that I had personally carried out the work depicted in the thesis Titled “**USE OF VIDEO LARYNGOSCOPE TO REDUCE COMPLICATIONS OF TRANSESOPHAGEAL ECHOCARDIOGRAPHY PROBE INSERTION: A MULTICENTRE RANDOMISED CONTROLLED STUDY; RESULTS FROM THE SCTIMST ARM**”.

No part of this thesis has been submitted for the award of any other degree or diploma prior to this date

Date:30/08/23

30

Signature



Name of the candidate Dr Vipin Raj V

CERTIFICATE BY THE RESEARCH GUIDE



SREE CHITRA TIRUNAL INSTITUTE FOR MEDICAL SCIENCES AND TECHNOLOGY, TRIVANDRUM

An Institution of National Importance established by an Act of the Indian Parliament(Act No.52 of 1980)
Dept. of Science and Technology, Govt. of India www.sctimst.ac.in

Name of the guide: **Prof Thomas Koshy**


Division/ Department: **Cardiothoracic and Vascular Anaesthesia**

This is to certify that Dr Vipin Raj V, department/ division of Cardiothoracic and Vascular Anaesthesia of this institute has fulfilled the requirements prescribed for the DM degree of the Sree Chitra Tirunal Institute for Medical Sciences and Technology, Trivandrum.

The thesis titled **“USE OF VIDEO LARYNGOSCOPE TO REDUCE COMPLICATIONS OF TRANSESOPHAGEAL ECHOCARDIOGRAPHY PROBE INSERTION: A MULTICENTRE RANDOMISED CONTROLLED STUDY; RESULTS FROM THE SCTIMST ARM”** was carried out under my direct supervision. No part of the thesis was submitted for the award of any degree or diploma prior to this date.

*Clearance was obtained from the Institutional Ethics Committee / Institutional Animal Ethics / Institutional Committee for Stem Cell Research / Other appropriate committees (if any, specify) for carrying out the study

Date 30/08/23

Dr Thomas Koshy 

Professor (Senior Grade) Division of Cardiothoracic and Vascular Anaesthesia

CERTIFICATE BY THE RESEARCH CO- GUIDE



SREE CHITRA TIRUNAL INSTITUTE FOR MEDICAL SCIENCES AND TECHNOLOGY, TRIVANDRUM

An Institution of National Importance established by an Act of the Indian Parliament (Act No.52 of 1980)

Dept. of Science and Technology, Govt. of India www.sctimst.ac.in

Name of the co- guide: **Prof Unnikrishnan K P**

Division/ Department: **Cardiothoracic and Vascular Anaesthesia**

This is to certify that **Dr Vipin Raj V**, department/ division of Cardiothoracic and Vascular Anaesthesia of this institute has fulfilled the requirements prescribed for the DM degree of the Sree Chitra Tirunal Institute for Medical Sciences and Technology, Trivandrum.

The thesis titled **“USE OF VIDEO LARYNGOSCOPE TO REDUCE COMPLICATIONS OF TRANSESOPHAGEAL ECHOCARDIOGRAPHY PROBE INSERTION: A MULTICENTRE RANDOMISED CONTROLLED STUDY; RESULTS FROM THE SCTIMST ARM”** was carried out under my direct supervision. No part of the thesis was submitted for the award of any degree or diploma prior to this date.

*Clearance was obtained from the Institutional Ethics Committee / Institutional Animal Ethics / Institutional Committee for Stem Cell Research / Other appropriate committees (if any, specify) for carrying out the study

Date 25.8.2023

Signature

Dr Unnikrishnan K P

Professor Division of Cardiothoracic and Vascular Anaesthesia SCTIMST



**SREE CHITRA TIRUNAL INSTITUTE FOR MEDICAL SCIENCES
AND TECHNOLOGY, TRIVANDRUM**

An Institution of National Importance established by an Act of the Indian Parliament
(Act No.52 of 1980)

Dept. of Science and Technology, Govt. of India www.sctimst.ac.in

APPROVAL OF THESIS

The thesis entitled

**USE OF VIDEO LARYNGOSCOPE TO REDUCE COMPLICATIONS OF
TRANSESOPHAGEAL ECHOCARDIOGRAPHY PROBE INSERTION:**

A MULTICENTRE RANDOMISED STUDY;

RESULTS FROM THE SCTIMST ARM

Submitted by

Dr Vipin Raj V, for the degree of


DM (CARDIOTHORACIC AND VASCULAR ANAESTHESIA)

of

SREE CHITRA TIRUNAL INSTITUTE FOR MEDICAL SCIENCES AND

TECHNOLOGY, TRIVANDRUM

is evaluated and approved by



Dr Thomas Koshy

Name and signature of the examiner

ACKNOWLEDGEMENTS

I would like to express deep sense of gratitude to Dr Thomas Koshy (Professor-Senior Grade, Division of Cardiothoracic and Vascular Anaesthesia , SCTIMST) for his valuable advice, guidance and encouragement in planning and executing this study.

I sincerely thank my co-guide Dr Unnikrishnan K P (Professor, Division of Cardiothoracic and Vascular Anaesthesia, SCTIMST) for his friendly guidance and whole-hearted support.

I am deeply indebted to Prof Shrinivas V G (Professor-Senior Grade and the Head, Department of anaesthesia, SCTIMST) for his whole hearted support and his enthusiasm to inculcate clinical research acumen in his residents.

I thank all the other consultants of Division of Cardiothoracic and Vascular Anaesthesia, my colleagues and the technicians who proved to be very helpful in conducting the study.

I would also like to extend my gratitude to all the consultants of Division of adult Cardiovascular Thoracic Surgery, SCTIMST for their kind co-operation during the study period.

I would like to express my immense sense of gratitude to all the patients who gave their consent to be a part of this study.

Last but not the least, I would like to thank all my family members and my friend whose constant support and encouragement enabled me to complete this study in its present form.

Dr Vipin Raj V

CONTENTS

| | Page No |
|--------------------------------------|----------------|
| Declaration by the Student | i |
| Certificate by the Research Guide | ii |
| Certificate by the Research Co-Guide | iii |
| Acknowledgements | iv |
| List of Figures | vi |
| List of Tables | vii |
| List of Abbreviations | viii |
| Synopsis | ix |
| Introduction | 1 |
| Aims and Objectives | 4 |
| Review of literature | 6 |
| Materials and Methods | 11 |
| Results | 18 |
| Discussion | 28 |
| Conclusions | 35 |
| Bibliography | 37 |
| Appendices | 41 |

LIST OF FIGURES

| Figure no | Figure Caption | Page no |
|------------------|--|----------------|
| Fig 1 | The Medicam Videolaryngoscope (Medicam, Mumbai, Maharashtra, India) | 16 |
| Fig 2 | Consort diagram | 19 |
| Fig 3 | Gender distribution of study subjects | 20 |
| Fig 4 | Gender distribution in groups C and V | 20 |
| Fig 5 | Mallampati grades of both groups | 21 |
| Fig 6 | Cormack-Lehane grades of both groups | 22 |
| Fig 7 | Distribution of surgeries in C group | 22 |
| Fig 8 | Distribution of surgeries in the V group | 23 |
| Fig 9 | Distribution of non- CABG surgeries in both groups | 23 |
| Fig 10 | Study outcomes-First attempt success rate | 25 |
| Fig 11 | Esophageal inlet in relation to larynx | 26 |
| Fig 12 | Photographs showing relationship of esophageal inlet in relation to larynx | 27 |

LIST OF TABLES

| Table no | Details | Page no |
|-----------------|--|----------------|
| Table 1 | Patients demographic & airway characteristics, surgical procedures | 24 |
| Table 2 | Study outcomes-Injuries | 25 |
| Table 3 | Study outcomes-first attempt success rate | 26 |

LIST OF ABBREVIATIONS

| | | |
|----|---------|---|
| 1. | SCTIMST | Sree Chitra Tirunal Institute for Medical Sciences and Technology |
| 2. | TEE | Trans Esophageal Echocardiography |
| 3. | MMP | Modified Mallampatti Score |
| 4. | CL | Cormack-Lehane grade |
| 5. | VL | Videolaryngoscope |
| 6. | ASA | American Society of Anesthesiologists |

SYNOPSIS

Introduction

Trans Esophageal Echocardiography (TEE) has emerged as a standard of care for cardiac surgeries in the perioperative period. The fact that TEE probe can be placed with minimal or no trauma makes it a viable option in the perioperative decision making. The complications if any that may arise from the probe insertion are usually mild. Serious complications, although exceedingly rare have however been reported after the TEE probe insertion. These include conditions like the injury to the upper airway, avulsion of tonsils, or esophageal tear. Videolaryngoscope is considered to be a highly useful tool in the armamentarium of anaesthesiologists. Its role in the management of 'difficult to intubate' cases cannot be over-emphasized. Use of direct laryngoscopy for difficult TEE placements has been adequately described in the literature. However, the use of videolaryngoscope specifically for this purpose has not been mentioned in the literature. The investigators postulate that TEE probe placement under videolaryngoscopic visualisation can decrease the incidence of probe-placement related injuries. A multicentre randomised controlled trial (RCT) was undertaken in 5 centres across the country to test this hypothesis. The results and discussion thereof from the SCTIMST arm of the trial is included herewith.

Objectives

Primary objective:

To find out the incidence of oropharyngeal injury associated with TEE probe insertion

Secondary objective:

1. To find out the number of attempts required for the successful placement of TEE probe
2. To find out the relationship of the esophageal inlet with respect to the laryngeal opening

Methods

This study was a prospective, single blinded Randomised Controlled Trial (RCT). Adult patients who underwent cardiac surgery in any of the adult cardiac surgery operation theatres (OT) and those who required TEE monitoring intra-operatively were included. These patients were randomised into two, viz the 'study' (videolaryngoscope, V) group and the 'control (C)' (blind TEE insertion) groups. Patients were randomised to 2 groups using computer generated random numbers. GA was administered as per the institution protocol. In the conventional group, mandible was lifted by means of direct pressure at the angle and TEE probe was inserted blindly. In the V group, the VL was inserted intraorally after viewing esophageal inlet, and the TEE probe was advanced into the esophagus under direct vision. TEE probe was removed after performing cardiac evaluations at the end of surgery, and the probe tip was examined for presence or absence of blood. A total of 80 patients were recruited (40 in each of the groups). The data thus collected was entered into excel spreadsheet. Numerical data was described in terms of absolute numbers, percentages. Mean and standard deviation was used as appropriate. Chi-square test was used to check for the significance between categorical variables.

Results

A total of 80 patients were recruited (40 in each group) which included 56 males and 24 females. All the baseline and the intraoperative parameters were comparable between the two groups. The average age of the patients thus recruited was 55.5 years (55.5 ± 11.4). Majority of the patients belonged to MMP grade 2 (46/80;57%); followed by MMP Grade 1 (27/80;33%). Majority of the patients studied belonged to Cormack Lehane (CL) grade 1 (38,47.5%), followed by CL2 (33, 41.2%). One case of lip injury in the C group and 1 case of posterior pharyngeal wall injury in V group was observed. There was no significant difference in the incidence of injury in each group. The first attempt success rate between the 2 groups was not statistically significant ($p=0.53$). With regard to the position of esophageal opening (V group), the most common position was posterolateral in relation to the laryngeal inlet ($n=18;45\%$). Others had the esophageal opening located directly posterior ($n=14;35\%$) and lateral ($n=8;20\%$) with regard to the laryngeal inlet.

Conclusion

From the SCTIMST arm of the study, we found that using a videolaryngoscope for TEE probe insertion didn't reduce the incidence of complications. Likewise, there was no significant benefit with the use of VL with regard to the 1st attempt success rate. However, the use of VL made it possible to visualise the anatomy of the esophageal inlet with regard to the laryngeal opening. This led to the observation that the esophageal opening is not always directly posterior to the larynx as is often mentioned in the literature. We found the most common location to be posterolateral followed by the directly posterior location of the esophagus. The least common was the lateral location of glottic inlet. These findings however have to be further validated by larger prospective studies. If so, these findings may help to decrease the overall complications associated with the TEE probe insertion which in turn may improve the quality of healthcare given to this highly morbid subset of patients.



INTRODUCTION

Transesophageal echocardiography (TEE) has emerged as major monitoring tool in the last few decades and has been established as an integral perioperative monitoring/assessment tool of all modern cardiac surgery operation theatres. Currently, it is considered to be a standard of care in the perioperative management of cardiac surgical or minimally invasive procedures. TEE assessment is generally considered to be safe and at the most, a low- risk procedure. Earlier retrospective studies have reported complications to be as low as (0.03-1.4%).¹⁻⁴ A national audit from the UK concluded that the incidence of major complications associated with TEE was 0.08% and showed higher chances of death once complications developed.⁵

Of late, the technology pertaining to the manufacture and use of videolaryngoscopes (VL) has improved greatly. VLs are now considered to be an important weapon in the weaponry of anesthesiologists in difficult airway management.⁶ Multiple case reports have demonstrated the utility of VL in cases of difficult TEE probe insertion.⁷⁻¹⁰ These were however based on evidence from individual patients. In a recent randomized controlled trial, videolaryngoscopy was found to increase the success rate of TEE probe insertion while reducing the pharyngeal injury (as compared to the conventional, blind insertion in patients who underwent cardiac surgery).¹¹ VL was also found to give a better view of the esophageal inlet as compared to conventional laryngoscopy thereby necessitating a significantly lesser number of attempts at successful TEE probe placement.¹² These were however single center studies which only looked at benefits of videolaryngoscopy-guided TEE probe insertion in terms of reduced number of attempts at successful probe insertion. A recent cadaveric study has described the anatomic variations in the location of the esophageal inlet with respect to the laryngeal opening.¹³ The VL may offer advantage in such cases with anatomical variation. Another manikin study done recently suggested that

VL may reduce the pressure on posterior pharyngeal wall during TEE insertion, irrespective of the clinicians' experience.¹⁴ This led the authors to hypothesize that the use of VL may minimize the complications secondary to TEE probe placement.





**AIMS AND
OBJECTIVES**

PURPOSE

As described, TEE probe insertion is often associated with oropharyngeal injuries which often go unnoticed. The investigators hypothesize that TEE placement under video-laryngoscopic visualisation would reduce the complications. Likewise, the jaw-thrust manoeuvre often used in cases of difficult TEE probe insertion might not be useful in all the cases and might actually be counter-productive in a few cases due to the variation in the anatomy of the oesophageal inlet with respect to the laryngeal inlet. Such cases can be easily identified with a VL and can be extrapolated to the general population. This would serve to formulate a universal protocol for the safe insertion of TEE probe in an already compromised group of patients-the cardiac patients posted for surgery. This study also will serve as a foundation for such studies in the paediatric population in whom a greater degree of care is warranted with regard to TEE probe placement.

AIMS AND OBJECTIVES

- 1.** The primary objective was to find out the incidence of oropharyngeal injury.
- 2.** The secondary objective was to find out the number of attempts required for the successful placement of the TEE probe. Also, the relation of the oesophageal opening with respect to the laryngeal inlet was noted in each of the cases.



**REVIEW OF
LITERATURE**

Transesophageal echocardiography (TEE) has emerged as a major monitoring tool in cardiac surgical patients. It is considered to be a standard of care in the perioperative management of cardiac surgery patients. The procedure is considered to be safe generally. In a retrospective study from Australia¹, the authors demonstrated the incidence of TEE related injury to be 13 per 10000 patients which again was more frequent in the elderly (>70 years). The incidence of TEE related mortality was 3 per 10000 patients. In another retrospective database audit from Australia, Lennon et al noticed a higher incidence of gastrointestinal complications in patients who underwent cardiac surgery with TEE being used (1.2% v 0.29%).² The authors then cautioned the clinicians to be aware of the late presentation of TEE complications.

In a study from two Taiwanese centers, intraoperative complications subsequent to TEE probe insertion occurred in 25 patients (0.4%) out of 6255 patients. Most of the complications were mild, usually mucosal bleeding and serious complications like the esophageal perforation occurred in only one patient³. In a single center retrospective cohort study of 7954 cardiac surgical patients from Canada, the overall incidence of TEE related complications was reported as 1.4%. The authors proved that advanced age, low body mass index, complex and prolonged surgeries requiring long bypass time were all independent risk factors for the development of these complications.⁴

While all these were retrospective studies, in a recent prospective one-year national audit by Ramalingam et al, it was shown that, out of 22314 study subjects, 17 of them (0.08% or 1:1300 examinations) had major complications (including seven deaths; 0.03% or 1:3000 incidence) which were directly attributable to these complications⁵. Thus, it was proven in this study that if any of the patients developed TEE related major complication,

the risk of death was as high as 40%. It is thus advisable for the clinicians to take every possible precaution so as to avoid these complications. In this study, it was proven that probe insertion was likely to be the most hazardous part of TEE examination and the authors recommended that the future research be aimed at optimizing the technique of TEE probe insertion so that the complications could be reduced as much as possible. In a systemic analysis on 35 cases of esophageal perforations, the authors noticed that, majority of the perforations had occurred in the presumed 'low-risk' examinations and thus, screening for high risk factors may not have eliminated the occurrence of perforation all together.¹⁵

A few studies had been done previously on the various techniques to improve safety of TEE probe insertion. In a study of 80 patients who underwent elective gynecological surgery under general anesthesia, the incidence of mucosal injury was high (55%) in the conventional group as compared to the group where the TEE probe insertion was done under rigid laryngoscopic assistance (5%, $p < 0.05$). Also, the number of attempts and postoperative odynophagia was lower in the rigid laryngoscope group.¹⁶ The incidence however may have been different in the cardiac surgical patients as majority of the patients are on antiplatelet/ anticoagulation medications and systemic heparinization is a universal practice at the time of cardiac surgery. In another prospective randomized study of 42 patients who underwent cardiac surgery, Chang et al used jaw thrust- assisted technique for TEE probe insertion. The authors concluded that jaw-thrust maneuver facilitated insertion of TEE probe (first attempt pass rate 90.5% v 52.4%; $p=0.04$) and reduced the concomitant oropharyngeal injury (52.4 v 9.5%; $p=0.006$).

Various single case reports have demonstrated the utility of VL for difficult TEE probe insertion. Hirabayashi et al used Airtraq video laryngoscope for the insertion of a TEE probe in a patient with difficult TEE probe insertion.⁷ Ammar et al used UE Medical VL 400 video laryngoscope for successful probe insertion when the TEE probe offered resistance on attempted blind placement. The authors noticed an anatomical variant of the oesophagus wherein it was on the side of the trachea instead of the normal retrotracheal position.⁸

Riley and colleagues reported a case of multiple failed attempts at TEE guided direct-current cardioversion. Pharyngeal visualisation was achieved with the introduction of a C-MAC video laryngoscope with a D-blade into the pharynx. The upper oesophagus was noted to be laterally displaced, accounting for the difficulties with blind intubation; however, insertion of the transducer probe was then readily achieved in the first attempt under real-time direct visualisation.⁹ Similarly, Kim et al encountered excessive resistance during TEE probe insertion in two patients undergoing atrial septal defect device closure. With McGrath VL authors could visualise esophageal opening clearly and further TEE probe insertion was easy¹⁰

There are a few single centre randomized studies performed on use of VL in assisting TEE probe insertion. Ishida et al compared Macintosh laryngoscope-assisted and McGrath MAC VL assisted TEE probe insertion in 100 patients undergoing cardiac surgery. The number of TEE probe insertion attempts was significantly smaller in the McGrath group than in the Macintosh group ($P = 0.039$). The success rate at the first attempt was 76% in the Macintosh group and 92% in the McGrath group. The incidence

of mucosal injury was 16% in the Macintosh group and 4% in the McGrath group (P=0.042).

Randomized study by Ozturk and Kavakli was aimed to compare the conventional technique with the use of the McGrath MAC VL for TEE probe insertion in terms of success rate, duration of insertion, and complications in patients undergoing cardiovascular surgery. The authors demonstrated that VL use increased the success rate (90.5% vs 43.9% in blind technique; p=0.016), reduced pharyngeal injury (2.4% vs 17.1% in blind technique; p=0.037). Thus, TEE probe insertion success rates appear to improve with VL technique¹¹. However, these are single centre studies primarily aimed at success rate for probe insertion.

In a cadaveric study, Jahangir and colleagues evaluated the variations in upper esophageal anatomy and location with respect to that of the larynx and its impact on TEE probe insertion. The esophageal hiatus was posterior and to the right of the trachea in most of the subjects (66%). In these patients, the traditional “forward” jaw thrust helped to open the esophageal hiatus. But some cadavers had the esophagus and trachea located almost side by side. This anatomic variation has not been reported in any patient studies so far¹³. Another study done recently by Kimomoto et al makes the case for use of VL for TEE probe insertion much stronger¹⁴. Twenty-seven junior (inexperienced group) and 10 senior (experienced group) anesthesiologists participated in this study. The TEE probe was inserted into an airway manikin in a blind fashion (blind group) or under visualization with the McGRATH (McGRATH group) video laryngoscope (three times each) This study suggested that VL may reduce the pressure on posterior pharyngeal wall during TEE insertion, regardless of clinician’s experience.



**MATERIALS AND
METHODS**



Methods

It was a prospective, single blinded, randomized controlled trial.

Setting

Tertiary care referral centre in south India

Prior approval was obtained from the Technical Advisory Committee and the Institutional Ethics Committee. Primary investigator (Observer 1) examined all the patients preoperatively and verified inclusion and exclusion criteria. A written informed consent for the study and anaesthesia was taken from all the patients. The trial was registered in the Clinical Trials registry (CTRI/2022/01/ 039313)

Rationale for patient selection

All the adult patients who underwent cardiac surgery in any of the adult Cardiac Surgery Operation Theatres (CSOT) at Sree Chitra Tirunal Institute for Medical Sciences and Technology (SCTIMST), Thiruvananthapuram and those who required TEE monitoring intra-operatively. These patients were randomised into two, viz the 'study'(V) group (videolaryngoscopic insertion)and the 'control' (C) group (blind TEE insertion). As TEE is considered to be a standard of care in the perioperative management of cardiac surgery patients and TEE probe insertion blindly is the most common technique being followed across the globe, no ethical concerns could have arose pertaining to the methodology of this study.

Inclusion Criteria

All the adult patients who came to the adult cardiac surgery operation theatre (CSOT) for surgery and those who needed intra-operative TEE monitoring and those who give consent for the study

Exclusion Criteria

1. Contraindications for TEE probe placement
2. Anticipated/ unanticipated difficult tracheal intubation, trauma during tracheal intubation
3. Patients with sore throat, oropharyngeal infection or neck pain

Recruitment

Recruitment of patients was done by the principal investigator, co-principal investigator and co-investigator. Hospital records were reviewed for eligibility. All the patients who were eligible were recruited for the study.

Sample size calculation

Previous studies had documented the incidence of oropharyngeal injury to be 15% and 5% in the C and V groups respectively: hence for adequate power, ($\alpha = 0.05$ and $\beta = 0.2$) a minimum of 138 patients in each of the groups was required. Hence, 175 patients were included per group to replace any dropouts. Thus, the sample size was 350 patients overall. Since this study was to be done across 5 centres in the country, the sample size per centre turned out to be 70 (35 in each group). Finally, to account for the drop outs, a total of 80 patients were included (40 in each of the two groups).

Data Collection Procedures

After careful assessment and written informed consent patients were considered for inclusion in the study. On patient's arrival in the operating room, a peripheral venous catheter was placed. Monitors included a 5-lead electrocardiography, pulse oximetry, invasive blood pressure, central venous pressure monitoring. In all patients, general anaesthesia was induced as per the institutional protocol. All patients were intubated using conventional rigid laryngoscope with a 7-7.5-mm inner diameter endotracheal tube for females and an 8-8.5 mm inner diameter endotracheal tube for males. The endotracheal tube was fixed to the right corner of the mouth. Anaesthesia was maintained as per the institutional protocol. After tracheal intubation, oropharyngeal secretions were suctioned out. Any blood staining or trauma during endotracheal intubation was appropriately managed and such patients were excluded from the study.

The patients were randomized by means of a computer-generated randomization order into 2 groups: conventional group (C group) and video laryngoscope group (V group). In the V group, the Medicam VL (Medicam, Mumbai, Maharashtra, India) was used for the TEE probe insertion. It is a Macintosh-type, non-channelled VL with a 60-degree viewing angle (Figure 1). The VL was inserted intraorally and after viewing the esophageal inlet, the TEE probe was advanced into the esophagus under direct vision.



Figure 1. The Medicam video laryngoscope (Medicam, Mumbai, Maharashtra, India)

In the C group, the mandible was lifted by jaw thrust and the TEE probe was inserted gently through the midline into the mouth with the right hand while the head was maintained in the neutral position. In the V group, the Medicam video laryngoscope (Medicam, Mumbai, Maharashtra, India) was inserted intraorally after viewing esophageal inlet, and the TEE probe was advanced into the esophagus under direct vision. The TEE probe was removed after performing cardiac evaluations at the end of surgery, and the tip of the probe was examined for presence or absence of blood. After TEE probe removal, all patients were examined with VL for pharyngeal injury & hematoma and the site of injury was documented with photograph. The number of attempts to insert TEE probe was also documented. In both groups, the relation of esophageal opening with respect to the laryngeal inlet was documented with photographs. These were evaluated by the anaesthesiologist blinded to the patient details. The patients were followed up till discharge for any TEE probe insertion related complications.

Oropharyngeal injury was defined as presence of blood at the tip of TEE probe at the end of surgery or any evidence of injury on VL examination at the end of surgery. The number

of attempts required for TEE probe insertion in each group was compared. The variations of esophageal opening in relation to larynx was documented in V group.

Data Analysis

Numerical data wherever appropriate was expressed using mean and standard deviation. The frequencies of observations were expressed as ratios and percentages wherever appropriate.

As described, a total of 80 patients were recruited (40 in each of the groups). All numerical data were tested for normal distribution with the Kolmogorov- Smirnov test. Differences between mean values for normally distributed variables were compared with the Student t-test. Non-normally distributed variables were compared with the Mann-Whitney U-test and Wilcoxon rank sum test. The chi- square test and Fisher exact tests were used for the categorical data as appropriate. A value of $p < 0.05$ was considered to be statistically significant. Statistical analysis was performed using SPSS version 11 statistical software (SPSS Inc., Chicago, IL).



RESULTS

Consort statement

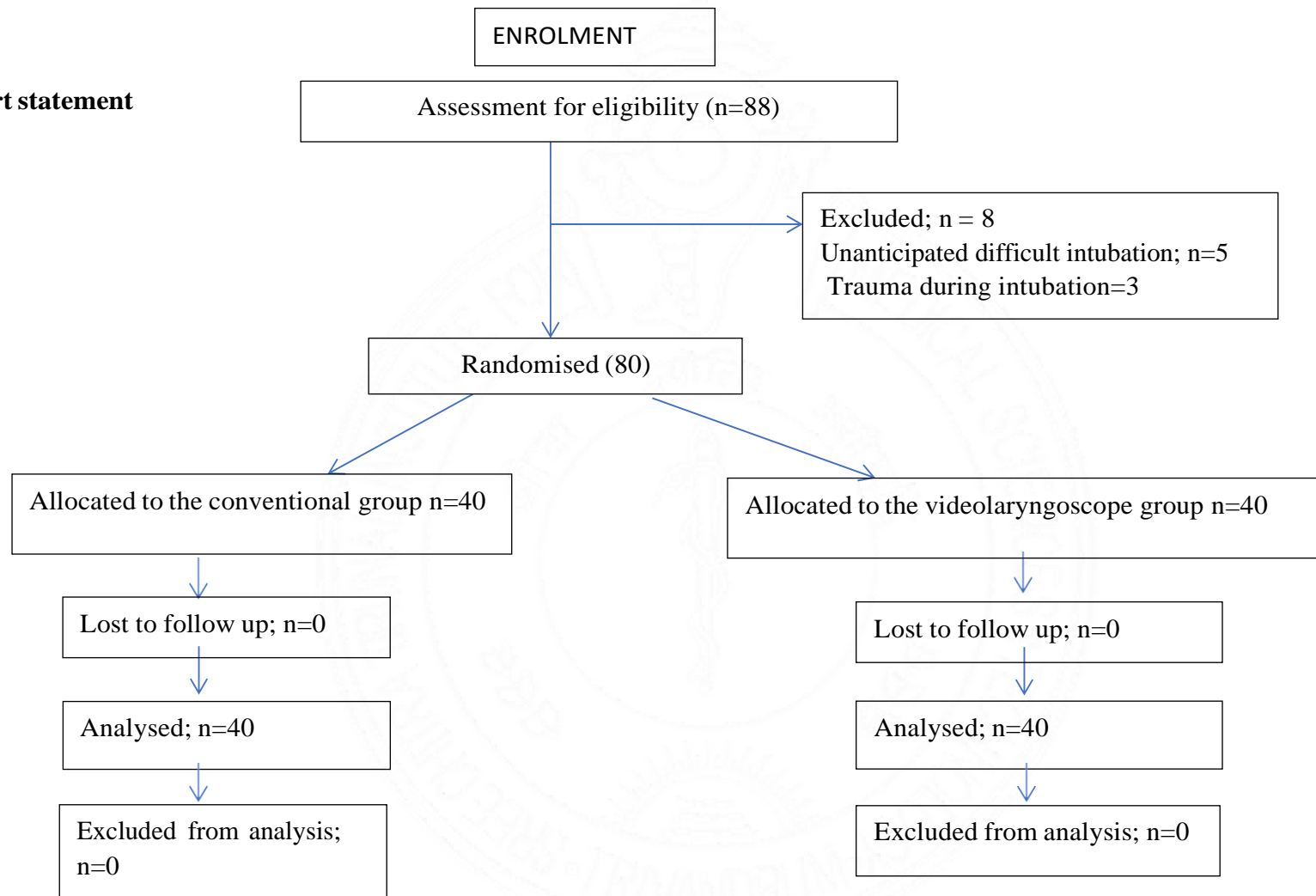


Figure 2: consort diagram

A total of 88 patients were included initially of which 5 patients had unexpected airway difficulty and 3 of them had traumatic intubation (Figure 2). Those 8 patients were hence excluded. Thus with no further exclusions, a total of 80 patients were included in the final data analysis (40 in C group and 40 in V group).

A total of 56 males and 24 females were included in the study (Figure 3).

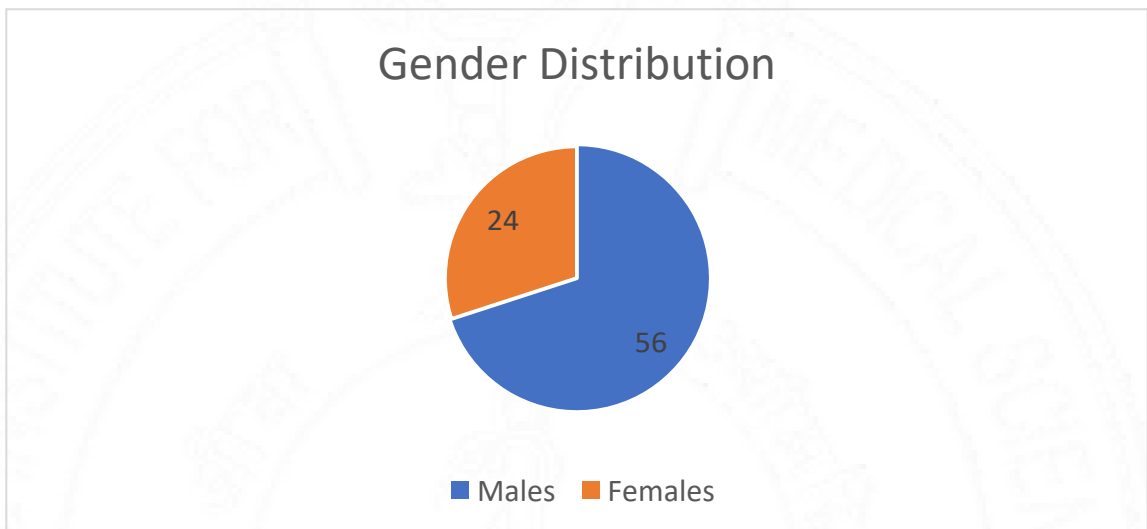


Figure 3: Gender distribution of study subjects

In the C group, a total of 26 were males, while 30 males were there in the V group. The number of females were 14 and 10 respectively in the two groups (Figure 4)

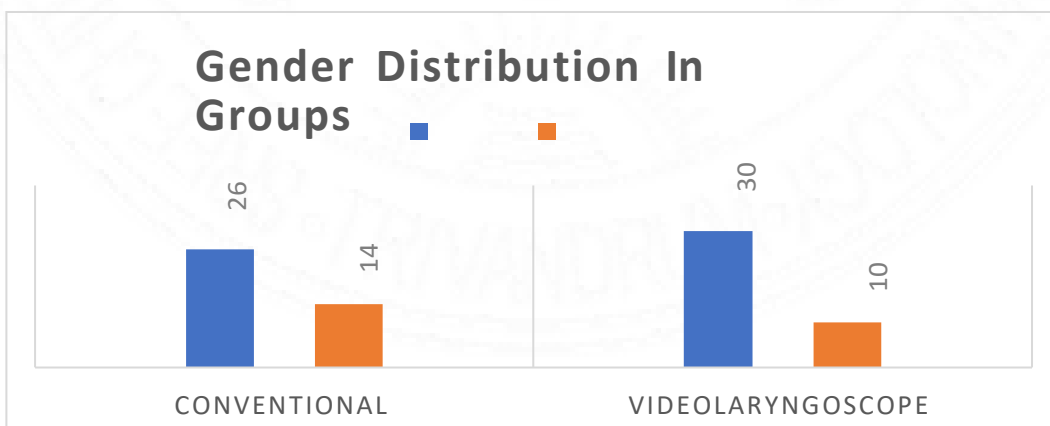


Figure 4: Gender distribution in groups C & V

The mean age (in years) was 56 ± 16 for the C group and 58 ± 16 for the V group. The mean weight was 64 ± 11.3 kgs in the C group and 66 ± 10.9 in the V group. The BMIs in these groups were 20.2 ± 1.8 and 22.4 ± 1.6 kg/m² respectively. The mean BSA (kg/m²) in the two groups were 1.68 ± 0.16 and 1.67 ± 0.14 respectively (Table 1). There are no statistical differences in demographics between the two groups.

The patients' Mallampati (MMP) grades were determined. In the C group, 14 belonged to MMP I, 24 belonged to MMP grade II and 2 patients belonged to MMP III. These numbers were 13, 22 and 5 respectively in the V group (Figure 5).

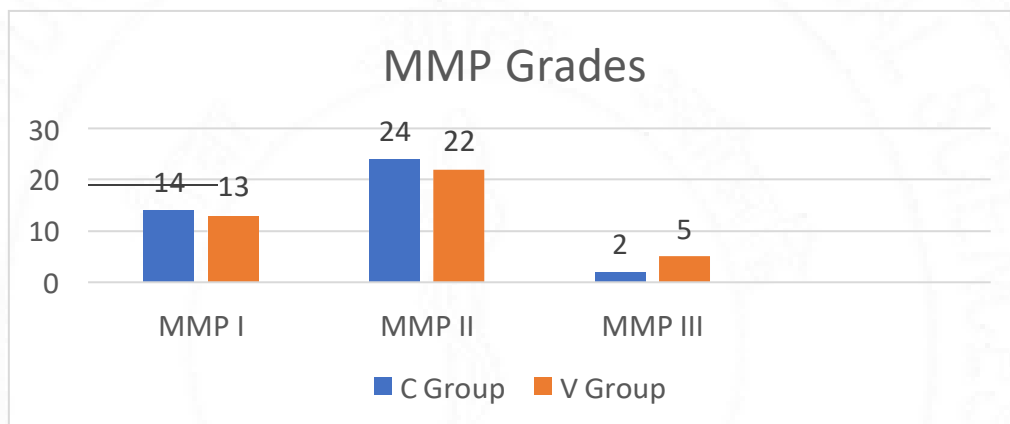


Figure 5: Mallampati Grades of both groups

Cormack Lehane (CL) grades of the patients were also noted at the time of intubation. In the C group, 20 patients belonged to CL grade I, 18 patients belonged to CL II while 2 patients had CL III. These numbers were 18, 15 and 7 respectively in the V group (Figure 6). Both groups are similar with regards airway characteristics (Table 1).

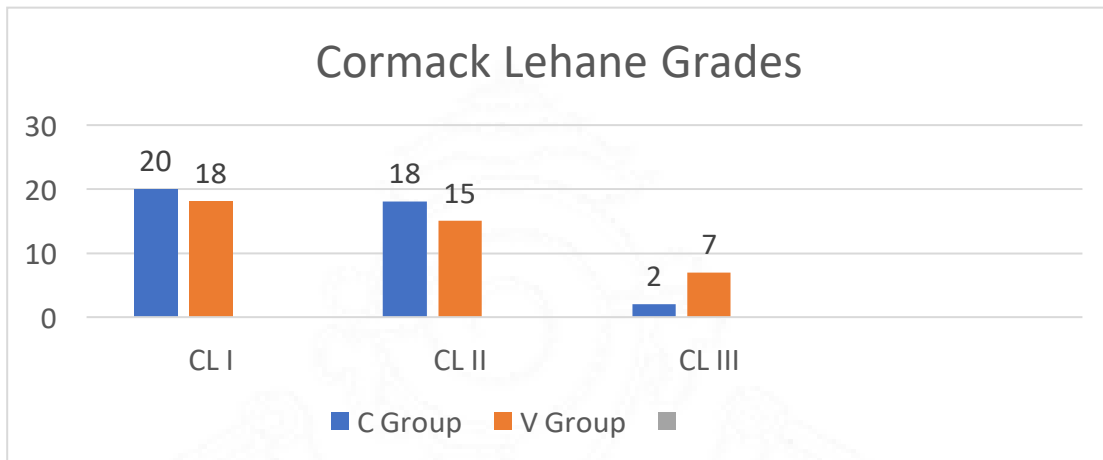


Figure 6: Cormack Lehane Grades of both groups

In the C group, 30 patients underwent CABG surgery while the remaining 10 underwent other surgeries (valve repairs, aortic procedures, ASD closures etc). The respective numbers in the V group were 25 and 15 respectively. (Figures 7 and 8)

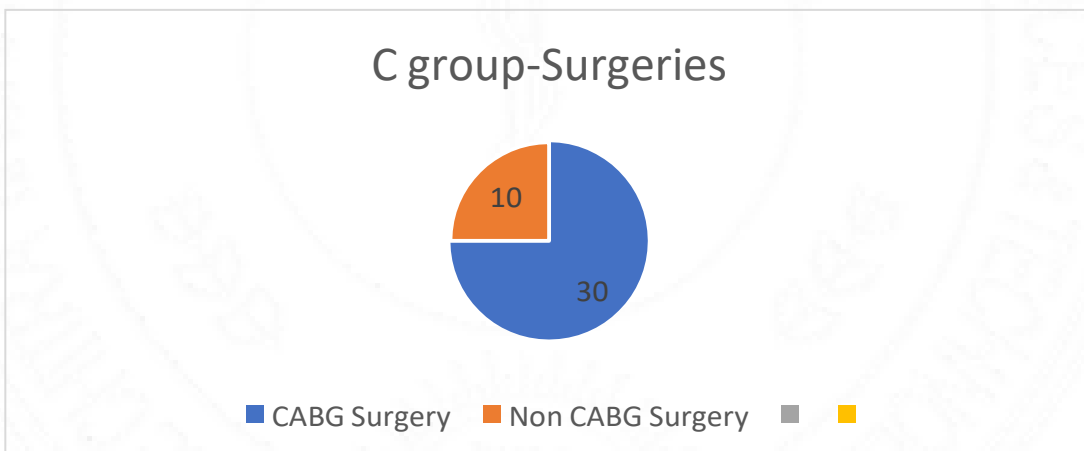


Figure 7: Distribution of surgeries in C group

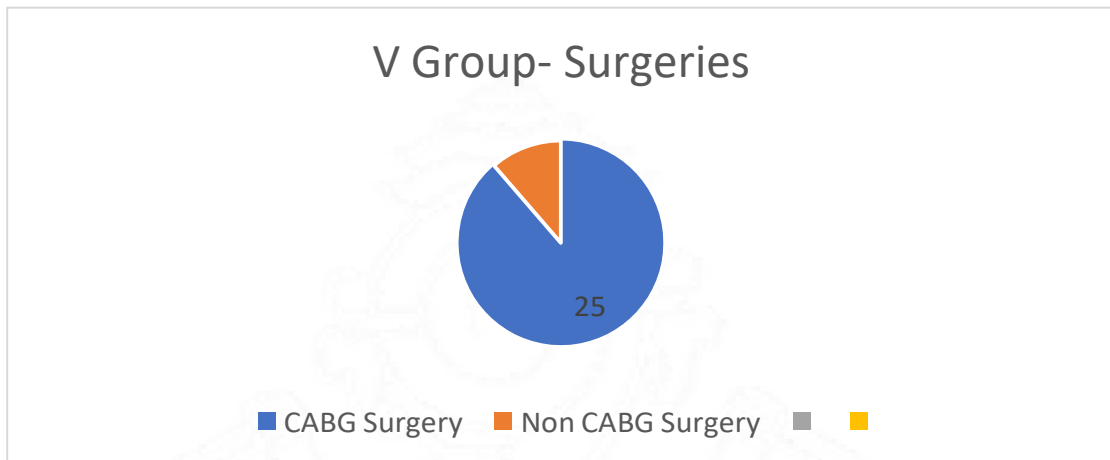


Figure 8 Distribution of surgeries in the V group

The non-CABG surgeries included the Mitral Valve Replacements (MVR), the Aortic Valve Replacements (AVR), Supra Coronary Ascending Aorta Repair (SCAAR), Bentall procedure and ASD closures. Their respective distributions are shown in the following bar diagrams (Figure 9).

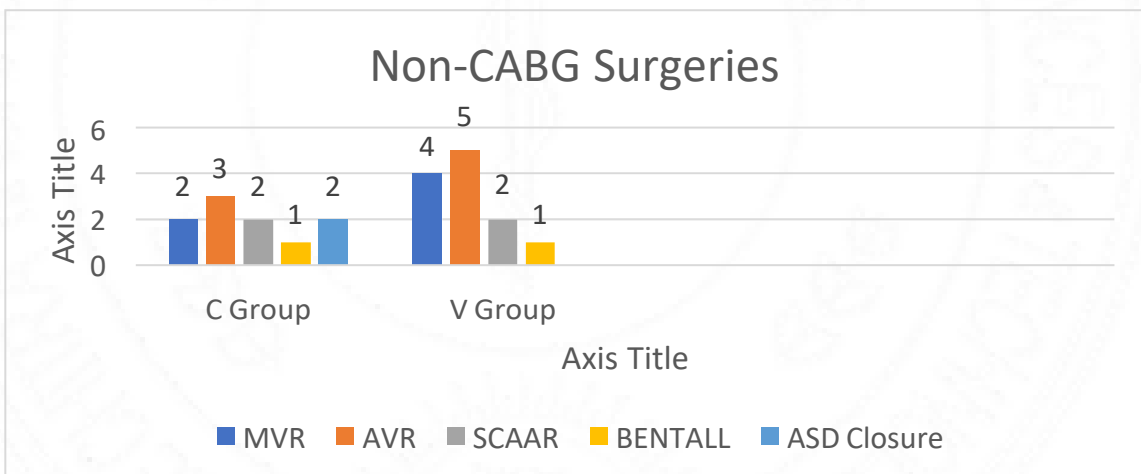


Figure 9: Distribution of non-CABG surgeries in both groups

The baseline characteristics of the study population belonging to both the groups have been tabulated below (Table 1). Parameters were compared using the tests to find out the difference between the means or difference between proportions (for numerical variables). The categorical variables were compared using the Chi square test. The population in the 2 groups were comparable in all respects.

| Variable | C Group | V Group | P Value |
|-----------------|------------------------------------|------------------------------------|----------------|
| Age (mean±SD) | 56±16 | 58±16 | 0.5 |
| Sex | Male=26 Female=14 | Male=30 Female=10 | 0.3 |
| Weight(mean±SD) | 64±11.3 | 66±10.9 | 0.4 |
| BMI (mean±SD) | 22.2±1.8 | 22.4±1.6 | 0.6 |
| BSA (mean±SD) | 1.68±0.16 | 1.67±0.14 | 0.7 |
| MMP Grade | MMP I=14 MMP II=24 MMP III=2 | MMP I=13 MMP II=22 MMP III=5 | 0.8 |
| CL Grade | CL I=20 CL II=18 CL III=32 | CL I=18 CL II=15 CL III=7 | 0.8 |
| Surgery | CABG=30 Non CABG=10 | CABG=25 Non CABG=15 | 0.6 |

Table 1: Patients demographic & airway characteristics, surgical procedures

One case of lip injury in the C group and 1 case of posterior pharyngeal wall injury was observed in the V group attributable to TEE probe insertion (Table 2). No other injuries were observed in the remaining 78 patients.

| Group | Injury | No Injury | P value |
|---------|--------|-----------|---------|
| C group | 1/40 | 39/40 | 1.000 |
| V group | 1/40 | 39/40 | |

Table 2: Study outcomes-Injuries

The incidence of injuries between the two groups was not significant (1/40 Vs 1/40; $\chi^2=0$; p=1)

In the C group, TEE probe was successfully inserted in the 1st attempt in 35 patients while the corresponding value in the V group was 33 (Figure 10). There was no significant difference in the first attempt success rate at TEE probe placement between the 2 groups (35/40 Vs 33/40; $\chi^2=0.3922$; p=0.532) (Table 3).

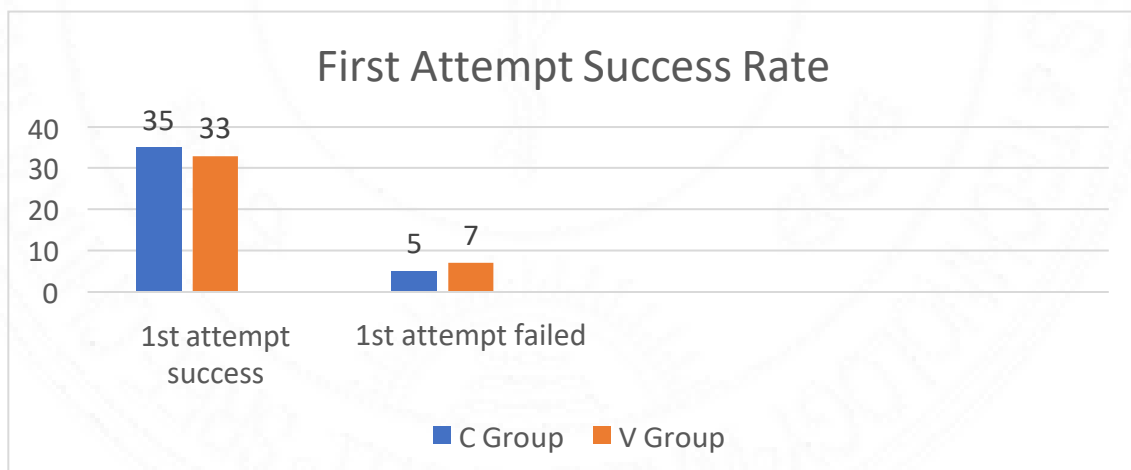


Figure 10: Study outcomes-First attempt success rate

| Group | 1 st attempt success | Chi square value | p value |
|---------|---------------------------------|------------------|---------|
| C group | 35/40 | 0.39 | 0.5 |
| V group | 33/40 | | |

Table 3 Study outcomes-first attempt success rate

In the V group, the position of the oesophageal opening with respect to the laryngeal inlet was also analysed (Figure 11). It was observed that 14 patients (35%) had their oesophageal opening directly posterior to the laryngeal inlet. The most common position of the oesophageal opening was however posterolateral to the laryngeal opening (18/40;45%). The lateral relation between the two inlets although lesser was found in 8 patients (20%) (Figure 12).

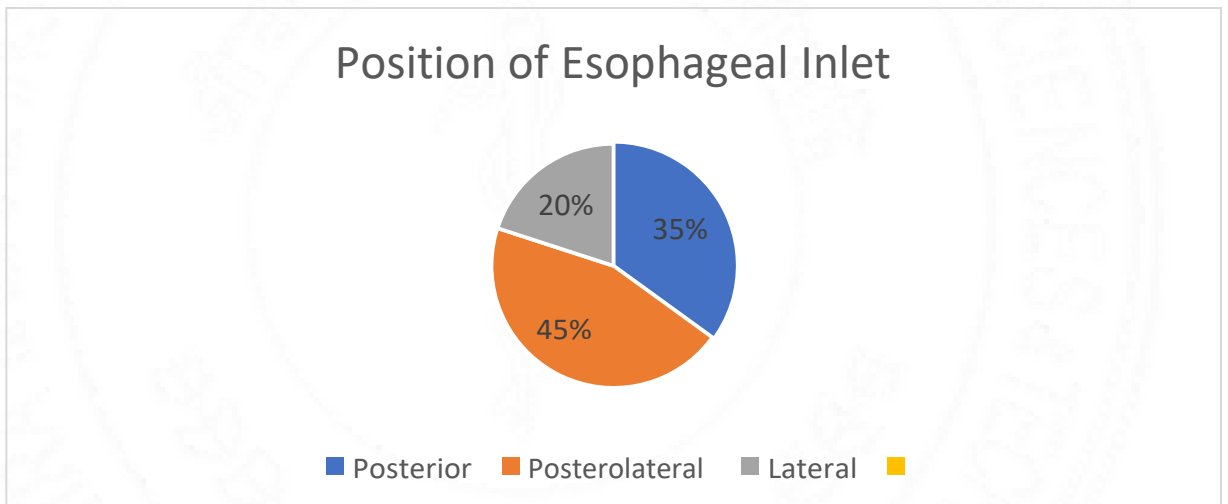
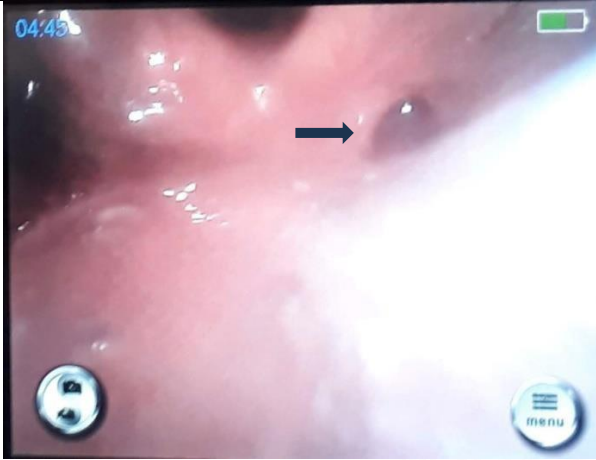
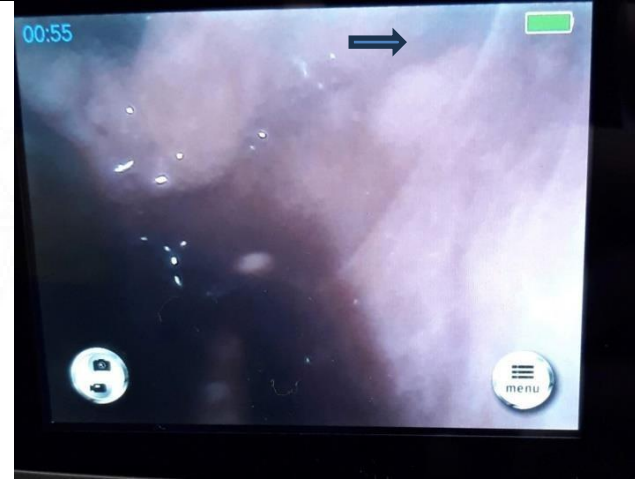

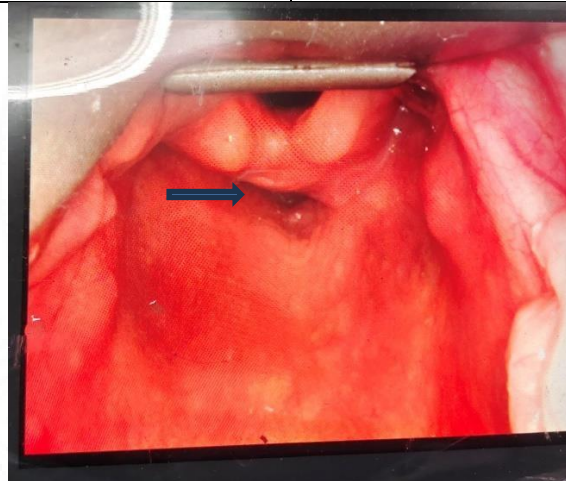
Figure 11: Esophageal inlet in relation to larynx



POSTERO LATERAL

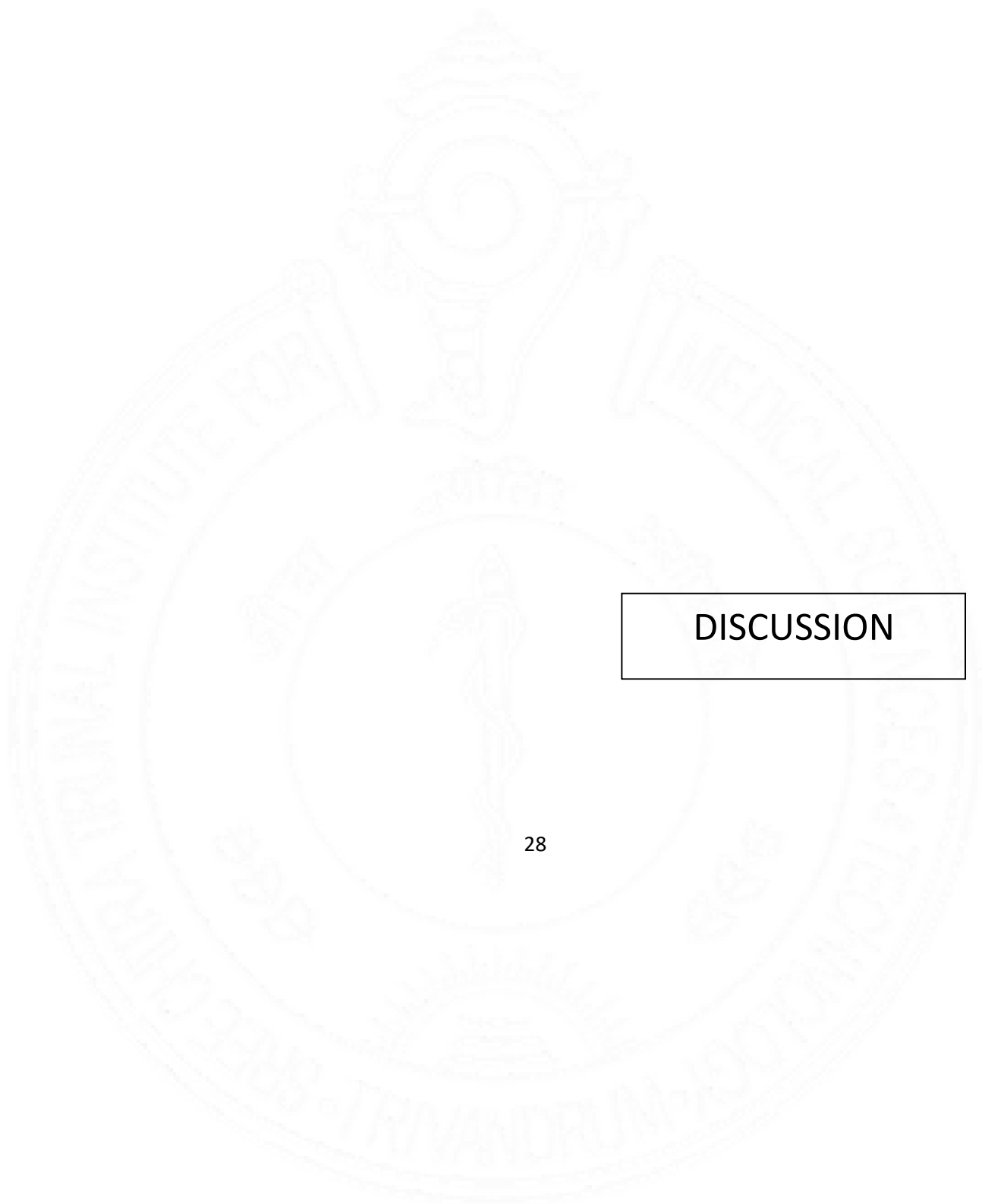

LATERAL



POSTERIOR

Figure 12: Relationship of esophageal inlet (arrow) in relation to larynx



DISCUSSION

Discussion

This prospective study had a total of 80 patients (40 in each group) for the final analysis. The patients in the two groups were comparable in all respects. It was seen from the SCTIMST arm, that the use of videolaryngoscope for TEE probe insertion didn't offer significant benefits in terms of the reduced incidence of injuries. This, was in clear contrast to the results from the multicentre trial (of which SCTIMST was one of the centres). The multicentre study showed that TEE placement under VL guidance significantly reduced the incidence of injury (26 vs 14; $p=0.029$).¹⁸ This result from the SCTIMST arm may be explained by the fact that all the clinicians who had inserted the TEE probe at SCTIMST very highly experienced (more than 15 years of experience) and held Fellowship in TEE (FTEE) certifications.

The second major finding was that there was no significant difference between the rates of first attempt success between the 2 groups in the SCTIMST arm. This again contradicted the results from the multicentre study, where there was a significant benefit with respect to the first attempt success in the V group (154 in C group Vs 176 in V group; $p=0.023$). This again might be attributed to the experience of the anaesthesiologists in addition to the fact that patients with anticipated difficult airway were not included in the study. Also, in our case, patients with MMP grade 3 were more in the V group than in the Cgroup, although it was not statistically significant.

The overall complications associated with this study (both groups included) was low in our study (2/80; 2.5%) when compared to the national multicentre study. This correlated well with the other previous studies conducted in this regard. For instance, In a retrospective audit from an Australian database, Lennon et al noticed that the incidence

of TEE probe insertion associated complications to be 1.2%². This outcome was from blind insertion of the TEE probe. Our results (more than double as compared to this study) is likely due to the reason that VL examination on probe removal would have picked up the cases of injuries which might otherwise have gone unnoticed.

In a study by Piercy et al, the overall incidence of complications was found to be 9 per 10000 patients. However, it was found that the incidence of injury was higher in patients older than 70 years (RR =3.3, p=0.03)³. The result from our study also corroborates this finding. In the study from the SCTIMST arm, both the cases of injuries were reported from patients more than 65 years of age. This further points to the fact that extra caution may be warranted at the time of TEE probe insertion in the elderly patients.

That caution has to be exercised by clinicians while attempting a TEE probe insertion cannot be over emphasized. In a study by Ramalingam et al, it was found that the likelihood of development of serious complications was extremely low (1 in 1000). However, the authors noted that with the development of a serious complication (eg oesophageal injury), the mortality rates were as high as 40%⁴. This finding underlines the need to follow up the patients to rule out these complications as they may occur much later after the TEE probe removal. In our study, we followed up the patients for a period of 1 week to rule out any complications secondary to the TEE probe insertion.

A study by Sandeep et al showed that TEE associated perforations occurred more commonly in elderly females and that the thoracic esophagus was the segment most commonly involved. It was also found that the patients with thoracic esophageal perforations presented rather late; usually after 48 hours⁵. This further justifies the follow up period of 1 week as per our study protocol. Although no incidence of esophageal

perforation was noted in our cases, the authors would like to believe that the late presentation of esophageal perforation could be detected by allowing the time period of 1 week. In the same study, Sandeep et al observed that the development of shock due to TEE-related esophageal perforation was invariably associated with a higher mortality (RR=3.8, p=0.02). In our study, extreme care was taken to avoid any such serious complications. The authors had also observed the hemodynamic parameters before the TEE probe placement, at the time of TEE placement and 3 minutes after the probe placement. This would have helped at least in part to pick up the early cases of esophageal perforations.

In a study by Pieters et al, it was shown that the oropharyngeal mucosal tear occurred less commonly when the VL was used for intubation (OR=0.16, p=0.02)⁶. Although the SCTIMST arm of the study found no reduction in mucosal tears with VL, the national study result confirmed this finding. It was observed that the mucosal injuries were significantly lesser in the V group (20% vs 35%; p=0.03). This further suggested that the use of VL might reduce the overall incidence of mucosal injury which was otherwise not infrequent with TEE insertion.

In a manikin study by Kimamoto et al, it was reported that VL guided TEE probe insertion significantly reduced the pressure on the posterior pharyngeal wall.⁷ This might explain the decreased incidence of posterior pharyngeal wall injury as seen in the multicentre trial. In our study, there was posterior pharyngeal wall injury in 1 patient in the V group and no such injury in C group. This low incidence only pointed that the clinicians were well versed with blind technique of TEE probe insertion. Additionally, the clinicians at SCTIMST resorted to 'Reverse Sellick's manoeuvre' (pulling the cricoid cartilage gently away from esophagus)

when they encountered resistance during probe insertion. This technique was published from SCTIMST in 2007¹⁹. This arguably helped in negotiating the TEE probe through the oropharynx into the oesophagus.

A study on 9 cadavers done by Jahangir et al showed that the position of the esophageal inlet with respect to the laryngeal opening to be highly variable. They observed that, in majority of patients (67%), the esophagus was posterolateral. In such patients the forward jaw thrust was found to be useful in the TEE probe insertion. In 2 cadavers, the esophageal and the laryngeal inlets were found to be located side by side. In such patients, the conventional jaw lift failed in successful TEE probe placement. In such cases, pulling the jaw to the left was found to aid in the smooth passage of the TEE probe into the esophagus. The authors thus concluded that early identification of such anatomical variations prior to the TEE probe insertion would help in successful placement of the TEE probe by allowing the clinicians to choose the appropriate maneuver¹⁴.

The scope of our study lies in the fact that the observations made by Jahangir et al had not been ever done on live patients. Use of VL in our study helped in describing the relationship between the two structures. In the V group, the VL helped in guiding the TEE probe into the esophagus under visualisation in addition to describing the position. In the SCTIMST arm of the study, we found that a majority of patients had a posterolateral location of the oesophagus (18;45%) while 14 patients (35%) had the oesophageal opening directly posterior. The remaining 8 patients had their laryngeal inlets located in the lateral position. These values were found to correlate well with those from the multicentre trial. These values were 47%, 45% and 12% respectively in the multicentre trial. It also validates the

fact that the posterolateral location of the esophagus is the most common. Further prospective studies however are needed to establish these facts beyond doubt.

Limitations of the study

- This study was limited to complications related to TEE probe insertion and did not assess other injuries related to repeated manipulations or thermal injury
- This study was not powered for assessing major injuries such as esophageal or gastric perforation, which often necessitate evaluation and additional interventions
- The use of esophagogastroduodenoscopy, the modality of choice for such evaluation, was not part of the present study.
- Patients with anticipated difficult airway who are likely to have distorted esophagus-laryngeal relations were excluded from the study

Future Prospects

Larger multi centre trials will further validate the study results. Once the beneficial effects of the VL in successfully placing the TEE probe is established, guidelines and recommendations with regard to the same can be formulated. All these will go a long way in improving the patient safety further. Also, the beneficial effect of VL (if any) in placing the TEE probe in cases of difficult airways and abnormal facial morphology needs to be established. Likewise, of the multiple types of the VLs available in the market, the one that is best suited for TEE probe insertion is not known. Although this study proved that the posterolateral oesophageal inlet was most common, the incidence of right posterolateral Vs left posterolateral oesophageal inlet is not yet known. Once established,

it would allow the clinicians to device newer maneuvers to successfully guide the TEE probe into the esophagus with a little effort.





CONCLUSIONS

Conclusions

1. Videolaryngoscopes may not have a beneficial effect in the successful TEE placement with respect to the first attempt success and the incidence of injuries.
2. The overall incidence of TEE related injuries is low overall.
3. Older patients have a higher likelihood of suffering injuries during the TEE placement.
4. There exists considerable variation in the relative locations of the esophageal and the laryngeal inlets.
5. Although posterolateral oesophageal inlet seems to be more common, the relative frequencies of the right vs left posterolateral esophageal inlet is not known.
6. The best VL with regard to the successful TEE probe placement is not known.
7. Large multi centred randomised trials are essential to find out the missing links.



BIBLIOGRAPHY

Bibliography

1. Piercy M, McNicol L, Dinh DT. Major complications related to the use of Transesophageal Echocardiography in cardiac surgery. *Journal of Cardiothoracic and Vascular Anesthesia*, 2009; 23: 62-5.
2. Lennon MJ, Gibbs NM, Weightman WM et al. Transesophageal Echocardiography–related gastrointestinal complications in cardiac surgical patients. *Journal of Cardiothoracic and Vascular Anesthesia*, 2005; 19:141-5.
3. Huang CH, Lu CW, Lin TY et al. Complications of intraoperative Transesophageal Echocardiography in adult cardiac surgical patients—Experience of two institutions in Taiwan. *J Formos Med Assoc* 2007; 106(1):92–5.
4. Purza R, Ghosh S, Walker C et al. Transesophageal Echocardiography complications in adult cardiac surgery: A retrospective cohort study . *Ann Thorac Surg* 2017;103:795–803.
5. Ramalingam G, Choi SW, Agarwal S et al. Complications related to peri-operative transoesophageal echocardiography – a one-year prospective national audit by the Association of Cardiothoracic Anaesthesia and Critical Care. *Anaesthesia* 2020, 75, 21–6.
6. Pieters BMA, Maas EHA, Knape JTA et al. Videolaryngoscopy vs. direct laryngoscopy use by experienced anaesthetists in patients with known difficult airways: a systematic review and meta-analysis. *Anaesthesia* 2017, 72, 1532–41.
7. Hirabayashi Y, Okada O, Seo N. Airtraq Laryngoscope for the Insertion of a Transesophageal Echocardiography Probe. *Journal of Cardiothoracic and Vascular Anesthesia*, Vol 2008; 22: 331-2.

8. Ammar KA, DuCanto J. Optically guided transoesophageal echocardiography probe insertion: what are we waiting for? *European Journal of CV Imaging* doi:10.1093/ehjci/jex101.
9. Riley RH, Rajwani A, Droste FH et al. Videolaryngoscopy to aid transoesophageal echocardiography probe insertion. *Anaesthesia and Intensive Care*. DOI: 10.1177/0310057X20905608.
10. Kim MK, Park SW, Sim Y et al. Use of a McGrath Videolaryngoscope to assist Transesophageal Echocardiography probe insertion in anesthetized patients. *Journal of Cardiothoracic and Vascular Anesthesia*
<http://dx.doi.org/10.1053/j.jvca.2014.09.007>.
11. Ozturk NK, Kavakli AS. Use of McGrath MAC Videolaryngoscope to assist Transesophageal Echocardiography probe insertion in intubated patients. *Journal of Cardiothoracic and Vascular Anesthesia* 2017; 31: 191–6.
12. Ishida T, Kiuchi C, Sekiguchi T et al. McGRATH MAC video laryngoscope for insertion of a transoesophageal echocardiography probe -A randomised controlled trial. *Eur J Anaesthesiol* 2016; 33:263–8.
13. Jahangir A, Shah, Ahmad MM et al. Visually guided TEE probe insertion, making a case based on anatomic variation: A cadaveric study. *Echocardiography*. 2018;35:1616–20.
14. Kumamoto T, Tashima K, Hiraoka C et al. McGRATH MAC video laryngoscope assistance during transesophageal echocardiography may reduce the risk of complications: a manikin study. *BMC Anesthesiology* (2021) 21:14.
15. Sainathan S, Andaz S. A systematic review of Transesophageal Echocardiography-induced esophageal perforation. *Echocardiography* 2013;30:977-83.

16. Na SW, Kim CS, Kim JY et al. Rigid laryngoscope-assisted insertion of Transesophageal Echocardiography probe reduces oropharyngeal mucosal injury in anesthetized patients. *Anesthesiology* 2009; 110:38 – 40.
17. Chang JE, Min SW, Kim CS et al. Effect of jaw thrust on Transesophageal Echocardiography probe insertion and concomitant oropharyngeal injury. *Journal of Cardiothoracic and Vascular Anesthesia* 2015;29: 1266–71.
18. Borde D, C K, Jasapara A, Shetty V, Juvekar N, Desurkar V, Gaidu J, Joshi P, Asegaonkar B, Kp U, V V, Joshi S, Koshy T. Use of a Video Laryngoscope to Reduce Complications of Transesophageal Echocardiography Probe Insertion: A Multicenter Randomized Study. *J Cardiothorac Vasc Anesth.* 2022 Dec;36(12):4289-4295. doi: 10.1053/j.jvca.2022.07.017. Epub 2022 Jul 21. PMID: 36038439.
19. Sinha PK, Koshy T. Reverse Sellick's maneuver for transesophageal echocardiographic probe placement. *J Cardiothorac Vasc Anesth.* 2007 Aug;21(4):626-8. doi: 10.1053/j.jvca.2006.10.010. Epub 2007 Jan 9. PMID: 17678806.



APPENDICES

Appendix A

Proforma

Use Of Video Laryngoscope To Reduce Complications Of Trans Esophageal
Echocardiography Probe Insertion: A Multicentre Randomized Study.

PROFORMA

Group: Conventional Laryngoscope/ Video Laryngoscope

Randomisation Code: __/__/__ (As per Randomisation Chart)

Hospital Name: _____

Date: __/__/____

Patient Name: _____

Hospital

ID: _____

Age: _____ Sex: _____ Height: _____ Weight: _____ BSA: _____

BMI: _____

Surgery: CABG/ MVR/AVR/DVR/ Aorta/ Others

(specify) _____

Preop Anti platelets/Anti Coagulants: Stopped/ ASA/ Clopidogrel/ Ticagrelor/ Warfarin

Mallampati Grade: I/ II/ III/IV

Before Probe Insertion: HR/SBP/DBP/MBP= __/__/__/__

During Probe Insertion: HR/SBP/DBP/MBP= __/__/ __/ __

3 Min after Probe Insertion: HR/SBP/DBP/MBP= __/__/__/ __

CL Grade on laryngoscopy for endotracheal intubation: I/ II/ III/ IV

Insertion attempts for TEE Probe: 1/ 2/ 3

Just Before Probe Insertion Photograph Taken in VL group: Date: __/__/__ &
Time __/__/__; Upper Esophageal Opening visualized: Y/N

Relation of Upper Esophageal Opening with Larynx: Posterior/ Posterior Lateral/ Lateral

After TEE Probe Removal Photograph: Date: __/__/__ Time: __/__/__

At end of procedure blood at tip of TEE probe: Y/N

At the end of procedure VL Scopy for Injury: No injury/ Dental Injury/ Posterior
Pharyngeal wall/ Piriform Sinus/ Tonsils/Epiglottis/ Post cricoid area/ Esophageal Inlet/

Any other Specify _____



श्री चित्रा तिरुनाल आर्युविज्ञान और प्रौद्योगिकी संस्थान, त्रिचेन्द्रम
तिरुवनन्तपुरम - ६९५०११, केरल, इंडिया

SREE CHITRA TIRUNAL INSTITUTE FOR MEDICAL SCIENCES AND TECHNOLOGY, TRIVANDRUM

Thiruvananthapuram - 695 011, Kerala, India

(An Institute of National Importance under Govt. of India)

Grams : Chitramet, Phone : +91-471-2443192, Fax : +91-471-2550720/2446433, E-mail : sc@scitinst.ac.in, Website : www.scitinst.ac.in

Institutional Ethics Committee

(IEC Regn No. ECR/189/Inst/KL/2013/RR-21)

SCT/IEC/1889/MAY/2022

01.09.2022

Dr. Vipin Raj V
Senior Resident
Department of Anaesthesiology
SCTIMST, Thiruvananthapuram

Dear Dr. Vipin Raj,

The Institutional Ethics Committee held on 13th May, 2022, reviewed and discussed your application to conduct the study titled "USE OF VIDEO LARYNGOSCOPE TO REDUCE COMPLICATIONS OF TRANSESOPHAGEAL ECHOCARDIOGRAPHY PROBE INSERTION: A MULTICENTRE RANDOMISED CONTROLLED STUDY" (IEC/1889).

The following members of the Ethics Sub-committee were present at the meeting held on 13th May, 2022.

| SL. No. | Member Name | Highest Degree | Gender | Scientific /Non Scientific | Affiliation with Institution(s) |
|---------|----------------------|-------------------------|--------|--|---------------------------------|
| 1. | Dr. Pradeep S | MBBS, MD | Male | Basic Medical Scientist | No |
| 2. | Smt. Sathi Nair | MA (English Literature) | Female | Lay Person | No |
| 3. | Dr. Christina George | MD Psychiatry | Female | Clinician | No |
| 4. | Dr. P. Manickam | BSMS, MSc (Epid), PHD | Male | Health Science Expert/ Social Scientist | No |
| 5. | Adv. Priya Kaimal | LLM, MBL | Female | Legal Expert | No |
| 6. | Dr. Manikandan.S | MBBS,MD,PDCC | Male | Clinician | Yes |
| 7. | Dr. Srinivas G | PHD | Male | Basic Medical Scientist (Member Secretary) | Yes |

The following documents were reviewed:Original submission

1. Responses/Amendments made based on the Reviewer's comments Checklist Form
2. Covering letter addressed to the Chairman, IEC, SCTIMST dated 20.11.2021
3. IEC Application Form
4. Declaration form
5. Project Proposal
6. Proforma
7. Patient Information Sheet in English and Malayalam
8. Definition and Informed Consent Form in English and Malayalam
9. CV of PI and Co-PIs
10. SRC Recommendation Letter

Revised submission

1. Covering letter addressed to the Member Secretary, IEC, SCTIMST
2. Copy of IEC Recommendation Letter dated 04.06.2022
3. Approval letter from Madras Medical Mission, Chennai dated 01.12.2021
4. Approval letter from Deenanath Mangeshkar Hospital & Research Centre, Pune dated 04.08.2021
5. Approval letter from Fortis Hospitals Limited, Mumbai dated 20.11.2021
6. Approval letter from Seth Nandlal Dhoot Hospital, Aurangabad dated 14.05.2021
7. Copy of the CTRI Registration Form
8. Responses/Amendments made based on the Reviewer's comments Checklist Form
9. Covering letter addressed to the Chairman, IEC, SCTIMST dated 20.11.2021
10. IEC Application Form
11. Declaration form
12. Project Proposal
13. Proforma
14. Patient Information Sheet in English and Malayalam
15. Definitions and Informed Consent Form in English and Malayalam
16. CV of PI and Co-PIs
- 17.

IEC Decision

The IEC approved the conduct of the study in the present form.

Remarks:

The Institutional Ethics Committee expects to be informed about the progress of the study, any SAE occurring in the course of the study, any changes in the protocol and patient information/informed consent and asks to be provided a copy of the final report.

There was no member of the study team who participated in voting / decision making process. The ethics committee is organized and operated according to the requirements of Good Clinical Practice and the requirements of the Indian Council of Medical Research (ICMR).

Sincerely,



Dr. G. Srinivas
Member Secretary, IEC

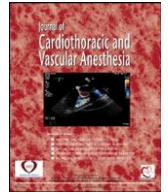


MEMBER SECRETARY
INSTITUTIONAL ETHICS COMMITTEE (IEC)
SCTIMST, THIRUVANANTHAPURAM



Contents lists available at ScienceDirect

Journal of Cardiothoracic and Vascular Anesthesia

journal homepage: www.jcvaonline.com

Original Article

Use of a Video Laryngoscope to Reduce Complications of Transesophageal Echocardiography Probe Insertion: A Multicenter Randomized Study



Deepak Borde, MD, DNB, FCA, FTEE^{a,*},
 Kumar C, MD, PDCC, FTEE^b,
 Amish Jasapara, MD, FTEE, FCA (EACTA)^c,
 Vijay Shetty, MD, DNB, PDCC^c,
 Nilesh Juvekar, MD, DNB, PDCC, FIACTA, FTEE^d,
 Vinayak Desurkar, MD, PDCC, FRCA^d,
 Jyoti Gaidu, MD, FIACTA, FTEE^d,
 Pooja Joshi, MD, FIACTA, FTEE^a, Balaji Asegaonkar, MD, DNB^a,
 Unnikrihnan KP, MD, FTEE, FASE^e, Vipinraj V, MD, DM^e,
 Shreedhar Joshi, MD, FCA, DM, FTEE^f,
 Thomas Koshy, DA, MD, PDCC, FICATA, FTEE, FRCP (Edin)^e

^aDepartment of Cardiac Anesthesia, Ozone Anesthesia Group, Aurangabad, Maharashtra, India

^bDepartment of Cardiac Anesthesia, Madras Medical Mission, Chennai, Tamilnadu, India

^cDepartment of Cardiac Anesthesia, Fortis Hospitals, Mulund, Mumbai, Maharashtra, India

^dDepartment of Cardiac Anesthesia, Deenanath Maneshkar Hospital, Pune, Maharashtra, India

^eDepartment of Cardiac Anesthesia, Sree Chitra Tirunal Institute of Medical Sciences and Technology,

Trivandrum, Kerala, India

^fDepartment of Cardiac Anesthesia, Narayana Institute of Cardiac Sciences, Bengaluru, Karnataka, India

Objective: The objective of this multicenter study was to test the hypothesis of whether the use of a video laryngoscope (VL) reduces complications related to transesophageal echocardiography (TEE) probe insertion.

Design: A multicenter randomized control study.

Setting: At 5 tertiary care level hospitals.

Participants: Three hundred sixty-three adult patients undergoing elective cardiac surgery.

Interventions: The patients were randomized into 2 groups—the conventional group (C group; n = 177) and the VL group (n = 186) for TEE probe insertion.

Measurements and Main Results: The primary endpoint of the study was the incidence of oropharyngeal injury, which was defined as blood at the tip of the TEE probe at the end of surgery and/or evidence of injury on VL examination at the end of surgery. The secondary endpoints of the study were the number of attempts required for successful TEE probe insertion and the relation between the esophageal inlet and the larynx. There was a higher incidence of injuries in the C group (n = 26; 14.7%) compared to the VL group (n = 14; 7.5%; p = 0.029). The number of attempts for probe insertion was significantly lower in the VL group (p = 0.0023). The most common relation between the esophageal inlet and the larynx was posterolateral (n = 88; 47%), followed by posterior (n = 77; 41%) and lateral (n = 21; 12%).

The research described was presented at the Indian Association of Cardiovascular and Thoracic Anesthesiologists Annual Meeting 2022 in Madurai, India.

*Address correspondence to Deepak Prakash Borde, MD, DNB, Department of Cardiac Anesthesia, Ozone Anesthesia Group, First Floor, OPD Wing, United CIIGMA Hospital, Shahnoorwadi, Aurangabad, Maharashtra, India 431001.

E-mail address: deepakborde2482@gmail.com (D. Borde).

<https://doi.org/10.1053/j.jvca.2022.07.017>

1053-0770/© 2022 Elsevier Inc. All rights reserved.

Conclusion: The use of VL was associated with a lesser incidence of injury compared to the conventional technique, and its use for this purpose is recommended. The use of VL for probe insertion resulted in fewer attempts compared with the conventional technique. Significant variations do exist in the relation between the esophageal inlet and the larynx, and direct visualization with VL may contribute to better safety.

© 2022 Elsevier Inc. All rights reserved.

Key Words: video laryngoscope; TEE; TEE-related injuries

TRANSESOPHAGEAL ECHOCARDIOGRAPHY (TEE) has emerged as a major monitoring tool in the recent past, and now has been established as an integral part of all modern cardiac surgery operating rooms. Monitoring with TEE generally is considered a safe procedure. Earlier retrospective studies have reported low complication rates (0.03%–1.4%).^{1–4} A recent prospective nationwide audit of 22,314 TEE examinations from the United Kingdom observed an incidence of major complications associated with TEE to be 0.08% (1:1300 examination) and a high probability of death (>40%) once such complications develop.⁵ Hence, clinicians must take every possible precaution to avoid these complications.

Video laryngoscopy (VL) has evolved in the recent past and is now considered an important constituent of the armamentarium of difficult airway equipment for anesthesiologists.^{6,7} A recent meta-analysis of 179 studies concluded that VL reduced the incidence of failed intubation and improved glottic view, with an almost similar time to intubation as compared to conventional direct laryngoscopy in a diverse population of adult patients undergoing intubation for both elective and emergency procedures.⁸ Various single-case reports have demonstrated the utility of the VL for difficult TEE probe insertion.^{9–12} In a recent randomized study, the use of VL increased the success rate of TEE probe insertion compared to conventional blind insertion in patients undergoing cardiac surgery.¹³ Also, VL provided a better view of the esophageal inlet and required fewer attempts at insertion compared to the conventional laryngoscopy technique.¹⁴ These were single-center studies to reduce the number of attempts required for TEE probe placement. Moreover, they were not powered adequately to detect a reduction in the incidence of injuries.

The objective of this multicenter study was to test the hypothesis of whether the use of VL reduces injuries related to TEE probe insertion.

Methods

This study was a multicenter, prospective, randomized controlled study conducted in India. The study protocol was approved by the Institutional Review Board from all 5 collaborating hospitals. Written informed consent was obtained from all participants. This study was registered as CTRI/2022/01/039313 at the Clinical Trials Registry of India (www.ctri.nic.in), which is a free and online public record system for the registration of clinical trials being conducted in India.

Patients aged 18-to-70 years of either sex undergoing elective cardiac surgery requiring TEE examination were enrolled. Valid written and informed consent was obtained from all participants. The exclusion criteria were as follows: any

contraindications for TEE insertion, patients with deranged coagulation parameters (prothrombin time as measured by patients with international normalized ratio >2, platelet count <100,000/mm³), anticipated or unanticipated difficult tracheal intubation, trauma during tracheal intubation, and patients with a sore throat, oropharyngeal infection, or neck pain.

After careful assessment and written informed consent, patients were considered for inclusion in the study. On arrival of the patient in the operating room, a peripheral venous catheter was inserted. Standard monitoring included 5-lead electrocardiography, pulse oximetry, invasive blood pressure, and central venous pressure monitoring. In all patients, general anesthesia was induced as per respective institutional protocol. All patients were intubated using a conventional rigid laryngoscope with an appropriately-sized endotracheal tube. The endotracheal tube was fixed to the left corner of the mouth. Anesthesia was maintained as per respective institutional protocol. After tracheal intubation, oropharyngeal secretions were suctioned. If there was blood staining, trauma due to tracheal intubation was diagnosed, and the patient was excluded from the study.

The patients were randomized by means of a computer-generated randomization order into the following 2 groups: the conventional group (C group) and the VL group. An experienced (>5 years of experience in cardiac anesthesia) board-certified TEE cardiac anesthesiologist performed the TEE probe insertion as per availability in the respective hospitals. In the C group, the mandible was lifted and flexed by putting the thumb of the left hand (whenever appropriate) into the mouth. The TEE probe was inserted gently through the midline into the mouth with the right hand while the head was maintained in a neutral position. In the VL group, the Medicam VL (Medicam, Mumbai, Maharashtra, India) was used for the TEE probe insertion. It is a Macintosh-type, non-channeled VL with a 60-degree viewing angle (Fig 1). The VL was inserted intraorally and after viewing the esophageal inlet, and the TEE probe was advanced into the esophagus under direct vision (Video 1). The TEE probe was removed after performing cardiac evaluation at the end of surgery, and the probe tip was examined for the presence or absence of blood. After TEE removal, all patients were examined with Medicam VL for pharyngeal injury and hematoma, and the site(s) of injury was documented. The Medicam company provided the Medicam VL for study purposes. However, the company was not involved in the study design, and they did not have access to the data of the study. The company did not participate in the study results analysis. The patients were followed up until discharge for any TEE probe insertion-related complications.



Fig 1. The Medicam video laryngoscope (Medicam, Mumbai, Maharashtra, India).

The number of attempts to insert the TEE probe was documented by an anesthesiologist blinded to the patient details. In the VL group, the relation between the esophageal inlet and the larynx was documented with a photograph. The photographs of the VL group were examined to determine the relationship between the esophageal inlet and the larynx, and classified as posterior, posterolateral, or lateral by a blinded anesthesiologist. The primary endpoint of the study was the incidence of oropharyngeal injury, which was defined as blood at the tip of the TEE probe at the end of surgery, and/or

evidence of injury (to the oropharynx, faucial pillars, soft palate, or esophageal inlet) on the VL examination at the end of surgery. The secondary endpoints of the study were the number of attempts to successfully insert the TEE probe and the variations of the esophageal inlet in relation to the larynx.

Previous studies^{13,14} have documented the incidence of oropharyngeal injury in 15% of patients in the C group and 5% in the VL group; the power calculation ($\alpha = 0.05$ and $\beta = 0.2$) indicated a minimum of 138 patients for each group. Hence, 175 patients were included per group to replace any dropouts, and the sample size was calculated as 350 patients. All numerical data were tested for normal distribution with the Kolmogorov-Smirnov test. Differences among mean values for normally distributed variables were compared with the student *t*-test. Nonnormally distributed variables were compared with the Mann-Whitney *U*-test and Wilcoxon rank-sum test. The chi-square test and Fisher exact test were used for categorical data when appropriate. A value of $p < 0.05$ was considered statistically significant. Statistical analysis was performed using SPSS version 11 statistical software (SPSS Inc, Chicago, IL).

Results

During the study period from January to April 2022, a total of 373 patients were enrolled. Ten patients were excluded from the study because of unanticipated difficult intubation (5 patients) and trauma during intubation, as evidenced by the blood during suctioning after intubation (5 patients). The final analysis included 363 patients, with 177 patients in the C group and 186 patients in the VL Group, as shown in Figure 2.

The baseline characteristics of patients in both groups were not statistically different, as shown in Table 1. In all, 40 patients (11%) sustained injury related to the TEE probe

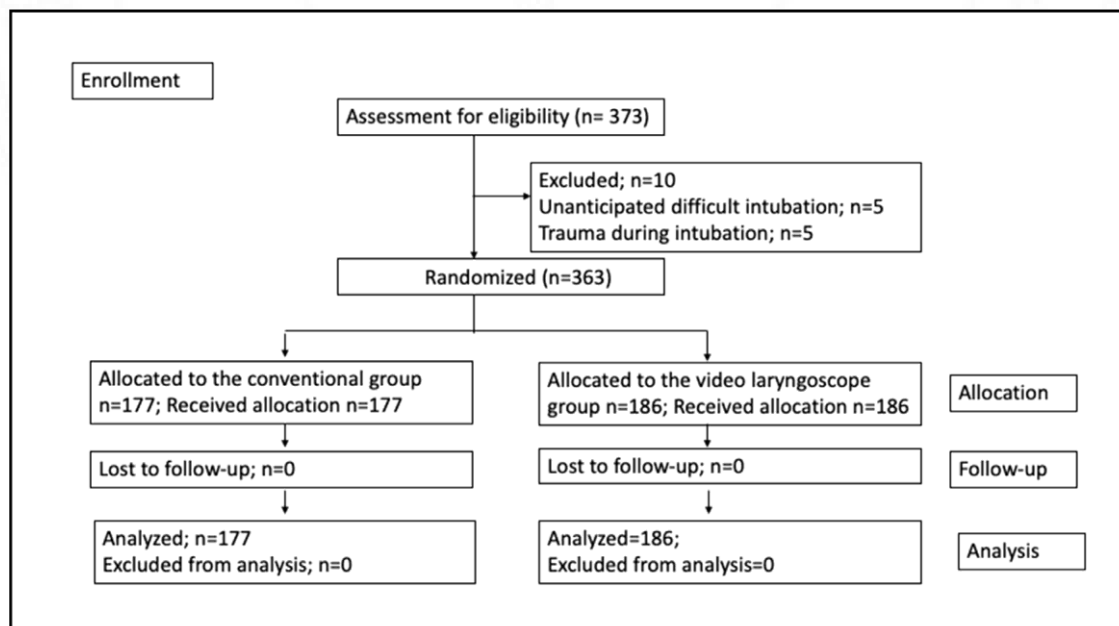


Fig 2. CONSORT diagram.

Table 1
Baseline Characteristics of Study Population

| Variables | | C Group (n = 177) | VL Group (n = 186) | p Value |
|---|---------------|----------------------|--------------------|---------|
| Age, mean \pm SD, y | | 54 \pm 14 | 55 \pm 14 | 0.649 |
| Sex, n (%) | Men Women | 65 (36.7) 112 (63.3) | 54 (29) 132 (71) | 0.119 |
| Weight, mean \pm SD, kg | | 63 \pm 11.5 | 63 \pm 11.7 | 0.513 |
| Body mass index, mean \pm SD, kg/m ² | | 24 \pm 4 | 24 \pm 4 | 0.68 |
| Body mass index classified | Underweight | 14 (7.9) | 13 (7) | 0.96 |
| | Normal weight | 94 (53.1) | 103 (55.4) | |
| | Pre-obesity | 55 (31.1) | 55 (29.6) | |
| | Obesity | 14 (7.9) | 15 (8.1) | |
| BSA, mean \pm SD, m ² | | 1.67 \pm 0.18 | 1.67 \pm 0.16 | 0.56 |
| Malampatti grade, n (%) | 0 | 0 (0) | 1 (0.5) | 0.335 |
| | 1 | 45 (25.4) | 56 (30.1) | |
| | 2 | 118 (66.7) | 109 (58.6) | |
| | 3 | 14 (7.9) | 20 (10.8) | |
| Cormack Lehane grade, n (%) | 1 | 66 (37.3) | 87 (46.8) | 0.181 |
| | 2 | 101 (57.1) | 89 (47.8) | |
| | 3 | 10 (5.6) | 10 (5.4) | |
| Surgery, n (%) | Non-CABG | 90 (50.8) | 84 (45.2) | 0.278 |
| | CABG | 87 (49.2) | 102 (54.8) | |

Abbreviations: BSA, body surface area; C group, conventional group; CABG, coronary artery bypass graft; VL group, video laryngoscope group.

insertion, as documented on post-TEE probe removal VL examination. There were significantly more injuries in the C group (n = 26; 14.7%) compared to the VL group (n = 14; 7.5%; p = 0.029). Also, for patients in the C group, the probe was inserted in the first attempt in 87% of patients; whereas in the VL group, it was 95% of patients (p = 0.023), as demonstrated in Table 2. The common sites of injuries documented on post-TEE probe removal were as follows: posterior pharyngeal wall (n = 23; 57.5%), esophageal inlet (n = 10; 25%), pyriform sinus (n = 3; 7.5%), and 1 patient each (2.5%) had injuries at the tonsil, lip, epiglottis, and uvula. Some of the sample injuries noted on the post-TEE removal VL examination are shown in Figure 3. In the VL group, the relation between the esophageal inlet and the larynx most commonly was posterolateral (n = 88; 47%), followed by posterior (n = 77; 41%), and, finally, in 21 patients (12%), the esophageal inlet was lateral to the larynx. These positions are shown in Figure 4.

When compared between patients with or without injury, there were no significant differences for age (p = 0.12), sex (p = 0.33), body mass index (p = 0.47), or type of surgery (coronary artery bypass graft v others; p = 0.27). All patients

were followed until discharge. There was no TEE probe insertion-related injury that needed further intervention.

Discussion

The main findings of this multicenter, randomized study were that the use of VL in comparison to the conventional technique was associated with a decreased incidence of complications, as well as fewer attempts for the successful insertion of the TEE probe. Additionally, there were significant variations in the relationship between the esophageal inlet and the larynx.

TEE has emerged as a major monitoring tool in cardiac surgical patients. The procedure generally is considered safe. In a state-wide retrospective study from Australia,¹ the authors demonstrated that the incidence of TEE-related injury was 13 per 10,000 patients, with a higher incidence in elderly (>70 years) patients. The incidence of TEE-related mortality was 3 per 10,000 patients. In another retrospective database audit from Australia, Lennon et al noticed higher gastrointestinal complications in patients who had cardiac surgery with TEE (1.2% v 0.29%).² The authors also recommended that clinicians should be aware of the late presentation of TEE-related complications. Whereas all these were retrospective studies,¹⁻⁴ in a recent prospective 1-year national audit, Ramalingam et al demonstrated that out of 22,314 examinations, 17 patients (0.08% or 1:1300 examinations) had major complications and 7 deaths (0.03% or 1:3000 examinations) directly attributed to these complications.⁵ This study suggested that if any patient developed TEE-related major complications, it was associated with a 40% risk of death; hence, it is imperative that the clinician take every possible precaution to avoid these complications. Probe insertion is likely the most hazardous part of TEE examination, and the authors recommended that future research should aim for optimal probe insertion to reduce the

Table 2
Study Outcomes

| Outcome Variables | C Group | VL Group | p Value |
|------------------------------------|-----------|------------|---------|
| Injury, n (%) | 26 (14.7) | 14 (7.5) | 0.029 |
| Attempts of probe insertion, n (%) | | | 0.023 |
| 1 | 154 (87) | 176 (94.6) | |
| 2 | 20 (11.3) | 10 (5.4) | |
| 3 | 3 (1.7) | 0 | |

Abbreviations: C group, conventional group; VL group, video laryngoscope group.

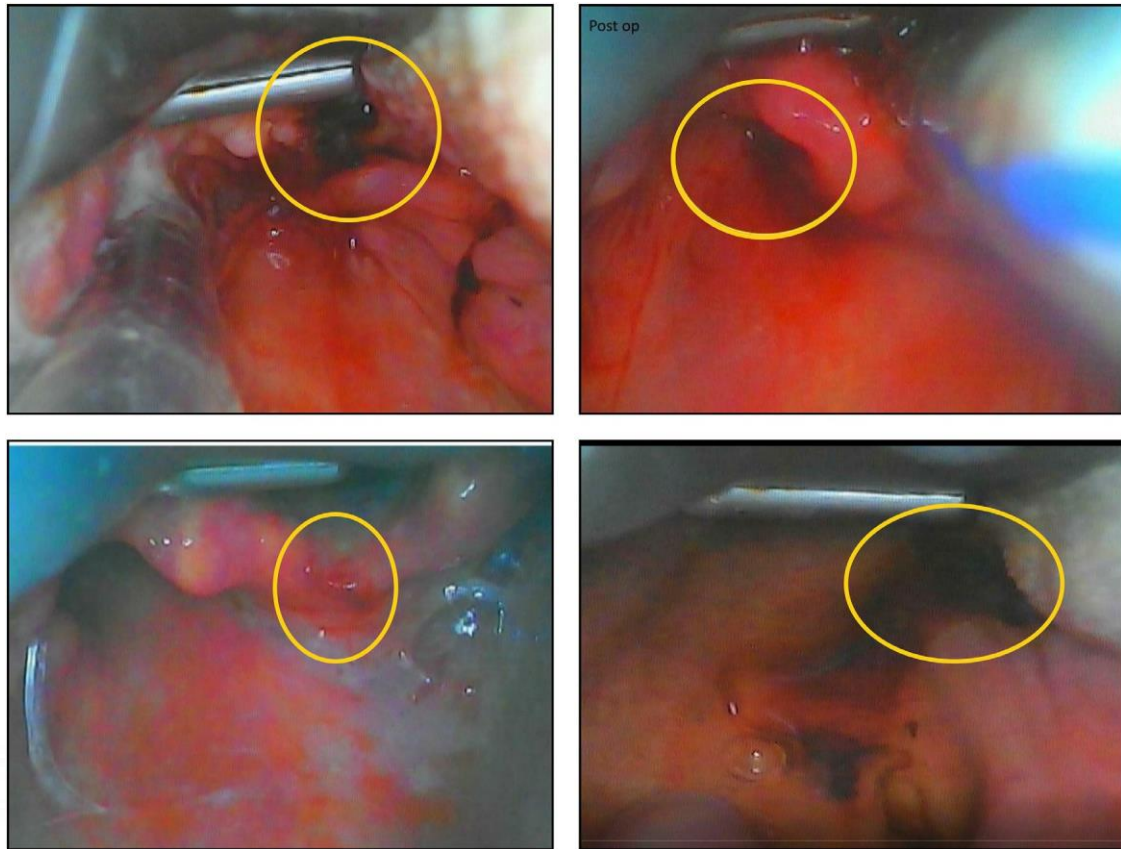


Fig 3. Examples of injuries due to the TEE probe insertion as documented on post-probe removal video laryngoscopy examination. Post op, postoperative; TEE, transesophageal echocardiography.

complications. In a systemic analysis of 35 cases of esophageal perforations, the authors noticed that a majority of the perforations occurred in low-risk examinations, and, thus, screening for high-risk factors may not eliminate the occurrence of a perforation.¹⁵

There were some previous studies on various techniques to improve the safety of TEE probe insertion, like the use of rigid laryngoscope¹⁶ and the jaw-thrust maneuver.¹⁷ Various single-case reports have demonstrated the utility of VL for difficult TEE probe insertion. Hirabayashi et al used an Airtraq VL (Prodol Meditec) for the insertion of a TEE probe in a patient with a difficult blind method.⁷ Ammar et al used the UE

Medical VL 400 VL (UE Medical Devices) when the TEE probe offered resistance on blind insertion. The authors noticed a normal anatomic variant of the esophagus—being on the side of the trachea instead of behind the trachea.⁸ Similarly, Riley et al reported a case of multiple failed attempts in a case of TEE-guided direct-current cardioversion. Pharyngeal visualization was achieved with the introduction of a C-MAC VL with a D-blade into the pharynx. The upper esophagus was noted to be laterally displaced, accounting for the difficulties with blind intubation; however, insertion of the probe now was achieved readily at the first attempt under real-time direct visualization.⁹ Similarly, Kim et al encountered excessive

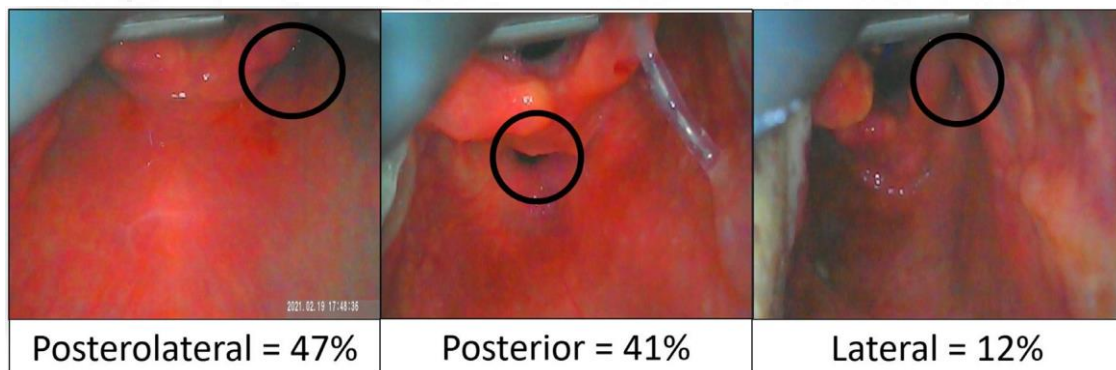


Fig 4. Variations in the relation between the esophageal inlet and the larynx.

resistance during TEE insertion in 2 patients undergoing atrial septal defect device closure. With the McGrath VL, the authors could visualize the esophageal inlet clearly, and further TEE probe insertion was easy.¹⁰

The results of the authors' study here confirmed the results of previous case reports and single-center randomized studies performed on the use of VL in assisting TEE probe insertion. The use of VL was associated with a lower incidence of injury compared to the conventional technique (14.7% v 7.5%; $p = 0.029$). Ishida et al¹⁴ compared Macintosh laryngoscope-assisted and McGrath MAC VL-assisted TEE probe insertion in 100 patients undergoing cardiac surgery. The number of TEE probe insertion attempts was significantly smaller in the McGrath group than in the Macintosh group ($p = 0.039$). The success rate at the first attempt was 76% in the Macintosh group and 92% in the McGrath group. The incidence of mucosal injury was 16% in the Macintosh group and 4% in the McGrath group ($p = 0.042$). Another randomized study by Ozturk and Kavakli¹³ aimed to compare the conventional technique with the use of the McGrath MAC VL for TEE probe insertion in terms of success rate, duration of insertion, and complications in patients undergoing cardiovascular surgery. The authors demonstrated that VL guidance increased the success rate (90.5% v 43.9%; $p = 0.016$) and reduced pharyngeal injury (2.4% v 17.1%; $p = 0.037$). Thus, TEE probe insertion success rates appeared to improve with the VL technique. However, these were single-center studies primarily aimed at the success rate for probe insertion. The present study was multicenter and powered adequately to assess the incidence of injuries. In addition, the authors' study here also confirmed that the use of VL reduced the number of attempts required for TEE probe insertion. Another very recent simulation study on mannequins made the case for the use of VL for TEE probe insertion even stronger.¹⁶ This study suggested that VL may reduce the pressure on the posterior pharyngeal wall during TEE insertion, regardless of the clinician's experience. The authors argue that this has the potential to reduce TEE probe insertion-related complications.

Another important and innovative finding of the present study was that there exist variations in relation to the esophageal inlet and the larynx. Although the most common relation was posterolateral, it is noteworthy that in 12% of patients, the esophageal inlet was related laterally to the larynx, as shown in Figure 4. In a cadaveric study, Jahangir et al evaluated variations in upper esophageal anatomy in relation to the larynx and its effect on TEE probe insertion.¹⁷ The esophageal hiatus was posterior and to the right of the trachea in most (66%). In these patients, the traditional "forward" jaw thrust helped to open the esophageal hiatus. However, some cadavers had the esophagus and trachea located almost side by side. In those patients, the jaw thrust maneuver may not be useful in conventional blind probe insertion. Another ultrasonographic study on the effectiveness of cricoid pressure demonstrated that the most common relation between the esophageal inlet and the trachea was posterolateral and not directly posterior.¹⁸ This finding concurred with the observations in the present study.

The present study had some limitations. This study was limited to complications related to TEE probe insertion and did not assess other injuries related to repeated manipulations or thermal injury. To minimize bias from visualizing the esophageal inlet position, esophageal inlet variations were noted only in the VL group, leading to limitation in the assessment of all patients. This study was not powered for assessing major injuries such as esophageal or gastric perforation, which often necessitate evaluation and additional interventions. The use of esophagogastroduodenoscopy, the modality of choice for such evaluation, was not part of the present study.¹⁹

In conclusion, the use of a VL was associated with a lesser incidence of injury compared to the conventional technique, and its use for this purpose is recommended. The VL guidance was associated with fewer attempts for a successful probe placement compared to the conventional technique. Significant variation exists in the relation between the esophageal inlet and the larynx, and direct visualization may contribute to improved safety with VL.

Conflict of Interest

None.

Acknowledgments

The investigators of this study would like to thank Medicam Company for providing Medicam VL scopes for the study purposes. However, the company was not involved in the study design, they didn't have access to data of the study and didn't participate in the study results analysis. The investigators also would like to thank all the surgical colleagues and supporting staff of the participating centers.

Supplementary materials

Supplementary material associated with this article can be found in the online version at [doi:10.1053/j.jvca.2022.07.017](https://doi.org/10.1053/j.jvca.2022.07.017).

References





















- Piercy M, McNicol L, Dinh DT, et al. Major complications related to the use of transesophageal echocardiography in cardiac surgery. *J Cardiothorac Vasc Anesth* 2009;23:62–5.
- Lennon MJ, Gibbs NM, Weightman WM, et al. Transesophageal echocardiography—related gastrointestinal complications in cardiac surgical patients. *J Cardiothorac Vasc Anesth* 2005;19:141–5.
- Huang CH, Lu CW, Lin TY, et al. Complications of intraoperative transesophageal echocardiography in adult cardiac surgical patients - experience of two institutions in Taiwan. *J Formos Med Assoc* 2007;106:92–5.
- Purza R, Ghosh S, Walker C, et al. Transesophageal echocardiography complications in adult cardiac surgery: A retrospective cohort study. *Ann Thorac Surg* 2017;103:795–803.
- Ramalingam G, Choi SW, Agarwal S, et al. Complications related to perioperative transoesophageal echocardiography — a one-year prospective national audit by the Association of Cardiothoracic Anaesthesia and Critical Care. *Anaesthesia* 2020;75:21–6.
- Pieters BMA, Maas EHA, Knape JTA, et al. Videolaryngoscopy vs. direct laryngoscopy use by experienced anaesthetists in patients with known

- difficult airways: A systematic review and meta-analysis. *Anaesthesia* 2017;72:1532–41.
- 7 Lewis SR, Butler AR, Parker J, et al. Videolaryngoscopy versus direct laryngoscopy for adult patients requiring tracheal intubation: A Cochrane systematic review. *Br J Anaesth* 2017;119:369–83.
 - 8 de Carvalho CC, da Silva DM, Lemos VM, et al. Videolaryngoscopy vs. direct Macintosh laryngoscopy in tracheal intubation in adults: A ranking systematic review and network meta-analysis. *Anaesthesia* 2022;77:326–38.
 - 9 Hirabayashi Y, Okada O, Seo N. Airtraq laryngoscope for the insertion of a transesophageal echocardiography probe. *J Cardiothorac Vasc Anesth* 2008;22:331–2.
 - 10 Afzal Ammar K, DuCanto J. Optically guided transoesophageal echocardiography probe insertion: What are we waiting for? *Eur Heart J Cardiovasc Imaging* 2017;18:1068.
 - 11 Riley RH, Rajwani A, Droste FH, et al. Videolaryngoscopy to aid transoesophageal echocardiography probe insertion. *Anaesth Intensive Care* 2020;48:157–8.
 - 12 Kim MK, Park SW, Sim Y, et al. Use of a McGrath videolaryngoscope to assist transesophageal echocardiography probe insertion in anesthetized patients. *J Cardiothorac Vasc Anesth* 2015;29:e16–7.
 - 13 Kavrut Ozturk N, Kavakli AS. Use of McGrath MAC videolaryngoscope to assist transesophageal echocardiography probe insertion in intubated patients. *J Cardiothorac Vasc Anesth* 2017;31:191–6.
 - 14 Ishida T, Kiuchi C, Sekiguchi T, et al. McGRATH MAC video laryngoscope for insertion of a transoesophageal echocardiography probe: A randomised controlled trial. *Eur J Anaesthesiol* 2016;33:263–8.
 - 15 Sainathan S, Andaz S. A systematic review of transesophageal echocardiography-induced esophageal perforation. *Echocardiography* 2013;30:977–83.
 - 16 Kumamoto T, Tashima K, Hiraoka C, et al. McGRATH MAC video laryngoscope assistance during transesophageal echocardiography may reduce the risk of complications: A manikin study. *BMC Anesthesiol* 2021;21:14.
 - 17 Jahangir A, Shah SP, Ahmad MM, et al. Visually guided TEE probe insertion, making a case based on anatomic variation: A cadaveric study. *Echocardiography* 2018;35:1616–20.
 - 18 Kei J, Utschig EE, van Tonder RJ. Using ultrasonography to assess the effectiveness of cricoid pressure on esophageal compression. *J Emerg Med* 2017;53:236–40.
 - 19 Freitas-Ferraz AB, Bernier M, Vaillancourt R, et al. Safety of transesophageal echocardiography to guide structural cardiac interventions. *J Am Coll Cardiol* 2020;75:3164–73.

Document Information

| | |
|-------------------|------------------------------------|
| Analyzed document | plagiarism check.docx (D173175887) |
| Submitted | 2023-08-28 05:26:00 |
| Submitted by | Dr P K Dash |
| Submitter email | dash@sctimst.ac.in |
| Similarity | 9% |
| Analysis address | sadh.sctims@analysis.arkund.com |

Sources included in the report

| | | | |
|-----------|--|---|----|
| W | URL: https://www.sciencedirect.com/science/article/abs/pii/S1053077016300039 Fetched: 2023-03-11 11:36:28 |   | 10 |
| W | URL: http://www.sctimst.ac.in/ Fetched: 2023-08-28 05:26:00 |   | 6 |
| SA | Thesis full sampath 51222.docx Document Thesis full sampath 51222.docx (D152455851) |   | 1 |
| W | URL: https://pubmed.ncbi.nlm.nih.gov/36722582/ Fetched: 2023-03-14 02:08:38 |   | 3 |
| SA | Dr.Reem Rachal Roy MD.Anaesthesiology.pdf Document Dr.Reem Rachal Roy MD.Anaesthesiology.pdf (D156859323) |   | 1 |
| SA | noorain thesis final copy.docx Document noorain thesis final copy.docx (D31221812) |   | 1 |
| W | URL: https://bmcanesthesiol.biomedcentral.com/articles/10.1186/s12871-020-01231-3 Fetched: 2021-10-08 16:06:23 |   | 5 |
| SA | babli thesis.docx Document babli thesis.docx (D142182247) |   | 1 |
| W | URL: https://revistachilenadeanestesia.cl/revchilanestv5115031055/ Fetched: 2022-08-02 11:53:43 |   | 1 |
| SA | Sree Chitra Tirunal Institute, Thiruvananthapuram / Manuscript.docx Document Manuscript.docx (D80265633) Submitted by: shri@sctimst.ac.in Receiver: shri.sctims@analysis.arkund.com |   | 2 |

Entire Document