

**CLINICAL OUTCOME AFTER  
ELECTROPHYSIOLOGICALLY AND  
ANATOMICALLY PRESERVED 7<sup>TH</sup> NERVE IN  
VESTIBULAR SCHWANNOMA PATIENT**



**DISSERTATION SUBMITTED FOR THE PARTIAL FULFILMENT  
FOR THE REQUIREMENT OF THE DEGREE OF  
M.CH NEUROSURGERY**

**DR. ARVIND KUMAR SINGH**

**M.CH NEUROSURGERY RESIDENT**

**SREE CHITRA TIRUNAL INSTITUTE FOR MEDICAL  
SCIENCES**

**AND TECHNOLOGY, THIRUVANANTHAPURAM,**

**KERALA 695011, INDIA**

**2021**

## **DECLARATION**

This thesis titled “Clinical outcome after electrophysiologically and anatomically preserved 7th nerve in vestibular schwannoma patient” is a consolidated report based on a bonafide study of the period from May 2019 to 31<sup>st</sup> July 2020, done by me under the Department of Neurosurgery, Sree Chitra Tirunal Institute for Medical Sciences & Technology, Thiruvananthapuram.

This thesis is submitted to SCTIMST in partial fulfilment of rules and regulations of MCh Neurosurgery examination.

Dr. Arvind Kumar Singh,

Department of Neurosurgery,

SCTIMST, Thiruvananthapuram.

August, 2021

## CERTIFICATE

This is to certify that the thesis entitled - “**Clinical outcome after electrophysiologically and anatomically preserved 7th nerve in vestibular schwannoma patient**” is a bonafide work of **Dr. Arvind Kumar Singh** and was conducted in the Department of Neurosurgery, Sree Chitra Tirunal Institute for Medical Sciences and Technology, Thiruvananthapuram (SCTIMST) under my guidance and supervision.

**Prof. Mathew Abraham,**  
[guide]  
Professor,  
Department of  
Neurosurgery, SCTIMST,  
Thiruvananthapuram.

**Dr. Ganesh Divakar**  
[Co-guide]  
Assistant Professor,  
Department of  
Neurosurgery, SCTIMST,  
Thiruvananthapuram.

**Prof. Easwer H V,**  
Professor and H.O.D.,  
Department of  
Neurosurgery, SCTIMST,  
Thiruvananthapuram.

## ACKNOWLEDGEMENT

First of all, I would like to thank my guide Prof. Mathew Abraham, Professor, and co-investigator Dr Ganesh Divakar, Department of Neurosurgery, whose support & guidance has been invaluable. I am eternally grateful and indebted for his contributions and suggestions, which were of crucial help during the entire work. He will always be a constant source of inspiration to me.

I owe a deep sense of gratitude to Prof. Easwer H V for his invaluable advice, encouragement and guidance, without which this work would not have been possible. His critical remarks, suggestions, helped me in achieving a high standard of work.

I am deeply indebted to Prof. Krishnakumar K., Dr. George Vilanilam, Dr. Jayanand Sudhir, Dr. Prakash Nair, Dr. Tobin George & Dr. Ganesh Divakar. I thank them for their constant encouragement and support.

My special thanks to Dr. Antony Stanley, research associate in my institute to help me with statistics.

I owe a thanks to my seniors Dr. Biren Patel and Dr. Shreykumar for the significant amount of the labor and support during the writing of this work.

I am grateful to my colleagues Dr Harshvardhan, Dr Sam, Dr Sanjay, Dr. Gautham, and my juniors Dr Ajit, Dr Darshan, Dr Sreenath, Dr Anand and Dr Arun, for their constant encouragement and

moral support & special gratitude to my juniors Dr. Darshan and Dr. Sreenath.

I am very grateful to my family; especially my wife Alisha and my parents for their constant moral support and help for my every academic activities

Lastly, I owe a deep sense of gratitude to all my patients without whom this work would not have been possible

## **ABBREVIATIONS**

STR – Subtotal resection

NTR – Near total resection

GTR – Gross total resection

FN – Facial nerve

VS – Vestibular schwannoma

POD- Post Operative Day

MRI- Magnetic Resonance Imaging

ASA- American Society of Anesthesiologist

SPSS- Statistically Package for Social science

GKS- Gamma Knife Surgery

HB Grading- House Brackmann Grading

IONM- Intra Operative Neuro Monitoring

## TABLE CONTENTS

<b>SL.No</b>	<b>TITLE</b>	<b>PAGE NO.</b>
<b>1</b>	<b>Synopsis</b>	<b>viii</b>
<b>2</b>	<b>Introduction</b>	<b>1</b>
<b>3</b>	<b>Review of literature</b>	<b>4</b>
<b>4</b>	<b>Aims &amp; Objectives</b>	<b>17</b>
<b>5</b>	<b>Materials And Methods</b>	<b>19</b>
<b>6</b>	<b>Results</b>	<b>30</b>
<b>7</b>	<b>Discussion</b>	<b>54</b>
<b>8</b>	<b>Conclusions</b>	<b>74</b>
<b>9</b>	<b>Bibliography</b>	<b>77</b>
<b>10</b>	<b>Annexure :</b> <ul style="list-style-type: none"><li>- <b>Patient proforma</b></li><li>- <b>Patient information sheet &amp; Consent form in English &amp; Malyalam</b></li><li>- <b>Institutional Ethics Committee Clearance letter</b></li><li>- <b>Plagiarism check report</b></li></ul>	<b>81</b>



# **SYNOPSIS**

## SYNOPSIS

**Background:** The goal of modern vestibular schwannoma surgery is not only to complete tumour removal but also to preserve functions. Cerebellopontine angle surgery carries a significant risk of impairing facial nerve function, especially with large masses. Avoidance of facial nerve injury postoperatively requires preoperative and intraoperative identification and hence the role of preoperative imaging and intraoperative monitoring.

**Objectives:** To evaluate the impact of identification of facial nerve preoperatively and intraoperative neurophysiological monitoring on the preservation of facial nerve function.

**Study design:** This is a prospective observational clinical study.

**Patients and methods:** This study was conducted on 35 patients operated upon for excision of vestibular schwannoma. Intraoperative monitoring was used for all patients. Patients were followed up for 3 months prospectively.

**Results:** In the current study mean age was 47.94 years and female predominance were seen (23/35). In 31/35 (88.57%) patients, IAC extension was noticed, 15/35 (42.86%) patients presented with HCP and out of which only 6 patients were required shunt (5 preoperatively and 1 postoperatively). The first symptom to appear in our patient was Hearing loss (74.29%) and the mean duration of the presentation was 37.51 to 45.32 months. In the Current study, FN was preserved electrophysiologically in 32/35(91.43%) patients and anatomically preserved in 34/35 (97.14%) patients and the most common FN displacement location was anteriorly (94%). In view of more cases included in series were large to giant size (28/35) with a mean size of 3.76 cm diameter so we were able to achieve GTR+NTR (51.43% + 40%) and 8.57% STR.

**Conclusion:** Facial preservation requires preoperative prediction of the location of the nerve in relation to the capsule, extra-arachnoidal dissection during surgery, and subtotal resection if intraoperative monitoring predicts a high risk, however if surgeon's experience is enough to take risk than even cystic lesion can be excised with care with good FN outcome.

**Keywords:** Vestibular schwannoma surgery, Facial nerve preservation.



# **INTRODUCTION**

## INTRODUCTION

Acoustic tumours are benign neoplasms of Schwann cell origin that occur predominantly on the vestibular branches of the acoustic nerve (80%) and from the cochlear part in only about 5-7% (1). The tumours variously known as acoustic neurinomas, acoustic neuromas, and vestibular schwannomas constitute an important intracranial pathology entity, accounting for 6 to 8% of all intracranial neoplasms and 80 to 90% of tumours of cerebellopontine angle (2). Since they arise from the superior division of the vestibular nerve and not from the acoustic division of the eighth cranial nerve, and are composed of Schwann cells in the neurilemma, the more accurate term “vestibular schwannoma” has been proposed (4). The majority of acoustic schwannomas are sporadic and unilateral (3). Bilateral tumours are hereditary and constitute less than 5% of all schwannomas (4). They present commonly in the fourth to sixth decade and it is a decade earlier in India (5, 6).

The clinical presentation of acoustic neuromas can vary widely, but the earliest symptom is usually hearing loss. A history of progressive unilateral hearing loss, usually over many months and sometimes years, is the hallmark of an acoustic neuroma. Compression of the facial nerve occurs early, but the facial symptoms are rare in the early stages. When they do occur, fasciculation's are the most common manifestation.

Anatomic and functional preservation of the facial nerve is a primary goal during microsurgical resection of vestibular schwannomas. While

the anatomic integrity of the facial nerve can be preserved in a majority of cases, this does not guarantee functional preservation (7). A normal initial facial nerve examination after surgery strongly correlates with long term functional preservation of the facial nerve even in the setting of delayed weakness. Patients with immediate postoperative facial nerve weakness represent a small but important group that is at increased risk for a poor facial nerve outcome. The ability to predict recovery versus permanent dysfunction would be beneficial in counselling patients as well as planning facial nerve rehabilitation. Intraoperative facial nerve monitoring has been shown to improve facial nerve outcome in multiple studies (8).

# **REVIEW OF LITERATURE**

## REVIEW OF LITERATURE

**History of vestibular schwannoma** - The first presumptive case of vestibular schwannoma dates back to the second half of the 18th century. As reported by Ahn, et al. (9), in 1777 Eduard Sandifort, described at autopsy the first unilateral acoustic tumor. Several reports on tumors related to the auditory nerve followed, but it was not until 1830 that Charles Bell gave an accurate description of what appears to be a definitive case of acoustic tumor. A few years later, Curveilhier published a detailed report on the progression of clinical symptoms and the postmortem findings in a patient. During the last decades of the 19th century, advances in the histological and pathological characterization of tumors led to a more solid correlation of a patient's clinical symptoms with the actual diagnosis obtained at autopsy. Sternberg (1900) is credited with the first accurate pathological description of an acoustic neurinoma (10).

The first reported case of successful surgery in the cerebellopontine angle (in which patient survived) was performed in 1894 by a British surgeon, Sir Charles Balance (11). In early part of this century most patients with vestibular schwannomas presented with very large tumors and significant brainstem compression. The aim of surgery was to decompress the posterior fossa and surgical mortality was 80%. In 1917 Cushing advocated subtotal resection of acoustic tumours and with improved surgical technique and haemostasis was able to lower perioperative mortality to 20% (12). Dandy was the first American surgeon to perform total resection of acoustic tumors successfully and the first to describe the unilateral approach to the

cerebellopontine angle. Because many patients at this time presented with facial palsy, postoperative facial nerve palsy was a uniform complication. This trend prevailed until the latter half of the last century; it is only in recent decades that emphasis has been placed on preservation of facial nerve function.

The achievements in vestibular schwannoma surgery were conspicuously marked by the following advances:

- A better understanding of the microsurgical anatomy
- Use of operating microscope
- Significant advances in neuroanaesthesia, neurophysiology, and in standard microsurgical techniques.

In 1931 Cairns was the first surgeon to document preserved facial nerve function. It was only until 1940, when Olivecrona employed an operating room nurse to observe facial twitching during tumor resection (12). In 1961, William House pioneered a new era in acoustic surgery with introduction of the operating microscope. He introduced the translabyrinthine and middle fossa approaches for removal of vestibular schwannoma tumours. In 1957, Theodore Kurze for the first time resected a vestibular schwannoma using an operating room microscope. In 1965, Kurze and Rand (13) reported suboccipital transmeatal microdissection to remove vestibular schwannoma totally, affording the possibility of preservation of the facial and cochlear nerves. These approaches and refinement of the technique also led to an increased rate of facial nerve preservation during tumor resection.

Further refinements by M. Gazi Yasargil in the microsurgical techniques and instruments revolutionized vestibular schwannoma surgery. He was influenced by the idea of Kurze and others to make microsurgery a fundamental part of modern neurosurgery (14). Using his extensive experience in vestibular schwannoma surgery, Majid Samii has established landmark outcomes with respect to the preservation of facial and hearing functions (15, 16).

In the cerebellopontine angle, tumour growth distorts normal anatomic relationships, making neural identification difficult. Of all the surgeries that entail surgery near the facial nerve, resection of acoustic neuroma involves the highest risk of iatrogenic injury (17). The intracranial facial nerve is more susceptible to injury because of the absence of a fibrous epineural protective layer found peripherally. In addition, the facial is thinned, attenuated and displaced by acoustic neuromas in the mid cerebellopontine angle. This segment of facial nerve, medial to the porus acousticus in the cerebellopontine angle, is the site of most injuries. Even anatomical preservation of the facial nerve during cerebellopontine angle surgery does not ensure normal or even satisfactory function (18).

**History of Facial nerve monitoring** - In performing intracranial surgery that requires prolonged dissection and retraction of vital centres and cranial nerves, intraoperative electrophysiological monitoring is useful to the surgeon in localization as well as in assessing the extent of the manipulation of these structures. Cranial nerves two to twelve can be monitored by evoked response potentials (visual evoked potentials, BAEPs), triggered EMG, or a combination of the two. Except for

cranial nerves two and eight, the remaining nerves can be monitored by compound muscle action potential (CMAP) triggered by manipulation or direct nerve stimulation. The nerves most commonly monitored during vestibular schwannoma surgery are cranial nerves seven and eight.

A variety of techniques are available for the electrodiagnosis of the pathologies of muscle, peripheral nerve, and central nervous system distribution. Historically, the earliest investigations were performed in the late 18th century by Galvani, who published his observations on electricity and muscle contraction. In 1848, Dubois-Raymond discovered the action potential and described it as a negative variation of the standing potential of a nerve related to the conduction of a nerve impulse. Soon thereafter, Hermann von Helmholtz recorded the conduction velocity in a median nerve in a human (19).

In 1893, Krause noted that low-current electrical stimulation of the seventh cranial nerve produced contractions in the facial muscles during sectioning of the eighth cranial nerve for tinnitus.

Before 1960, a large percentage of patients who underwent vestibular schwannoma surgery had significant long term facial nerve dysfunction, House-Brackmann grade 3 or worse (20). In 1970's and early 1980's, before the common use of intraoperative facial nerve monitoring (IOFNM), facial paralysis after acoustic neuroma surgery was still a significant issue. By the early 1990's, the advantages of IOFNM (Intra-Operative Facial Nerve Monitoring) in cerebellopontine angle surgery were clear.

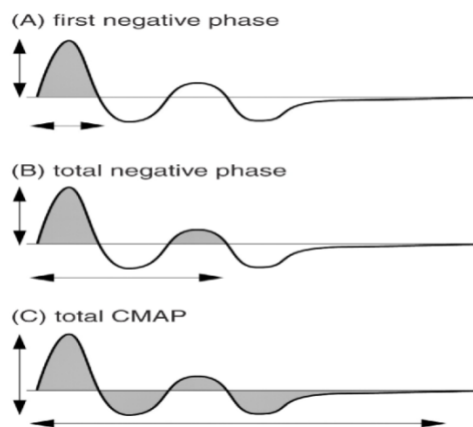
Historically, detection of facial nerve activity during surgery was possible by observation of facial muscle movement or by ingenious inventions such as suturing bells to the patient's face and listening for a response. J. David Williams in 1988 described a technique in which "jingle bells" were sutured in three positions on the face at the points of maximum excursion of the facial musculature when stimulated by a Hilger nerve stimulator set at 2 mA (21). This procedure was used to monitor movement of the facial nerve while surgeon dissects the nerve in the cerebellopontine angle and internal auditory canal.

To facilitate the preservation of the facial nerve during resection of large acoustic neuromas, Delgado, et al, (22) 1979 developed a modified system of intraoperative electromyography. This method involved stimulation of the facial nerve with a probe during surgery. Surface electrodes over the facial muscles detected the evoked responses and an oscilloscope was used to monitor the activity of the facial nerve. They photographed the EMG recordings for the purpose of detecting small changes that might occur during the operation and that would indicate deterioration of facial nerve function.

In 1982, Sugita and Kobayashi (23) monitored facial nerve function by positioning accelerometers over the facial muscles and transducing the output to an audiometry signal that could be heard by the surgeon. For recognition of the facial muscle responses to stimulation, they used a newly designed facial monitor. Accelerometers weighing 3 gm were attached to the orbicularis oculi and oris muscles. The facial movements were converted to sound by means of an

accelerometer, amplifier, and speaker. Thus the surgeon was thus able to recognise the facial responses without necessity of having the patient's face observed under the drapes by an anesthesiologist or ancillary personnel.

Later in 1984, Moller and Jannetta (24) combined the audiometry feedback features with the use of EMG to develop a more sophisticated level of monitoring. In addition these investigators introduced monopolars, low impedance constant voltage stimulation to localize the facial nerve and assess its functional integrity. The electrical activity (EMG responses) of the facial muscles were recorded from two needle electrodes (Grass Type E2 subcutaneous platinum needles), one placed in the orbicularis oris and the other in the orbicularis oculi. The ground electrode was placed on the forehead. The potentials from these two electrodes are amplified differentially using a Grass P511J amplifier equipped with a current limiting probe. The potentials were displayed on an oscilloscope, and wave made available through a loudspeaker using an audio-amplifier.



**Anatomy and Physiology of Nerve Conduction and Electrophysiological basis of nerve monitoring** - The peripheral nerve trunk contains motor, sensory and autonomic axons, which may be myelinated or unmyelinated; the myelinated ones have a faster conduction velocity. Conduction has two types: continuous or saltatory. The former occurs in unmyelinated nerve fibers and is continuous and bidirectional. Saltatory conduction occurs in myelinated fibers. When a mixed nerve is maximally stimulated and recorded monophasically, there is a somewhat irregular contour to the action potential based on the different velocities and thresholds of the nerve (this is called a “compound nerve action potential” CMAP). Following the fall of the electrical response in the action potential, there are two low amplitude, relatively low deflections, based on prior spike activity. The first is a negative after-potential. The nerve is still excitable at this point, and, in fact, may be more easily excitable. Following this, a positive after-potential occurs where the nerve has a high threshold to activation. Both states relate to Na<sup>+</sup> permeability. A motor unit consists of a motor axon and the population of muscle fibers innervated. The neuromuscular junction is a synapse at which the neural impulse stimulates the release of acetylcholine from the axon terminals, resulting in a brief muscle contraction. The consequent electrical response is the CMAP Fig. 1.

Fig 1- CMAP Variables= Compound muscle action potential; vertical arrows = CMAP amplitude; horizontal arrows= CMAP duration; shaded phase CMAP area.

**Facial Nerve Monitoring and Postoperative Function** - Before the use of intraoperative monitoring, the anatomical preservation rate of facial nerve ranged from 30-96.6% and the functional preservation rate

ranged from 20-77% in various studies. The premise of using intraoperative facial nerve monitoring in acoustic neuromas is that facial nerve outcome will be improved in the immediate and late postoperative period. The facial nerve function following acoustic tumour surgery with the use of monitoring showed anatomical preservation rate of 80–100% and the functional preservation rate from 53–100% in various studies.

Niparko, et al, (25) in 1989 for the first time reported the results of correlating proximal to distal amplitude ratios with facial nerve outcome in 29 patients who underwent translabyrinthine excision of the acoustic neuroma and were followed for one year. Of these 29 cases, 24 demonstrated equal responses with proximal and distal stimulation (1:1) at the completion of the procedure. 16 of these 24 patients (67%) demonstrated normal facial function (House and Brackmann Grade I) 1 week postoperatively. One year postoperatively, 21 of these 24 patients (88%) had Grade I facial function. None of these 24 patients demonstrated complete postoperative facial paralysis. Thus, equal distal-proximal evoked responses suggested a good prognosis for the eventual recovery. 4 out of the 29 cases demonstrated a reduced proximally evoked response. In one of these 29 cases, proximal stimulation evoked no response. Two of the four cases with a reduced proximal response demonstrated facial weakness (Grade III and V) 1 week postoperatively. One of these two cases regained normal facial function after 1 year. The single case of absence of the proximally evoked response demonstrated complete paralysis (Grade VI) 1 week and 1 year postoperatively. Thus it was concluded that a reduced proximal response at the end of the procedure may indicate

postoperative facial weakness. The mere presence of a response with proximal stimulation at the end of the procedure, however, indicates that the facial nerve is at least partially intact. However, the authors did not correlate the values of proximal to distal amplitude ratios with final facial nerve outcome and did not study the association between intraoperative amplitude ratios, initial postoperative facial nerve function, and final facial nerve function.

Ebersold, et al., (26) in 1992 reported that proximal to distal amplitude ratios greater than 0.9 were associated with good initial and final postoperative facial nerve function; ratios between 0.5 and 0.9 were associated with significant initial postoperative facial nerve weakness but good final facial nerve function; ratios less than 0.5 were associated with poor initial facial nerve function and varying degrees of final facial nerve weakness.

Taha, et al, (27) in 1995 reported the first detailed analysis of the association between proximal to distal facial nerve amplitude ratios and initial and final postoperative facial nerve function. The facial nerve was stimulated using a monopolar stimulator probe with a constant current of 4 pulses per second for 100 msec. The stimulus was set at the lowest intensity required to elicit an EMG response, beginning at 0.05 mA and not exceeding 1 mA. The facial nerve was stimulated at the proximal and distal points after tumor excision. The response amplitudes were recorded in microvolts. Six readings were obtained: three from proximal and three from distal stimulation. The highest proximal to distal ratios were used to predict initial and final postoperative facial nerve function. They found that higher proximal to

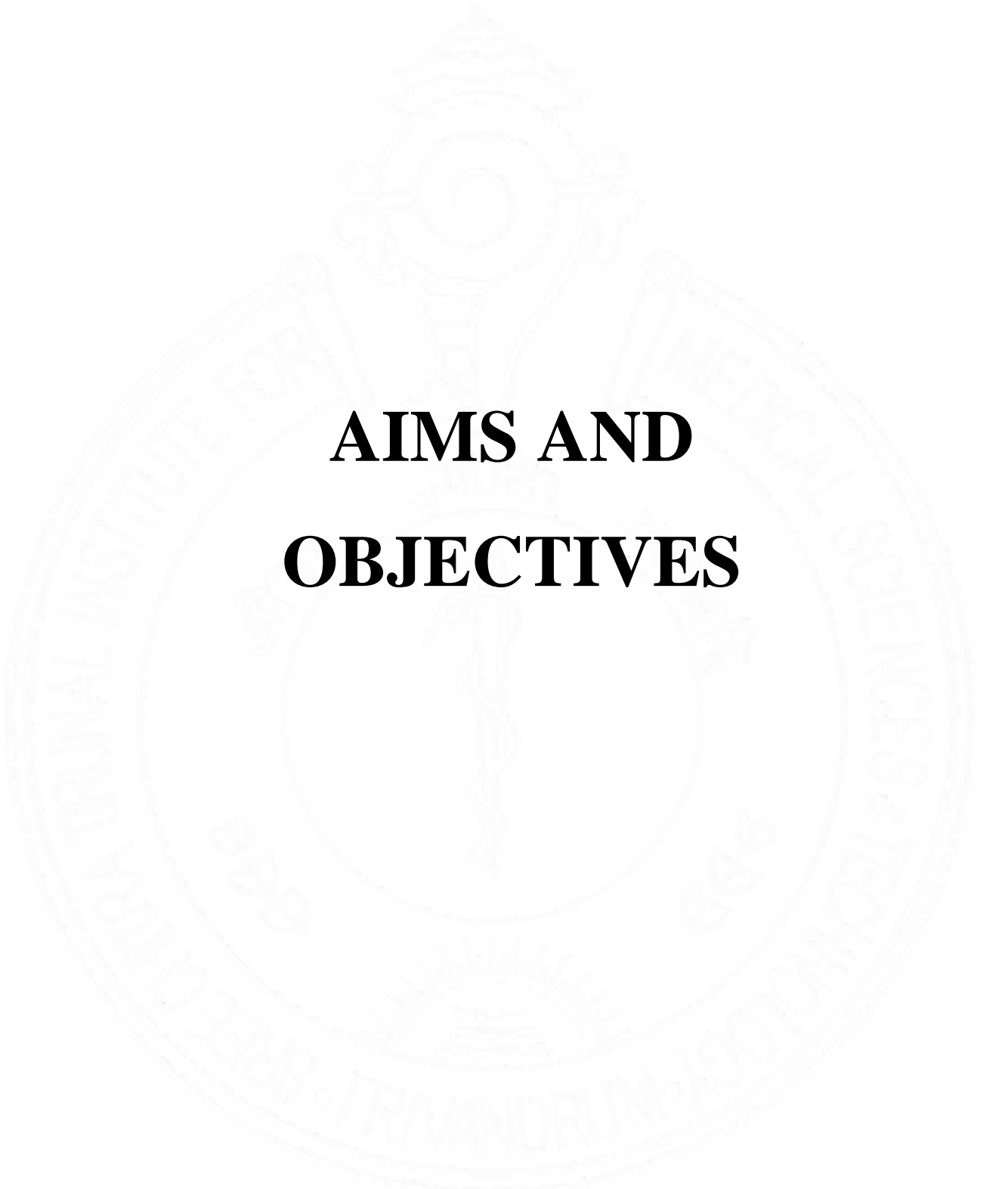
distal amplitude ratios were associated with better initial and final postoperative facial nerve function. All patients with ratios greater than 2:3 had grade III or better initial postoperative facial nerve function and grade I final facial nerve function. 90% of patients with ratios between 1:3 and 2:3 had grade III or worse initial postoperative facial nerve function and all had grade III or better final postoperative facial nerve function. All patients with ratios less than 1:3 had grade IV or worse initial and final postoperative facial nerve function. However, the result of this study was inconclusive because the rates of facial nerve recovery in different patient groups overlapped and the number of patients (twenty) was too small.

Sobottka, et al, (28) in 1998 also evaluated amplitude ratios for a series of 40 patients. They also evaluated proximal and distal absolute EMG amplitudes and stimulation threshold for prediction of initial postoperative nerve function and recovery of function. Good initial facial nerve outcome (modified House and Brackmann grading I & II) was found in 15/16 patients with a proximal EMG amplitude greater 800 microvolts and in 19/22 patients with proximal stimulation threshold of less than 0.3 mA. Sixteen of 16 patients with proximal stimulation threshold equal to or greater than 0.3 mA had moderate to severe facial palsy (HB III or worse). Six of six patients with without evokable proximal amplitude initially had poor facial nerve function (HB IV). A proximal amplitude of 300 microvolts or less and a proximal to distal amplitude ratio below 1: 3 were found in the absence of functional recovery in 6/8 (75%) and 5/6 (83%) patients with initial HB IV, respectively. They concluded that absolute values of proximal amplitudes were more reliable predictors than proximal to distal ratios.

Goldbrunner RH, et al, (29) in 2000 did a quantitative analysis of absolute values and ratios (proximal/distal) of evoked EMG parameters (amplitude, latency and duration) in 137 patients and were correlated with postoperative ( 1week, 6 weeks and 6 months) facial nerve function. Absolute values of EMG amplitude and amplitude ratios (proximal/distal) demonstrated a good predictive power. For EMG latencies, only the ratios revealed a significant correlation with facial nerve function. Latencies and latency ratios are also easily influenced by intraoperative maneuvers that lead to nerve edema and reversible nerve blocks. They found that an amplitude ratio of greater than or equal to 0.3 had a good chance for facial nerve function recovery and in contrast, a ratio of less than 0.1 had poor facial nerve function outcome. Because absolute values of CMAP amplitudes are available at every phase during surgery, these are the most appropriate parameters for routine assessment of the status of the facial nerve during surgery. So it was concluded that due to their lower predictive power, latency ratios should be used only as supplementary parameters and statements concerning expected facial nerve outcomes should be based on the amplitude ratios, which are the strongest predictors.

Isaacson et al, (30) in 2003 did a retrospective case review of 229 patients undergoing resection of vestibular schwannoma with intraoperative facial nerve monitoring at a single institution. They found that the proximal to distal amplitude ratio and proximal electric threshold were statistically significant in predicting facial nerve outcome. They concluded that the use of intraoperative facial nerve monitoring may be useful to predict poor long term outcomes and thus modify the timing of rehabilitation.

Various parameters have been studied during the facial nerve monitoring in acoustic nerve tumour and cerebellopontine angle surgeries. The correlation between the tumour size with the facial function outcome after surgery of vestibular Schwannoma has been reported from 80 to 100 % in tumour size less than 2 cm however when the size of lesion increases to more than 4 cm then facial nerve preservation's results varies from 20 to 85% in various studies.



# **AIMS AND OBJECTIVES**

## **AIMS AND OBJECTIVES**

This study aims is to access the clinical outcome after electrophysiologically and anatomically preserved 7<sup>th</sup> nerve in vestibular schwannoma patients. Our primary objective was to evaluate the various factors related to the postoperative outcome of the facial nerve after IONM & comparing them with follow up improvement and previous works of literature.

The following characteristics were included in our study:

- Preoperative facial nerve HB grade.
- Post Operative facial nerve HB grade at immediate POD, after 1 month and at 3 month follow up.
- IAM extension of lesion.
- Size of lesion
- Demographic distribution in our country
- Effect of Extent of resection and facial nerve outcome.
- Per of need of shunt or EVD placement
- Displacement of facial nerve in relation to lesion and facial nerve outcome.



# **METHODOLOGY**

## METHODOLOGY

The study was initiated after obtaining institutional review board approval. We included a total of 35 consecutive patients, operated on between May 2019 to July 2021. Prospective study and analysis were done of 35 patients who underwent surgery till July 2021. Patients of 18 to 60 years of ASA grade I and II, posted for elective vestibular schwannoma excision based on preoperative MRI.

Number- The sample size of 35 was taken for this prospective observational study. They were recruited from the elective neurosurgical operation theatre list.

Extent/Degree of Resection (EOR)-The degree of resection is classified as gross total resection(GTR), near-total resection (NTR), and subtotal resection (STR).GTR was performed only if a clear plane of dissection was available in arachnoid plane while doing surgery. NTR- defined as remnants of IAC tumour or tumour adhering to the facial nerve or brain stem. STR- defined as resection of less than 95% of the tumour.

All surgeons went for surgery with the intent to achieve GTR, but radical extirpation was avoided while intraoperative monitoring of facial nerve or vital signs disturbances is seen further. STR and NTR were planned preoperatively in patients only with advanced age and medical co-morbidities.EOR was decided with the help of follow up CECT on POD 1 as per institute protocol.

**Clinical assessment of facial nerve:-** facial nerve was assessed with the help of House Brackmann grading system and taste sensation was assessed in the anterior 2/3<sup>rd</sup> of the affected side of the tongue.

**Electrophysiological monitoring-** The interruption of dissection of facial nerve from the tumour was done at 50% of the response of the nerve to a supramaximal stimulation (0.8 mA) at the brainstem associated with strong adherence of tumour to the 7th cranial nerve. These criteria are based on an earlier study by the Mayo clinic showing the usefulness of interrogating intraoperative 7th cranial nerve function to predict which patient will ultimately have good facial nerve function. Eight Channels FN monitoring (NIM, Medtronic) was used for electromyography, and response taken into consideration were the highest amplitude response of the 8 channels. The difference between electrode impedance was less than 1 $\Omega$ , and the FN was electrically stimulated by a monopolar probe with a 0.5 mm tip. Square current waves with 100 msec duration at 4Hz frequency were applied as stimulation. Electrophysiological monitoring was done with the placement of electrodes over frontalis muscle, orbicularis oculi, orbicularis oris and lateral pterygoid muscle.

**Surgical Procedure** – All patients were operated in the supine position under GA through retro sigmoid approach. For all patients no premedication was given, Induction done with injection propofol (2 mg/kg), injection fentanyl (2 micrograms/kg), and atracurium (0.5 mg/kg) before endotracheal intubation. To avoid confounding electrophysiological issues, anaesthesia was maintained during the procedure with an intravenous infusion of propofol by TIVA and

Fentanyl infusion (1-2 microgram/kg/hr), and Neuromuscular monitoring was done after achieving TOF 75% with the infusion of atracurium 0.5mg/kg/min. Ventilation was done with O<sub>2</sub> : Air = 50 % : 50 %. Body temperature was kept between 36 degrees centigrade and 37 degrees centigrade with a blanket. Mean blood pressure was maintained between 65 and 75 mm of Hg and end-tidal CO<sub>2</sub> between 30 to 35 mm of Hg to preserve brain perfusion. After opening the dura mater, the VS was initially de-bulked intratumorally with normal capsule preservation. The FN was stimulated supramaximally using 0.8 mA stimulating current and the peak response obtained from the channel having the greatest amplitude was recorded as a baseline. Then FN dissection was started laterally and tumour resection was done under the constant visual observation of the FN. When FN was adherent to the lesion, proximal supramaximal stimulation was regularly performed after each piece of tumour was removed and dissection was interrupted if there is a loss of response is close to 50% associated with adherence of the lesion to the FN with interruption of the pial plane of FN. This method of dissection was only used in the patients with an adherent FN, if the dissection is straightforward, this method was not used and GTR was performed. After identification of FN current was reduced to 0.2 mA and further to 0.05 mA while putting probe over the FN itself.

**Eligibility Inclusion criteria:**

- Patients posted for elective vestibular schwannoma excision based on preoperative MRI.
- Age 18-60 years.

- ASA grades I and II. (inclusion of higher grade will cause difficulty in the clinical assessment of facial nerve in the post-op period due to co-morbidities).
- Patient with pre-operative House Brackmann grading of facial nerve I and II.

**Exclusion criteria :**

- Patient refusal for study.
- Age less than 18 years and more than 60 years.
- ASA grades III and IV
- Proptosis
- H/o eye/facial injury
- H/o facial nerve palsy
- H/o previous surgery of CP angle lesion
- Any requirement of Post-op RT/or h/o pre-op GKS.
- Any patient with pre-op House Brackmann grading of the facial nerve is more than and equal to III.

**Statistical analysis:** Data was manually entered into the proforma. Analysis was done by the investigators. It was not analysed to understand caste, class, ethnicity, race differentials. Data were analysed with IBM SPSS Statistics for Windows, version 23.0 (IBM Corp.). Descriptive statistics were used to analyse patient demographics, presenting symptoms, perioperative complications and tumour characteristic. Continuous variables were described as mean, median and interquartile ranges, as appropriate, and categorical variables were presented as frequencies.

**Surgical procedures-** Prior to the definitive surgery, anesthetic considerations were taken, aiming at optimum cerebellar relaxation. Propofol was the preferred anesthetic agent; it does not interfere with monitoring techniques. A short-act muscle relaxant sufficient for intubation was given. Park-bench/ Lateral position was the preferred position for all of the patients.

In the present study, all the cases were operated by retrosigmoid approach with lateral position. In our series, using retro-sigmoid approach alone visualization of tumor–brainstem interface and facial nerve preservation could be possible even in giant sized tumors with out much difficulty.

#### **Steps in retro-sigmoid approach-**

Position -Modified park bench (Lateral decubitus position)

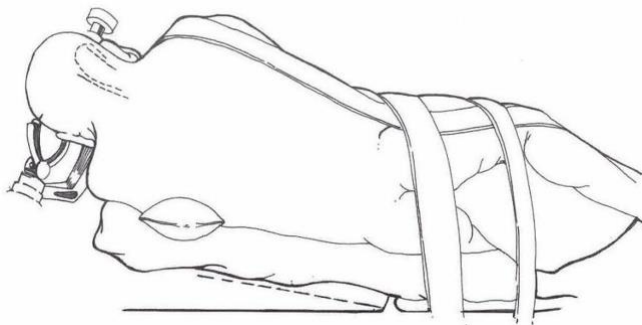


Fig 2 . Lateral decubitus position

- Vertically oriented "S" shaped incision 4 cm posterior to the ear canal is made.

- Small craniectomy is performed, anterior and superior limits of the craniotomy are the sigmoid and transverse sinuses, respectively. Laterally exposed mastoid air cells near the sigmoid sinus are occluded with bone wax to prevent transgression of CSF.
- The dura is then opened and reflected.
- Cisterna magna is opened to release the CSF which maximizes posterior fossa relaxation and minimizes the need to retract the cerebellum.
- Once adequate exposure has been obtained, the tumor is clearly visualized along with the brainstem and lower cranial nerves. The facial nerve is displaced anteriorly and superiorly in the cerebellopontine angle. The tumor displaces the trigeminal nerve upward and the glossopharyngeal and vagus nerves downward.
- The arachnoid over the tumor can be stripped away without coagulation, it provides not only the best plane for dissection but also a protective barrier for the cranial nerves and their small feeding vessels.
- After peeling away the arachnoid, a non stimulating area on the posterior tumor is coagulated with bipolar cautery and opened with microscissors and specimens are sent for pathologic study.
- Debulking of the tumor is the next step and must be carefully performed under an operating microscope, using micro dissecting instruments, so as to maintain the anterior portions of the capsule if injury to cranial nerve VII and/or VIII are to be avoided.

- Depending on the size of the tumor, this process of internal decompression followed by dissection and inward rolling the capsule may need to be repeated several times.
- Once the tumor has been substantially debulked, the posterior wall of the internal auditory canal can be removed using a high-speed drill. Great care must be taken to avoid injuring the labyrinth while removing the posterior wall of the internal auditory canal. Drilling continues until the dura is seen. Drilling is stopped before the lateral edge of tumor is reached.
- Once the internal auditory canal is exposed, the dura is opened and the tumor is removed from it. The superior vestibular nerve, inferior vestibular nerve, and tumour are identified in the posterior aspect of the canal. Gentle retraction of the superior vestibular nerve reveals the facial nerve, which is identified physiologically with a stimulator at minimal settings (0.05 mA). The vestibular nerves are sectioned laterally, and tumour dissection is performed in the plane between the tumour and the facial and cochlear nerves in a lateral to medial fashion.
- Once the tumour dissection is complete, bone surrounding the IAC is sealed with bone wax and fibrin glue.
- Eventually, the surgeons left with the anterior portions of the capsule adhered to the brainstem and cranial nerve VII. As the tumor capsule is carefully removed from the brainstem, the root entry zone of cranial nerve VII can be identified. The capsule is then carefully removed from the facial nerve with as little trauma as possible. The facial

nerve monitoring is of great help in this portion of the dissection to preserve the facial nerve.

- All the lower cranial nerves and draining veins are preserved. Good hemostasis is secured, dura closed with pericranial patch and wound closed in layers.

#### **Advantages -**

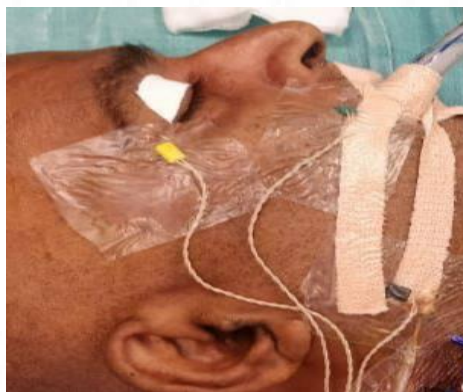- No tumour size limitation, can be applied to all acoustic tumors.
- Hearing preservation possible.
- Best wide-field visualization of the posterior fossa.
- Auditory brainstem implant placement possible
- Consistent facial nerve identification.

#### **Disadvantages -**

- Limited exposure of lateral IAC
- Intradural drilling
- Postoperative headaches
- Cerebellar retraction
- Facial nerve identification is relatively late in the dissection.

**Electrode positioning** - Two electrodes were used subdermally for the orbicularis oculi muscle (at the lateral aspect of the orbit), another two electrodes for the orbicularis oris muscle at the corner of the mouth, and one electrode at the forehead. These steps, together with the

setup of the device settings, were carried out by the electrophysiology team. Surgical procedure was carried out as classic suboccipital craniectomy. After durotomy and tumor identification, the stimulating electrode was applied to the posterior capsule. We started by pulsed stimulation using monopolar electrode, and at the same time, the electrophysiology team enabled an intensity of 0.8 mA threshold initially before decompression of lesion and lowered the intensity to 0.2 and then finally to 0.05 mA while checking the facial nerve integrity at

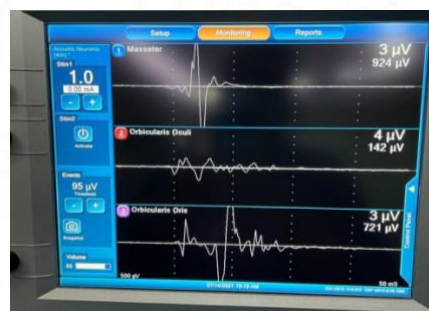
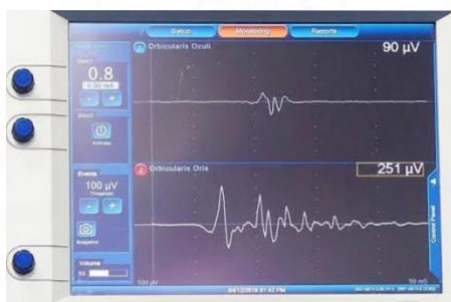
the end of surgery.

Fig 3:- Insertion of IONM electrode

**Interpretation of the neurophysiological monitoring responses-** At the first stage, the action potential response of the stimulated muscle(s) was recorded. The second step was that we started by central debulking. During the procedure of central debulking then separation of the capsule from the nerve or from the brainstem, we were notified by the electrophysiology team if there are recorded responses (train or burst types), either from individual muscle or all muscles. Immediately, we had stopped our procedure till disappearance of the response waves. We considered that persistence of the train response for more than 4 min denoted expected injury. Because of our strategy to preserve the

functional integrity of the nerve, we decided to remove the neoplastic tissue as much as possible provided that there are no recorded waves. In the last step, before dural closure, we tried to stimulate at the region where the nerve exits the brain stem and at the region of entry into the internal acoustic meatus. If there was a recorded response using the baseline stimulus, we expected that the nerve is functionally intact while if the intensity needed had to be increased, then weakness was expected. If no response, an injury was predicted.





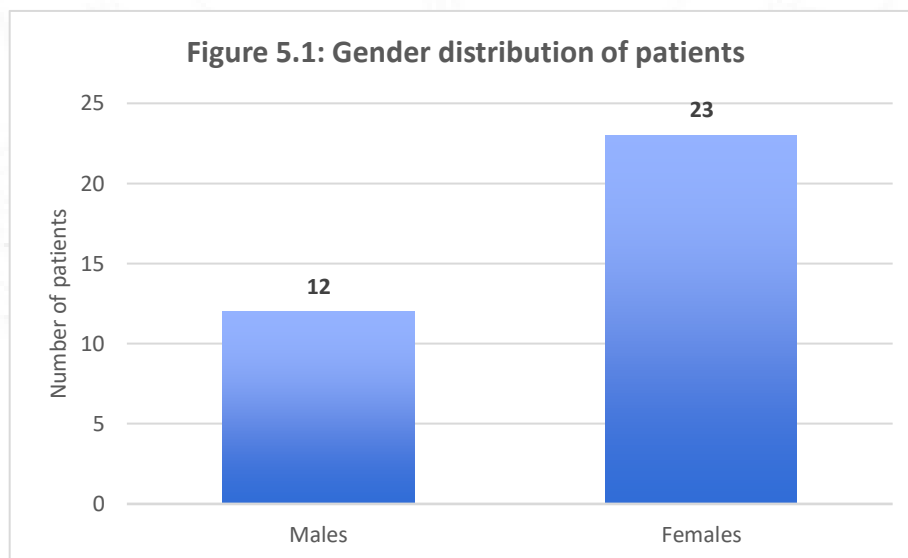
# **RESULTS**

## RESULTS

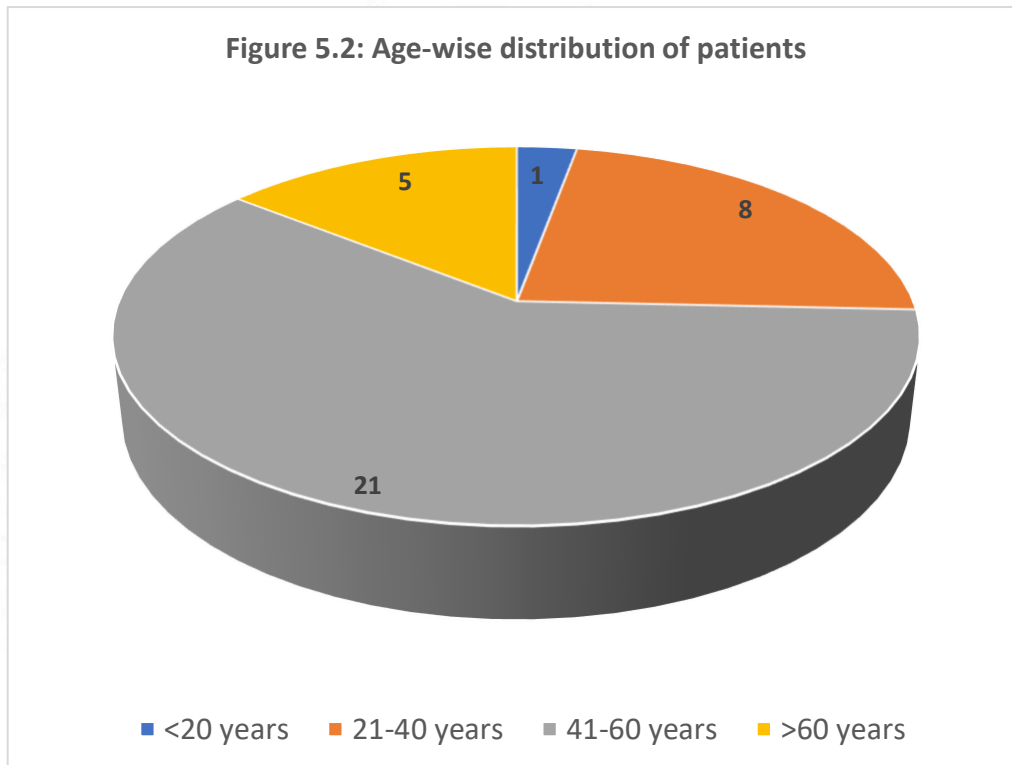
### 1. Demographic Details :

35 patients were enrolled in the study. The mean age was found to be 47.94 + 12.44 years. The range of age of enrolled patients was 17 to 65 years. Majority of enrolled patients were females (n=23) as shown in figure 5.1. Table 5.1 gives the demographic details of study.

<b>Table 5.1: Demographic details in study</b>	
<i>Parameter assessed</i>	<i>Calculated value</i>
Mean age (+ SD) (years)	47.94 + 12.44
Minimum age (years)	17
Maximum age (years)	65
Median age (years)	50
Number of males	12
Number of females	23



Majority of the enrolled patients in the study belonged to the age group of 41-60 years (n=21), followed by 21-40 years age group (n=8). (Figure 5.2).



## 2. IAC Canal extension and drilling:

In the study, 31 of the 35 enrolled patients had IAC canal extension. 25 of the 35 enrolled patients underwent IAC drilling in the study, as mentioned in table 5.2 below.

<b>Table 5.2: IAC Canal extension and drilling in study</b>		
	<i>Yes</i>	<i>No</i>
IAC Canal extension	31 (88.57%)	4 (11.43%)
IAC Drilling	25 (71.43%)	10 (28.57%)

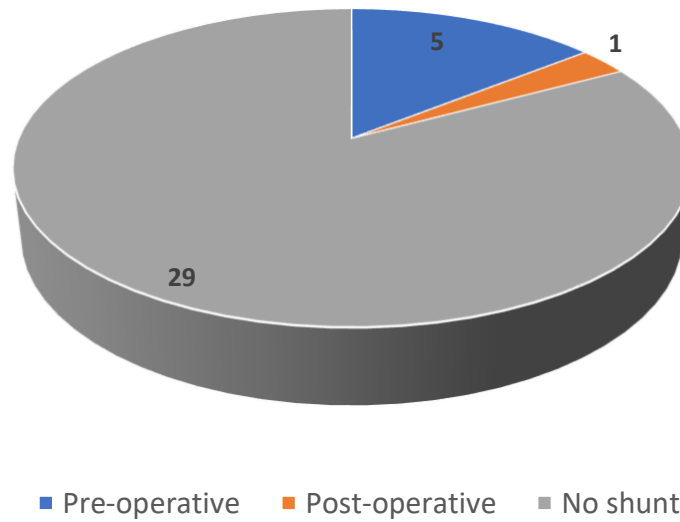
## 3. Hydrocephalus and shunt status:

15 of the 35 patients suffered from hydrocephalus in the study. Of these 15, 6 patients (40% of the hydrocephalus patients) underwent shunt placement in the study, as mentioned below in table 5.3.

<b>Table 5.3: Hydrocephalus and Shunt status in study</b>		
	<i>Yes</i>	<i>No</i>
Hydrocephalus present?	15 (42.86%)	20 (57.14%)
Shunt placed?	6 (17.14%)	29 (82.86%)

Of the 6 patients having shunts placed, pre-operative shunt placement was done in 5 patients while 1 patient had it done post-operatively. (Table 5.3)

**Figure 5.3: Shunt placement status of enrolled patients**



#### **4. Clinical symptoms in study:**

The first symptom noted most in the study was hearing loss (n=26), followed by headache and vomiting (n=4), while 2 patients had gait disturbance (n=2). (Table 5.4)

<b>Table 5.4: First symptom noted in patients</b>	
<i>First Symptom</i>	<i>Number of patients</i>
Gait disturbance	2 (5.71%)
Hearing loss	26 (74.29%)
Headache and vomiting	4 (11.43%)
Others	3 (8.57%)

## 5. Duration of Symptoms:

The mean duration of symptoms in the study was found to be 37.51 + 45.32 months. The median duration was noted to be 12 months, with a range of 2 months to 216 months. (Table 5.5)

<b>Table 5.5: Duration of Symptoms (months)</b>	
<i>Parameter assessed</i>	<i>Calculated value</i>
Mean duration of symptoms (months)	37.51 + 45.32
Median duration of symptoms (months)	12
Minimum duration of symptoms (months)	2
Maximum duration of symptoms (months)	216

## 6. Distribution of patients based on Duration of Symptoms:

Majority of the patients in the study were found to be suffering from clinical symptoms from less than one year (n=18). 10 patients suffered from symptoms from more than 5 years. (Table 5.6)

<b>Table 5.6: Distribution of patients based on Duration of Symptoms</b>	
<i>Duration of symptom</i>	<i>Number of patients</i>
<1 year	18 (51.43%)
1 year to 5 years	7 (20%)
>5 years	10 (28.57%)

**7. Per-operative electrophysiological and anatomical preservation:**

32 of the 35 enrolled patients were electrophysiologically preserved per-operatively while 34 of the 35 enrolled patients were anatomically preserved per-operatively (Table 5.7).

**Table 5.7: Per-operative electrophysiological and anatomical preservation status in study**

	<i>Yes</i>	<i>No</i>
Electrophysiological preservation	32 (91.43%)	3 (8.57%)
Anatomical preservation	34 (97.14%)	1 (2.86%)

**8. Pre-operative MRI Findings:**

27 of the 35 enrolled patients suffered from solid lesions while 3 patients had cystic lesion on MRI. 5 patients had both solid plus cystic lesion on MRI assessment. (Table 5.8)

**Table 5.8: Nature of lesions on MRI**

<i>Nature of lesion</i>	<i>Number of patients</i>
Solid	27 (77.14%)
Cystic	3 (8.57%)
Solid plus Cystic	5 (14.29%)

## 9. Facial nerve displacement:

22 of the 35 patients enrolled had facial nerve displacement in the antero-superior quadrant on MRI. 11 patients had the displacement in the antero-inferior quadrant on MRI evaluation (Table 5.9).

<b>Table 5.9: Facial nerve displacement on MRI</b>	
<i>Displacement</i>	<i>Number of patients</i>
Antero-inferior	11 (31.43%)
Antero-superior	22 (62.86%)
Postero-superior	1 (2.86%)
Postero-inferior	1 (2.86%)

### 10. Facial nerve outcome assessment on follow-up:

Pre-operatively, majority patients (n=31/35) had grade 1 eye closure. Post-operatively, 17 patients had grade 1 eye closure on day 2 or 3, 18 patients had grade 1 eye closure at 1 month follow-up while 20 patients had grade 1 eye closure at 3 months follow-up. At the 3-month follow up, 9 patients had either grade 3 or grade 4 eye closure (Table 5.10).

	<b>Time of Assessment</b>		
	<i>Post-op (day 2 or 3)</i>	<i>Post-op 1 month</i>	<i>Post-op 3 months</i>
Grade 1	17 (48.57%)	18 (51.43%)	20 (57.14%)
Grade 2	5 (14.29%)	6 (17.14%)	4 (11.43%)
Grade 3	8 (22.86%)	5 (14.29%)	5 (14.29%)
Grade 4	5 (14.29%)	5 (14.29%)	4 (11.43%)
Grade 5	0	0	1 (2.86%)

**11. Facial nerve outcome assessment:**

Pre-operatively as well as post-operatively on follow-ups, majority of the patients in the study had taste sensation present. Pre-operatively, 4 patients had taste sensation absent while 7 patients at 3-month follow-up had absent taste sensation (Table 5.11A).

<b>Table 5.11A: Facial nerve outcome assessment for taste sensation</b>			
	<b>Time of Assessment</b>		
	<i>Post-op (day 2 or 3)</i>	<i>Post-op 1 month</i>	<i>Post-op 3 months</i>
Present	23 (65.71%)	27 (77.14%)	27 (77.14%)
Absent	12 (34.29%)	7 (20%)	7 (20%)

Pre-operatively, 25 of the enrolled patients in study had grade 1 mouth weakness, while none of the patients had grade 4 or grade 5 mouth weakness. Post-operatively on day 2 or 3, 9 patients had grade 1 level mouth weakness, while 8 patients had grade 4 level mouth weakness. Post-operatively at 1 month follow-up, 14 patients had grade 1 mouth weakness, 9 patients had grade 2 mouth weakness, 5 patients had grade 3 mouth weakness, 4 patients grade 4 and 2 patients had grade 5 mouth weakness. Post-operatively at 3 months follow-up, 15 patients had grade 1 mouth weakness, 10 patients had grade 2 mouth weakness, 4 patients had grade 3 mouth weakness, 2 patients grade 4 and 3 patients had grade 5 mouth weakness. (Table 5.11 B)

<b>Table 5.11 B: Facial nerve outcome assessment for mouth weakness</b>			
	<b>Time of Assessment</b>		
	<i>Post-op (day 2 or 3)</i>	<i>Post-op 1 month</i>	<i>Post-op 3 months</i>
Grade 1	9 (25.71%)	14 (40%)	15 (42.86%)
Grade 2	10 (28.57%)	9 (25.71%)	10 (28.57%)
Grade 3	8 (22.86%)	5 (14.29%)	4 (11.43%)
Grade 4	8 (22.86%)	4 (11.43%)	2 (5.71%)
Grade 5	0	2 (5.71%)	3 (8.57%)

Pre-operatively, 28 of the enrolled patients in study had grade 1 forehead movement, 5 patients had grade 2 while 2 patients grade 3 forehead movement. None of the patients had grade 4 or grade 5 forehead movement pre-operatively. Post-operatively on day 2 or 3, 15 patients had grade 1 level forehead movement, 9 patients had grade 2, 4 patients had grade 3, while 7 patients had grade 4 level forehead movement. Post-operatively at 1 month follow-up, 16 patients had grade 1 forehead movement, 7 patients had grade 2 forehead movement, 5 patients had grade 3 while 4 patients grade 4 and 2 patients had grade 5 forehead movement. Post-operatively at 3 months follow-up, 17 patients had grade 1 forehead movement, 8 patients had grade 2, 4 patients had grade 3, 2 patients grade 4 and 3 patients had grade 5 forehead movement. (Table 5.11C)

<b>Table 5.11C: Facial nerve outcome assessment for forehead movement</b>			
	<b>Time of Assessment</b>		
	<i>Post-op (day 2 or 3)</i>	<i>Post-op 1 month</i>	<i>Post-op 3 months</i>
Grade 1	15 (42.86%)	16 (45.71%)	17 (48.57%)
Grade 2	9 (25.71%)	7 (20%)	8 (22.86%)
Grade 3	4 (11.43%)	5 (14.29%)	4 (11.43%)
Grade 4	7 (20%)	4 (11.43%)	2 (5.71%)
Grade 5	0	2 (5.71%)	2 (8.57%)

**12. Facial nerve function status at last follow-up in comparison to pre-operative status:**

The facial nerve function at last follow-up was compared to pre-operative status. For eye closure, 23 patients had similar status, 1 patient had better function while 11 patients worsened on last follow-up. For taste sensation, 23 patients had similar status, 7 patients had better function while 5 patients worsened on last follow-up. For mouth weakness as well as forehead movement both, 16 patients had similar status, 3 patients had better function while 16 patients worsened on last follow-up. (Table 5.12)

<b>Table 5.12: Facial nerve function status at last follow-up in comparison to pre-operative status</b>			
	Same as pre-op	Better than pre-op	Worse than pre-op
Eye closure	23 (65.71%)	1 (2.86%)	11 (31.43%)
Taste sensation	23 (65.71%)	7 (20%)	5 (14.29%)
Mouth weakness	16 (45.71%)	3 (8.57%)	16 (45.71%)
Forehead movement	16 (45.71%)	3 (8.57%)	16 (45.71%)

**13. Relation of symptom duration with facial nerve outcome :**

<b>Table 5.13: Comparison of mean symptom duration between those having stable or better outcome and worse outcome (facial nerve function)</b>			
	<i>Stable or better function at last follow-up</i>	<i>Worse function at last follow-up</i>	<i>P value</i>
Eye closure	30.92 + 32.91	51.90 + 64.51	<b>&lt;0.01*</b>
Taste sensation	39.6 + 48.11	35 + 31.19	0.32
Mouth weakness	29.68 + 28.52	46.81 + 59.24	<b>&lt;0.01*</b>
Forehead movement	28.61 + 27.45	47.79 + 53.67	<b>&lt;0.01*</b>

P value < 0.05 considered significant by unpaired t test

The subgroup of patients having worse outcomes for eye closure, mouth weakness and forehead movement at last follow-up had a significantly greater duration of symptoms ( $p < 0.05$ ) in comparison to the group of patients having stable or better outcome at last follow-up.

**14. Extent of resection and its impact on outcome:**

18 of the 35 enrolled patients underwent gross total resection (GTR) in study. 14 patients underwent near total resection while 3 patients underwent subtotal resection (Table 5.14).

<b>Table 5.14: Distribution of patients based on extent of resection</b>	
	<i>Number of patients</i>
Gross total resection (GTR)	18 (51.43%)
Near total resection (NTR)	14 (40%)
Subtotal resection (STR)	3 (8.57%)

The extent of resection had no significant association with the outcome of facial nerve assessment at the final follow-up ( $p>0.05$ ). (Table 5.14.1)

**Table 5.14.1: Association between EOR type and the patient outcome of facial nerve function at last follow-up**

<i>Function assessed</i>	<i>EOR</i>	<i>Stable or better function at last follow-up</i>	<i>Worse function at last follow-up</i>	<i>P value</i>
Eye closure	GTR	12	6	0.98
	NTR or STR	12	5	
Taste sensation	GTR	16	2	0.65
	NTR or STR	14	3	
Mouth weakness	GTR	10	8	0.99
	NTR or STR	9	8	
Forehead movement	GTR	10	8	0.99
	NTR or STR	9	8	

P value  $>0.05$  considered not significant by chi-square test

**15. Association between nature of lesion and the patient outcome of facial nerve function:**

Nature of lesion on MRI and its association with facial nerve functional outcome:

The nature of lesion on MRI evaluation had no significant association with the outcome of facial nerve assessment at the final follow-up, for any of the function evaluated ( $p>0.05$ ). (Table 5.15)

<b>Table 5.15: Association between nature of lesion and the patient outcome of facial nerve function at last follow-up</b>				
<i>Function assessed</i>	<i>Nature of lesion (MRI)</i>	<i>Stable or better function at last follow-up</i>	<i>Worse function at last follow-up</i>	<i>P value</i>
Eye closure	Solid	20	7	0.22
	Cystic	4	4	
Taste sensation	Solid	22	5	0.31
	Cystic	8	0	
Mouth weakness	Solid	15	12	0.99
	Cystic	4	4	
Forehead movement	Solid	15	12	0.99
	Cystic	4	4	

P value  $>0.05$  considered not significant by chi-square test

**16. Operative blood loss and its relationship with facial nerve functional outcome:**

The mean blood loss in the study was noted to be 1182.86 + 545.29 ml. The range of blood loss noted in the study was 400 ml to 2600 ml. (Table 5.16)

<b>Table 5.16: Blood loss during surgery (ml)</b>	
<i>Parameter assessed</i>	<i>Calculated value</i>
Mean blood loss	1182.86 + 545.29
Median blood loss	1200
Minimum blood loss	400
Maximum blood loss	2600

<b>Table 5.16.1: Association of Blood loss with size of lesion</b>	
<i>Size of lesion</i>	<i>Mean blood loss</i>
2-3 cm (n=7)	685.71 + 600
3-4 cm (n=19)	1178.95 + 597.75
>4 cm (n=9)	1366.67 + 357.07
<b>P value</b>	<b>&lt;0.01*</b>

P value < 0.05 considered significant by one-way ANOVA test

As mentioned in table 5.16.1 above, the mean blood loss increased with an increase in size of lesion. The difference between the different sub-groups divided based on size of lesion was statistically significant (p<0.05).

**17. Comparison of mean symptom duration between those having stable or better outcome and worse outcome:**

The subgroup of patients having worse outcomes for eye closure, mouth weakness and forehead movement at last follow-up had a significantly greater blood loss during surgery ( $p < 0.05$ ) in comparison to the group of patients having stable or better outcome at last follow-up.

**Table 5.17: Comparison of mean symptom duration between those having stable or better outcome and worse outcome (facial nerve function)**

	<i>Stable or better function at last follow-up</i>	<i>Worse function at last follow-up</i>	<i>P value</i>
Eye closure	1079.16 + 591.22	1409.09 + 353.43	<b>&lt;0.01*</b>
Taste sensation	1186.67 + 573.39	1160 + 378.15	0.54
Mouth weakness	1078.94 + 612.44	1406.25 + 440.41	<b>&lt;0.01*</b>
Forehead movement	1078.94 + 612.44	1406.25 + 440.41	<b>&lt;0.01*</b>

P value < 0.05 considered significant by unpaired t test

**18. Final outcome based on the size of lesion:**

Patients having lower size of lesion was found to be having lower grade of facial nerve functional outcome dysfunction, indicating better outcomes for patients with lower size of lesion. On the contrary,

majority patients with higher lesion size had a higher grade of functional outcome dysfunction at final follow-up, indicating that possibly higher size of lesion have greater facial nerve functional loss (Table 5.18).

<b>Table 5.18: Final outcome based on the size of lesion</b>						
<b>Size of lesion</b>	<b>Grade for final outcome at 3 months follow-up</b>					
	Absent	Grade 1	Grade 2	Grade 3	Grade 4	Grade 5
<b>Eye Closure</b>						
2-3 cm (n=7)	-	5	1	1	0	0
3-4 cm (n=19)	-	13	1	2	2	1
>4 cm (n=9)	-	2	2	2	2	0
<b>Taste Sensation</b>						
2-3 cm (n=7)	0	7*	-	-	-	-
3-4 cm (n=19)	4	15*	-	-	-	-
>4 cm (n=9)	3	5*	-	-	-	-
<b>Mouth Weakness</b>						
2-3 cm (n=7)	-	3	3	1		
3-4 cm (n=19)	-	11	3	2	1	2
>4 cm (n=9)	-	1	4	1	1	1
<b>Forehead Movement</b>						

2-3 cm (n=7)	-	3	3	1	0	0
3-4 cm (n=19)	-	12	2	2	1	2
>4 cm (n=9)	-	2	3	1	1	1

\* Indicates presence of taste sensation, 1 patient with >4 cm lesion loss follow up and hence not evaluated

In current study majority of cases were medium size and giant size of lesion. 07 patient out of 35 were between 2 to 3 cm, 19/35 were in size between 3 to 4 cm and 9/35 patients were giant lesion( > 4 cm). There were no lesion less than 2 cm of size was in current study.

#### **Eye Closure-**

Lesion size between 2 to 3 cm - 5/7 patient had grade 1 and one each had grade 2 and grade 3 as final out come of eye closure.

Lesion Size between 3 to 4 cm – 13/19 patient had grade 1, 1 patient had grade 2, 2 patient had grade 3 and grade 4 each, 1 patient had grade 5 eye closure as final out come.

Lesion size > 4 cm – 2 out of 9 patient had grade 1,2,3,4 each and none of the patient had grade 5 eye closure deficit.

#### **Taste Sensation-**

Lesion size between 2 to 3 cm – all 7 patient had no loss of taste sensation post operatively.

Lesion size between 3 to 4 cm – 4/19 patient had loss of taste sensation and 15 patient does not have any loss of taste sensation post operatively.

Lesion size > 4 cm – 3 out of 9 patient had loss of taste sensation and 5 patient had no loss of taste sensation post operative period.

#### **Mouth weakness-**

Lesion size between 2 to 3 cm – 3 patients had grade 1 and 2 each and 1 patient had grade 3 of mouth weakness in post operative period.

Lesion size between 3 to 4 cm – 11/19 patient had grade 1, 3 patients had grade 2, 2 patient had grade 3, 1 patient had grade 4 each and 2 patient had grade 5 of mouth weakness in post operative period.

Lesion size > 4 cm – 1 out of 9 patient had grade 1, 4 patient had grade 2 and 1 patient each had 3,4 and grade each and none of the patient had grade 5 eye closure deficit.

#### **Forehead Movement-**

Lesion size between 2 to 3 cm – 3 patients had grade 1 and 2 each and 1 patient had grade 3 of forehead movement in post operative period.

Lesion size between 3 to 4 cm – 12/19 patient had grade 1, 2 patients had grade 2 and grade 3 each, 1 patient had grade 4 and 2 patient had grade 5 forehead movement in post operative period.

Lesion size > 4 cm – 2/9 patient had grade 1, 3 patient had grade 2 and 1 patient each had 3,4 and grade 5 in post operative period.

### **19. Final outcome based on IAC Drilling in surgeries done by single surgeon of department:**

On analysing the final follow-up outcome based on IAC Drilling in surgeries done by single surgeon, who has massive experience, it was found that no major difference in final outcome of facial nerve was

noted in between those who had IAC drilling and those who did not undergo IAC drilling however with drilling better extent of resection was achieved (table 5.19).

<b>Table 5.19: Final outcome based on the IAC Drilling (n=24/25) one patient lost follow up</b>						
<b>IAC Drilling status</b>	<b>Grade for final outcome at 3 months follow-up</b>					
	<b>Absent</b>	<b>Grade 1</b>	<b>Grade 2</b>	<b>Grade 3</b>	<b>Grade 4</b>	<b>Grade 5</b>
<b>Eye Closure</b>						
IAC Drilling not done (n=4)	-	3	0	1	0	0
IAC Drilling done (n=21)	-	11	2	5	2	0
<b>Taste Sensation</b>						
IAC Drilling not done (n=4)	1	3*=present	-	-	-	-
IAC Drilling done (n=21)	3	17*=present	-	-	-	-
<b>Mouth weakness</b>						
IAC	-	2	1	1	0	0

Drilling not done (n=4)						
IAC Drilling done (n=21)	-	9	5	2	2	2
<b>Forehead Movement</b>						
IAC Drilling not done (n=4)	-	2	1	1	0	0
IAC Drilling done (n=21)	-	11	3	2	2	2

\* Indicates presence of taste sensation, 1 patient with IAC drilling lost follow up and hence not evaluated



# **DISCUSSION**

## DISCUSSION

Vestibular schwannoma surgery and use of IONM is well established technology used in neurosurgery, however prospective studies in this regard are very less in number and to access the real data in India were missing, the aim of this prospective observational study was to establish the Indian data for the purpose of establishing our own facts for future references.

The aim of current study is to evaluate whether the use of electrophysiology can help to increase the extent of resection while preserving good postoperative facial nerve function in the case of difficult surgical scenario while dissecting the facial nerve from the tumour.

Previously multiple studies evaluated pre/per and post-operative predictors of long-term facial nerve outcomes. Most common factors are noticed for predicting worse postoperative facial nerve outcomes include large tumour size, medial(cisternal) location, per-op nerve manipulation, neurophysiologic monitoring feedback, immediate postoperative HB grade, and the presence of preoperative facial nerve palsy.

Surgical experience often allows the complete removal of large vestibular schwannomas with functional preservation of the facial nerve, and it remains the one of the best treatments because it is definitive. In contrast, to get normal postoperative facial function, partial resection has been advocated since the reports of Cushing. Formerly published literature analysis showed that near total resection is optimal in cases where the facial nerve is in peril while resection (dense adhesion with poor plane between the nerve, pia-mater, and tumor). By using partial resection strategy the patient should be able to retain normal facial function with a very small tumour remnant, but this residue will require additional treatment by stereotactic radiosurgery. (higher risk of FN palsy)

Postoperative recovery of FN function is recorded with wide variation in previous studies, with improvement over the course of weeks to years. This certainty made FN function the core of many studies; however, clinical characteristics and prognostic factors continue to be defined. Recovery of nerve function depends on the recovery of axonal stretch injury, strengthening of remaining motor synapses at the neuromuscular junction, and even cortical reorganisation and sensorimotor reintegration.

processes. In present era electrophysiological monitoring capabilities fail to predict which patients will be left with “poor” facial function after surgery (HB grade IV or worse), which is not allowing to the use of these devices for per-operative decision-making considering definitive correction as neural grafting techniques.

Only few articles and data comprise the timeline of recovery for patients with preoperative palsy, and the prognosis of facial nerve function in these patients. “An early report by Neely and Neblett in 1983 described three patients with preoperative FN palsy. All three of these patients with preoperative palsy had HB grade VI facial nerve function postoperatively”. However, this finding is likely due to the historical nature of this study and its not true representation of facial nerve outcomes in the current era of advanced microsurgical resection techniques. “Inamasu described in 2000, 02 patients with preoperative HB grade II facial palsy, both of them remained stable at 6-month follow-up”. In view of Pandemic we are unable to achieve the number required for long term follow up and no conclusion could me made, however its notice that that recovery of facial nerve can be seen even in first 3 months of post operative period if the nerve is well preserved electrophysiologically and anatomically.

The Facial nerve displacement is more common in anterior part of lesion, while doing surgery we should consider the pre operative imaging to read the position of the facial nerve in respect to the lesion and we should planed the surgery and decompression of lesion according to the displacement of the facial nerve. In Current study 33 patient out of 35 were having facial nerve displacement anteriorly and out which 11(31.43%) patient were having antero-inferiorly and 22 (62.86%) were having antero-inferiorly. Only 2 patient out of 35 were having posterior displacement of facial nerve. With this findings we can consider the early decompression of lesion as posterior aspect and reduce the risk of facial nerve injury.

In this present study, 28/35 patients had either a large or giant sized VS. Majority of our patients sought medical attention at a stage when they developed disabling hearing loss (74.29%) and/or the symptoms of raised intra-cranial pressure. Pre-operative VP shunt was not required in majority of the patients, but few patients reported late with signs of raised intra-cranial pressure and underwent shunt procedures. In the present study the pre-operative shunt was done in 5 patients before definitive surgery and 01 patient in post operative period

underwent shunt placement. The incidence of preoperative shunt was only 17.14% however it was noticed in literature as high as 66% in the series reported by Ramamurthi et al.

Gross total resection of tumor was achieved in 51.43% (18/35) and Near total resection was achieved in 40% (14/35) of the patients. “Yamakani reported complete tumor excision in 86% patients by retro-mastoid approach for large acoustic tumors”. “Lanman reported a higher rate (96.3%) of total removal by the trans-labyrinthine approach”. [31] Ebersold [32] achieved total tumor resection in 97.2% (249/256) by retro-mastoid approach for tumors of all sizes. Samii [16] reported complete excision in 97.9% patients by sub-occipital trans-meatal approach.

Anatomical preservation of facial nerve was achieved in 97.14 % (34/35) of patients and electrophysiologically preservation was done in 91.43% (32/35) of patient. In previously published literatures the anatomical preservation rate is 80-90% with the removal of large tumors either by the trans-labyrinthine approach [31,34,35] or by the retro-mastoid approach. [33,36] Other authors have reported the anatomical preservation of the facial nerve for tumors > 4 cms ranging from 89% to

92% by trans-labyrinthine approach[37-40] and 78%-94% by sub-occipital-retro-sigmoid approach [36,40] Samii and Matthias reported preservation rate of 87% with tumor size >3 cm until 1988, but in most recent 200 cases preservation rates rose to 94% independent of tumor size.[40] According to Whittaker et al a surgeon operating less than 12 cases per year cannot expect to get equal results of large series. The tumour size, is one of the critical factors responsible for the preservation of the FN function, having a reciprocal relationship i.e. larger the size of tumor lesser the chances of preservations[31,36] was also observed in this present study.

In our small series, 68% patients had stable to improved facial nerve outcomes after surgery. However preoperative facial nerve status may be more important for determining long-term outcome than immediate postoperative HB grade.

Imaging characteristics and surgical goals must be carefully considered in these patients, and it is noteworthy that in this series the tumors were relatively large (mean: 3.76 cm), often solid. This current study also showed that tumour size is well associated to per-operative bleeding and final out come of the facial nerve.

Single the most experience surgeon's data was extracted from the study data and analysed separately in which comparison of drilling of IAC and removal of lesion with the lesion which were not extended to IAC and didn't underwent drilling of IAC were compared. It's a well established fact that drilling of IAC will cause more morbidity and risk of bleeding due to sinus injury and injury to nerve at IAC is more, however with this risk if we are able to remove the lesion from the IAC, than we will be able to achieve more clearance of lesion and low chance of residual with low risk of recurrence. With this intended 25 patient were taken for the surgery and out of which 24 were followed up to 3 months. We were not able to find any deterioration of facial nerve outcome in comparison to other studies where no IAC drilling was done and complete removal of the lesion was not achieved. This analysis also suggested that with good experience there was similar facial nerve outcome can be achieved with more clearance of lesion with the drilling of IAC and removal of lesion.

On the basis of above results, we recommend that a venture at gross-total resection should be pursued, but only in a prudent manner, with an acceptance of residual tumor in cases in which the tumor cannot

be safely dissected from the facial nerve. These are tough decisions that must be made per-operatively by experienced surgeons; however, even with subtotal resection, good decompression of the facial nerve and surrounding structures can be achieved. Patients with subtotal resection must be followed, and further treatment would come with an increased risk for facial nerve outcomes.

**Facial nerve preservation-** In our study tumour size was significantly related to post-operatively facial nerve function. The correlation between the tumour size and postoperative outcome of facial nerve is accepted. In previous studies the incidence of facial nerve palsy was 80% for the tumour size between 2 to 3cm in diameter and it was 46% in larger tumours greater than 3 cm in diameter. Tumour size is most important predictor of facial nerve palsy. In current study there were no significant difference seen between solid or cystic lesion excision and outcome of facial nerve (it was probably a small number in study), however in previous studies suggestive of cystic lesion are having poor facial nerve outcome. Thus we recommend that NTR is good surgical strategy for cystic vestibular schwannoma, however if surgeon experience is good then we should go for maximal safe resection even in cystic lesions.

## **Limitation and drawbacks of study-**

### **Advantage-**

- Same type of treatment modalities used for all patient and surgeons goes for surgeries with intend to get maximum safe resection. (No heterogeneous treatment in series).
- Pre-operative facial nerve palsy patient were also included in this series to find out the difference between pre op and post op palsy outcome differences.
- Separate assessment of the components of facial nerve (Eye closure/Taste/forehead movement/deviation of angle of mouth) were done in this study to understand the various components of the HB grade of facial nerve palsy.

### **Limitation-**

- Follow up is only 3 months.
- In view of our institute being tertiary care centre, the size of lesion reported to this institute were more in the medium and giant category, so final out come of facial nerve is difficult to compare with previous studies.

- Time taken to achieve the number in this prospective study and follow up were severely affected by the current pandemic so follow up was not able to kept for longer period.
- Further improvement of their facial function over a longer period cannot be ruled out.
- It can be difficult to distinguish large vestibular schwannomas causing mass effect on the facial nerve from a true facial nerve schwannoma. The large size of these tumors might obscure their true nerve origin.

### Various Studies and their result

1 <sup>st</sup> Author, year and country	No of patient	Mean age in year	Gender	Mean Tumour Size in mm	Approach	EOR	Preservation of 7 <sup>th</sup> nerve	Outcome in HB grading
Vijendra K Jain India 2021	259 (9 died on post op)	11 to 78	M-151 F- 108	Giant (>40 mm)-56% Large(25-40mm)-41.3% Medium (10-25 mm)- 2.7%	RSSO	Complete removal in 250 patients (96.5%)	79.2% (198/250) Giant- 76.5% Large- 81.3% Medium- 100%	Grade 1&2 Giant- 21/69 Large-31/67 Medium-2/2  Grade 3&4 Giant-36/69 Large- 28/67 Medium- 0/2  Grade 5&6 Giant-12/69 Large-0/6 Medium- 0/2

<b>1<sup>st</sup> Author, year and country</b>	<b>No of patient</b>	<b>Mean age in year</b>	<b>Gender</b>	<b>Mean Tumour Size in mm</b>	<b>Approach</b>	<b>EOR</b>	<b>Preservation of 7<sup>th</sup> nerve</b>	<b>Outcome in HB grading</b>
Chang S Canada 2019	434	49.1	M- 213 F- 221	26+/- 1	RSSO- 85% TLA- 7.3% MFA- 3.9%	GTR- 83% NTR- 9.0% STR-8.1%	NA	Grade1 & 2- 96% Grade 3 & 4- 4%
Luciano Italy 2020	26 (Cystic VS)	53.5+/- 12.9	M- 15 F- 11	32	RSSO	GTR & NTR - 16/26 STR- 9/26 PR- 1/26	-	Grade1- 72% (18/26) Grade2- 6/26 Grade3- 2/26

<b>1<sup>st</sup> Author, year and country</b>	<b>No of patient</b>	<b>Mean age in year</b>	<b>Gender</b>	<b>Mean Tumour Size in mm</b>	<b>Approach</b>	<b>EOR</b>	<b>Preservation of 7<sup>th</sup> nerve</b>	<b>Outcome in HB grading</b>
Ashraf Mohamed Egypt 2019	32 (IONM-100%)	-	M-10 F- 22	-	-	NTR- 62.5% STR- 37.5%	-	Grade 1- 68.75% Grade 3 – 6.25% Grade 4- 12.5% Grade 6- 12.5% Grade 2 and 5- 0%

<b>1<sup>st</sup> Author, year and country</b>	<b>No of patient</b>	<b>Mean age in year</b>	<b>Gender</b>	<b>Mean Tumour Size in mm</b>	<b>Approach</b>	<b>EOR</b>	<b>Preservation of 7<sup>th</sup> nerve</b>	<b>Outcome in HB grading</b>
Ismail Taha Finland 2019	95 (NTR+ CK radio Sx)	54	M-37 F- 58	29.66+/- 15	RSSO	<b>GTR-</b> Gr1&2- 29.9% Gr3&4- 28.6% Gr5&6 33.3% <b>NTR</b> Gr1&2- 60.3% Gr3&4- 71.4% Gr5&6- 46.7%		Grade 1&2- 67% Grade3&4- 16% Grade 5&6- 17%

<b>1<sup>st</sup> Author, year and country</b>	<b>No of patient</b>	<b>Mean age in year</b>	<b>Gender</b>	<b>Mean Tumour Size in mm</b>	<b>Approach</b>	<b>EOR</b>	<b>Preservation of 7<sup>th</sup> nerve</b>	<b>Outcome in HB grading</b>
Huang X China 2018	103	47.5	M- 48 F- 55	32	NA	NA	Only intact included	Grade 1&2- 76% Grade 3&4- 24%
Muhammad Shaheryar Pakistan 2018	27	43	M- 18 F-9	>40 (in 77.7%) 30-40 (in 33%)	RSSO	NA	NA	Grade 1&2- 29.6% Grade 3&4- 55.5% Grade 5- 14.81
Hong WM China 2017	105 (IOM used in 83.1%)	48.7	M-41 F- 64OF	>30 (90.5%)	RSSO	GTR- 80.9% NTR- 14.3% PR-4.8%	95.3%	Grade 1&2- 74.4%

<b>1<sup>st</sup> Author, year and country</b>	<b>No of patient</b>	<b>Mean age in year</b>	<b>Gender</b>	<b>Mean Tumour Size in mm</b>	<b>Approach</b>	<b>EOR</b>	<b>Preservation of 7<sup>th</sup> nerve</b>	<b>Outcome in HB grading</b>
Boublata L Algeria 2017	151	48.2	M-43 F- 98	31-60	RSSO	GTR/NTR- 82.6% STR- 13.9% PR- 3.3%	89.6%	Grade 1&2- 82% Grade 3 & 4 - 12% Grade 5-6.6 %
Huang X China 2017	1167 (IONM in 82%)	47.5	M- 535 F- 632	>30	RSSO	GTR- 86.2% STR- 13.6% PR- 0.2%	92.8%	Grade 1&2- 87.9% Grade 3&4- 11.6% Grade 5&6- 0.3%
Huang X China 2017	657	46.8	M-368 F-289	>40	RSSO	GTR- 84.6% NTR- 15.1% PR- 0.3%	89.6	Grade 1&2- 55.8% Grade 3 - 19.8% Grade 4-6- 24.4%

<b>1<sup>st</sup> Author, year and country</b>	<b>No of patient</b>	<b>Mean age in year</b>	<b>Gender</b>	<b>Mean Tumour Size in mm</b>	<b>Approach</b>	<b>EOR</b>	<b>Preservation of 7<sup>th</sup> nerve</b>	<b>Outcome in HB grading</b>
Bhimrao S Canada 2016	367	49	M- 178 F- 189	26+/- 10	RSSO- 87% TLA- 10% MFA- 3%	STR-9%	NA	Grade 1&2- 95% Grade 3&4- 4.2% Grade 5&6- 0.6%
Kunert P Poland 2016	212	< 50- 121 >50 -91	M- 83 F- 129	30	RSSO- 99% TLA- 1%	GTR- 99% NTR- 1%	84-94%	Grade 1-3- 77% Grade 4-6- 23%
Nejo T Japan 2016	556 D- 21 ND- 535	46	M- 246 F- 310	D-28 ND- 24	RSSO	GTR & NTR- D- 38.1% ND- 85.4% STR-8.1%	D- 100% ND-99.4%	Grade 1&2- D- 95.2% ND- 97%

<b>1<sup>st</sup> Author, year and country</b>	<b>No of patient</b>	<b>Mean age in year</b>	<b>Gender</b>	<b>Mean Tumour Size in mm</b>	<b>Approach</b>	<b>EOR</b>	<b>Preservation of 7<sup>th</sup> nerve</b>	<b>Outcome in HB grading</b>
Zhang J China 2015	221	46.1	M-105 F- 116	>30 (82.8%) <30(17.2%)	RSO	NTR- 90% STR-10%	NA	Grade 1-3- 82.8% Grade4- 7.2% Grade5- 10%
Liu SW China 2015	106	48	M- 40 F-66	>30	RSSO	GTR- 82.1% STR- 14% PR- 3.7%	98.1%	Grade1&2- 79.3% Grade 3- 20.8% Grade 4- 0.9%
Spector S Israel 2015	130	44.3	M- 54 F- 76	30+/- 11	NA	GTR- 76.1% STR-20% PR- 3.9%	NA	Grade1&2- 83.1% Grade3&4- 13.1% Grade 5&6- 4.7%

<b>1<sup>st</sup> Author, year and country</b>	<b>No of patient</b>	<b>Mean age in year</b>	<b>Gender</b>	<b>Mean Tumour Size in mm</b>	<b>Approach</b>	<b>EOR</b>	<b>Preservation of 7<sup>th</sup> nerve</b>	<b>Outcome in HB grading</b>
Zhang X China 2005	105	46.8	M- 41 F- 64	>40	RSSO	GTR- 86.7% STR- 13.3%	79.1%	Grade 1&2- 56.7% Grade 3&4- 21.8% Grade 5- 21.9%
Magnan France 2002	119	NA	NA	<25	RSSO	NA	100%	Grade 1&2- 96% Grade 3&4- 24%
Tonn J-C Germany 2000	508 (IOM- 80%)	51.3	M- 263 F- 245	8-40	RSS)	NA	NA	Grade 1&2- With IOM- 88.7% Without IOM- 69.5%



# **CONCLUSIONS**

## CONCLUSION

Despite the high proportion of large lesion in this series, our study of facial nerve outcome is comparable to other previous literature. Among so many factors affecting the facial nerve outcome like surgeon experience, solid or cystic nature, involvement of IAC, per-op facial nerve involvement, however, the most important one is tumour size. The larger the lesion will have poor outcome postoperatively and cut of the size of lesion in few previous literature are mentioned as 2 cm , however in current study its 4 cm and more.

With the above findings, we can recommend that avoid the wait and watch policy and in this new era of microsurgical techniques and Intra-operative nerve monitoring approach we should diagnose lesion early and cut off limit for a good outcome of surgery is less than 4 cm. In our recommendation tumour size for surgery is  $> 2$  cm and  $< 4$  cm, except in elderly where we can still use wait and watch policy. If we are going for surgery for lesion  $> 4$  cm, pre-operative counselling for poor facial nerve outcome to be expected.

Another observation in our study is about cystic lesion of vestibular schwannoma, these patient will have a poor outcome of the

facial nerve after surgery if we are going for GTR, however if a good experience surgeon is operating than even in cystic lesion we can expect a good post op outcome one. So if young surgeon with less experience is operating a cystic lesion or a solid lesion with poor planes seen on imaging pre-operatively, than he can plan for subtotal resection of facial nerve and counsel the patient pre-operatively. Appropriate selection of cases, meticulous surgical techniques and IONM are pivotal for good facial nerve outcome in this ear.

The future of facial nerve preservation with IONM in vestibular schwannoma's patients is the pre-operative analysis of FN with use of neuronavigation on based of DTI sequence of MRI identification of facial nerve per-operatively.



# **BIBLIOGRAPHY**

1. Samii M, Turel KE, Penkert G: Management of seventh and eighth nerve involvement by cerebellopontine angle tumours. *Clin Neurosurg* 32: 242, 1985.
2. Grossman RG, Loftus CM (eds): *Principles of Neurosurgery*, ed 2. Philadelphia: Lippincott- Raven, 1999.
3. Robinson K, Rudge P: The differential diagnosis of cerebellopontine angle lesions. *J Neurol Sci* 60; 1,1983.
4. Eldridge R, Parry D: Summary: Vestibular Schwannoma (Acoustic Neuroma) consensus development conference. *Neurosurgery* 30: 962-964, 1992.
5. Harner SG, Ebersold MJ : Management of acoustic neuromas. *J Neurosurg* 63: 175, 1985.
6. Sambasivan M, Mathai KV, Chandy J: Surgical experience with eighty cases of acoustic neurinomas. *Neurol (India)* 14:125, 1966.
7. Moskowitz N, Long, DM. Acoustic neurinoma. Historical review of a century of operative series. *Neurosurgery Quarterly* 1991; 1; 2-18.
8. Kileny P, Kemink J, Tucci D, Hoff J. Neurophysiologic intraoperative facial and auditory function in acoustic neuroma surgery. In: Tos M, Thomson J, eds. *Acoustic Neuroma: Proceedings of the First International Conference on Acoustic Neuroma*, Amsterdam/New York: Kugler Publications, 1992: 569-74.
9. Ahn MS, Jacler RK, Lusting LR: The early history of the neurofibromatosis. *Arch Otolaryngol Head Neck Surg* 122: 1240-1249, 1996.
10. Theofilos G. Machinis, et al. History of acoustic neurinoma surgery; *Neurosurgery Focus* 18(4): April 2005.
11. Stone JL: Sir Charles Balance: Pioneer British Neurological Surgeon. *Neurosurgery* 44: 610-632, 1999.
12. Prakash Sampath et al. Facial nerve injury in acoustic neuroma (vestibular schwannoma) surgery: etiology and prevention: *J Neurosurgery* 87: 60-66, 1997.
13. Rand RW, Kurz T. Preservation of vestibular, cochlear, and facial nerves during microsurgical removal of acoustic tumors. Report of two cases. *J Neurosurgery* 28: 158-161, 1968.
14. Tew JM Jr: M. Gazi Yasargil. Neurosurgery's man of the century. *Neurosurgery* 45: 1010-1014; 1999.
15. Samii M, Matthies C: Management of 1000 vestibular schwannomas: hearing function in 1000 tumour resections. *Neurosurgery* 40: 248-262; 1997.

16. Gharabhahi A, Samii A, Koerbel A, Rosahi SK, Tatagiba M, Samii M. Preservation of function in vestibular schwannoma surgery. *Neurosurgery* 60(2Suppl): ONS124-ONS128, 2007.
17. May M, Wiet RJ. Iatrogenic injury: prevention and management. In; May M, ed. *The Facial Nerve*, New York; Thieme Medical Publisher, 1986; 549-560.
18. Brackmann DE. A review of acoustic tumors: 1979-1982. *Am J Otol* 1984; 5: 233-244.
19. Richard M. Lehman, M.D. A review of neurophysiological testing. *Neurosurg Focus* 1694): Clinnical Pearl1, 2004.
20. Kartush JM, Lundy LB. Facial nerve outcome in acoustic neuroma surgery, *Otolaryngol Clin North Am*, 1992; 25: 623-647.
21. Williams JD , Lehman R. Bells against palsy. *Am J Otol* 1988; 9; 81-82.
22. Delgado TE, Bucheit WA, Rosenholtz HR, Chrissian S. Intraoperative monitoring of the facial muscle evoked responses obtained by intracranial stimulation of the facial nerve; a more accurate technique for facial nerve dissection. *Neurosurg* 1979; 4; 418-421.
23. Sugita K, Kobayashi S. Technical and instrumental improvements in the surgical treatment of acoustic neurinomas. *J Neurosurg* 1982; 57; 747-752.
24. Moller AR, Jannetta PJ. Preservation of facial function during removal of acoustic neuromas; use of monopolar constant voltage stimulation and EMG. *J Neurosurg* 1984; 61; 757-760.
25. Niparko JK, Kileny PR, Kemink JL, Lee HM, Graham MD; *Am J Otol*, 1989 Jan; 10(1): 55-61.
26. Ebersold M, Harner SG, Beatty CW, et al. Current results of the retrosigmoid approach to acoustic neurinoma. *J Neurosurg* 76; 901-909, 1992.
27. Taha JM, Tew JM Jr, Keith RW. Proximal to distal facial amplitude ratios as predictors of facial nerve function after acoustic neuroma excision; *J Neurosurg* 83; 994-998, 1995.
28. Sobottka SB, Sachackert G, May SA, Wiegleb M, Reis G. Intraoperative facial nerve monitoring predicts facial nerve outcome after resection of vestibular schwannoma. *Acta Neurochir (Wien)* 140; 235-242, 1998.
29. Goldbrunner RH, Schlake HP, Christian M, Tonn JC, Jan Helms, Klaus R. *Neurosurgery*, Vol.46, No. 5, May 2000: 1140-1148.

30. Isaacson B, Kileny PR, El-Kashlam H, Gadre AK. Intraoperative monitoring and facial nerve outcomes after vestibular schwannoma resection. *Otol Neurotol*. 2003 Sep; 24(5):812-817.
31. Lanman TH, Brackmann DE, Hitselberger WE, Subin B. Report of 190 consecutive cases of large acoustic tumors (vestibular schwannoma) removed via the translabyrinthine approach. *J Neurosurg* 1999;90:617-23. 14.
32. Ebersold MJ, Harner SG, Beatty CW, Harper CM, Quast LM. Current results of the retromastoid approach to acoustic neurinoma. *J Neurosurg* 1992;76:901-9.
33. Samii M, Matthies C. Management of 1000 vestibular schwannomas (acoustic neuromas): Surgical management and results with an emphasis on complications and how to avoid them. *Neurosurgery* 1997;40:11-23.
34. Sluyter S, Graamans K, Tulleken CA, et al. Analysis of the results obtained in 120 patients with large acoustic neuromas surgically treated via the translybrinthine-transtentorial approach. *J Neurosurg* 2001;94:61-6.
35. Mamikoglu B, Weit RJ, Esquivel CR. Translabrynthine approach for the management of large and giant vestibular schwannomas. *Otol Neurotol* 2002;23:224-7.
36. Ebersold MJ, Harner SG, Bealy CW, et al. Current results of the retromastoid approach to acoustic neurinomas. *J Neurosurg* 1992;76:901-9.
37. Tos M, Thomsen J, Harmsen A. Results of translabyrinthine removal of 300 acoustic neuromas related to tumor size. *Acta Otolaryngol Suppl* 1988;452:38-51.
38. Sterkers JM, Morrison GA, Sterkers O, El-Dine MM. Preservation of facial, cochlear, and other nerve functions in acoustic neuroma treatment. *Otolaryngol Head Neck Surg* 1994;110:146-55.
39. Briggs RJS, Luxford WM, Atkins JS, Hitselberger WE. Translabyrinthine removal of large acoustic neuromas. *Neurosurgery* 1994;34:785-92.
40. Samii M, Matthies C. Management of 1000 vestibular schwannomas (acoustic neuromas): The facial nerve –preservation and restitution of function. *Neurosurgery* 1997;40:684-95.



# **ANNEXURE**



**Appendix -1**

Face	Grade	Characteristics
<b>Forehead</b>	<b>I.</b> Normal	Normal function
	<b>II.</b> Mild dysfunction	Slight weakness to good function
	<b>III.</b> Moderate Dysfunction	Noticeable slight to moderate movement
	<b>IV.</b> Moderately severe Dysfunction	Obvious weakness or disfiguring asymmetry
	<b>V.</b> Severe Dysfunction	Barely perceptible motion
	<b>VI.</b> Total paralysis	No movement
<b>Eye</b>	<b>I.</b> Normal	Normal Function
	<b>II.</b> Mild Dysfunction	Complete closure with minimal effort
	<b>III.</b> Moderate Dysfunction	Obvious weakness, eye closure with effort
	<b>IV.</b> Moderately severe Dysfunction	Incomplete eye closure
	<b>V.</b> Severe Dysfunction	Barely perceptible eye movement
	<b>VI.</b> Total Paralysis	No movement
<b>Mouth</b>	<b>I.</b> Normal	Normal Function
	<b>II.</b> Mild Dysfunction	Slight asymmetry or weakness of mouth movement
	<b>III.</b> Moderate Dysfunction	Obvious but no disfiguring weakness
	<b>IV.</b> Moderately Severe Dysfunction	Asymmetry at rest
	<b>V.</b> Severe Dysfunction	Barely perceptible mouth movement
	<b>VI.</b> Total Paralysis	No movement

**Appendix -2**

Taste can be objective in terms of the five tastes (sweet, salt, sour, bitter, and savory) but it can also be subjective in terms of what we deem "good" and "bad." Taste is "subjective, objective, and qualitative". We are going to check only subjective taste sensation in anterior 2/3<sup>rd</sup> part of tongue.

**Procedure of testing Taste-**

1. After rinsing the oral cavity we will ask patient to drink plain water approximates 20 ml.
2. We will put sweet solution over the operated side of anterior 2/3<sup>rd</sup> part of the tongue.
3. We will ask the patient about to categorize the taste. (sweet/salt)
4. Later we will put salt solution over the operated side of anterior 2/3<sup>rd</sup> part of the tongue.
5. We will ask the patient about to categorize the taste. (sweet/salt).

## INFORMATION SHEET

**TITLE OF THE STUDY: Clinical outcome after electrophysiologically and anatomically preserved 7<sup>th</sup> nerve in vestibular schwannoma patients.**

**Study number:** \_\_\_\_\_

**Participant's name:** \_\_\_\_\_

**Date of Birth / Age (in years):** \_\_\_\_\_

**Son/daughter of** \_\_\_\_\_

**Q. What is vestibular schwannoma?**

Ans- It's a benign tumor that develops on a nerve in the ear that connects the inner ear to the brain. It affects balance and hearing.

**Q. What is the treatment for vestibular schwannoma?**

Ans- vestibular schwannoma are treated with observation, surgery or radiation, depending on the tumors size, the patients symptoms, and the age of the patient. Small asymptomatic tumors may require no treatment other than observation. Small symptomatic or large symptomatic tumors can be treated either by surgical removal or stereotactic radiosurgery.

**Q. What is the surgery for Vestibular Schwannoma?**

Ans- Vestibular schwannoma surgery takes place within a hospital setting while you are under general anesthesia. The first step is a craniotomy, the removal of a small section of skull, so the surgeon can access the location of your tumor. He or she will remove as much of the tumor as possible, taking care to disturb as little of the surrounding tissues as possible. Because of the location of vestibular schwannomas, there are many important nerves nearby. Sometimes removing an entire tumor increases the risk of hearing loss or facial weakness, because it is so close to the responsible nerves. If so, your surgeon may choose to leave some of the tumor behind and use radiation therapy following surgery to eradicate any remaining cells. Once all or part of the tumor has been removed, the vestibular schwannoma surgeon will replace the bone removed during the craniotomy and secure it in place using small screws and/or plates. Sutures or staples will be used to close the incision site, and your recovery process will begin.

**Q. what is the recovery time from Vestibular Schwannoma Surgery?**

Ans- As you review the following information, keep in mind that your experience may vary and that your surgeon will be able to give you more individualized expectations. However, the following guidelines will apply to most patients at a high level and will help you have a better idea of what you may experience during your recovery period.

### **Immediately After Surgery-**

Immediately following your procedure, you will be moved to NSICU and you recover from your anesthesia. Your healthcare team will monitor your breathing, blood pressure and heart rate, keeping close watch until they have determined you are stable and ready to be transferred to NSWARD.

### **In the Hospital-**

Most patients can expect to spend approximately 3-5 days in the hospital following vestibular schwannoma surgery, though again this depends on your individual condition. During this period, you will be monitored for any signs of complications. Once doctor determines you are ready, you will be discharged to home to begin your recovery at home.

### **At Home: The Weeks Following Surgery-**

When you return home, your doctor will give you a list of activity restrictions, including things like avoiding strenuous activities or heavy lifting. This may mean that you cannot perform activities you may not have previously considered, such as household chores, childcare and running etc. It can be helpful

to arrange for assistance with these activities beforehand, especially during your first couple of weeks of recovery. After approximately two weeks, your pain will likely lessen. Around this two-week point, you can expect to see your doctor for a follow-up visit for suture/staple removal and to reassess your activity restrictions.

#### **At Home: The Months Following Surgery-**

Most patients are able to return to work and most pre-surgery activities within 6-12 weeks. You may still experience residual symptoms in the months following your vestibular schwannoma treatment, including headaches, facial muscle weakness, dizziness, or vision and/or hearing difficulties. Your doctor will evaluate your progress during continuing follow-up visits and may refer you to a physical therapist or audiologist if complications do not resolve.

#### **Your Personal Vestibular Schwannoma Recovery Time-**

After reading these general guidelines, it's important that you keep two things in mind during your recovery process. First, your vestibular schwannoma recovery time may vary, depending on your individual condition and health history. Do not be discouraged if your recovery seems to be different than these guidelines. The healing process takes time and varies from patient to patient. Second, your doctor is going to give you activity restrictions to help you heal as quickly and completely as possible. Never exceed these limitations, even if you feel like you are physically capable. Instead, consult with your doctor and discuss how you are feeling. He or she may adjust your restrictions if you are ready. The body requires time to heal and any limitations are designed to give your body a chance to recover from the stress of surgery.

#### **Q. What are the complications of vestibular schwannoma surgery?**

Ans- No procedure is ever completely free of risks. However, vestibular schwannoma surgery has been performed for many years with successful results and limited complications. There are possible minor and major complications that can occur during vestibular schwannoma surgery. Minor complications are, in most cases, temporary and are often easily treated.

**Minor complications** of vestibular schwannoma surgery can include, but are not limited to:-

- Infection
- Nausea and vomiting
- Minor bleeding
- Allergic skin reaction
- Skin numbness
- Painful or abnormal scar formation.

There are a number of possible major complications that can occur. Your overall health will play a role in your likelihood of developing complications. For example, patients with severe heart disease, diabetes, lung disease, or kidney disease may have a higher chance of complications occurring than those who are healthier.

Depending on the individual situation, a major complication may lead to a longer hospital stay, a blood transfusion, a repeat surgery, or in rare cases, permanent disability, or even loss of life. Your risk for major complications depends on several different factors and may be higher or lower than average.

**Major complications** of vestibular schwannoma surgery can include, but are not limited to:

- Loss of hearing (Permanent)
- Headaches
- Nerve, spinal cord, or brain damage
- Weakness or paralysis of the muscles of the face
- Eye problems, such as blurred vision, dryness, excessive tearing, and corneal abrasions
- Blood clots
- Embolism
- Stroke
- Infection
- Major bleeding due to blood vessel injury
- Swelling of the brain (hydrocephalus)

- Return of the vestibular schwannoma tumor.

It is possible that these complications have happened or have occurred very rarely. However, it's important for you to know and understand all the possible complications associated with the surgery, so that you're fully informed. It is also important to realize that even in the best surgical hands, complications do occur, and they do not always imply that something went wrong in your procedure.

**Q. If you take part what will you have to do?**

This study will only analyse the Clinical outcome after electrophysiologically and anatomically preserved 7<sup>th</sup> nerve. You will not be required to do anything apart from the regular follow up that will be advised to you.

**Q. Can you withdraw from this study after it starts?**

Your participation in this study is entirely voluntary and you are also free to decide to withdraw permission to participate in this study. If you do so, this will not affect your usual treatment at this hospital in any way.

**Q. What will happen if you develop any study related injury?**

This study only analyzes the Clinical outcome after electrophysiologically and anatomically preserved 7<sup>th</sup> nerve and thus we do not expect any injury to happen to you but if you do develop any side effects or problems due to the study, these will be treated at this institute by the experienced team of medical professionals. We are unable to provide any monetary compensation, however.

**Q. Will you have to pay for the study?**

The study will only analyse the Clinical outcome after electrophysiologically and anatomically preserved 7<sup>th</sup> nerve. You will undergo in natural process of your treatment for vestibular schwannoma at this institute and no extra cost will be borne by you for this particular study.

**Q. What happens after the study is over?**

You may or may not benefit from this study. If the study is found useful then during subsequent reviews you can be managed according to outcome of this study.

**Q. Will your personal details be kept confidential?**

The results of this study may be published in a medical journal but you will not be identified by name in any publication or presentation of results. However, your medical notes may be reviewed by people associated with the study, without your additional permission, should you decide to participate in this study.

**If you have any further questions, please ask Dr. Arvind Kumar Singh (tel: 7730949211) or email: aravind7440@sctimst.ac.in**

**IEC Member Secretary  
Dr. Mala Ramanathan  
Phone Number : 0471 2524234**

**കാര്യവിവരണപത്രം**

പഠനശീർഷകം

ശസ്ത്രക്രിയയ്ക്കുവിയേയരായ വെസ്റ്റിബുലാർ ഷാനോമരോഗികളിലെ ഇലക്ട്രോഫിസിയോളജി ക്ലബും ശാരീരികവുമായി സംരക്ഷിച്ച ഏഴാം നെർവിന്റെ ചികിത്സാപരമായ നേട്ടം

പഠന നമ്പർ.

പങ്കാളിയുടെ പേര്

ജനനതീയതി/ വയസ്സ് (വർഷത്തിൽ)

..... പുത്രൻ/പുത്രി

**ചോദ്യം: എന്താണ് വെസ്റ്റിബുലാർ ഷാനോമ ?**

ഉത്തരം: തലച്ചോറുമായി ബന്ധപ്പെടുന്ന ചെവികളിലെ നെർവിലെ ഉണ്ടാകുന്ന അപായകരമല്ലാത്ത മുഴ. അത് സന്തുലിതാവസ്ഥയെയും കാഴ്ചയെയും ബാധിക്കുന്നു.

**ചോദ്യം: വെസ്റ്റിബുലാർ ഷാനോമയ്ക്കുള്ള ചികിത്സയെന്താണ് ?**

ഉത്തരം: മുഴയുടെ വലുപ്പത്തെയും രോഗിയുടെ ലക്ഷണങ്ങളെയും പ്രായത്തെയും ആശ്രയിച്ച് നിരീക്ഷണം, ശസ്ത്രക്രിയ, റേഡിയേഷൻ എന്നിവയാൽ ചികിത്സിക്കാം. ചെറിയ ലക്ഷണങ്ങളില്ലാത്ത മുഴകൾക്ക് നിരീക്ഷിക്കുക എന്നതിനപ്പുറം ചികിത്സയാവശ്യമില്ല. ചെറുതോ വലുതോ ആയ ലക്ഷണങ്ങളുള്ള മുഴകൾ ശസ്ത്രക്രിയവഴി നീക്കം ചെയ്യുകയോ കൃത്യമായി കേന്ദ്രീകരിച്ച റേഡിയേഷൻ (സ്റ്റീരിയോറ്റാറ്റിക് റേഡിയോ സർജറി)ശസ്ത്രക്രിയ ചെയ്യുകയോ ആവാം.

ചോദ്യം: പ്രധാന നെർവിലെ ഷാനോമയ്ക്കുള്ള ശസ്ത്രക്രിയ എന്താണ്? ഉത്തരം: ആശുപത്രിയിൽ താങ്കളെ പൊതുവായി മയക്കിയാണ് പ്രധാന നെർവിലെ ഷാനോമയ്ക്കുള്ള ശസ്ത്രക്രിയ നടത്തുന്നത്.

ആദ്യനടപടി സർജൻ മുഴയെ സമീപിക്കാൻ തലയോട്ടിയിലെ ചെറിയ ഒരു ഭാഗം നീക്കം ചെയ്യുക എന്നതാണ്. സമീപ കലകളെ പരമാവധി കുറച്ചുമാത്രം ബുദ്ധിമുട്ടിച്ചുകൊണ്ട് സർജൻ സാധ്യമാകുന്നിടത്തോളം മുഴ നീക്കം ചെയ്യും. അനേകം പ്രധാന നെർവുകളുടെ സാമീപ്യമുള്ളതാണ് പ്രധാന

നെർവിലെ ഷാനോമയുടെ സ്ഥാനം എന്നതിനാൽ, മുഴ പൂർണ്ണമായി നീക്കം ചെയ്താൽ കേൾവിനഷ്ടം, മുഖത്തിന്റെ ദുർബലവും തുടങ്ങിയവയുണ്ടായേക്കാം. അങ്ങനെയെങ്കിൽ താങ്കളുടെ സർജൻ മുഴയുടെ ചില അംശങ്ങൾ നിലനിർത്തുകയും ശസ്ത്രക്രിയയ്ക്കുശേഷമുള്ള റേഡിയേഷൻ ചികിത്സവഴി

അവശേഷിക്കുന്ന കോശങ്ങൾ ഉൻമൂലനം ചെയ്യുകയും ചെയ്യും. മുഴയുടെ എല്ലാ ഭാഗങ്ങളും നീക്കിയശേഷം തലയോട്ടിയുടെ നീക്കംചെയ്ത ഭാഗം ചെറിയ സ്ക്രൂവും പ്ലേറ്റുകളുമുപയോഗിച്ച് തൽസ്ഥാനത്ത് ഉറപ്പിക്കുകയും ചെയ്യും. ശസ്ത്രക്രിയ നടത്തിയ സ്ഥലം തുന്നിക്കെട്ടുകയോ സ്റ്റേപ്പിൾ ചെയ്യുകയോ ചെയ്യുകയും താങ്കളുടെ സുഖപ്പെടലാരംഭിക്കുകയും ചെയ്യും.

**ചോദ്യം. പ്രധാന നെർവിലെ ഷാനോമയ്ക്കുള്ള ശസ്ത്രക്രിയയിലെ സങ്കീർണ്ണതകളെന്തെല്ലാം?**

ഉത്തരം. ഒരു നടപടിയും പൂർണ്ണമായും അപായരഹിതമല്ല. എന്നിരുന്നാലും, വർഷങ്ങളായി പരിമിതമായ സങ്കീർണ്ണതകളോടെ വിജയകരമായ ശസ്ത്രക്രിയകൾ പ്രധാന നെർവിലെ ഷാനോമയ്ക്കു നടത്തപ്പെടുന്നു. പ്രധാന നെർവിലെ ഷാനോമയ്ക്കുള്ള ശസ്ത്രക്രിയയിൽ ലഘുവോ ഗുരുതരമോ ആയ സങ്കീർണ്ണതകളുണ്ടാവാൻ സാധ്യതയുണ്ട്. മിക്കവാറും കേസുകളിലെ ലഘുവായ സങ്കീർണ്ണതകൾ താൽക്കാലികവും എളുപ്പത്തിൽ ചികിത്സിക്കാവുന്നതുമാണ്.

പ്രധാന നെർവിലെ ഷാനോമയ്ക്കുള്ള ശസ്ത്രക്രിയയിലെ ലഘുവായ സങ്കീർണ്ണതകൾ ഇവയാണ് പക്ഷേ പരിധിയില്ല

- അണുബാധ
- മനംപിരട്ടലും ഛർദ്ദിയും
- ചെറിയ രക്തസ്രാവം
- ചർമ്മത്തിലെ അലർജി
- ചർമ്മത്തിലെ മരവിപ്പ്
- വേദനാജനകമോ അസാധാരണമോ ആയ മുറിവിന്റെ തഴമ്പ്

പ്രധാന നെർവിലെ ഷാനോമയ്ക്കുള്ള ശസ്ത്രക്രിയയിലെ ഗുരുതരമായ സങ്കീർണ്ണതകൾ ഇവയാണ് പക്ഷേ പരിധിയില്ല

- കേഴ്വി നഷ്ടം (സ്ഥിരമായത്)
- തലവേദന
- നെർവ്, നട്ടെല്ല്, തലച്ചോർ എന്നിവയിലെ തകരാർ
- മുഖപേശികളുടെ ദൗർബല്യമോ തളർച്ചയോ
- മങ്ങിയ കാഴ്ച, വരൾച്ച, അമിതമായ കണ്ണുനീർ, കൃഷ്ണമണിയിലെ തകരാറുകൾ പോലുള്ള കണ്ണിന്റെ പ്രശ്നങ്ങൾ
- രക്തക്കട്ടകൾ
- നീർവീക്കം
- മസ്തിഷ്കഘാതം
- അണുബാധ
- രക്തക്കുഴലിന്റെ പരക്കുമൂലമുള്ള ഗുരുതരമായ രക്തസ്രാവം
- തലച്ചോറിലെ നീർവീക്കം( ഹൈപ്പോസിഫാലസ്)
- പ്രധാന നെർവിലെ ഷാനോമ വീണ്ടും വരിക

വളരെ അപൂർവ്വമായി ഈ സങ്കീർണ്ണതകളുണ്ടാകുകയോ ഉണ്ടാകാൻ സാധ്യതയോ ഉണ്ട്. എന്തായാലും താങ്കൾക്ക് പൂർണ്ണമായ ബോധ്യം ഉണ്ടാകേണ്ടത് പ്രധാനമാകയാൽ സാധ്യതയുള്ള എല്ലാ സങ്കീർണ്ണതകളും താങ്കൾ അറിയുകയും മനസ്സിലാക്കുകയും ചെയ്യേണ്ടതുണ്ട്. ഏറ്റവും നല്ല ശസ്ത്രക്രിയാവിദഗ്ദ്ധനായാലും സങ്കീർണ്ണതകളുണ്ടാവാം, എല്ലായ്പ്പോഴും താങ്കൾക്ക് സ്വീകരിച്ചു എന്തെങ്കിലും നടപടി തെറ്റായിപ്പോയി എന്ന് അതിനർത്ഥമില്ല.

**ചോദ്യം. താങ്കൾ പങ്കെടുക്കുന്നതിനെക്കുറിച്ചെന്തെല്ലാം ചെയ്യണം?**

ഇലക്ട്രോഫിസിയോളജിക്കലും ശാരീരികവുമായി സംരക്ഷിച്ച ഏഴാം നെർവിന്റെ ചികിത്സാ നേട്ടം വിലയിരുത്തുകമാത്രമാണ് ഈ പഠനം ചെയ്യുന്നത്. താങ്കൾക്ക് നിർദ്ദേശിക്കപ്പെടുന്ന പതിവ് തുടർച്ചി കിസയ്ക്കപ്പറം താങ്കളൊന്നും ചെയ്യേണ്ടതില്ല.

**ചോദ്യം:** പ്രധാന നെർവിലെ ഷാനോമയ്ക്കുള്ള ശസ്ത്രക്രിയയ്ക്കുശേഷം ഭേദമാകാൻ എത്ര സമയമെടുക്കും.?

ഉത്തരം: താങ്കൾ താഴെപ്പറയുന്ന വിവരങ്ങൾ പരിഗണിക്കുമ്പോൾ ഓർക്കുക താങ്കളുടെ ഡോക്ടർക്ക് കൂടുതൽ വ്യക്തിഗതമായ പ്രതീക്ഷകൾ നൽകാനാകും. എന്നിരുന്നാലും, താഴെപ്പറയുന്ന മാർഗ്ഗനിർദ്ദേശങ്ങൾ വലിയ അളവിൽ രോഗികൾക്ക് ബാധകമാകുകയും താങ്കളുടെ രോഗം ഭേദമാകുന്ന കാലയളവിൽ താങ്കൾക്ക് എന്തു പ്രതീക്ഷിക്കാം എന്നതിനെപ്പറ്റി മെച്ചപ്പെട്ട ധാരണ നൽകുകയും ചെയ്യും.

**ശസ്ത്രക്രിയ കഴിഞ്ഞാലുടനെ**

ശസ്ത്രക്രിയകഴിഞ്ഞിട്ട് മയക്കത്തിൽനിന്നും താങ്കൾ ഉണരുന്നതിനിടയിൽ ഒരു പ്രത്യേക മുറിയിലേക്ക് മാറ്റും. താങ്കൾ സ്ഥിരതകൈവരിച്ചു എന്നും ആശുപത്രിയിലെ താങ്കളുടെ മുറിയിലേക്ക് മാറ്റാം എന്നും നിശ്ചയിക്കുന്നതുവരെ താങ്കളുടെ ശ്വസനം, രക്തസമ്മർദ്ദം ഹൃദയമിടിപ്പ് എന്നിവ താങ്കളുടെ ആരോഗ്യ പരിചരണം നടത്തുന്ന സംഘം നിരീക്ഷിക്കും.

**ആശുപത്രിയിൽ**

പ്രധാന നെർവിലെ ഷാനോമയ്ക്കുള്ള ശസ്ത്രക്രിയയ്ക്കുശേഷം മിക്കവാറും രോഗികൾ ഏകദേശം 3 മുതൽ 5 ദിവസം ആശുപത്രിയിൽ ചിലവഴിക്കും, അത് താങ്കളുടെ വ്യക്തിപരമായ സാഹചര്യത്തെ ആശ്രയിച്ചിരിക്കും. ഈ സമയത്ത് താങ്കളിൽ എന്തെങ്കിലും സങ്കീർണ്ണതകളുണ്ടാകുന്നോ എന്ന് നിരീക്ഷിക്കും. താങ്കൾക്ക് വീട്ടിൽ പോയി സുഖപ്പെടാൻ താങ്കൾ തയ്യാറായി എന്ന് ഡോക്ടർ തീരുമാനിച്ചുകഴിഞ്ഞാൽ താങ്കളെ ആശുപത്രിയിൽ നിന്നും വിടുതൽ ചെയ്യും.

**വീട്ടിൽ. ശസ്ത്രക്രിയകഴിഞ്ഞുള്ള ആഴ്ചകൾ**

താങ്കൾ വീട്ടിലേയ്ക്ക് മടങ്ങുമ്പോൾ ഡോക്ടർ ബുദ്ധിമുട്ടുള്ള പ്രവൃത്തികൾ, ഭാരമുയർത്തൽ ഉൾപ്പെടെയുള്ള പ്രവൃത്തികൾ നിയന്ത്രിക്കാനുള്ള ഒരു പട്ടിക നൽകും. വീട്ടിലെ പണികൾ, കുട്ടികളെ പരിചരിക്കൽ ഓട്ടം തുടങ്ങിയ താങ്കൾ മുൻപരിഗണിക്കാത്ത പല പ്രവൃത്തികളും താങ്കൾ ഒഴിവാക്കാണം. മുൻകൂട്ടിത്തന്നെ ഇത്തരംകാര്യങ്ങൾക്ക് സഹായിക്കാൻ ആളെ ഏർപ്പാടാക്കുന്നത് നന്ന്. ഏകദേശം രണ്ടാഴ്ചകഴിയുമ്പോഴേക്ക് താങ്കളുടെ വേദന കുറഞ്ഞേക്കാം. ഏകദേശം ഇക്കാലത്ത് തുന്നൽ/സ്റ്റേപ്പിൾ നീക്കംചെയ്യാൻ താങ്കൾക്ക് ഡോക്ടറെ സന്ദർശിക്കാം. സങ്കീർണ്ണതകൾ പരിഹരിക്കപ്പെട്ടില്ലെങ്കിൽ ഒരു ഫിസിയോതെറാപ്പിസ്റ്റിനെയോ ഓഡിയോളജിസ്റ്റിനെയോ കാണാൻ ഡോക്ടർ ആവശ്യപ്പെടുത്താം.

**താങ്കളുടെ വ്യക്തിപരമായ പ്രധാന നെർവിലെ ഷാനോമ ഭേദമാകാൻ വേണ്ടുന്ന സമയം**

ഈ മാർഗ്ഗനിർദ്ദേശങ്ങൾ വായിച്ചശേഷം താങ്കളുടെ ഭേദമാകൽ പ്രക്രിയയിൽ രണ്ട് കാര്യങ്ങൾ ഓർക്കുന്നത് പ്രധാനമാണ്. ആദ്യം, താങ്കളുടെ വ്യക്തിപരമായ അവസ്ഥയും ആരോഗ്യ ചരിത്രവും നൂസരിച്ച് അസുഖം ഭേദമാകാനെടുക്കുന്ന സമയം വ്യത്യസ്തമായേക്കാം. മാർഗ്ഗനിർദ്ദേശങ്ങളിൽനിന്ന് വ്യത്യസ്തമാണ് താങ്കളുടെ ഭേദമാകാനെടുക്കുന്ന സമയം എന്നതിൽ വിശ്വസിക്കരുത്. ഭേദമാകാനെടുക്കുന്നസമയം രോഗികളിൽ വ്യത്യസ്തമാണ്. രണ്ടാമതായി, താങ്കളുടെ ഡോക്ടർ പ്രവൃത്തികളിൽ നിയന്ത്രണം ഏർപ്പെടുത്തുന്നത് താങ്കൾക്ക് കഴിവതും വേഗം അസുഖം ഭേദമാകാനാണ്. താങ്കൾക്ക് ശാരീരികമായി ശേഷിയുണ്ടെന്ന് തോന്നിയാലും ഈ പരിധി ഒരിക്കലും ലംഘിക്കരുത്. പകരം ഡോക്ടറുമായി കൂടിയാലോചിക്കുകയും താങ്കൾക്കെന്ത് തോന്നുന്നു എന്ന് ചർച്ച ചെയ്യുകയും ചെയ്യുക. താങ്കൾ തയ്യാറാകുമ്പോൾ നിയന്ത്രണങ്ങൾ ക്ക് മാറ്റം വരുത്തിയേക്കാം. ശരീരത്തിന് ഭേദമാവാൻ സമയം ആവശ്യമാണ് ശസ്ത്രക്രിയയുടെ സമ്മർദ്ദത്തിൽ നിന്നും താങ്കളുടെ ശരീരത്തിന് മോചനത്തിന് അവസരം നൽകാനാണ് നിയന്ത്രണങ്ങൾ.

**ചോദ്യം പഠനമാരംഭിച്ചശേഷം താങ്കൾക്ക് പിൻമാറാമോ?**

താങ്കളുടെ പഠനത്തിലുള്ള പങ്കാളിത്തം തികച്ചും സ്വമേധയാ ഉള്ളതും പഠനത്തിൽ പങ്കെടുക്കാൻ നുള്ള സമ്മതം പിൻവലിക്കാൻ താങ്കൾക്ക് സ്വാതന്ത്ര്യമുള്ളതുമാണ്. താങ്കളതുചെയ്യുന്നതുകൊണ്ട് ആശുപത്രിയിലെ താങ്കളുടെ പതിവ് ചികിത്സ ഒരുവിധത്തിലും ബാധിക്കില്ല.

**ചോദ്യം. താങ്കൾക്ക് പഠനസംബന്ധമായി എന്തെങ്കിലും പരക്കുണ്ടായാലേന്ത് സംഭവിക്കും.?**

ഇലക്ട്രോഫിസിയോളജിക്കലും ശാരീരികവുമായി സംരക്ഷിച്ച ഏഴാം നെർവിന്റെ ചികിത്സാ നേട്ടം വിലയിരുത്തുകമാത്രമാണ് ഈ പഠനം ചെയ്യുന്നത് ആകയാൽ പഠനസംബന്ധമായി താങ്കൾക്ക് പരക്കുണ്ടാകുമെന്ന് ഞങ്ങൾ പ്രതീക്ഷിക്കുന്നില്ല. പക്ഷേ പഠനവുമായി ബന്ധപ്പെട്ട് എന്തെങ്കിലും പാർശ്വഫലങ്ങളോ പ്രശ്നങ്ങളോ ഉണ്ടായാൽ അത് ഈ ആപത്രിയിൽ വിദഗ്ദ്ധരായ ഡോക്ടർമാർ ചികിത്സിക്കും. എന്നിരുന്നാലും സാമ്പത്തികമായ നഷ്ടപരിഹാരം നൽകാൻ ഞങ്ങൾക്കാവില്ല.

**ചോദ്യം. താങ്കൾ പഠനത്തിന് പണം മുടക്കണോ?**

ഇലക്ട്രോഫിസിയോളജിക്കലും ശാരീരികവുമായി സംരക്ഷിച്ച ഏഴാം നെർവിന്റെ ചികിത്സാ നേട്ടം വിലയിരുത്തുകമാത്രമാണ് ഈ പഠനം ചെയ്യുന്നത് താങ്കൾ പ്രധാന നെർവിലെ ഷാനോമയ്ക്കുള്ള സ്വാഭാവികമായ ചികിത്സയ്ക്ക് ഈ ആശുപത്രിയിൽ വിധേയമാകുകയാണ്. ഈ പഠനത്തിനായി അധികച്ചിലവൊന്നും താങ്കൾ വഹിക്കേണ്ടതില്ല.

**ചോദ്യം. പഠനമവസാനിച്ചശേഷം എന്തുണ്ടാകും.?**

താങ്കൾക്ക് ഈ പഠനത്തിൽനിന്നും നേട്ടമുണ്ടാവുകയോ ഇല്ലാതിരിക്കുകയോ ആവാം. പഠനം വിജയകരമായാൽ താങ്കളുടെ തുടർചികിത്സാ സമയത്ത് അതിനനുസൃതമായി ചികിത്സിക്കപ്പെടും.

**ചോദ്യം. താങ്കളുടെ വ്യക്തിവിവരങ്ങൾ രഹസ്യമായിരിക്കുമോ?**

പഠനഫലങ്ങൾ വൈദ്യശാസ്ത്ര ജേർണലിൽ പ്രസിദ്ധീകരിക്കുമെങ്കിലും താങ്കളെ പേരുകൊണ്ട് തിരിച്ചറിയാനിടയാക്കുന്നതൊന്നും പ്രസിദ്ധീകരണത്തിലോ പ്രദർശനങ്ങളിലോ ഉണ്ടാകില്ല. താങ്കൾ പഠനത്തിൽ പങ്കെടുക്കാൻ സമ്മതിച്ചാൽ, താങ്കളുടെ ചികിത്സാവിവരങ്ങൾ താങ്കളുടെ പ്രത്യേക അനുമതി കൂടാതെതന്നെ പഠനവുമായി ബന്ധപ്പെട്ടവർ പരിശോധിച്ചേക്കാം.

പഠനസംബന്ധമായി താങ്കൾക്ക് കൂടുതൽ ചോദ്യങ്ങളുണ്ടെങ്കിൽ ദയവായി ചോദിക്കുക ഡോ. അരവിന്ദ് കുമാർ സിങ് (ഫോൺ. 7730949211)

ഈമെയിൽ. [arvindminta2006@sctimst.ac.in](mailto:arvindminta2006@sctimst.ac.in)

ഐഇസി മെമ്പർ സെക്രട്ടറി

ഡോ. മാലാ രാമനാഥൻ

ഫോൺ 0471-2524234 email [iec.mem.sec@sctimst.ac.in](mailto:iec.mem.sec@sctimst.ac.in)



श्री चित्रा तिरुनाल आयुर्विज्ञान और प्रौद्योगिकी संस्थान, त्रिवेन्द्रम  
तिरुवनन्तपुरम - ६९५०११, केरल, इंडिया

SREE CHITRA TIRUNAL INSTITUTE FOR MEDICAL SCIENCES AND TECHNOLOGY, TRIVANDRUM  
Thiruvananthapuram - 695 011, Kerala, India  
(An Institute of National Importance under Govt. of India)

Grams : Chitramet, Phone : +91-471-2443152, Fax : +91-471-2550728 / 2446433, E-mail : scl@sclimst.ac.in, Website : www.sclimst.ac.in

**Institutional Ethics Committee**  
(IEC Regn No. ECR/189/Inst/KL/2013/RR-16)

SCT/IEC/1525 /FEBRUARY-2020

03.08.2020

Dr. Arvind Kumar Singh  
Senior Resident  
Department of Neurosurgery  
SCTIMST, Thiruvananthapuram

Dear Dr. Arvind Kumar Singh,

The Institutional Ethics Committee reviewed and discussed your application to conduct the study entitled "CLINICAL OUTCOME AFTER ELECTROPHYSIOLOGICALLY AND ANATOMICALLY PRESERVED 7TH NERVE IN VESTIBULAR SCHWANNOMA PATIENTS (IEC/1525)\* on 15<sup>th</sup> February, 2020.

The following documents were reviewed:

Original submission

1. Covering letter addressed to the Chairperson, IEC, SCTIMST dated 22.01.2020 with checklist
2. Full proposal
3. IEC Application Form
4. Proforma
5. Forwarding letter from the HOD
6. TAC Approval letter
7. Information Sheet and Consent Form in English and Malayalam
8. CV of Principal Investigator and Co-Principal Investigators

Revised submission

1. Covering letter addressed to the Member Secretary, IEC, SCTIMST dated 09.07.2020 with checklist
2. Full proposal
3. IEC Application Form
4. Proforma
5. Forwarding letter from the HOD
6. TAC Approval letter
7. Revised Patient Information Sheet and Consent Form in English and Malayalam
8. CV of Principal Investigator and Co-Principal Investigators

Page 1 of 2

The following members of the Ethics Committee were present at the meeting held on 15<sup>th</sup> February, 2020 at G. Parthasarathi Board Room, AMCHSS, SCTIMST

SL. No.	Member Name	Highest Degree	Gender	Scientific /Non Scientific	Affiliation with Institution(s)
1.	Dr. R V G Menon	M Tech, PhD	Male	Lay Person (Chairman)	No
2.	Dr. Rema M. N	MD	Female	Basic Medical Scientist	No
3.	Dr. Kala Kesavan. P	MBBS, MD	Female	Basic Medical Scientist	No
4.	Dr. K R S Krishnan	M.E., Ph.D.	Male	Medical Technology	Yes
5.	Dr. Harikrishna Varma PR	Ph.D( Materials Science)	Male	Medical Technology	Yes
6.	Dr. S S Giri Sankar	LL.M. Ph.D.	Male	Legal Expert	No
7.	Dr. Anand Kumar A	MD, DM	Male	Clinician	No
8.	Dr. Aneesh V Pillai	BA. LLB (Hons.), LLM, Ph. D, SET (Law)	Male	Legal Expert	No
9.	Smt. Sathi Nair	MA (English Literature)	Female	Lay Person	No
10.	Dr. P. Manickam	BSMS, MSc (Epid),PhD	Male	Health Science Expert/ Social Scientist	No
11.	Dr. Christina George	MD Psychiatry	Female	Clinician	No
12.	Mr. Satheesh Chandran	MSW, PGDPM	Male	Lay person/ NGO/ Social Scientist	No
13.	Dr. Mala Ramanathan	PhD	Female	Social Scientist (Member Secretary)	Yes

#### IEC Decision

The IEC approved the conduct of the study in the present form.

#### Remarks:

The Institutional Ethics Committee expects to be informed about the progress of the study, any SAE occurring in the course of the study, any changes in the protocol and patient information/informed consent and asks to be provided a copy of the final report.

There was no member of the study team who participated in voting / decision making process. The ethics committee is organized and operated according to the requirements of Good Clinical Practice and the requirements of the Indian Council of Medical Research (ICMR).

Sincerely,



**Mala Ramanathan**  
Member Secretary, IEC