

SREE CHITRA TIRUNAL INSTITUTE FOR MEDICAL SCIENCES AND TECHNOLOGY

Thiruvananthapuram – 695011, India



WORK RECORD

Name : VIJAY THOMAS CHERIAN

Course : MCh

Discipline : CARDIOVASCULAR AND THORACIC SURGERY

Year of Study : Jan 2013 – Dec 2015

CERTIFICATE

I hereby certify that I have performed / assisted all the procedures listed in the work record.

Place: Thiruvananthapuram

Signature :

Date: Oct 2015

Name : VIJAY THOMAS CHERIAN

FORWARDED

The above candidate has satisfactorily carried out the minimum required procedures

Place: Thiruvananthapuram

Signature :

Date: Oct 2015

Name : (Prof. Jayakumar K)

Head of the department

Department of CVTS

SCTIMST,
Thiruvananthapuram

PROCEDURES PERFORMED

PROCEDURE	NUMBER OF CASES
ASD CLOSURE	8
RE-EXPLORATION FOR BLEEDING	2
SUBXYPHOID PE DRAINAGE	2
PG EXPLANTATION	2
DELAYED STERNAL CLOSURE	2
PD INSERTION	6

PROCEDURES ASSISTED

ADULT CARDIAC SURGERY

PROCEDURE	NUMBER OF CASES
CABG	140
OPCAB	3
CABG + LV PLICATION	6
CABG + LAD / RCA ENDARTERECTOMY	6
CABG + CEA	1
REDO CABG	1
AVR + CABG	9
MVR + CABG	9
CABG WITH AORTOPLASTY	1
CABG + MV REPAIR	3
VSR REPAIR+CABG	3
CABG+ASD CLOSURE	1
CABG WITH BROKEN PCI GUIDEWIRE RETRIEVAL VIA AORTOTOMY	1
LA MYXOMA EXCISION	2
SUPRACORONARY ASC AO REPLACEMENT	3
MODIFIED BENTALL'S PROCEDURE	7
MODIFIED BENTALL'S PROCEDURE+SEPTAL MYECTOMY	1
AVR	30
AVR + MV REPAIR	4

PROCEDURES ASSISTED ADULT CARDIAC SURGERY

PROCEDURE	NUMBER OF CASES
AVR + AORTOPLASTY	2
AVR + SAM EXCISION	1
AV REPAIR	1
NUNEZ AORTIC ROOT ENLARGEMENT+AVR+CABG	1
RSOV+VSD CLOSURE	1
SAM EXCISION	2
MODIFIED MORROWS MYECTOMY	3
MVR	32
MVR + TVA	3
MV REPAIR WITH VSD CLOSURE	1
MV REPAIR	13
TV REPAIR	3
PARTIAL AVCD	4
DVR	21
DVR + TVA	4
ASD CLOSURE	8
ASD CLOSURE + TVA	1
DOUBLE PATCH REPAIR (SV ASD)	4
REDO MV PARAVALVAR LEAK REPAIR+AVR	1

PROCEDURES ASSISTED

CONGENITAL HEART SURGERY

PROCEDURE	NUMBER OF CASES
MINI STERNOTOMY ASD CLOSURE	3
ASD CLOSURE	14
ASD DEVICE RETREVAL	1
DOUBLE PATCH REPAIR (SV ASD)	7
WARDEN'S PROCEDURE	4
ASD CLOSURE + PULMONARY VALVOTOMY + MPA PLASTY	1
ASD CLOSURE + MV REPAIR	1
VSD CLOSURE	19
VSD CLOSURE + AV REPAIR	3
VSD CLOSURE + MV REPAIR	1
ICR (TOF)	25
ICR + PA PLASTY	5
ICR + ICA TRANSLOCATION	1
ICR (DORV&VSD PS)	8
2 PATCH REPAIR (CAVCD)	2
ASO	7
ASO + VSD CLOSURE	5
DOTY'S AORTOPLASTY	1

PROCEDURES ASSISTED

CONGENITAL HEART SURGERY

PROCEDURE	NUMBER OF CASES
RASTELLI	2
TCPC	3
LCA TRANSLOCATION	1
LCA TRANSLOCATION + KAY'S MV ANNULOPLASTY	1
TAPVC REPAIR	10
TAPVC REPAIR + WARDEN'S PROCEDURE	2
COA REPAIR	5
COA REPAIR + PA BAND	1
PA BANDING	4
BDG	14
ONE AND HALF(CONE REPAIR+BDG) FOR EBSTEINS ANOMALY	1
TRUNCUS ARTERIOSUS REPAIR	1
UNIFOCALISATION OF MAPCAS	1
ICR WITH RV-PA CONDUIT	2
RMBTS	2
MV REPAIR	1
EXCISION OF SAM	2
ATRIAL SEPTECTOMY	1
PDA LIGATION	2

PROCEDURES ASSISTED

CONGENITAL HEART SURGERY

PROCEDURE	NUMBER OF CASES
AVR FOR POST ICR FOR TOF WITH AR	1
TAP WITH RVOT REPAIR FOR FAILED RVOT PERFORATION AND HEMOPERICARDIUM	1
LPA PLASTY	2
SUPRAMITRAL RING EXCISION	1
MODIFIED MELBOURNE SHUNT	1
RE-IMPLANTATION OF RPA AND PDA INTERRUPTION IN HEMITRUNCUS	1

MISCELLANEOUS PROCEDURE

PROCEDURE	NUMBER OF CASES
DSC	12
EPICARDIAL PPI LEAD PLACEMENT	3
PE DRAINAGE	5
TRACHEOSTOMY	1
DIAPHRAGMATIC PLICATION	1
PMMC FLAP REPAIR FOR DSWI	3
HOMOGRAFT HARVESTING AND TRIMMING	4
STERNAL WIRE REMOVAL	2
WOUND DEBRIDEMENT AND SUTURING	4
RE EXPLORATIONS FOR BLEEDING	8
SPLIT SKIN GRAFTING FOR SSI	2
PG EXPLANTATION	3
BRACHIAL EMBOLECTOMY	1
ENDOSCOPIC VEIN HARVESTING FOR CABG	2

PAPER PRESENTATION

- 1. Bovine aortic arch with supraaortic stenosis INDIAN HEART JOURNAL AUGUST 2015, CO-AUTHOR**
- 2. “A (not so) sheepish issue: A new myocardial management protocol in sheep.” GOLD MEDAL AT SCIENCE FETE ON SCIENCE FETE AT SCTIMST DAY**

CASES PERFORMED

LIST OF OPEN HEART CASES PERFORMED

S.NO	H.NO	NAME	AGE	SEX	DOS	DIAGNOSIS	PROCEDURE	SUPERVISED BY
1	368831	AKSHAY KRISHNA	5	M	13-Aug-2015	ACHD, OS ASD, NO PAH, GOOD LV, SR	TPP CLOSURE OF OS ASD	DR. THOMAS MATHEW
2	361580	SUCHITHRA S	16	F	13-Jul-2015	ACHD, OS ASD, MILD PAH GOOD LV, SR	TPP CLOSURE OF OS ASD	DR. VIVEK PILLAI
3	394825	.VISHNU V.J	17	M	3-Jul-2015	ACHD, OS ASD, NO PAH, GOOD LV, SR	DIRECT CLOSURE OF OS ASD	DR. BINEESH KR
4	362388	NILOFER NISA	8	F	13-Apr-2015	ACHD, OS ASD, GD LV, SR	TPP CLOSURE OF OS ASD	DR. SABARINATH MENON
5	354796	HAMSA K.S	36	M	19-Feb-2015	ACHD, OS ASD, MILD PAH GOOD LV, SR	TPP CLOSURE OF ASD	DR. BINEESH KR
6	386235	MINHA FATHIMA	4	F	26-Aug-2015	ACHD, OS ASD, MILD PAH, GOOD LV, SR	TPP CLOSURE OF OS ASD	DR. SABARINATH MENON
7	395480	ADITHYAN B	8	M	5-Aug-2015	ACHD,OSASD, MILD PAH, GDLV, SR	TPP CLOSURE OF OS ASD	DR. THOMAS MATHEW
8	376362	SHANTHA P	54	F	8-Oct-2014	ACHD, OS ASD, MILD PAH, GD LV, SR	DIRECT CLOSURE OF OS ASD	DR. BINEESH KR

CASES ASSISTED

SL. NO	HNO	NAME	AGE	SEX	DOS	POSTOP DIAGNOSIS	PROCEDURE EXECUTED	SURGEON
1	355826	MUHAMMED ISMAIL M	0	M	10-Jan-2013	CCHD,CARDIAC TAPVC,PFO,SEVERE PAH,SR,STERNUM KEPT OPEN	DELAYED STERNAL CLOSURE	DR. SABARINATH MENON
2	321154	SABIRA M.	21	F	11-Jan-2013	CCHD,TOF,GOOD CONFLUENT PA,LEFT ICA FROM LPA,SR	ICR+TAP+MONOCUSP RECONSTRUCTION OF RVOT + REIMPLANTATION OF LEFT ICA TO LEFT ECA	DR. BAIJU S.DHARAN
3	355593	JASIM	0	M	15-Jan-2013	ACHD,HEMITRUNCUS, RPA FROM AORTA,PDA,SEV PAH,SR	RPA REIMPLANTATION + PDA INTERRUPTION	DR. BAIJU S.DHARAN
4	298193	NITHA PRATHAP	3	F	16-Jan-2013	CCHD,TOF,RESTRICTI VE VSD,HYPOPLASTIC TRICUSPID VALVE,SEV PS,DIFFUSE BRANCH PA STENOSIS,S/P BPV,SR	ICR+TAP+MONOCUSP RECONSTRUCTION OF RVOT+RPA PLASTY+PFO RESTRICTED	DR. BAIJU S.DHARAN
5	350932	ABHINAV R	3	M	16-Jan-2013	ACHD,SP VSD,RCC PROLAPSE, MOD-SEV AR,SR	GP CLOSURE OF SP VSD+ AV REPAIR(TRIANGULAR PLICATION OF RCC)+PDA INTERRUPTION	DR. BAIJU S.DHARAN
6	344695	MATHES R.	0	M	31-Jan-2013	ACHD,SA VSD,ADDITIONAL APICAL VSD,ASD,PDA,SEV PAH,SR	GP CLOSURE OF SA VSD+TPP CLOSURE OF ASD+PDA INTERRUPTION+PFO KEPT OPEN	DR. SABARINATH MENON
7	331463	JOEL JOSE	2	F	01-Feb-2013	ACHD,SA VSD,PDA,PAH,SR	GP CLOSURE OF SA VSD + PDA INTERRUPTION	DR. SABARINATH MENON
8	223885	HAIL MARY E.J.	9	F	04-Feb-2013	CCHD, DORV,VSD,PS,CONFL UENT PA,S/P BDG+MPA	RESTERNOTOMY+EXTRA CARDIAC FENESTRATED(5MM) FONTAN WITH 20MM	DR. BAIJU S.DHARAN

						BANDING,S/P MAPCA COILING,RESIDUAL MAPCA,SA	PTFE+CONFLUENCE PLASTY	
9	351171	ADWAITH C P	0	M	05-Feb-2013	ACHD,PARTIAL AVCD,SR	ICR,AVCD REPAIR(TPP CLOSURE OF OP ASD+CLEFT AML REPAIR+PFO CLOSED)	DR. THOMAS MATHEW
10	356531	SHIBILA FATHIMA R	0	F	06-Feb-2013	S/P TAPVC REPAIR, DSWI	WOUND DEBRIDMENT AND STERNAL REWIRING	DR. BAIJU S.DHARAN
11	354339	B/O RANJANA	0	M	25-Feb-2013	CCHD,DTGA,ASD,SP VSD,HYPOPLASTIC RV,S/P BAS,SR	ATRIAL SEPTECTOMY+PA BANDING(24MM)+STENTE D STERNUM	DR. BAIJU S.DHARAN
12	357063	SHABEEL K.	0	M	27-Feb-2013	CCHD,SC TAPVC,ASD,SEV PAH,PDA,SR	TAPVC REPAIR(SUTURELESS TECHNIQUE)+WARDENS PROCEDURE+PFO OPEN	DR. BAIJU S.DHARAN
13	349137	SAJEED M.	41	M	01-Apr-2013	RHD,BAV,SEV CAL AS,MOD AR,SEV LV DYSFN,NC,SR	AVR #23 CHVP VALVE	DR. PRAVEEN VARMA P.K.
14	353190	SAINABA BEEVI A.	50	F	01-Apr-2013	HOCM,SEV LVOTO,MOD MR,SAM,SR	MYECTOMY(MORROW'S OPERATION)	DR. VIVEK V. PILLAI
15	302255	USHA T.K.	43	F	02-Apr-2013	RHD, SEV CALC MS, MOD MR, GOOD LV, MOD PAH, SR, NC	MVR #29 CHVP	DR. VIVEK V. PILLAI
16	328588	REJANI A	25	F	03-Apr-2013	RHD, SEV AR, MILD MR, DIL LV,SR	AVR #23 CHVP	DR. PRAVEEN VARMA P.K.
17	342099	SHANTHI K	39	F	15-Apr-2013	RHD, SEV MR, MOD MS, MILD PAH, GOOD LV,SR	MVR # 29 CHVP	DR. VIVEK V. PILLAI
18	349274	JAYA KUMAR S	32	M	26-Apr-2013	RHD,SEV CAL MS,MILD-MOD MR,LAA CLOT,GOOD LV,AF	MVR #29 SJM+PARTIAL PMLP+LA CLOT EXTRACTION+LAA EXCLUSION	DR. VARGHESE T.PANICKER
19	351374	NISHALAL U J	22	F	29-Apr-2013	ACHD,SAVSD,SEV PAH,PROLAPSED AML,MOD MR,DILATED ANNULUS,PDA,GDLV, SR	DACRON PATCH CLOSURE OF SA VSD+MV REPAIR(NO 30 SADDLE RING SJM)+TRANS PA PDA CLOSURE	DR. VIVEK V. PILLAI

20	356422	SOBHANAMMA .S	46	F	30-Apr-2013	MVP, SEV MR, MILD PAH, GOOD LV, SR, BA, HTN, CERVICAL SPONDYLITIS	MV REPAIR(QUADRANGLUAR RESECTION OF P1 AND P2 SEGMENTS) WITH NO 35 TAYLOR RING	DR. PRAVEEN VARMA P.K.
21	9206426	RAMACHANDRAN NAIR.M.	67	M	30-Apr-2013	SSI LT LOWER LIMB, S/P CABG	SSG	DR. JAYAKUMAR K
22	350400	THANKAMMAL P	53	F	13-May-2013	CAD,LMCA+,TVD,GDL V,SR,DM,HTN	CABG X 4 GRAFTS LIMA-LAD,RSVG- RAMUS, RPDA,TERM OM.	DR. JAYAKUMAR K
23	360154	BHARATHI AMMA K	65	F	14-May-2013	CAD,TVD,MILD LVD,SR,DM,HTN	CABG X 5 GRAFTS LIMA-LAD,RSVG-D1,OM2,LPLB,PRECRUX RCA	DR. JAYAKUMAR K
24	9205294	DAS.N.C.	64	M	14-May-2013	RHD, RE SEV MS, MOD MR, MILD AR, SEV PAH, AF, S/P CMV, GOOD LV, NC	MVR WITH 29 SJM + TV REPAIR	DR. VARGHESE T.PANICKER
25	345112	SHEMINA B.	17	F	15-May-2013	RHD,SEV MR.,MILD MS,SEV PAH,GD LV,SR	MVR WITH #29 SJM + PMLP	DR. PRAVEEN VARMA P.K.
26	337562	THANKALEKSHMI C.	44	F	16-May-2013	ACHD,OS ASD,MILD PAH,SR,POLIO LT LL	DIRECT CLOSURE OF OS ASD	DR. JAYAKUMAR K
27	354044	SUBAIR .K.V	50	M	17-May-2013	CAD,TVD,GD LV, SR, DM, HTN	CABG X 4 GRAFTS(LIMA-LAD,RSVG-MAJ D, OM1,PDA)	DR. VIVEK V. PILLAI
28	337509	SUBITHA M	25	F	20-May-2013	RHD,SEVERE AS,MOD MR, MOD AR, MILD PAH,GDLV.SR	AVR #19 CHVP+ MV REPAIR	DR. VARGHESE T.PANICKER
29	350941	THIRAVIAM C	57	M	21-May-2013	ACHD,OS ASD,MOD PAH,NC,SR	ACHD,OS ASD,MOD PAH,NC,SR	DR.GEORGE J VALOORAN
30	351942	BABUKUTTAN NAIR T	48	M	22-May-2013	CAD,TVD,GD LV,DLP,SR,RT HYDROCELE,LT ECTOPIC TESTIS(PERINEUM)	OPCABG(LIMA-LAD,RSVG-D1,PDA)	DR. JAYAKUMAR K
31	356239	RAJESWARI P S	50	F	28-May-2013	DSWI,S/P CABG(QSTEOMYELITIS)	WOUND DEBRIDEMENT AND SEQUESTRECTOMY+PMMC FLAP REPAIR	DR. JAYAKUMAR K

32	352091	VIJAYAN PILLAI R	52	M	18-Jun-2013	CAD,TVD,GDLV,SR,HT N,HBSAG+	CABG X 4 GRAFTS(LIMA- LAD,RSVG-RAMUS SUP BR,MAJOR OM,2ND PLB)	DR. JAYAKUMAR K
33	273350	LUKOSE N.	45	M	19-Jun-2013	RHD,S/P CMV,S/P PTMC,SEV RE MS,MOD AR,MOD PAH,GDLV,SR	DVR(MV#27 SJM & AV #21 SJM)	DR. VARGHESE T.PANICKER
34	357747	RAVEENDRAN PILLAI N.	55	M	19-Jun-2013	CAD,TVD,GDLV,SR,DM ,HTN,DLP	CABG X 5GRAFTS (LIMA- LAD,RSVG- D2,OM3,RPDA,RAMUS)	DR. JAYAKUMAR K
35	362563	JEYA RAJ .S	60	M	20-Jun-2013	CAD,TVD,OLD IWMI,GDLV,SR,DM	CABG X 3GRAFTS(LIMA- LAD,RSVG-TERM OM ,RAMUS)	DR. PRAVEEN VARMA P.K.
36	350694	ANILKUMAR R	44	M	24-Jun-2013	RHD, SEV MS, MOD AR, MOD AS,GD LV,SR,NC	DVR(MV #25 SJM & AV #21 SJM)	DR. VARGHESE T.PANICKER
37	350341	VALSA T.R	51	F	26-Jun-2013	RHD, SEVMR, MOD MS,SEV PAH,LV DYSFUNCTION,BIPOL AR DISORDER	MVR # 25 SJM+ PMLP	DR. PRAVEEN VARMA P.K.
38	364732	AMAL G	1	M	12-Sep-2013	CCHD, HYPOPLASTIC TV, PV, RV, OSASD, GD LV, SR, SPELLS	BDGS + FENESTRATED CLOSURE OF ASD	DR. THOMAS MATHEW
39	364185	ASHNA MOL	0	F	26-Sep-2013	CCHD,SV(LV),SEV PAH,MOD COA+ARCH HYPOPLASIA,PDA DEP SYSTEMIC CIRCULATION,S/P BAS,GDLV,SR	RESECTION OF COA AND EXTENDED E-E ANASTAMOSIS+PA BANDING WITH 24 MM MERSILENE TAPE VIA L POSTEROLATERAL THORACOTOMY(RACHS 3)	DR. BAIJU S.DHARAN
40	308075	SANJAY K	3	M	26-Sep-2013	ACHD, SPVSD, NON OBSTRUCTIVE SUB AORTIC MEMBRANE, MILD AR, GD LV, SR	TRANS PA GORETEX PATCH CLOSURE OF VSD WITH SUB AORTIC MEMBRANE EXCISION	DR. BAIJU S.DHARAN
41	366452	KURIAKOSE C E	53	M	17-Oct-2013	MVP, SEV MR, AF	MVR #33 SJM + PMLP	DR. PRAVEEN VARMA P.K.
42	273350	LUKOSE N.	45	M	17-Oct-2013	EARLY PVE,PARAVALVAR MR,S/P DVR(MV #25SJM,AV #21	RESTERNOTOMY,PARAV ALVAR MR REPAIR+AV EXPLANTATION+AVR # 19 SJM+BPP CLOSURE OF	DR. VARGHESE T.PANICKER

						SJM)GOOD LV/RV,SR,NC,DM	AORTOTOMY	
43	364282	SANTHA KUMARI . A.K	63	F	21-Oct-2013	CAD,TVD,GD LV,SR,DM,HTN,DLP	CABG X 6 GRAFTS(LIMA TO LAD AND RSVG TO MAJOR DIAGONAL,OM2,TERMINA L OM, RAMUS AND RPDA) ,TERMINAL OM PIGGYBACKED TO RAMUS	DR. JAYAKUMAR K
44	22470	RUKIYA.C.	61	F	22-Oct-2013	RHD,SEV MS,S/P CMV,MOD MR,MOD TR,MOD PAH,FAIR RV,GD LV,AF,NC,DM	MVR # 27 SJM + PMLP + TVA #30 MC3 RING	DR. PRAVEEN VARMA P.K.
45	363944	VINCENT J.	45	M	22-Oct-2013	DVHD,SEV AR,DIL AO,MILD LVD,SR,NC,DM	AVR #27 CHVP+AORTOPLASTY	DR. VARGHESE T.PANICKER
46	358870	PERUMAL V.	63	M	23-Oct-2013	BAV,SEV AS,MODAR,GDLV,SR, NC	AVR # 19 PM MAGNA	DR. VARGHESE T.PANICKER
47	362281	SYAMALA B.	53	F	13-Nov-2013	RHD,S/P CMV,SEV RE MS,MILD MS, MILD TR, GD LV, SR, NC	MVR # 25 CHVP + PARTIAL PMLP	DR. PRAVEEN VARMA P.K.
48	367284	SAINULABDHEEN I.	59	M	28-Nov-2013	CAD,LMCA+TVD,SEV LVD,SR,HTN,DM	CABG X 4 GRAFTS(LIMA- LAD,RSVG- D1,MAJ OM, PDA)+LINEAR PLICATION OF LV	DR. JAYAKUMAR K
49	367803	ESARY V	46	M	29-Nov-2013	CAD,LMCA DISSECTION,TVD,SEV LVD,SR,DM,HTN,DLP	CABG X 4 GRAFTS (LIMA- LAD,RSVG-MAJ D,RI,RPLB)	DR. VIVEK V. PILLAI
50	341834	RUGMINI S	59	F	29-Nov-2013	RHD,S/P MVR #25 SJM+PMLP+TV ANNULOPLASTY,PV THROMBOSIS, GD LV, AF,NC,OLD CVA	REDO MVR # 25 CHVP	DR. VARGHESE T.PANICKER
51	272355	VASANTHY T.	44	F	02-Dec-2013	BAV, SEV CAL AS,DILATED AORTA,GD LV,SR,NC	AVR #21 CHVP + AORTOPLASTY	DR. VARGHESE T.PANICKER
52	359447	VASANTHI .A	29	F	02-Dec-2013	RHD, SEV MR, MOD MS, MILD AR, MOD PAH, GOOD LV,	MVR #27CHVP WITH PMLP	DR. VIVEK V. PILLAI

						ATRIAL FLUTTER		
53	367253	RAJAN G.	62	M	03-Dec-2013	CAD, TVD, FAIR LV, SR, DM, DLP, OSTEOARTHRITIS	CABG X 4 (LIMA TO LAD; RSVG TO D1, OM1 & TERM OM)	DR. JAYAKUMAR K
54	366781	ZULFIKAR S	48	M	03-Dec-2013	CAD, TVD, GOOD LV, SR	CABG X 4 GRAFTS (LIMA TO LAD, RSVG TO D1, MAJOR OM AND RPDA)	DR. JAYAKUMAR K
55	360697	MARIAMMA.C	65	F	04-Dec-2013	CAD,TVD,SEV CAL AS,GDLV,SR,DM,HTN, DLP	AVR # 19 PM+CABG X 3G(RSVG- LAD,D2,RPDA)	DR. VIVEK V. PILLAI
56	364382	DEVU C.P.	50	F	02-Jan-2014	ACHD,OSASD,MOD MR,MILD PAH,GDLV,SR,NC,S/P HYSTERECTOMY	MV REPAIR(27 ANNULOPLASTY RING) +TPP CLOSURE OF ASD	DR. VIVEK V. PILLAI
57	356487	AJMAL K	16	M	02-Jan-2014	RHD,SEV AR,MOD MR,MOD LVD,SR	AVR #25 CHVP + MV REPAIR #31 TAILOR RING ANNULOPLASTY	DR. VARGHESE T.PANICKER
58	363697	CHATHU P K	64	M	03-Jan-2014	SEV CAL AS, MOD AR,GDLV,SR,NC	AVR #19 PM	DR. VARGHESE T.PANICKER
59	318623	RAHIM S	53	M	07-Jan-2014	CAD.TVD,MOD LVD,SR,/P PTCA(LAD&RCA)	CABG X 3 GRAFTS (LIMA-LAD,RSVG-RPDA,RPLB)	DR. PRAVEEN VARMA P.K.
60	212918	SHYLA R.	36	F	07-Jan-2014	RHD,SEV MR,MOD TR,SEV PAH,PDA,MOD RV DYSFN,GDLV,SR,DEPRESSIVE DISORDER	MVR # 25 CHVP+PMLP+BICUSPIDIS ATION OF TRICUSPID VALVE+PDA CLOSURE(TRANS PA)	DR. VARGHESE T.PANICKER
61	367922	ABU SHAMIL P.M	8	M	09-Jan-2014	CCHD, DORV,VSD,PS,TA,ASD , S/P LMBTS	BDG (RACHS2)	DR. SABARINATH MENON
62	365714	JOSE T.L.	51	M	16-Jan-2014	CAD,DVD,FAIR LV,SR	CABG X 3 GRAFTS(LIMA-LAD;RSVG-D1 & PDA)	DR. JAYAKUMAR K
63	372287	SIVANANDAN V.A.	64	M	21-Jan-2014	CAD,TVD,OLD ACS,GDLV,SR,DM,HTN ,COPD	CABG X 3 GRAFTS(LIMA-LAD;RSVG-D1 & RPDA)	DR. VIVEK V. PILLAI
64	372063	PRABHAKARAN NAIR S.	56	M	21-Jan-2014	CAD,TVD,GDLV,SR,DM ,DLP,VV	CABG X 6 GRAFTS (LIMA - LAD; RSVG-MAJ D,BOTH BRANCHS OF OM,AM,DISTAL RCA)	DR. JAYAKUMAR K
65	369325	SELVA KUMAR S	61	M	03-Feb-2014	CAD,TVD,REC	CABG X 5 GRAFTS(LIMA-	DR. JAYAKUMAR K

						MI,GDLV,SR,DM,HTN,D LP	LAD;RSVG-MAJ D,RI,MAJ OM,RPDA)	
66	364014	FATHIMA BEEVI . P	52	F	13-Feb-2014	RHD,MOD MS,MOD MR,MOD-SEV PAH,GDLV,SR,NC	MVR #25 CHVP+PMLP	DR. VARGHESE T.PANICKER
67	270581	JOSE C. D.	51	M	26-Feb-2014	CAD, TVD, GDLV, SR, DM, HTN, DLP	CABG X 4GRAFTS(LIMA-LAD & RSVG-D1,TERM OM,PDA)	DR. JAYAKUMAR K
68	247643	SUDAKARAN.C.	31	M	26-Feb-2014	RHD,SEV AR, MOD AS, MOD MS,MOD-SEV MR,MILD PAH,GDLV,AF	DVR(MV #23 CHVP +PMLP;AV #19 SJR)	DR. VARGHESE T.PANICKER
69	370138	VIJAYAKUMARAN K	60	M	03-Mar-2014	CAD,OLD MI,MILD LVD,TRIVALMR,SR,EPI CARDIAL CYST,DM,HTN,DLP	CABG X 5 GRAFTS (LIMA-LAD,RSVG-RI,MAJ OM,PDA,PLB)+EPICARDIA L CYST EXCISION,LV LINEAR PLICATION(ANTERIOR WALL)	DR. JAYAKUMAR K
70	368478	MANOHARAN K	58	M	03-Mar-2014	CAD,TVD,GDLV,SR,HT N,DLP	CABG X 5 GRAFTS (LIMA-LAD.RSVG-D1,D2,OM1,RPLB)	DR. JAYAKUMAR K
71	363460	ANANDABHAI AMMA . J	64	F	04-Mar-2014	CAD,TVD,GDLV,SR,HT N,BA	CABG X 4 GRAFTS (LIMA-LAD;RSVG-D1,OM1 & LPDA)(OM1 ENDARTERECTOMY)	DR. JAYAKUMAR K
72	326723	ATHULYA T.K	17	F	04-Mar-2014	ACHD,OS ASD,GDLV,SR	TPP CLOSURE OF ASD	DR. BINEESH K.R.
73	270147	RANJINI.R.	22	F	05-Mar-2014	RHD,SEV MR,MOD SEV AR,SEV TR,SEV PAH,GDLV,SR	DVR(MVR #27 CHVP+PMLP;AVR #19 CHVP)+TVA #28 MC3 RING	DR. VARGHESE T.PANICKER
74	361993	SOBHESH .K	31	M	07-Mar-2014	?IE SEQ,SEV AR,MILD AS,GD LV,LVH,SR,SCHIZOPH RENIA	AVR 3 21 CHVP	DR. VARGHESE T.PANICKER
75	339027	SURENDRAN A.	60	M	12-Mar-2014	CAD,DVD,OLD MI,SEV AR,MOD LVD,SR,LBBB,HTN.AN KYLOSING SPONDYLITIS	AVR #21 PM MAGNA+CABG X 3 GRAFTS(RSVG-LAD.D1.LPDA)	DR. VIVEK V. PILLAI

76	374523	AMBIKA P.	54	F	13-Mar-2014	CAD,LMCA,TV,REC MI,GDLV,SR.,HTN,DLP	CABG X 5 GRAFTS (LIMA-LAD,RSVG-MAJ DIAG,MAJ OM,PDA,PLB)	DR. JAYAKUMAR K
77	372862	MOHANDAS G.	61	M	28-Mar-2014	CAD,TVD,GDLV,SR,DM ,HTN,DLP,OSA	CABG X 6 GRAFTS(LIMA-LAD(VEIN PATCH AUGMENTATION);RSVG-D1,RI,OM2,RPDA,RPLB)	DR. PRAVEEN VARMA P.K.
78	376771	MOHANAN M	56	M	31-Mar-2014	CAD,RECENT MI,LMCA,TVD,MILD LVD,SR,DM,VV.	CABG X 6 GRAFTS(LIMA-LAD;RSVG-D1,RI,MAJ OM,RPDA.RPLB)	DR. PRAVEEN VARMA P.K.
79	376963	KANNAN R	0	M	07-Apr-2014	CCHD,DTGA,IVS,ASD, PDA,REGRESSED LV,SR,1LCX2R	ASO	DR. BAIJU S.DHARAN
80	374579	SREENANDA S.P.	0	F	11-Apr-2014	CHD,SA VSD,ASD,MVP ,MILD MR,SEVERE PAH,SR	VSD CLOSURE+ASD CLOSURE	DR. BAIJU S.DHARAN
81	339187	VIDHYA LEKSHMI S.	3	F	14-Apr-2014	DORV,SA VSD,MOD INF PS,MILD LPA ORIGIN STENOSIS,SR	TRANS RA PA ICR	DR. THOMAS MATHEW
82	340441	AL-HAMEED A A	3	M	16-Apr-2014	ACHD, POSTERIOR ASD, GD LV, SR	TANNED PERICARDIAL PATCH CLOSURE OF ASD	DR. ASHOK KUMAR C J
83	371177	ANEESH B	0	M	21-Apr-2014	ACHD,SA VSD,PFO,SEV PAH,SR	VSD CLOSURE WITH GORETEX PATCH	DR. SABARINATH MENON
84	366289	NIHAL K N	0	M	22-Apr-2014	CCHD,TA	PDA INTERRUPTION(WITH PARTIAL STENT RETRIEVAL)+BDGS+ATRIAL SEPTECTOMY+LPA&RPA PLASTY WITH TPP	DR. BAIJU S.DHARAN
85	319816	KRISHNA BABU	8	F	24-Apr-2014	CCHD,MALALLIGNED VSD, SEV INF PS, PDA, GOOD CONF PA, SR, NC	TRANS RA ICR	DR. SABARINATH MENON
86	332629	SAGUN	2	F	30-Apr-2014	CCHD,SA,DC,COMMON ATRIUM,SV-RV TYPE,PAPVC(R),PDA, OLD IE,OLD MCA STROKE	B/L BDG	DR. THOMAS MATHEW

87	376289	ANANTH RAM	0	M	30-Apr-2014	MALALIGNED VSD,MOD PS,MOD PAH,B/L SVC,SR,NC.	TRANS RA- PA ICR	DR. THOMAS MATHEW
88	352308	AMEYA K S	1	F	02-May-2014	MALALIGNED SA VSD,SEV PAH,SR.	VSD CLOSURE	DR. SABARINATH MENON
89	377270	MUHAMMED RAYYAN M S	0	M	05-May-2014	CCHD,DTGA,SPVSD,L ARGE ASD,LV REGRESSED,SR,1LCX 2R	ASO + VSD CLOSURE	DR. BAIJU S.DHARAN
90	338273	ARYA B S	4	F	06-May-2014	ACHD,OSASD,NO PAH,SR	TPP CLOSURE OF OSASD	DR. SABARINATH MENON
91	237295	JESSICA MANUEL	12	F	08-May-2014	ACHD,SA VSD,MOD AR(NCC PERFORATION),SAM, MOD LVOTO,NO PAH,SR	DC OF VSD+SAM EXCISION+ AV REPAIR	DR. THOMAS MATHEW
92	378184	CHINNU	3	F	09-May-2014	TOF WITH SEV PS,FAIR & CONFLUENT PA,GDLV,SR,VESSEL CROSSING RVOT,RECURRENT SPELLS,CSOM,FTT	TRANS RA PA ICR(INF RESECTION+VSD CLOSURE+MPA PATCH AUGMENTATION+TYSHAK (12) BALLON DILATATION OF PV)	DR. THOMAS MATHEW
93	188617	JEENA RAMESAN	15	F	12-May-2014	SS,DC,CTGA,VSD,PA, S/P LMBTS(2001),B/L BDG(2002),MILD AVVR,GOOD VENTRICULAR FN,SR	EXTRACARDIAC FENESTRATED FONTAN(WITH 22 PTFE GRAFT AND 6MM FENESTRATION)	DR. BAIJU S.DHARAN
94	376404	BLESON S VICTOR	0	M	15-May-2014	CCHD,DTGA,MULTIPLE VSD,S/P BAS,PRESERVED LV,SR,1LCX2R	ASOVSD CLOSURE(APICAL EXCLUSION)	DR. BAIJU S.DHARAN
95	337951	HAJIRA ISSANI	2	F	21-May-2014	ACHD,SA VSD,SEV INF PS,CONF PA,GDLV,SR,NC,PFO	TRANS RA ICR(PTFE PATCH CLOSURE OF VSD+INFUNDIBULAR RESECTION+PFO KEPT OPEN)	DR. THOMAS MATHEW
96	900948 5	CHINNAMMA.A.M.	43	F	22-May-2014	ACHD,SA VSD,SEV PAH,MOD TR,MILD MR,SR	VSD CLOSURE+DEVEGA'S TV REPAIR+PFO OPEN	DR. THOMAS MATHEW

97	348785	RUKSANA F	1	F	26-May-2014	ACHD,SA VSD,OS INFUNDIBULAR PS,CONF GOOD PA,GDLV, NC, SR	TRANS RA ICR(GP CLOSURE OF VSD+INFUNDIBULAR RESECTION)	DR. SABARINATH MENON
98	336291	ADIJAI J	5	M	27-May-2014	ACHD,SEVERE SUPRAVALVULAR AS,GDLV,SR	DOTY'S AORTOPLASTY	DR. BAIJU S.DHARAN
99	215936	VISHNU.J.	11	M	28-May-2014	CCHD,SV(RV),SEV PS,S/P RT BDG(2006),CONF PA,SR.	FENESTRATED EXTRACARDIAC FONTAN WITH 20MM PTFE GRAFT AND 4 MM FENESTRATION.	DR. BAIJU S.DHARAN
100	308918	KARUPPASAMY.K.	21	M	29-May-2014	SEV AR, P/S ICR+TAP+MONOCUSP FOR TOF	REDOSTERNOTOMY + AVR #29 CHVP	DR. BAIJU S.DHARAN
101	353655	ADITHYA KRISHNA .P	4	F	30-May-2014	ACHD,SA VSD,MULTIPLE MUSCULAR VSD,PDA,SEV PAH,GDLV,SR	GP CLOSURE OF VSD+ DC OF MULTIPLE VSDS+PDA INTERRUPTION	DR. SABARINATH MENON
102	369156	SIVAN PILLAI K.	74	M	02-Jun-2014	CAD,TVD,GDLV,SR,DM ,HTN,DLP,S/P PHLEBECTOMY LT LL AND VV RT LL.	CABG X 3 GRAFTS(LIMA- LAD,RSVG TO MAJ OM AND RPDA)	DR. PRAVEEN VARMA P.K.
103	311901	NELSON T	54	M	03-Jun-2014	CAD,TVD,RECRRT ACS,UA,GDLV,SR,DM, HTN,DLP,?POLIO RT LEG	CABG X 5 GRAFTS (LIMA- LAD;RSVG- D1,OM1,RPDA,RPLB)	DR. JAYAKUMAR K
104	378263	SUBHASH B K	56	M	04-Jun-2014	CAD,TVD,OLD IWMI,SEV MR,SEV LVD,SR,DM,DLP	CABG X 3 GRAFTS(RSVG- MAJ OM,D1,RPDA) + MVR #27 CHVP	DR. VIVEK V. PILLAI
105	307365	MOHANAN P	41	M	09-Jun-2014	RHD,SEV CAL MS,MILD MR,MILD AR,MOD PAH,CAD,OLD MI,MILD LVD,AF.NC	MVR # 27 CHVP+PMLP	DR. VARGHESE T.PANICKER
106	379097	SARASWATHY AMMA C	63	F	09-Jun-2014	S/P MI, VENTRICULAR SEPTAL RUPTURE,SEV LV DYSFN,SR,CONTRLLD FAILURE	VSR CLOSURE WITH PRE- CLOTTED FELT PATCH+LV ANNEURYSMORAPHY+CA BG X 1 GRAFT(RSVG-LAD)	DR. JAYAKUMAR K

107	379369	RAJAN CHENGUNI	50	M	10-Jun-2014	CAD,LMCA+TVD.GDLV .SR.HTN,DLP,?BPH	CABG X 4 GRAFTS(LIMA- LAD,RSVG-D,MAJ OM,PLB)	DR. JAYAKUMAR K
108	375459	SUNIL KUMAR G	49	M	11-Jun-2014	SEV AS,MOD AR,SEV LVD,SR,NC,DM	AVR # 23 CHVP	DR. BINEESH K.R.
109	378990	VASANTHAKUMAR E S	51	M	12-Jun-2014	CAD,TVD,HTN,SEIZUR E DISORDER,SR,DLP	CABG X 6 GRAFTS (LIMA- LAD,RSVG- DIAG,OM2,OM3,TERM OM,AM)	DR. JAYAKUMAR K
110	910490 4	SAJI KUMAR.K.	36	M	12-Jun-2014	RHD,SEV AR,ASC AO DILATATIONDILATED LV,GDLV,SR,NC	BENTALLS PROCEDURE(#29 CHVP+#30 ALBOGRAFT)	DR. JAYAKUMAR K
111	368746	SIDHARTH .S	12	M	13-Jun-2014	SEV TR, ATL PROLAPSE,GDLV/RV, SR	TV REPAIR(NEOCHORDAE TO ATL+TVA #28 MC3 RING)	DR. VIVEK V. PILLAI
112	370815	VISHALAKSHI AMMA .S	62	F	13-Jun-2014	CAD,DVD,LMCA,MR,G DLV,SR,DM,HT,DLP	CABG X 4 GRAFTS (LIMA- LAD;RSVG-MAJ D,OM1 AND TERM OM)	DR. JAYAKUMAR K
113	377324	CHANDRAMATHY AMMA K	70	F	16-Jun-2014	CAD,TVD,GDLV,SR,DM ,HTN,DLP	CABG X 4 GRAFTS(LIMA- LAD;RSVG-OM1,TERM OM,AMPDA)	DR. JAYAKUMAR K
114	379496	SHAJI B S	45	M	17-Jun-2014	D,TVD,GDLV,SR,DM,H TN,DLP	CABG X 4 GRAFTS(LIMA- LAD.RSVG-OM,TERM OM,PDA)(OM PIGGYBACKED TO TERM OM)	DR. VIVEK V. PILLAI
115	960880 5	SANTHA HARIDASAN	52	F	18-Jun-2014	S/P ASD CLOSURE,S/P PPI FOR SSS,SVC OBSTRUCTION	PG CHANGE	DR. BINEESH K.R.
116	377049	DEVARAJAN N	67	M	18-Jun-2014	CAD,TVD,GDLV,SR,DM ,HTN,DLP	CABG X 5 GRAFTS(LIMA- LAD;RSVG-MAJ D,BOTH BRS OF RI,DISTAL RCA)	DR. JAYAKUMAR K
117	306228	SAIFUDEEN P K	31	M	19-Jun-2014	ASC AO & ROOT ANEURYSM,SEV AR,DYNAMIC LVOTO,DIL LV,GDLV,AF,NC,MARF ANS SYNDROME	BENTALL'S PROCEDURE(# 27 CHVP+28 ALBOGRAFT)+SEPTAL MYECTOMY	DR. JAYAKUMAR K
118	380828	ANIL KUMAR P	53	M	22-Jun-2014	TYPE A AORTIC DISSECTION,SEV	SUPRACORONARY ASCENDING AORTIC	DR. JAYAKUMAR K

						AR,FAIR LV,AC PULM EDEMA,HTN,SR	REPLACEMENT WITH #30 ALBOGRAFT+RESUSPEN SION OF AORTIC VALVE	
119	376622	KALIRAJ V	49	M	23-Jun-2014	CAD,SVD,GDLV,SR,DM ,HTN,DLP	OPCAB X 2 GRAFTS(LIMA- LAD;RSVG-DI)	DR. JAYAKUMAR K
120	370151	VARGHESE G	64	M	23-Jun-2014	SEV CAL AS,CAD,SVD,GDLV,SR	AVR #19 SJM+CABG X 2 GRAFTS(RSVG-LAD&D1)	DR. VARGHESE T.PANICKER
121	375328	MOHANAN C	62	M	24-Jun-2014	CAD,TVD,MOD LVD,SR,DM,HTN	CABG X 5 GRAFTS (LIMA- LAD;RSVG-RI,MAJ OM,PDA,PLB)	DR. VIVEK V. PILLAI
122	375684	UMAIBA BEEVI M.	60	F	24-Jun-2014	POST CABG, DSWI	DEBRIDEMENT + PM FLAP REPAIR	DR RAMRAJ
123	373034	BHADRAN P.	53	M	25-Jun-2014	CAD,TVD,GDLV,SR,DM ,HTN,HCV +VE	CABG X 5 GRAFTS(LIMA- LAD;RSVG-LAD,D1,MAJOR OM AND RPDA)	DR. VIVEK V. PILLAI
124	372188	NAZAR M.	46	M	26-Jun-2014	CAD,TVD,S/P PTCA- RCA,GDLV,SR,DM,HTN	CABG X 4 GRAFTS(LIMA- LAD;RSVG-MAJ D,OM1,TERM OM)	DR. VIVEK V. PILLAI
125	367380	RAMESH P.	32	M	27-Jun-2014	RHD,SEV MR,MOD MS,MILD PAH,S/P CMV,GDLV,AF	MVR # 29 CHVP+PMLP	DR. VIVEK V. PILLAI
126	364218	ROOPESH.R.	0	M	03-Jul-2014	CHD,TOF,PA,PDA DEP PULM CIRC,S/P RMBTS (3MM PTFE),.SPELLS	TRANS RA-PA ICR(GP CLOSURE OF VSD+TAP+INF RESECTION+MONOCUSP RECONSTRUCTION OF RVOT)TAKEDOWN OF RMBTS+PFO OPEN	DR. BAIJU S.DHARAN
127	379338	B/O BUSHRA P	0	F	04-Jul-2014	LARGE INFLOW VSD,SV PHYSIOLOGY,SEV PAH,GOOD VENT FUNCTION,SR	PA BANDING AT 26MM WITH MERSILENE TAPE	DR. SABARINATH MENON
128	341884	AKHIL A	3	M	07-Jul-2014	TOF,CONF PA,GD LV, SR	TRANS RA ICR+PV INSPECTION	DR. THOMAS MATHEW
129	338531	ATHIRA J	5	F	09-Jul-2014	ACHD, OS ASD, PDA	TPP CLOSURE OF OS ASD + PDA INTERRUPTION	DR. ANANTHANARAYANAN C.

130	329891	HIDHASH K P	3	M	10-Jul-2014	CCHD,DTGA,SP VSD,SEV SV PS, STRADDLING MV,ASD,CONF PA,GDLV,SR,NC	RASTELLI PROCEDURE (# 21 SIZE PA HOMOGRAFT),PFO OPEN	DR. BAIJU S.DHARAN
131	370736	VEERAR ABDULLA S	0	M	11-Jul-2014	OF,CONF PA ANATOMY,NC,SR	ICR(GP CLOSURE OF VSD+INF RESECTION+RVOT PATCH AND MPA PATCH AUGMENTATION	DR. THOMAS MATHEW
132	381681	B/O SARAFUNNEESA	0	F	14-Jul-2014	SP/RMBTS WITH STENTED STERNUM	DSC	DR. SABARINATH MENON
133	351593	AKSHAY LAL S S	1	M	14-Jul-2014	SP/ICR FOR TOF WITH SSI	DEBRIDMENT & RESUTURING	DR. SABARINATH MENON
134	328992	SIYAD S.	8	M	16-Jul-2014	CCHD TOF CONF PA SR NC	TRANS RA PA ICR	DR. THOMAS MATHEW
135	369974	ANURAG .S	5	M	16-Jul-2014	ACHD SV ASD PAPVC OF RUPV,GDLV,SR	WARDENS PROCEDURE	DR. THOMAS MATHEW
136	353221	B/O SAJNA	1	F	18-Jul-2014	TOF CONF PA ANATOMY SEV INF PS GDLV SR NC	ICR+RVOT PATCH	DR. THOMAS MATHEW
137	339351	MOHAMMED AMEEN ASHTAQ	8	M	21-Jul-2014	ACHD SVASD PAPVC OF RUPV GDLV SR	DOUBLE PATCH REPAIR	DR. SABARINATH MENON
138	365349	ABHINAV A P	2	M	23-Jul-2014	ACHD SV ASD PAPVC OF RUPV SR NC	DOUBLE PATCH REPAIR	DR. THOMAS MATHEW
139	382218	ASRITH S	0	M	25-Jul-2014	DTGA, IVS, P/BAS, REGRESSING LV, 1LCX2R	ASO	DR. BAIJU S.DHARAN
140	381681	B/O SARAFUNNEESA	0	F	29-Jul-2014	PA,VSD,FAIR PA,/P RMBTS/PDA LIGATION/PE DRAINAGE,SEV TR.	REDO STERNOTOMY AND TV REPAIR	DR. BAIJU S.DHARAN
141	380941	PRATHEEKSHA P	1	F	30-Jul-2014	TOF,FAIR CONF PA, DUAL LAD CROSSING RVOT,B/L SVC,SR,SPELLS	ICR+TRANSANNULAR PATCH	DR. THOMAS MATHEW

142	382696	ABHIRAMI B S.	2	F	01-Aug-2014	CCHB, NORMAL CARDIAC ANATOMY	PERMANENT PACEMAKER IMPLANTATION	DR. SABARINATH MENON
143	338534	AJISHA M	8	F	04-Aug-2014	AVCD,ADD OS ASD,MOD MR,MILD TR,PAH,SR	ICR(MV REPAIR+TPP CLOSURE OF OSTIU, PRIMUM ASD AND OS ASD) (MINISTERNOTOMY APPROACH)	DR. THOMAS MATHEW
144	329155	THAINESH MARIYAL L	38	F	06-Aug-2014	EBSTEIN ANOMALY OF TV,SEV TR,NO ASD,SR	ONE AND A HALF REPAIR(CONE REPAIR+ BDG)	DR. BAIJU S.DHARAN
145	379658	ANCY A.B	2	F	07-Aug-2014	SVASD,PAPVC OF RUPV TO SVC-RA JN,NO PAH,SR	DOUBLE PATCH REPAIR	DR. SABARINATH MENON
146	377739	SREELEKSHMI RATHEESH	1	F	08-Aug-2014	S/P VSD CLOSURE WITH SURGICAL SITE GRANULOMA.	DEBRIDEMENT AND RESUTURING	DR. SABARINATH MENON
147	381882	ANAMIKA.B	0	F	08-Aug-2014	ACHD,MAL-ALLIGNED SAVSD,FENESTRATE D IAS,SEV PAH,SR	GP CLOSURE OF VSD+FENESTRATED TPP CLOSURE OF ASD.	DR. SABARINATH MENON
148	383183	RESHNAV R.	3	M	09-Aug-2014	LARGE ATRIAL MASS ?MYXOMA, NO PAH,REC. LARGE LT.MCA INFARCT,SR	LA MASS EXCISION	DR. SABARINATH MENON
149	353908	SURABHI .S.G	5	F	11-Aug-2014	SA VSD,INF PS,GDLV,SR	TRANS RA ICR	DR. THOMAS MATHEW
150	199344	INDUMATHI S.	17	F	12-Aug-2014	INF PS, OSASD,RV DYS,SR	ICR+TRANSANNULAR PATCH+MONOCUSP RECONSTRUCTION OF RVOT AND ASD CLOSURE WITH FENESTRATED TPP.	DR. THOMAS MATHEW
151	383310	B/O SAHIRA.	0	M	13-Aug-2014	OBST.SC TAPVC,ASD,PDA,SEV PAH	PRIMARY SUTURELESS REPAIR	DR. THOMAS MATHEW
152	383471	B/O PREETHA	0	F	19-Aug-2014	TRUNCUS ARTERIOSUS(TY1V),IN TERRUPTED AO ARCH (TY B),TRUNCAL REGURGITATION,BIVE NT DYSFN,SINGLE CORONARY,SR	TRUNCAL VALVE REPAIR+TRUNCUS ARTERIOSUS REPAIR(# 17 PA CONDUIT)+ARCH REPAIR+PFO OPEN	DR. BAIJU S.DHARAN

153	373544	NAUHMANN BISHEER	14	M	21-Aug-2014	ACHD,SV ASD,PAPVC OF RUPV AND RMPV, SR	DOUBLE PATCH REPAIR	DR. SUDIP DUTTA BARUAH
154	383782	AL AMEEN A.	0	M	22-Aug-2014	ACHD,SEV PSCA COA,SEV BIVENTRICULAR DYSFUNCTION,SR	RESECTION AND EXTENDED END-END ANASTAMOSIS	DR. BAIJU S.DHARAN
155	377240	HASHEEM ZIN M	0	M	25-Aug-2014	TOF,GOOD CONF PA , PDA, SR,NC, SPELLS+	ICR+RVOT PATCH+MPA PLASTY	DR. THOMAS MATHEW
156	340280	AMEER ABBAS N.	3	M	01-Sep-2014	CCHD,TOF,CONF PA,NC,SR,	ICR+RVOT PATCH(TPP)+MPA PATCH(TPPC)	DR. THOMAS MATHEW
157	379869	B/O SHYNI	0	F	02-Sep-2014	CCHD,TOF,CONF FAIR PA,LPA STENOSIS,NC,SR,H/O SPELLS	ICR+TAP+MONOCUSP RECONSTRUCTION OF RVOT+LPA PLASTY	DR. THOMAS MATHEW
158	330284	MUHAMMED BILAL A	3	M	03-Sep-2014	PA,SA VSD,MAPCAS,CONF POOR PA,RPA STENOSIS,GD BV FUNCTION,SR	UNIFOCALISATION OF MAPCA TO UPPER BR OF RPA+ICR(4MM FENESTRATED GP)+TAP+MONOCUSP RECONSTRUCTION OF RVOT+MPA,CONFLUENCE AND BR PA PLASTIES	DR. BAIJU S.DHARAN
159	330719	ADVAITH A R	3	M	08-Sep-2014	TOF,FAIR CONF PA,STATIC ENCEPHALOPATHY,SR,NC	ICR+RVOT PATCH+ MPA PATCH	DR. THOMAS MATHEW
160	294793	AJI .R	7	M	10-Sep-2014	ACHD, PARTIAL AVCD,CLEFT AML, SEV MR,MOD TR,PFO,SEV PAH,SR+ ATRIAL ECTOPICS	PAVCD REPAIR(CLEFT AML REPAIR+MV ANNULOPLASTY+TPP CLOSURE OF OPASD+TV REPAIR)+ PFO MADE RESTRICTIVE	DR. BAIJU S.DHARAN
161	381841	VARSHA M	0	F	12-Sep-2014	CARDIAC TAPVC,HYPOPLASTIC LA/MV,MULTIPLE VSDS,ASD,SEV PAH,SR	PA BANDING TO 27MM(MERSILENE TAPE)+ATRIAL SEPTECTOMY+ CS CUTBACK	DR. BAIJU S.DHARAN
162	361021	DANISH MOHAMMED	1	M	12-Sep-2014	TOF,CONF FAIR PA,PDA,ASD,B/L	ICR+RVOT PATCH	DR. SABARINATH MENON

						SVC,SR.		
163	384645	B/O ASIA BEEVI	0	M	16-Sep-2014	CSEV POST SUBCLAV COA,OSASD,SEV PAH,BIVENTRICULAR DYSFN,SR	RESECTION AND EXTENDED END TO END ANASTAMOSIS	DR. BAIJU S.DHARAN
164	880616 7	RAJESH.M.	32	M	18-Sep-2014	BLEEDING, S/P BIVENTRICULAR REPAIR	RE-EXPLORATION AND HEMOSTASIS	DR. THOMAS MATHEW
165	368287	MOHAMMED FAHAD.T.N	0	M	26-Sep-2014	CCHD,TOF,S/P BPV,CONF PA,LPA STENOSIS,SR,NC	ICR+TAP WITH MONOCUSP RECONSTRUCTION OF RVOT+ LPA PLASTY+PFO CLOSED	DR. THOMAS MATHEW
166	383449	AAZA FATHIMA A.N.	0	F	29-Sep-2014	S/P ICR+TAP+LPA PLSTY+MNOCUSP RCNST RVOT FOR TOF WITH CHB	PPI	DR. SABARINATH MENON
167	374925	VIGEESH V.	0	M	30-Sep-2014	DORV,SP VSD,SEV PAH,GDLV,SR,1L2RCX	ASO+VSD CLOSURE+PFO OPEN	DR. BAIJU S.DHARAN
168	374165	RAVEENDRAN R.	64	M	01-Oct-2014	CAD,TVD,GDLV,SR,DM	CABG X 4 GRAFTS(LIMA- LAD.RSVG- MAJ D, OM2,RPDA)	DR. JAYAKUMAR K
169	316066	RAMA LEKSHMI.S	37	F	01-Oct-2014	RHD,SEV MS,MILD MR,SEV AS,MILD AR,MOD TR,GDLV,SR,/P BMV AND BTV	DVR+TV REPAIR(MVR 23 CHVP, AVR 17 CHVP)	DR. VARGHESE T.PANICKER
170	329248	KHADEEJA P	48	F	07-Oct-2014	SAM, MILD LVOTO,MILD AR,GDLV,SR,NC	SAM EXCISION	DR. VIVEK V. PILLAI
171	381415	SURESH BABU R	45	M	08-Oct-2014	CAD,LMCA+TVD,REC ACS,GDLV,SR,DM,HTN .DLP	CABG X 5 GRAFTS (LIMA- LAD;RSVG-MAJ D, OM1, TERM OM, RCA)	DR. JAYAKUMAR K
172	376362	SHANTHA PADMANABHAN	54	M	08-Oct-2014	ACHD,OSASD,MILD PAH,GD VENT FN, SR	TPP CLOSURE OF OSASD	DR. BINEESH K.R.
173	379147	VASANTHY L	66	F	09-Oct-2014	CAD,LMCA,TVD,GDLV, SR,DM,HTN,DLP	CABG X 6 GRAFTS(LIMA- LAD, RSVG- D1, D2, OM1, RPDA & RPLB)	DR. JAYAKUMAR K
174	374009	DASSAN C	51	M	10-Oct-2014	RHD SEV MR MOD AR MILD PAH GD LV AF	DVR (MVR - #29 CHVP; AVR - #23 CHVP)	DR. VARGHESE T.PANICKER

						NC		
175	382246	SASIDHARAN B.	69	M	13-Oct-2014	CAD, TVD, GDLV, SR,DM, HTN, DLP	CABG X 6G (LIMA--> D1, RSVG --> DISTAL LAD, PDA, PLB, OM <MEDIAL & LATERAL BRANCH>	DR. VIVEK V. PILLAI
176	375058	AHMED RIZA	60	M	14-Oct-2014	RHD SEV RE MS MOD AR SEV TR ORG TVD S/P BMV OS ASD AF COPD GOUT	DVR (MVR #23 CHVP; AVR # 17 CHVP)+TVA(28 MC3 RING)+DC OF ASD	DR. VARGHESE T.PANICKER
177	375676	GIRISAN PILLAI P K	63	M	15-Oct-2014	CAD TVD SEV AR SEV AS SEV LVD MOD RVD MOD PAH AF	AORTIC ROOT ENLARGEMENT(NUNEZ) + AVR # 21 PM + CABG X 2 GRAFTS(RSVG- D2 AND RV BRANCH)	DR. VARGHESE T.PANICKER
178	350448	RAMACHANDRAN K	55	M	16-Oct-2014	MVP SEV MR DIL LV CAD SVD SR	MVR #29 CHVP + CABG X 1 GRAFT (LIMA- LAD)	DR. VARGHESE T.PANICKER
179	356149	SUNIL S	31	M	17-Oct-2014	ACHD, OSASD, MILD- MOD PAH,SR, GD BV FUNCTION	TPP CLOSURE OF OSASD	DR. SIVAPRASAD V.
180	380200	GOPALAKRISHNAN P	58	M	23-Oct-2014	CAD,TVD,MOD LVD,LV CLOT,SR,HTN	CABG X 4 GRAFTS (LIMA- MID LAD, RSVG- DISTAL LAD,MAJ OM,RPDA)+ENDARTEREC TOMY OF MID LAD+ LV CLOT EXTRACTION	DR. VIVEK V. PILLAI
181	358346	SREEKUMARI AMMA S.	54	F	23-Oct-2014	? TAKAYSU ARTERITIS,CAD,LMCA +TVD,MOD AR,GDLV,SR,H/O MYOCARDITIS & DCMP, LT SCA STENOSIS,B/L VERTEBRAL ART STENOSIS	AV REPAIR(COMMISSUROPL ASTY)+ CABG X 4 GRAFTS(RSVG- LAD,DIAG,OM,RPLB)	DR. VIVEK V. PILLAI
182	386442	SOUDHAMINI C	73	F	24-Oct-2014	CAD,DVD,GDLV,SR,HT N,S/P PCI TO LCX AND POBA TO LAD	CABG X 3 GRAFTS(LIMA- LAD; RSVG- MAJ DIAG AND OM2)	DR. JAYAKUMAR K
183	378321	DEVAKI M K	63	F	24-Oct-2014	CAD,DVD,GDLV,SR,OL D CVA,DM,HTN,LCA STENOSIS	CABG X 3 GRAFTS(LIMA- LAD;RSVG- MAJ DIAG+PDA)	DR. VIVEK V. PILLAI

184	380327	ACHUTHAN V	54	M	27-Oct-2014	CAD,TVD,GDLV,SR,DM,HTN	CABG X 6 GRAFTS(LIMA-LAD,RSVG-D1,OM1,OM2,PDA & PLB)	
185	331741	NISHANTH C.R.	14	M	28-Oct-2014	RHD,RESTRICTIVE PML AND A2 PROLAPSE WITH SEV MR,MILD TR,SEV PAH,GDLV,SR	MV REPAIR (ANNULOPLASTY WITH #25 TAILOR RING)	DR. VARGHESE T.PANICKER
186	380351	SUKUMARAN K	62	M	29-Oct-2014	CAD,TVD,GDLV,SR,DM,HTN,DLP	CABG X 4 GRAFTS(LIMA-LAD;RSVG-PDA, OM1 & OM2)	DR. JAYAKUMAR K
187	386312	SASIDHARAN NAIR K.	52	M	29-Oct-2014	CAD,TVD,GDLV,SR,HTN	CABG X 5 GRAFTS (LIMA - LAD; RSVG - D1, MAJ OM, TERM OM & RPDA)	DR. JAYAKUMAR K
188	376855	AYISHA KUTTY PALA	33	F	31-Oct-2014	ACHD,OS ASD,TRIVIAL MR,MILD PAH,GD BIVENTRICULAR FN,SR.	TPP CLOSURE OF ASD	DR. BINEESH K.R.
189	374393	APPU N	63	M	04-Nov-2014	BAV,SEV CAL AS,ANEURYSMAL ASC AORTA,GDLV,LBBB,1 HB, NC, SR	MODIFIED BENTALL PROCEDURE (#27 CHVP + #28 ALBOGRAFT)	DR. JAYAKUMAR K
190	378891	GOPAKUMAR P R	43	M	05-Nov-2014	CAD,TVD,FAIR LV, MILD MR,SR,DM,HTN	CABG X 4 GRAFTS (LIMA - LAD; RSVG - DIAG, MAJ OM, RPDA)	DR. VIVEK V. PILLAI
191	376855	AYISHA KUTTY PALA	33	F	06-Nov-2014	PE,S/P ASD CLOSURE	PE DRAINAGE	DR. BINEESH K.R.
192	385819	VISWAMBARAN M.G.	61	M	06-Nov-2014	CAD,LMCA,TVD,GDLV,HTN,HYPOTHYROIDISM	CABG X 6 GRAFTS (LIMA - LAD, RSVG - D2, OM1, OM2, DISTAL RCA, AMPDA)	DR. JAYAKUMAR K
193	360121	SABU JOSEPH	47	M	06-Nov-2014	HOCM,SEV LVOTO, GOOD LV,SR		DR. VIVEK V. PILLAI
194	386728	GOPALAKRISHNAN NAIR B.	64	M	07-Nov-2014	CAD,TVD,MILD LVD,SR,HTN,DLP,HYPOTHYROID	CABG X 5 GRAFTS(LIMA - LAD; RSVG - MAJ DIAG, OM1,OM3 & RPDA) + RE-EXPLORATION FOR GRAFT THROMBOSIS AND THROMBUS ASPIRATION	DR. JAYAKUMAR K
195	971049	THANGAMANI.V.	49	F	10-Nov-2014	RHD,SEV AR,MOD	AVR # 17 SJR	DR. BINEESH K.R.

	9					AS,MILD MR,GD LV,SR,NC		
196	378275	JANAKI M	30	F	11-Nov-2014	RHD,SEV AS,MOD AR,SEV MS,MOD MR,NO PAH,GDLV,SR	DVR(MVR 3 23 CHVP AND AVR 3 19 CHVP)	DR. VARGHESE T.PANICKER
197	380933	SASIDHARAN D	59	M	12-Nov-2014	CAD,TVD,MILD LVD,SR,DLP,VV	CABG X 3 GRAFTS (LIMA-LAD; RSVG- MAJ DIAG AND AMPDA)	DR. VIVEK V. PILLAI
198	378068	BALAN P.	58	M	14-Nov-2014	ACHD,OSASD,GDLV,N O PAH,SR,COPD	TPP CLOSURE OF ASD	DR. SIVAPRASAD V.
199	384352	MANOHARAN N.	58	M	14-Nov-2014	CAD,TVD,OLD MI, RECENT UA, GDLV,SR,DM,HTN,BPH	CABG X 5 GRAFTS (LIMA-LAD; RSVG- MAJ DIAG,RI,RPLB & RPDA)	DR. VIVEK V. PILLAI
200	385751	SREEKANDAN NAIR	58	M	17-Nov-2014	RHD, SP/OMV, S/P CMV FOR SEV MS, SEV MR,MOD MS,SEV PAH, GOOD VENT FUNCTION, AF, HCV+	REDOSTERNOTOMY + MVR # 27 CHVP	DR. VARGHESE T.PANICKER
201	385947	VIJAYAN C.	62	M	17-Nov-2014	CAD,TVD,OLD MI,SEV LVD,SR,DM,HTN,RENAL DYSFN	CABG X 5 GRAFTS (LIMA-LAD; RSVG - MAJ DIAG, OM2, OM3 & RPDA) + LINEAR PPLICATION OF LV	DR. JAYAKUMAR K
202	370553	VIJAYAMMA K N	72	F	18-Nov-2014	BAV SEV CAL AS MOD AR MOD MR PAH MOD LV DYSFUNCTION SR NC RENAL DYSFUNCTION CCF	AVR # 19 PM	DR. VARGHESE T.PANICKER
203	386174	SHEEBA LALU	46	F	18-Nov-2014	MVP,SEV MR, SEV PAH,DIL LV, GDLV,SR,NC	MV REPAIR(TRIANGULAR RESECTION OF PML AND MVA WITH # 35 TAILOR RING)	DR. VARGHESE T.PANICKER
204	385232	NARAYANAN NAIR K.	65	M	19-Nov-2014	BAV SEV CAL AS CAD DVD SEV LV DYSFUNCTION SR HTN DM	AVR # 23 PM + CAVG X 2 GRAFTS (RSPV - DISTAL RCA , OM3)	DR. VARGHESE T.PANICKER
205	379634	KUMAR A	36	M	20-Nov-2014	RHD,SEV MS,SEV MR,GD BV FUNCTION, MOD PAH,SR	MVR # 23 CVP + PARTIAL PMLP	DR. BINEESH K.R.
206	382532	RESHMA R.	21	F	21-Nov-2014	ACHD, MULTIPLE OSASD, MILD-MOD	TPP CLOSURE OF OS ASDS AND PULMONARY	DR. BINEESH K.R.

						PS, NO PAH, GD BIVENT FUNCTION, SR	VALVOTOMY	
207	378727	MUHAMMED ASHRAF K	41	M	24-Nov-2014	SEV AR, AO ROOT DIL, ASC AO ANEURYSM, MILD MR, DIL LV, SEV LVD, SR, MARFANS	MODIFIED BENTALL'S PROCEDURE(# 29 CHVP & #30 ALBOGRAFT)	DR. JAYAKUMAR K
208	379814	RAMACHANDRAN NAIR N	53	M	25-Nov-2014	CAD TVD MOD LVD SR OLD CVA DM HTN	CABG X 4 GRAFTS(LIMA - LAD,RSVG - DIAG, RI, MAJ OM)(DIAGONAL PIGGYBACKED TO RAMUS)	DR. JAYAKUMAR K
209	325286	RAJAGOPALAN NAIR .K	69	M	26-Nov-2014	CAD TVD MOD LV DYSFN SR DM DLP BPH S/P PCI	CABG X 5 GRAFTS(LIMA - LAD;RSVG - D1,D2,MAJ OM & RPDA)	DR. JAYAKUMAR K
210	380647	SOSAMMA ANTONY	70	F	26-Nov-2014	CAD TVD GDLV SR DM HTN	CABG X 5 GRAFTS(LIMA-LAD;RSVG- DISTAL LAD,RI,MAJ OM,RPDA)	DR. JAYAKUMAR K
211	384168	YASODHARAN K.	70	M	27-Nov-2014	S/P CABG (3 GRAFTS WITH MOD LV DYSFUN) WITH SSI OF CHEST WITH STERNAL WOUND DEHISCENCE	FLAP RECONSTRUCTION OF THE STERNAL WOUND	DR. SIVAPRASAD V.
212	288678	THAMPI V K	57	M	27-Nov-2014	CAD TVD MOD-SEV MR MILD PAH GDLV SR RENAL DYSFN	CABGX 4 GR(LIMA-->LAD, RSVG-->UPPER BRANCH OF MAJ DIAGONAL, OM,RPDA, OM PIGGY BACKED TO DIAGONAL) MV REPAIR WITH # 26 SADDLE RING ANNULOPLASTY	DR. VIVEK V. PILLAI
213	387171	SARANGAPANI E.K.	55	M	28-Nov-2014	CAD,MULT VSR,MOD MR,H/O VT/VF->DC VERTED,HF,SEV LVD,SR	VSR CLOSURE(THROUGH L VENTRICULOTOMY)+ CABG X 3 GRAFTS(RSVG-LAD, MAJ OM & RCA)+ MVA(#29 TAILOR RING)	DR. JAYAKUMAR K
214	385269	NARAYANAN NAIR A.R.	71	M	28-Nov-2014	CAD,TVD,GDLV,SR,HT N	CABG X 4 GRAFTS (LIMA-LAD; RSVG-MAJ DIAG, MAJ OM & LPDA)	DR. JAYAKUMAR K

215	384909	NAZARUDEEN T.	61	M	01-Dec-2014	CAD,TVD,GDLV,SR,HT N,DM	CABG X 5 GRAFTS (LIMA- LAD; RSVG-MAJOR OM, MAJOR DIAGONAL,LPDA AND DISTAL RCA)	DR. VIVEK V. PILLAI
216	387777	LALITA GHOSH	52	F	01-Dec-2014	CAD,TVD,LMCA,GDLV, SR,,LT SCA STENOSES,LT RENAL ARTERY STENOSES,HTN,DLP	CABG X 6 GRAFTS(RSVG- -> LAD, D1,TERM OM, MAJ OM, , DISTAL RCA, RCA WITH ENDARTERECTOMY OF RCA,(DIST RCA PIGGY BACKED TO PROX RCA)	DR. VIVEK V. PILLAI
217	278369	DEVASIA A.M.	58	M	02-Dec-2014	CAD,TVD,GDLV,SR,DL P	CABG X 5 G RAFTS (LIMA - LAD; RSVG - D1, OM1, OM3(TERMINAL OM) AND DISTAL RCA)	DR. JAYAKUMAR K
218	382767	NITHYA THILAK	19	F	02-Dec-2014	PARTIAL AVCD(OPASD+CLEFT AML), OSASD, MILD MR, NOPAH, SR, HYPOTHYROID	MV REPAIR(CLEFT REPAIR) + TPP CLOSURE OF OP ASD + DC OF OS ASD	DR. VARGHESE T.PANICKER
219	380046	REMA DEVI K	57	F	03-Dec-2014	CAD,TVD,GDLV,SR,DM ,HTN,DLP	CABG X 5 GRAFTS (LIMA- LAD; RSVG-MAJ D, OM2, OM3 AND RCA)	DR. JAYAKUMAR K
220	336173	SUNEESH C A	33	M	04-Dec-2014	MARFANS SYND, SEV MR, MVP(A2, A3 PROLAPSE), MOD PAH, FAIR LV, SR	MV REPAIR (2 NEOCHORDAE + #31 TAILOR RING ANNULOPLASTY)	DR. VARGHESE T.PANICKER
221	386686	THANKAPPAN S.	56	M	04-Dec-2014	CAD,TVD,LMCA,GDLV, DM,HTN,DLP,SR	CABG X 6 GRAFTS(LIMA TO LAD,RSVG TO D1,OM1,OM2,ACUTE MARGINAL AND PDA)RPDA PIGGYBACKED TO ACUTE MARGINAL,D1 PIGGYBACKED TO OM1	DR. JAYAKUMAR K
222	990696 9	BABY JALAJA S.	39	F	05-Dec-2014	RHD, SEV MS, SEV MR, MILD TR, MILD PAH, GOOD VENTRICULAR FUNCTION, AF	MVR # 25 CHVP+PMLP	DR. BINEESH K.R.
223	350966	KOILPILLAI M	49	M	08-Dec-2014	ACHD, OS ASD, CLEFT AML, MOD MR, SEV	TPP CLOSURE OF ASD, MV REPAIR(CLEFT AML	DR. JAYAKUMAR K

						TR, MOD PAH, GOOD BIV FUNCTION, AF, NC	REPAIR+ KAYS ANNULOPLASTY), TV REPAIR(DEVEGAS ANNULOPLASTY)	
224	382600	MURUGAN P.	60	M	09-Dec-2014	CAD DVD GDLV SR HTN DLP	CABG X 3 GRAFTS (LIMA - LAD. RSVG - RAMUS AND MAJ OM)	DR. VIVEK V. PILLAI
225	385567	PADMANABHAPILLAI T.	70	M	09-Dec-2014	SEV CAL AS, CAD, DVD, S/P PCI TO RCA, GDLV, DLP, HTN	AVR # 19 PM + CABG X 1 GRAFT (RSVG - MAJ OM)	DR. VIVEK V. PILLAI
226	379512	SHAHUL HAMEED M	61	M	10-Dec-2014	CAD,TVD,OLD MI,SEV MR,SEV LVD,HTN,DLP,SR	MVR #25 PERIMOUNT+CABGX5GR(LIMA-DIAGONAL,RSVG-LAD,RAMUS,MAJ OM,RPDA)	DR. VIVEK V. PILLAI
227	380019	JALAJA MONY	59	F	11-Dec-2014	CAD TVD GDLV SR DM HTN DLP	CABG LIMA - LAD, RSVG - D1, D2, ANTERIOR BRANCH OF OM AND RCA	DR. JAYAKUMAR K
228	387125	AJAY KUMAR A.	44	M	11-Dec-2014	CAD TVD GDLV SR HTN DM DLP	CABG X 4 GRAFTS (LIMA-LAD; RSVG-MAJ DIAG, MAJ OM & RPDA)	DR. JAYAKUMAR K
229	386947	JAYAKUMARI S.	63	F	12-Dec-2014	CAD,TVD,GDLV,SR,DM ,HTN,DLP	CABG X 5 GRAFTS (LIMA-LAD;RSVG- DIAGONAL, MAJOR OM, TERM OM & RPDA)	DR. JAYAKUMAR K
230	367547	SIVARATHINAM S	68	M	15-Dec-2014	BAV SEV CAL AS ,GDLV,SR,NC	AVR # 21 PM	DR. BINEESH K.R.
231	375690	AHAMMED IBRAHIM A.	56	M	15-Dec-2014	CAD,TVD,LMCA,OLD IWMI,FAIR LV, SR,DM,HTN	CABG X 5 GRAFTS (LIMA-LAD; RSVG- D1,MAJ OM, LPDA & RPDA)	DR. VIVEK V. PILLAI
232	383166	RAMACHANDRAN R.	65	M	16-Dec-2014	CAD, LMCA, TVD, OLD AWMI, MILD LVD, SR, DLP	CABG X 3 GRAFTS (LIMA-LAD;RSVG-PLB,OM3 AND DISTAL LAD)	DR. VIVEK V. PILLAI
233	382437	SHAMSUDEEN K.	52	M	17-Dec-2014	CAD,DVD,AWMI,MILD LVD,SR,EX SMOKER	CABG X 4 GRAFTS(LIMA-LAD; RSVG-PROXIMAL LAD, OM2 & OM3) + LINEAR PPLICATION OF LV	DR. VIVEK V. PILLAI

234	386375	SHAHUL HAMEED P.	27	M	17-Dec-2014	RUPTURED SOV (RCC), SMALL SPVSD, MILD PAH, GDLV,SR	DC OF VSD + RSOV REPAIR WITH DACRON PATCH REINFORCEMENT	DR. VIVEK V. PILLAI
235	383685	RAMACHANDRAN K.M.	57	M	18-Dec-2014	CAD,TVD,GDLV,SR,HT N,PVOD(LT. SCA)	CABG X 6 GRAFTS (LIMA-LAD;RSVG-DISTAL LAD, MAJ D, OM1,OM2 & RPDA)	DR. JAYAKUMAR K
236	325119	PRABHU D	34	M	19-Dec-2014	RHD,SEV CAL MS,GDLV,SR	MVR # 27 CHVP+PMLP	DR. BINEESH K.R.
237	388228	VADHYAR R.S.	73	M	19-Dec-2014	CAD,TVD,GDLV,SR,DM ,HTN	CABG X 4 GRAFTS (LIMA - LAD; RSVG- C)	
238	383028	JANARDHANAN V.G.	73	M	23-Dec-2014	CAD,TVD,SEV LV DYSFUNCTION,SR	CABG X 5 GRAFT(LIMA-LAD,RSVG-D1, D2, MAJ OM & RPDA)	DR. JAYAKUMAR K
239	386904	MOHANAKUMAR K.	54	M	29-Dec-2014	CAD TVD GDLV SR HTN DM DLP	CABG X 5 GRAFTS (LIMA-LAD,RSVG-D1, MAJ OM, AM & RPDA)	DR. JAYAKUMAR K
240	380642	UDAYAPPAN V P	56	M	30-Dec-2014	RHD SEV CAL MS MILD MR MILD PAH SR ANOMALOUS RCA	MVR # 25 CHVP + PARTIAL PMLP	DR. BINEESH K.R.
241	383301	SIVASANKARAN V.	52	M	30-Dec-2014	CAD TVD GDLV SR HTN DM DLP	CABG X 5 GRAFTS (LIMA - LAD, RSVG - MAJ DIAG, MAJ OM,AM & DISTAL RCA)	DR. JAYAKUMAR K
242	387940	PADMA DEV K.P.	63	M	31-Dec-2014	CAD LMCA DVD SEV LVD SR	CABG X 3 GRAFTS (LIMA-LAD;RSVG-D1 AND MAJOR OM) WITH LAD ENDARTERECTOMY AND VEIN PATCH AUGMENTATION	DR. JAYAKUMAR K
243	377155	VIJAYAN K P	56	M	01-Jan-2015	BAV SEV CAL AS MILD AR GDLV SR	AVR #23 CHVP	DR. BINEESH K.R.
244	385534	RATHINA SABAPATHY R.	65	M	02-Jan-2015	CAD TVD MILD MR GDLV SR DM	CABG X 5 GRAFTS (LIMA-LAD; RSVG - MAJ DIAG, OM2, TERM OM AND RPDA)	DR. VIVEK V. PILLAI
245	384221	VIJAYAN N.	60	M	03-Jan-2015	MUCOSAL ISCHAEMIA BUT NO GANGRENE, S/P AVR # 23 CHPY+ MV REPAIR WITH ? MESENTRIC ISCHAEMIA	EXPLORATORY LAPAROTOMY	DR. BINEESH K.R.

246	316243	BIBIN DEV J.S.	22	M	05-Jan-2015	RHD,SEV AS,MOD AR,MOD MS,MILD MR,GDLV,SR	AVR #18 ATS+ OMV	DR. VIVEK V. PILLAI
247	383436	ARJUNAN PILLAI C.	69	M	05-Jan-2015	CAD,TVD,MOD LVD,SR,DM	CABG X 4 GRAFTS(LIMA-LAD, RSVG- D1, D2 & OM2)	DR. VIVEK V. PILLAI
248	385268	THANKAPPAN NAIR C.	60	M	06-Jan-2015	SEV CAL. AS CONC. LVH MILD AR NO PAH SR GDLV DM HTN	AVR # 19 PM	DR. BINEESH K.R.
249	383455	MATHAI E.	60	M	06-Jan-2015	CAD TVD GDLV SR DM HTN DLP	CABG X 4 GRAFTS (LIMA - LAD; RSVG- DISTAL LAD,MAJ OM AND RPDA)	DR. VIVEK V. PILLAI
250	384224	ANILKUMAR S.	54	M	07-Jan-2015	SEV AR,GDLV,SR,CKD,HTN ,NC	AVR # 23 CHVP	DR. VARGHESE T.PANICKER
251	383136	PRABHAKARAN R.	70	M	07-Jan-2015	CAD,TVD,SEV LVD,SR,DM,HTN,DLP, OLD MI	CABG X 5 GRAFTS (LIMA-LAD;RSVG-DISTAL LAD,MAJ OM,D1 AND RPDA)	DR. VIVEK V. PILLAI
252	359020	USHAKUMARI S.	48	F	08-Jan-2015	RHD,SEV CAL MS,MOD MR,MOD PAH,GDLV,AF	MVR # 27 CHVP + PARTIAL PMLP	DR. VIVEK V. PILLAI
253	290468	KOMALAM P K	56	F	08-Jan-2015	CAD, TVD, GDLV, SR, DM, HTN, DLP	CABG X 6 GRAFTS. LIMA TO LAD , RSVG TO DISTAL LAD , MAJOR OM, DIAGONAL 1 & DIAGONAL 2, RPDA	DR. VIVEK V. PILLAI
254	383500	ABBAS A.	51	M	09-Jan-2015	CAD, TVD, GDLV, SR, DM, HTN, DLP	CABG X 6 GRAFTS LIMA-LAD, RSVG MAJ DIAGONAL, RI, OM1, OM2 & RPDA.(RAMUS PIGGYBACKED TO DIAGONAL)	DR. JAYAKUMAR K
255	382286	NISHAD P V.	29	M	09-Jan-2015	ACHD PARTIAL AVCD(OPASD CLEFT AML) MOD MR NO PAH SR	PARTIAL STERNOTOMY TPP CLOSURE OF OP ASD AND AML CLEFT REPAIR	DR. VARGHESE T.PANICKER
256	386741	KATHIRU KUNJU M.	63	M	12-Jan-2015	CAD,SVD,GDLV,SR,HTN,DM,DLP,SP/PTCA TO RCA WITH ENTANGELD & STUCK	CABG X 1 GRAFT(RSVG-->RPDA DISTAL TO STENT)+ GUIDE WIRE RETRIVAL THROUGH	DR. VIVEK V. PILLAI

						CORONARY GUIDE WIRE	AORTOTOMY	
257	383873	MOHANAN V.	57	M	12-Jan-2015	CAD,TVD,GDLV,SR	CABG X 4 GRAFTS(LIMA-->LAD, RSVG-->MAJ DIAGONAL, MAJ. OM, RPDA)	DR. VIVEK V. PILLAI
258	383067	VARGHEESE P O.	60	M	13-Jan-2015	CAD, TVD, LMCA, GDLV,SR, BA, DLP	CABGX 5 GRAFTS(LIMA-->LAD, RSVG--> DIST LAD, MAJOR DIAGONAL, MAJOR OM, 1ST RPDA, DISTAL LAD PIGGY BACKED TO DIAGONAL)	DR. VIVEK V. PILLAI
259	380589	ASMABI A	34	F	14-Jan-2015	RHD SEV MS MILD MR SEV AS MOD AR SEV PAH SR PVOD	DVR : AVR #17 CHVP AND MVR #25 CHVP	DR. VARGHESE T.PANICKER
260	388404	ANILKUMAR .V.R.	51	M	14-Jan-2015	CAD TVD GDLV SR HTN DLP	CABG X 5 GRAFTS (LIMA-LAD;RSVG- MAJ DIAG,OM1,OM2 AND RPDA)	DR. JAYAKUMAR K
261	253997	SHEELA R.	37	F	15-Jan-2015	RHD SEVERE MS MOD MR MOD AS MOD AR FAIR LVF AF NC	DVR(AVR # 17 SJR & # 25 CHVP)	DR. VARGHESE T.PANICKER
262	383620	SARADHA G.	67	F	15-Jan-2015	CAD TVD GDLV TRIVIAL AS SR DM HTN DLP BA	CABG X 5 GRAFTS (LIMA-LAD,RSVG- DISTAL LAD,MAJ DIAGONAL,DISTAL OM AND RPDA)	DR. JAYAKUMAR K
263	371876	BALAN.K	64	M	16-Jan-2015	RHD SEV MS MOD MR CAD SVD SR	MVR # 25 CHVP (PREMOUNT) + CABG X 1 GRAFT (RSVG - LAD)	DR. VARGHESE T.PANICKER
264	990269 2	ABRAHAM MATHEW	56	M	16-Jan-2015	CAD, TVD, ACS-UA, NO PAH, GDLV, SR, HTN	CABG X 6 GRAFTS(LIMA-LAD;RSVG- D1, D2, MAJ OM,RPDA & RPLB)D1 PIGGYBACKED TO D2	DR. JAYAKUMAR K
265	387900	GOPINATHAN PILLAI V.K.	54	M	19-Jan-2015	CAD TVD GDLV SR DM	CABG X 4 GRAFTS (LIMA - LAD, RSVG - OM2, OM3, PDA)	DR. VIVEK V. PILLAI
266	387142	GIREESAN K.	50	M	19-Jan-2015	MVP, SEV MR, GOOD LV FUNCTION, AF, NC	MVR # 27 CHVP	DR. BINEESH K.R.
267	389119	BHASKARAN PILLAI P.	70	M	20-Jan-2015	CAD TVD GDLV SR DM HTN	CABG X 3 GRAFTS (LIMA - LAD, RSVG - DISTAL LAD,	DR. VIVEK V. PILLAI

							MAJOR OM, PDA)	
268	383773	HAKKIM B.	23	M	21-Jan-2015	RHD,SEV MR,MILD MS,DIL LV,GDLV,SR	MVR # 2 7 CHVP + PMLP	DR. VIVEK V. PILLAI
269	380211	SUDHA L	61	F	21-Jan-2015	CAD TVD GDLV SR HTN DM	CABG X 3 GRAFTS (LIMA - LAD, RSVG - OM1, MAJ DIAG)	DR. VIVEK V. PILLAI
270	387890	GANGADHARAN PILLAI G.	64	M	22-Jan-2015	CAD,TVD,MILD LVD,SR,DM,HTN,DLP	CABGX 5 GRAFTS(LIMA TO LAD,RSVG TO MAJ DIAGONAL,MAJ OM,RAMUS,DISTAL RCA)	DR. VIVEK V. PILLAI
271	391076	GEORGE E.	75	M	23-Jan-2015	CAD, TVD, LMCA,REC IWMI, S/P PTCA RCA, GDLV, MILD MR, SR	CABGX4 GRAFTS(RSVG TO LAD, RAMUS, DIAGONAL, P DA, DIAGONAL PIGGYBACKED TO RAMUS)	DR. VIVEK V. PILLAI
272	384445	ESSAKKIAMMAL K.	63	F	27-Jan-2015	CAD TVD ACS-UA SR GDLV DM HTN DLP HYPOTHYROIDISM	CABGX5 GRAFTS(LIMA-LAD,RSVG- DISTAL LAD,MAJ DIAG,MAJ OM,AMPDA)	DR. VIVEK V. PILLAI
273	383675	SASIDHARAN C.	56	M	28-Jan-2015	CAD TVD RECENT IWMI SR GDLV DM HTN,DLP	CABGX5GRAFTS(LIMA-LAD,RSVG-D1,D2,2ND BR TERM OM,DISTAL RCA)	DR. VIVEK V. PILLAI
274	388946	SAIFUDHEEN S.	56	M	29-Jan-2015	CAD,TVD,SP/PTCA TO RCA (2003), GDLV.SR, DLP	CABG X 6 GRAFTS(LIMA-->LAD, RSVG--> D1,D2,RI, RPDA,RPLB)	DR. VIVEK V. PILLAI
275	970726 5	ANGAMMAL.M.	53	F	30-Jan-2015	SEV MS, S/PBMV, MOD MR, SEV AS, MOD AR, MILD TR, MILD PAH , SEV LVD, MILD RVD,AF	DVR, AVR # 19 SJM, MVR # 27 CHVP	DR. VIVEK V. PILLAI
276	382910	ALEYKUTTY THANKACHAN.	62	F	02-Feb-2015	CAD,DVD,NSTEMI(23.7 .14), GDLV,SR,DM,HTN,DLP ,B/L VV	LIMA-->LAD, RSVG-->MAJ DIAGONAL, MAJ OM	DR. VIVEK V. PILLAI
277	382610	USHA S.	47	F	03-Feb-2015	CAD, LMCA, TVD, MOD MR, MOD - SEV PAH, SEV LVDM SR, DM, HTN.	CABG X 5 GRAFTS (LIMA - LAD, RSVG - MAJ DIAG, MAJ OM , RPDA, DISTAL LAD)	DR. VIVEK V. PILLAI
278	269288	MURUGA DAS.	31	M	04-Feb-2015	RHD, BAV,SEV AR,	AVR # 25 SJM	DR. VIVEK V. PILLAI

						FAIR LV, MILD MR, SR		
279	386857	ANANTHAKRISHNAN N.	50	M	04-Feb-2015	CAD,TVD,GDLV,SR,HT N	CABG X 4 GRAFTS(LIMA-->LAD, RSVG-->D2, MAJ OM,RPDA)	DR. VIVEK V. PILLAI
280	391588	THULASI R	54	F	05-Feb-2015	CAD, TVD, LMCA, RECENT MI, MILD LVD, SR, DM, HTN	CABG X 5 GRAFTS (LIMA - LAD, RSVG - MAJ DIAGONAL, MAJ OM, RPDA, DISTAL LAD)	DR. VIVEK V. PILLAI
281	253828	AIYAPPAN M.P.	66	M	06-Feb-2015	BAV SEV CAL AS HYPERTROPHIC LV, GOOD LV SR DM	AVR #21 PM MAGNA	DR. VIVEK V. PILLAI
282	388265	MURALEEDHARAN C.	46	M	06-Feb-2015	CAD TVD MOD LVD ANEURYSMAL LV APEX SR HTN DLP	CABG X 4 GRAFTS (LIMA - LAD, RSVG - OM, DIAGONAL, PDA) + LV PLICATION	DR. JAYAKUMAR K
283	382320	SAMUEL KUTTY E.	61	M	09-Feb-2015	CAD TVD OSASD MILD PAH GDLV SR	CABG X 3 GRAFTS(RSVG-> LAD, MAJ OM, AM)+ DIRECT CLOSURE OF OSASD	DR. VIVEK V. PILLAI
284	371124	SARADA KUMARI G	53	F	09-Feb-2015	TAV, SEV CAL AS, MOD AR, GDLV, SR, HYPOTHYROIDISM	AVR # 17 SJM (HP SERIES)	DR. BINEESH K.R.
285	384954	RAMAKRISHNAN S	65	M	10-Feb-2015	CAD TVD ACS NSTEMI GDLV SR DM HTN	CABGX 4 GRAFTS(LIMA TO LAD,RSVG TO TERM OM,MAJOR OM,RCA)	DR. VIVEK V. PILLAI
286	291524	SAJU J.	42	M	10-Feb-2015	RHD SEV CALCIFIC MS MILD MR MOD PAH SR NC	MVR#27CHVP+PARTIAL PMLP	DR. BINEESH K.R.
287	391123	NOOHU MOHAMMED K.	69	M	12-Feb-2015	CAD TVD ACS(11/14)MOD LVD MOD MR, PORCELAIN AORTA, DM HT DLP	BEATING HEART CABG ON PUMP X 4 GRAFT(LIMA-->LAD, RSVG--> MAJOR OM, PDA, PLB) ENDARTERECTOMY OF PDA & PLB	DR. JAYAKUMAR K
288	392203	NARAYANAN T.	38	M	13-Feb-2015	TYPE A AO DISSECTION,SEV AR, MILD PE,MILD HF,SR,GDLV	MODIFIED BENTALLS PROCEDURE(AVR 25#CHVP+26 #ALBO GRAFT)	DR. JAYAKUMAR K
289	392142	SUSEELA C.	55	F	13-Feb-2015	CAD,ACS/NSTEMI(3.2.14),LMCA,DVD,GDLV,S	CABGX 4 GRAFTS(LIMA TO LAD,RSVG TO MAJ	DR. VIVEK V. PILLAI

						R,HTN	OM,DIAGONAL,RPDA)	
290	392268	SUBBULAKSHMI P.	42	F	14-Feb-2015	LA MYXOMA, MV OBSTRUCTION, SEV PAH, RV DYSFUNCTION,GDLV, SR	MYXOMA EXCISION WITH TPP CLOSURE	DR. VIVEK V. PILLAI
291	385442	GOPALAKRISHNAN ACHARY D.	63	M	16-Feb-2015	CAD,TVD,NSTEMI(JULY 2014),LMCA,GDLV,SR, HTN	CABGX 7 GRAFTS(LIMA-- .LAD, RSVG-- . DIST LAD, MAJ DIAGONAL, MAJ OM, TERM OM, RPDA, RPLB)	DR. JAYAKUMAR K
292	386507	ABDUL RASHEED A.K.	36	M	18-Feb-2015	MVP OF AML & PML,SEV MR,DILATED LV, GDLV,SR	MV REPAIR (TRIANGULAR RESECTION OF P2 & FREE EDGE PPLICATION OF P3)+ RING ANNULOPLASTY # 31 TAYLOR RING	DR. VARGHESE T.PANICKER
293	240469	ARUL RAJ.M.	22	M	18-Feb-2015	S/PBMV, ,SEV RE MS, SEV AS,MOD AR,MOD MR,MOD TR,MOD PAH,GDLV,SR	DVT(MVR # 23 CHVP, AVR # 19 CHVP) TV REPAIR(RELEASE OF PM FROM ANTERIOR SEPTAE)	DR. VARGHESE T.PANICKER
294	383416	MURUGAN N.	58	M	19-Feb-2015	CAD,DVD,FLAIL AML,SEV MR, MILD-MODLVD,SR	MVR#29CHVP+CABGX 2 GRAFTS(RSVG TO TERM OM,RPDA)	DR. VARGHESE T.PANICKER
295	354796	HAMZA K.S	36	M	19-Feb-2015	ACHD,OSASD,MILD PAH,GDLV,SR,	TPP CLOSURE OF OSASD	DR. VIJAY THOMAS CHERIAN
296	381608	SUKHADEV K C	50	M	20-Feb-2015	MVP(P2 SEG)SEV MR,MOD PAH,GDLV,SR	MV REPAIR WITH TRIANGULAR RESECTION OF P2 SEGMENT WIRH 31# TAILOR RING ANNULOPLASTY	DR. VARGHESE T.PANICKER
297	330644	CHANDRAN H	49	M	23-Feb-2015	CAD UA(2007)TVD S/P PTCA(OM) GDLV SR DM HTN DLP LFFT VV		DR. VIVEK V. PILLAI
298	371553	AMMUKUTTY K	66	F	23-Feb-2015	ACHD, SVASD, SR, DM, HTN, DLP, NC	DOUBLE PATCH CLOSURE OF ASD	DR. BINEESH K.R.
299	385994	PUSHPA N.	61	F	24-Feb-2015	CAD TVD GDLV SR DM HTN DLP HYPOTHYROID OSA	CABG X 6 GRAFTS (LIMA-LAD,RSVG- PROXIMAL LAD,D1,OM2,OM3 & RPDA)	DR. JAYAKUMAR K
300	384312	JOHNY G.	41	M	25-Feb-2015	CAD TVD MOD LVD,	CABG X 5 GRAFTS (LIMA -	DR. JAYAKUMAR K

						SR DM HTN	LAD, RSVG - D1, OM, DISTAL LAD AND RPDA)	
301	391429	RAGHAVAN K.	73	M	26-Feb-2015	CAD TVD RECENT UA GDLV SR DM HT DLP	CABGX 5 GR(LIMA-LAD,RSVG-DIAGONAL,OM,OM2,LPDA)	DR. JAYAKUMAR K
302	392590	RAMACHANDRAN N K.	61	M	26-Feb-2015	CAD IWMI VSR MOD TR MOD PAH SR CAUDA EQUINA	CABGX4GR(RSVG-LAD,D1,MAJ OM,DISTAL RCA)+VSR REPAIR WITH PRECLOTTED TEFLON PATCH+LV PLICATION	DR. JAYAKUMAR K
303	386319	SANTHA M.	60	F	27-Feb-2015	SEV AS,CALCIFIC AV,MILD AR,CAD,TVD,GDLV,SR ,DLP	CABG X 3 GRAFTS(RSVG->LAD,MAJ OM, RPDA), AVR #19 PM	DR. VARGHESE T.PANICKER
304	385748	ASHOKAN K.B.	45	M	02-Mar-2015	CAD,TVD,REC MI,MOD LVD,SR,DLP	CABG X 5 GRAFTS(LIMA-LAD, RSVG-MAJ D,MAJ OM,RPDA & AM)	DR. JAYAKUMAR K
305	250403	RAMACHANDRAN M.	20	M	02-Mar-2015	RHD,SEV AR,MILD MR,MILD LVD,MILD PAH,SR	AVR #21 SJR	DR. BINEESH K.R.
306	385012	VALARMATHI N.	34	F	03-Mar-2015	OSASD, SEV PAH, MILD MR,GDLV,SR	TPP CLOSURE OF ASD CLOSURE	DR. BINEESH K.R.
307	391602	PRAKASH CHANDRA NAIR	56	M	03-Mar-2015	CAD,TVD, GDLV, SR, RECENT MI, HTN, DLP	CABG X 7 GRAFTS(LIMA-LAD,RSVG- DISTAL LAD,D1,D2,MAJ OM,RPDA AND DISTAL RPDA: DISTAL LAD PIGGYBACKED TO D2)	DR. JAYAKUMAR K
308	9803099	SUDHAKARAN.C.	61	M	04-Mar-2015	MVP,FLAIL PML,SEV MR,MOD PAH,GDLV,SR,HTN	MVR # 29 PM	DR. VIVEK V. PILLAI
309	390652	SABU K NORBERT	49	M	06-Mar-2015	CAD,UA,DVD,GDLV,SR ,DLP	CABGX 3 GRAFTS(LIMA-LAD,RSVG-DISTAL LAD,DISTAL RCA,DISTAL LAD PIGGY BACKED TO RCA)	DR. JAYAKUMAR K
310	386332	SUSHEELAMMA L.	74	F	06-Mar-2015	CAD,P/PCI TO LAD,TVD,GDLV,SR,DM	CABGX3GRAFTS(LIMA-LAD,RSVG-D1,RPDA)	DR. JAYAKUMAR K
311	389881	SUSHILA DEVI S.	65	F	09-Mar-2015	CAD,TVD,GDLV,SR,DM ,HTN,DLP,CA CX	CABG X 4 GRAFTS (LIMA-LAD; RSVG- D1, PLB & RPDA)	DR. JAYAKUMAR K

312	385430	SAINABA AZEEZ	35	F	09-Mar-2015	ACHD, SV ASD, PAPVC OF RUPV TO SVC/RA JUNCTION, GDLV,SR	ASD CLOSURE AND PAPVC REROUTING WITH TPP USING DOBULE PATCH TECHNIQUE	DR. BINEESH K.R.
313	386569	SUDHARMAN K.	63	M	10-Mar-2015	CAD,LMCA+TVD,GD LV,SR,HTN,DLP	CABG X 4 GRAFTS (LIMA- LAD' RSVG- D1, MAJ OM & RPDA)	
314	390514	LEKSHMI L.	61	F	11-Mar-2015	CAD, LMCA+TVD,MILD MR.SEV LVD,REC ACS:NSTEMI, SR,DM,DLP,HTN	CABG X 5 GRAFTS (LIMA- LAD: RSVG-D1, MAJ OM, PRE CRUX RCA & RPDA WITH RCA ENDARTERECTOMY)	DR. JAYAKUMAR K
315	385638	VINCENT NICHOLAS	75	M	12-Mar-2015	CAD,TVD,REC ACS, GD LV,SR, DM, OLD CVA WITH BASILAR ARTERY STENOSIS	CABG X 3 GRAFTS (LIMA- LAD; RSVG- OM1 & RPDA)	DR. JAYAKUMAR K
316	382462	MAHESH V.	21	M	12-Mar-2015	ACHD, OS ASD, NO PAH, GD VENT FN, SR, GILBERT SYNDROME	DIRECT CLOSURE OF OSASD	DR. BINEESH K.R.
317	389373	SIVAPRASAD K.	57	M	13-Mar-2015	CAD,TVD,REC MI, MOD LVD, SR,DM	CABG X 5 GRAFTS(LIMA- LAD, RSVG- MAJ D, OM1, OM2 AND RPDA)	DR. JAYAKUMAR K
318	382889	OMANAYAMMA K.	62	F	16-Mar-2015	RHD, SEV CALC AS, MILD AR, MILD MS/MR, ATRIAL BIGEMINI,GD LV	AVR#21 PM	DR. VARGHESE T.PANICKER
319	390868	ABDUL KAREEM A.	59	M	16-Mar-2015	CAD,TVD,LMCA, GDLV, SR,DM,	CABGX5 GRAFTS(LIMA- LAD,RSVG-DISTAL LAD,MAJ OM,MAJ DIAGONAL,PRE CRUX RCA)	DR. VIVEK V. PILLAI
320	388168	THRESSIYA J	67	F	17-Mar-2015	RHD, CALCIFIC MV, SEV MS, MILD-MOD MR, MIOD PAH, AF	MVR # 27 CHVP+PMLP	DR. BINEESH K.R.
321	386781	THANKAPPAN G.	65	M	17-Mar-2015	CAD,TVD, GDLV, SR, STABLE ANGINA, HCV POSITIVE	CABGX 4 GRAFTS (RSVG- LAD,TERM OM,INFERIOR BR OF DIAGONAL,RPDA)	DR. VIVEK V. PILLAI
322	386940	SUKUMARAN K P.	60	M	18-Mar-2015	CAD, TVD, LMCA,GDLV,SR,HTN	CABGX 5 GR(LIMA- LAD,RSVG-DISTAL LAD,UPPER BRANCH OF DIAGONAL,MAJ	DR. VIVEK V. PILLAI

							OM,DISTAL RCA)	
323	390631	RUFIE JOSEPH	75	F	18-Mar-2015	SEV. CAL. MS, MOD. PAH, GDLV, AF,BA	MVR#25 PM+PARTIAL PMLP	DR. VARGHESE T.PANICKER
324	387264	BALASUBRAMANIYA N K.	32	M	18-Mar-2015	BAV, SEVERE AR, DILATED LV, NO PAH, MOD LVD, SR	AVR # 29 SJR	DR. BINEESH K.R.
325	379200	ABBAS M	62	M	19-Mar-2015	MVP, SEV MR, SEV PAH, ASD, CAD, DVD	MVR#27PM+PARTIAL PMLP+CABGX2 GR(RSVG-LAD,MAJ OM)	DR. VIVEK V. PILLAI
326	392823	VIJAYAN A.A.	42	M	20-Mar-2015	CAD,TVD,REC AWMI, FAIR LV, SR	CABGX 3 GRAFTS(LIMA-LAD,RSVG-MAJ OM,RPDA)	DR. VIVEK V. PILLAI
327	382552	SARALA DEVI D.	11	F	20-Mar-2015	ACHD, LARGE OS ASD,RHD,SEV MR , SEV PAH, GD LV, SR	MV REPAIR (NEOCHORDAL REPLACEMENT OF A2+#27 DURAN ANCOR ANNULOPLASTY RING) +TPP CLOSURE OF OS ASD	DR. VARGHESE T.PANICKER
328	391587	HARIKUMAR K.	54	M	23-Mar-2015	CAD, OLD MI, S/P PTCA, GDLV, SR, DM, HTN, DLP,PERIARTHRTIS LRFT SG	CABG X 5 GRAFTS(LIMA-LAD;RSVG-MAJ D ,RI,MAJ OM & RPDA)	DR. JAYAKUMAR K
329	385449	BAHULEYAN D.	64	M	23-Mar-2015	CAD,TVD,MILD LVD,SR,HTN,B/L LL PVOD	CABG X 5 GRAFTS (LIMA-LAD;RSVG-D1,D2,MAJ OM & RPDA)	DR. JAYAKUMAR K
330	920620 2	ANILKUMAR.R.	41	M	24-Mar-2015	RHD, S/P CMV, SEV CALC RE- MS, MOD MR,MOD PAH, AF,NC	MVR#25CHVP+PARTIAL PMLP	DR. BINEESH K.R.
331	389481	NAGASWAMY A.	61	M	25-Mar-2015	CAD, DVD, BAV, DILATED ROOT OF AO, MOD AS, SEV AR, MOD MR,SR	CABGX 2 GRAFTS(RSVG-LAD,AM)+MODIFIED BENTALL(AVR#27CHVP+2 8#ALBOGRAFT)	DR. JAYAKUMAR K
332	371677	SHYMON P.A	27	M	26-Mar-2015	S/P BENTALL, IE, AV DEHISCENCE FROM AO GRAFT, MARFAN, SR	REDO BENTALL PROCEDURE AND EXCISION OF PSEUDOANEURYSM(AVR #27CHVP+ALBOGRAFT	DR. JAYAKUMAR K

							#28	
333	388642	SUSEELAN P.	67	M	26-Mar-2015	CAD, TVD,LMCA,GD LV, SR,FH+,EXSMOKER	CABGX 5 GRAFTS(LIMA-LAD,RSVG-MAJ OM,D1,RAMUS,RPDA)	DR. VIVEK V. PILLAI
334	391841	PURUSHOTHAMAN NAIR N.	61	M	27-Mar-2015	CAD,TVD,LMCA,GDLV, SR,HTN	CABGX6 GRAFTS(LIMA-LAD,RSVG-DIAGONAL,MAJ OM,RAMUS,RPDA,RPLB)	DR. JAYAKUMAR K
335	389808	SUBASH T P.	59	M	31-Mar-2015	CAD, TVD, GD LV, SR,DM,HTN	CABG X 5 GRAFTS(LIMA-LAD,RSVG-D3,MAJ OM BOTH BRANCHES,RPDA)	DR. JAYAKUMAR K
336	347986	AJEENA J.	3	F	01-Apr-2015	ACHD SA-VSD, SEV PS, SR, NC	VSD CLOSURE (GORTEX PATCH) WITH PULMONARY VALVOTOMY	DR. BAIJU S.DHARAN
337	393694	B/O RAJEENA	0	F	02-Apr-2015	POST SUBCLAVIAN COA SEV PAH EBSTEINS ANAMOLY MOD TR SMALL ASD GD VENTRICULAR FUNCTION SR	COA REPAIR(RESECTION AND EXTENDED END-END ANASTOMOSIS)	DR. BAIJU S.DHARAN
338	346991	MERFIN J B	11	F	07-Apr-2015	ACHD SAVSD SEV PS SR NC	ICR (TRANS RA VSD CLOSURE WITH INFUNDIBULAR RESECTION)	DR. SABARINATH MENON
339	374422	NILA RENJITH	2	F	08-Apr-2015	SVASD WITH RUPV OF APICAL UPPER AND MIDDLE PVS TO SVC/RA JN. ,MILD PAH,SR,NC	WARDENS PROCEDURE	DR. BAIJU S.DHARAN
340	389884	SNEHA M.P.	0	F	09-Apr-2015	CAVD RASTELLI TY A, ADDLN OSASD, MILD AAVR(R>L), SEV HYPERKINETIC PAH SR DOWNS SYND	AVCD REPAIR DOUBLE PATCH REPAIR(FENESTRATED ASD PATCH)	DR. SABARINATH MENON
341	382454	PRARTHANA ANN RAJESH	0	F	10-Apr-2015	MITRAL ATRESIA, LARGE MUSCULAR VSD, REST ASD S/P PAB S/P BAS	REDO STERNOTOMY, BDG, MPA INTERRUPTION, ATRIAL SEPTECTOMY	DR. BAIJU S.DHARAN
342	380113	MOHAMMED NAFI	1	M	13-Apr-2015	UNOBSTRUCTED SC	TAPVC REPAIR+	DR. SABARINATH MENON

						TAPVC WITH PAPVC OF RUPV - SVC/RA JN, ASD, MOD PAH, GD VENY FN, SR	WARDENS PROCEDURE	
343	362388	NELOFER NISA	7	F	13-Apr-2015	OSASD, PDA, NO PAH, GD VENT FN, SR	TPP CLOSURE OF OSASD	DR. VIJAY THOMAS CHERIAN
344	214490	ASNA K.N.	13	F	16-Apr-2015	DTGA, VSD, PS , S/P BAS, BDG, ATRIAL SEPTECTOMY S/P TPCP	REDO STERNOTOMY, LPA PLASTY, TV REPAIR	DR. SABARINATH MENON
345	374670	AKSHANTH M S	3	M	17-Apr-2015	ACHD, SAVSD, NO PAH, GOOD BIVENTRICULAR FUNCTION, SR, H/O IE ++	VSD CLOSURE WITH TPP PATCH	DR. SABARINATH MENON
346	339238	SNEHA B.S.	9	M	17-Apr-2015	CCHD, TOF, INF PS, CONF PA, SR, NC	ICR (RVOT PATCH) + PFO KEPT OPEN	DR. SABARINATH MENON
347	262294	ALBIN JOHNY	14	M	23-Apr-2015	SHONE COMPLEX(INCOMPLETE), SUPRAMITRAL MEMBRANE, SEV PAH, P/BALLON DILTN COA, P/COA REPAIR, GDLV, SR	SUPRAMITRAL MEMBRANE EXCISION	DR. BAIJU S.DHARAN
348	393708	THANSIKA R.	0	F	24-Apr-2015	DORV SPVSD WITH INFLOW EXTENSION ASD PDA SEV PAH GDLV SR	ASO+VSD CLOSURE(GP)+ PFO OPEN	DR. BAIJU S.DHARAN
349	395538	B/O NASEERA	0	M	27-Apr-2015	POSTSCA COA WITH DISTAL ARCH HYPOPLASIA, SUPRAMITRAL MEMBRANE, MILD MS, BAV, SMALL VSD, SEV PAH, SR	RESECTION AND EXTENDED E-E ANASTAMOSIS WITH REVERSE SUBCLAVIAN FLAP BY LAFT POSTEROLATERAL THORACOTOMY	DR. BAIJU S.DHARAN
350	8900099	NEETHU.P.Y	26	F	27-Apr-2015	ACHD DORV SAVSD MULTIPLE VSD SEVERE INF PS PDA SR NC	ICR (RVOT PATCH) + PDA INTERRUPTION + PFO MADE RESTRICTIVE	DR. SABARINATH MENON
351	386611	FIDA FATHIMA K.	0	F	28-Apr-2015	ACHD, LARGE INFLOW VSD WITH SA	VSD CLOSURE(TPP)+ ASD CLOSURE(DC)+ PDA	DR. THOMAS MATHEW

						EXTENSION, STRADDLING TV, PDA, ASD, SEV PAH, SR	INTERRUPTION	
352	395411	YAHYA SWALIH T.P.	0	M	29-Apr-2015	CCHD OBST SC TAPVC(PVS-CC-VV- INNOMINATE V) ASD SEV PAH CCF SR	TAPVC REPAIR	DR. SABARINATH MENON
353	394443	UMAIR	0	M	30-Apr-2015	OBS MIX TAPVC(RT PVS AND LEFT LPV- CC-CS AND LUPV TO INNOMINATE V) GDBV FN SR	TAPVC REPAIR (RACHS 2)(CS CUTBACK WITH PLASTY AT CC-CS JN AND LUPV-LAA ANASTAMOSIS)	DR. BAIJU S.DHARAN
354	369327	SHREYA.A.	1	F	30-Apr-2015	TOF CONFL PA GD BV SR NC CYANOTIC SPELLS	ICR+TAP+MONOCUSP RECONSTRUCTION OF RVOT+PFO OPEN	DR. SABARINATH MENON
355	386334	PRITHIKA R.	1	F	05-May-2015	ACHD, LARGE PM VSD WITH SA EXTENSION, HYPERKINETIC PAH, SR,NC	GP CLOSURE OF VSD	DR. BAIJU S.DHARAN
356	910746 0	RAJESWARI M	24	F	06-May-2015	ACHD,DC VSD, SEV PAH, MOD MR,SR	VSD CLOSURE WITH GORTEX PATCH & MV ANNULOPLASTY	DR. THOMAS MATHEW
357	318090	AYANA P	4	F	07-May-2015	TOF, GD CONFLUENT PA, PAPVC OF LUPV- INNOMINATE V, GOOD BV FUNCTION, SR,NC	ICR+TAP+MONOCUSP RECONSTRUCTION OF RVOT+LUPV-LAA ANASTAMOSIS	DR. SABARINATH MENON
358	361936	NADVA AFRIN .B	3	F	08-May-2015	TOF, CONF PA, LPA STENOSIS, GD BIVENTRICULAR FUNCTION, SR, SMALL VESSEL CROSSING RVOT	TRANS RA-PA ICR+PULMONARY VALVOTOMY+LPA PLASTY&MPA AUGMENTATION+PFO OPEN	DR. SABARINATH MENON
359	390136	B/O SIMI	0	M	11-May-2015	PA,IVS,PDA DEP PULM CIRC.S/P PDA STENTING,BIPARTITE RV,NC,SR	ICR WITH TRANS ANNULAR PATCH+MONOCUSP RECONSTRUCTION OF RVOT,PDA INTERRUPTION WITH	DR. THOMAS MATHEW

							STENT RETRIEVAL,TV REPAIR+BDG+PFO MADE RESTRICTIVE	
360	214490	ASNA K.N.	13	F	12-May-2015	S/P TCPC, REDO, LPA PLASTY, FENESTRATED FONTAN, LIVER INJURY WITH LOCALISED COLLECTION	RT THORACOTOMY WITH SUTURING OF LIVER LACERATION AND EVACUATION OF CLOTS	DR. SABARINATH MENON
361	324240	SREYA S. SHAJI	4	F	12-May-2015	PDA,SEV HYPERKINETIC PAH, S/P PDA DC,DEVICE EMBOLISATION(LPA OCCLUSION BY PDA DEVICE)GDLV,SR	PDA INTERRUPTION AND DEVICE RETRIEVAL FROM LPA AND LPAPLASTY	DR. BAIJU S.DHARAN
362	386696	NIDHIN DANIEL S.B.	3	M	14-May-2015	SVASD,PAPVC OF RUPV TO SVC,NO PAH,GD VENT FN,SR	WARDENS PROCEDURE	DR. SABARINATH MENON
363	396523	SHIRANJEEVI S.	0	M	15-May-2015	CCHD,PA,IVS,PDA DEPENDENT PULMONARY CIRCULATION,HYPOP LASTIC RV,TV,B/V RHABDOMYOMA	BDG	DR. SABARINATH MENON
364	393494	B/O DIVYA	0	F	18-May-2015	CCHD, DORV, LARGE SP VSD, SEV PAH, PFO, 1LCX2R, B/L SVC, SR	ASO+VSD CLOSURE	DR. BAIJU S.DHARAN
365	384643	KIRAN S NAIR	3	M	19-May-2015	ACHD, SVASD, RUPV & RMPV TO SVC - RA JUNCTION ,NO PAH, SR	WARDENS PROCEDURE	DR. THOMAS MATHEW
366	375903	AARUSH BOSE	1	M	19-May-2015	CCHD, PA, INTACT IVS, PDA DEPENDENT PULM CIRCULATION, S/P PDA STENT,	BDGS+ATRIAL SEPTECTOMY+ MAPCA INTERRUPTION	DR. THOMAS MATHEW

						RESTRICTIVE ASD, MAPCA, HYPOPLSTIV TV & RV,, SR , NC		
367	339069	ANANYA R V	4	F	20-May-2015	ACHD, SA VSD, MILD AR, MILD PAH, GD LV, SR, NC	GP CLOSURE OF VSD	DR. BAIJU S.DHARAN
368	361982	B/O ASIYA	2	M	21-May-2015	DILV,SV(LV),MILD TR,GD SV FN,SEV PS,SR	BDGS+PA BANDING	DR. SABARINATH MENON
369	309351	SOORAJ G.	18	M	22-May-2015	SS,MC,CCTGA,SPVSD(REMOTE), MOD VALVULAR PS,GD CONFL PA, HYPOPLSTIC MV,SR,NC	BDGS	DR. BAIJU S.DHARAN
370	395995	MUHAMMED SIYAN P.	0	M	25-May-2015	ALCAPA,DILATED CM,SEV LVD,MOD MR,SR	LCA TRANSLOCATION + MV ANNULOPLASTY	DR. BAIJU S.DHARAN
371	396659	ANDRIA JACOB	3	F	26-May-2015	UNROOFED CORONARY SINUS, CS TYPE ASD, B/L SVC (RAGHIB'S SYNDROME), ADDITIONAL OSASD, GD VENTRICULAR FUNCTION, SR	BPP CLOSURE OF ASD, DC OF OSASD, L SVC- RAA ANASTOMOSIS(MINISTER NOTOMY)	DR. THOMAS MATHEW
372	385725	DHARSIKA C.	0	F	27-May-2015	ACHD, PERIMEMBRANOUS VSD WITH SUBAORTIC EXTENSION , HYPERKINETIC PAH, B/L SVC, SR,NC	VSD CLOSURE WITH GORTEX PATCH	DR. BAIJU S.DHARAN
373	378392	SHIFANA M S	1	F	28-May-2015	SA VSD, MILD INFUNDIBULAR HYPERTROPHY, NON OBSTRUCTIVE SAM, SEV PAH, SR	TRANS RA ICR WITH SAM EXCISION	DR. THOMAS MATHEW
374	379819	ARAYMAN MISRA	1	M	29-May-2015	TOF, INF + VALVAR PS, GD CONFLUENT PAS, GD VENT FN, SR,	ICR=TAP=MONOCUSP RECONSTRUCTION OF RVOT	DR. BAIJU S.DHARAN

						NC.		
375	376371	ISMAIL M	15	M	01-Jun-2015	ACHD,OSASD,NO PAH,GDLV,SR	TPP CLOSURE OF OSASD	DR. BINEESH K. R.
376	390807	KUMARI SHEELA C.	50	F	01-Jun-2015	TAKYASUS ARTERITIS,CAD,DVD,SEVRE AR,LT SCACTO,B/L CAROTID STENOSIS,PORCEALIN AORTA	AVR # 21 CHVP	DR. VIVEK V. PILLAI
377	384978	UMMER P.	43	M	03-Jun-2015	SEV CAL AS/MOD AR/TRIVIAL MR/GDLV/NC/SR	AVR #19 ONX	DR. VIVEK V. PILLAI
378	389877	ANEESH RAMANAN	32	M	03-Jun-2015	CAD/DVD/AWMI/MILD LVD/SR	CAG X 3 GRAFTS (LIMA-LAD , RSVG - DIAG 1 /OM)	DR. VIVEK V. PILLAI
379	222782	SABU.B.	37	M	04-Jun-2015	RHD,S/P BMV , SEVRE MS , SEV AS , MOD-SEV AR , MILD PAH , GDLV , SR	DVR (MVR # 25 CHVP + PARTIAL PMLP , AVR # 19 CHVP)	DR. VIVEK V. PILLAI
380	386598	SAINUDEEN KUNJUA.	72	M	04-Jun-2015	CAD,LMCA,TVD,GDLV,SR,BPH	CABG X 4 GRAFTS (LIMA - LAD , RSVG - DIAG 1 , OM , RPLB)	DR. VIVEK V. PILLAI
381	387836	SALEEK P.	22	M	05-Jun-2015	ACHD,OSASD,MID PAH,GDLV,SR	TPP CLOSURE OF ASD	DR. BINEESH K. R.
382	338997	AJAYAKUMAR D	55	M	05-Jun-2015	CAD,TVD,MVP OF PML,SEV MR, PREVIOUS IE(2014),GDLV,SR,DM, DLP	CABG X 3 GRAFTS(LIMA-->LAD, RSVG--> D1, MAJOR OM) MV ANNULOPLASTY WITH TRIANGULAR RESECTION OF PML + # 28 SADDLE RING	DR. VIVEK V. PILLAI
383	324814	SUJATHA V.U.	36	F	08-Jun-2015	RHD,P/CMV,RE SEVMS,MILD MR,MOD AR,MILD TR,SEV PAH,GDLV,BA	DVR (MVR # 25 CHVP +PMLP , AVR # 19 CHVP)	DR. VARGHESE T.PANICKER
384	386064	MOHANAN N V.	61	M	08-Jun-2015	CAD,DVD,P/PCI-LAD,MOD LVD,MOD MR,MILD PAH,SR,DM,HTN,DLP	CABG X 4 GRAFTS (LIMA - LAD , RSVG -D1 ,D2 ,MAJ OM)	DR. JAYAKUMAR K
385	387896	MOOSA K.	70	M	09-Jun-2015	CAD TVD GOOD LV MILD MR CONC LVH	CABG X 5 GRAFTS (LIMA - LAD, RSVG - D1, OM1,	DR. JAYAKUMAR K

						SR DM	PDA, PLB)	
386	395845	HARIDAS P.	61	M	10-Jun-2015	BAV, CAL AO VALVE,SEV AS,MOD AR,MILLVD,SR,NC	AVR # 23 PM	DR. BINEESH K. R.
387	363984	RAVEENDRAN V K	58	M	10-Jun-2015	CAD, TVD, MOD LVD, SR, DM, HTN, DLP.	CABG X 4 GRAFTS(LIMA-LAD, RSVG - D1, RAMUS, PDA)	DR. JAYAKUMAR K
388	393067	MADHUSOODHANAN NAIR B.	59	M	11-Jun-2015	CAD,TVD,GDLV,SR,DM ,HTN,DLP	CABG X 5 GRAFTS (LIMA-LAD / RSVG- D1 ,D2,OM1,OM2)	DR. JAYAKUMAR K
389	9208624	VENUKUMARAN.P.K.	66	M	11-Jun-2015	RHD,P/BMV,RE SEV MS,MOD MR,MOD PAH,GDLV,MILD RV DYSFUNCTION,AF,MILD CAD,SEIZURE DISORDER	MVR # 25 PM + PMLP	DR. VARGHESE T.PANICKER
390	397366	CHANDRA BOSE P.	50	M	12-Jun-2015	CAD TVD LMCA, GDLV, SEV MR, SR, REC AMI	CABG X 5 GRAFTS (LIMA - LAD, RSVG - D1, RI, RPDA, RPLB) + MVR # 25 CHVP	DR. JAYAKUMAR K
391	389953	GIREESH K.K.	30	M	15-Jun-2015	RHD, SEV MS, MOD MR, MOD PAH, FAIR LV, LAE CLOT, AF, NC	MVR# 27 CHVP + LAE CLOT EXTRACTION + LAE EXCLUSION	DR. BINEESH K. R.
392	396967	SATHISH BABU S.	58	M	15-Jun-2015	CAD TVD FAIR LV, REC MI, SR,	CABG X 4 GRAFTS (LIMA - LAD, RSVG - D1, OM1, RCA AT CRUX)	DR. JAYAKUMAR K
393	389678	MADHUKUMAR B.	54	M	16-Jun-2015	CAD TVD, REC MI, GDLV, MOD AR, SR, HTN	CABG X 4 GRAFTS (LIMA - LAD, RSVG - BOTH BRANCHES OF OM1, AMPDA)	DR. JAYAKUMAR K
394	386646	THANGAMANI M.	69	F	17-Jun-2015	BAV SEV CAL AS, MOD AR, GDLV, SR, HTN	AVR # 19 PM	DR. BINEESH K. R.
395	387628	REGHU J.	59	M	18-Jun-2015	CAD TVD SEV LVD TRIVIAL MR SR HTN DLP LT CVA	CABG X 3 GRAFTS (LIMA-LAD,RSVG-OM1 (MEDIAL BR) , TERM OM)	DR. VARGHESE T.PANICKER
396	8701813	CELINA.U	44	F	19-Jun-2015	RHD,P/CMV,P/DVR,SE V TR,MOD TS,GDLV,CONTROLLED CHF,AF,NC	TV ANNULOPLASTY WITH # 31 TAYLOR RING	DR. VARGHESE T.PANICKER

397	317634	SUDHARSANAN G	56	M	22-Jun-2015	SEV CAL AS MILD AR GDLV SR NC ? COPD	AVR# 23 CHVP	DR. BINEESH K. R.
398	396335	HASSAN RAWTHAR	73	M	23-Jun-2015	CAD,LMCA,TVD,NSTE MI,GDLV,MILD MR, SR,HTN	CABGX 4 GRAFTS(LIMA-- >LAD, RSVG-->MAJ OM,ACUTE MARGINAL, EARLY RPDA)	DR. JAYAKUMAR K
399	389700	GOPINATHAN NAIR M.	66	M	24-Jun-2015	CAD,LMCA,TVD,MOD LVD,SR,DM,HTN,DLP	CABG X 5 GRAFTS (LIMA- LAD , RSVG - DISTAL MAJOR DIAGONAL , OM1 , TERMINAL OM , RCA) + CRT LEAD IMPLANTATION	DR. JAYAKUMAR K
400	391472	ASOKAN V.	53	M	25-Jun-2015	CAD TVD LMCA GDLV SR DM HTN DLP	CABG X 6 GRAFTS (LIMA - PROX LAD, RSVG - DISTAL LAD, MAJ D, UPPERBRANCH OF RAMUS, MAJ OM, ACUTE MARGINAL)	DR. VIVEK V. PILLAI
401	920765 7	SABU.V.P.	46	M	26-Jun-2015	RHD P/CMV(94) SEV MS MOD AR TRIV AS MOD PAH GDLV SR NC	MVR # 31 CHVP + PMLP	DR. VIVEK V. PILLAI
402	384809	GOPINATHAN NAIR G.	68	M	29-Jun-2015	SEV CAL AS MOD AR MILD MR GDLV SR NC BPH SEIZURE DISORDER	AVR # 23 PERIMOUNT	DR. BINEESH K. R.
403	397084	SANKARAN NAIR L.	60	M	29-Jun-2015	SEV CAL AS CONC LVH NO PAH GDLV SR MILD CAD DLP HTN	AVR # 21 PERIMOUNT MAGNA	DR. VIVEK V. PILLAI
404	387252	PARAMASIVAN S.	43	M	30-Jun-2015	MVP OF PML P2 SEGMENT SEV MR NO PAH GD LV SR NC	MV REPAIR P2 SEGMENT TRIANGULAR RESECTION WITH MVA # 31 DURAN ANCORE RING	DR. VARGHESE T.PANICKER
405	391810	SAVITHRY M.K.	61	F	30-Jun-2015	CAD TVD GDLV SR DM HTN TIA	CABG X 3 GRAFTS (LIMA- LAD , RSVG - D1 , MAJ OM)	DR. VIVEK V. PILLAI
406	390062	CHELLI T P.	55	M	01-Jul-2015	CAD TVD P/PCI LAD MILD LVD SR COPD DLP HTN	CABG X 4 GRAFTS (LIMA- D1;RSVG-LAD, MAJ OM AND RPDA)MAJ OM PIGGYBACKED TO LAD	DR. VIVEK V. PILLAI
407	391674	SAINUDHEEN P.P.	50	M	01-Jul-2015	CAD TVD FAIR LV SR HTN	CABG X 5 GRAFTS (LIMA- LAD; RSVG- DISTAL LAD,	DR. VIVEK V. PILLAI

							MAJ D, RPDA & RPLB)RPLB PIGGYBACKED TO RPDA	
408	390088	ASMA BEEVI	62	F	02-Jul-2015	CAD TVD GDLV SR DM HTN	CABG X 4 GRAFTS (LIMA- LAD; RSVG - D1, MAJ OM AND RPDA)	DR. VIVEK V. PILLAI
409	391170	KANNAN K.	41	M	03-Jul-2015	CAD, TVD, FAIR LV, SR, DM, DLP	CABG X 5 GRAFTS (LIMA - LAD, RSVG - MAJ D, MAJ OM, RPDA, RPLB)	DR. VIVEK V. PILLAI
410	394825	VISHNU V J	17	M	03-Jul-2015	ACHD OSASD NO PAH GDLV	DC OF OSASD	DR. VIJAY THOMAS CHERIAN
411	390973	SUNDARESAN K P.	66	M	06-Jul-2015	CAD,TVD,GD LV,SEV CAL AS, MILD AR, MR, CONC LVH,DM, HTN,DLP	CABG X 3 GRAFTS(RSVG- LAD,RI,PDA) + AVR # 21 PM	DR. VARGHESE T.PANICKER
412	390912	RETHNA BAI N	55	F	07-Jul-2015	RHD SEV MS, MOD MR, SEV TR, MILD PAH, MOD LVD, AF P/CVA, NC	MVR (# 29 CHVP) + TVA (# 30 MC3 RING)	DR. VIVEK V. PILLAI
413	390980	WILSON C.V.	57	M	08-Jul-2015	CAD,TVD,GD LV,SR,P/PCI, DLP	CABG X 5 GRAFTS (LIMA- LAD; RSVG- MEDIAL BR OF MAJ DIAGONAL, BOTH BRS OF MAJ OM & RPDA)	DR. JAYAKUMAR K
414	377070	BABU N	67	M	09-Jul-2015	CAD, TVD, MOD LVD, SR, OLD CVA, DM, HTN, DLP	CABG X 5 GRAFTS (LIMA- LAD; RSVG- MAJ DIAGONAL, RI, LPLB AND RPDA)	DR. JAYAKUMAR K
415	210186	GOPALAKRISHNAN NAIR.C	72	M	10-Jul-2015	SEV CAL AS, MOD AR, ASCENDING AORTIC ANEURYSM, MINOR CAD, GDLV, SR	MODIFIED BENTALLS PROCEDURE (#23 PM + 26MM ALBOGRAFT)	DR. JAYAKUMAR K
416	395287	ABDUL AZIZ M.	55	M	13-Jul-2015	CAD,DVD,TRIVIAL MR,MILD AR/TR,MOD LVD,SR,DM	CABG X 2 GRAFTS (LIMA- LAD , RSVG - MAJ OM)	DR. VIVEK V. PILLAI
417	361580	SUCHITRA S.	16	F	13-Jul-2015	ACHD,OS ASD,GDLV,SR,MILD PAH	TPP CLOSURE OF ASD	DR. VIJAY THOMAS CHERIAN
418	391823	REJIN JOY D.	33	M	14-Jul-2015	RHD,SEV MS,MILD- MOD AS,MILD AR,SEV PAH,LA CLOT,AF	DVR (MVR # 27 CHVP + PMLP , AVR # 21 CHVP)+ LA CLOT REMOVAL	DR. VARGHESE T.PANICKER

419	392098	SUDHAKARAN NAIR M.G	52	M	14-Jul-2015	SEV CALCIFIC AS,MOD AR,MILD LVD,VENTRICULAR BIGEMINY	AVR # 21 CHVP	DR. VIVEK V. PILLAI
420	393350	ANTONY RAVI T.	45	M	15-Jul-2015	RHD,SEV AR,MILD AS,MILD MR,MILD LVD,NC	AVR # 23 SJR	DR. BINEESH K. R.
421	381610	THANKAMMA L	62	F	15-Jul-2015	CAD,TVD,MILD LVD,DM,SR,LEFT RENAL A. STENOSIS	CABG X 4 GRAFTS(LIMA- LAD,RSVG-DISTAL RCA,MAJOR OM,TERMINAL OM)+ DACRON WRAP AORTOPLASTY	DR. VIVEK V. PILLAI
422	391428	KARTHIYANI N.K.	60	F	16-Jul-2015	CAD,TVD,MOD LV,CONC LVH,SR,DM,DLP,HTN	CABG X4 GRAFTS (LIMA - LAD , RSVG - RAMUS , MAJ OM , RCA)	DR. VIVEK V. PILLAI
423	960786 1	RAJALEKSHMI	31	F	20-Jul-2015	RHD,SEV MR,GDLV,SR	MV REPAIR # 27 DURAN ANCORE ANNULOPLASTY RING	DR. VARGHESE T.PANICKER
424	382161	THIMOTHY A L.	62	M	20-Jul-2015	CAD,TVD,GDLV,SR,DM ,DLP.	CABG X 6 GRAFTS(LIMA- LAD,RSVG-MAJ DIAGONAL, BOTH BRANCHES OF RI, MAJ OM AND DISTAL RCA,DIAGONAL PIGGY BACK TO MEDIAL RI)	DR. JAYAKUMAR K
425	392302	SOMASEKHARA KURUP M.S.	51	M	21-Jul-2015	S/P CABG,SSI LT LEG,RECURRENT ULCER LT LEG	RE SSG	DR. BINEESH K. R.
426	391398	FASEELABEEVI A.	48	F	21-Jul-2015	CAD,TVD,DUAL LAD,GDLV,SR,DM,HTN ,DLP	CABG X 5 GRAFTS(LIMA- LAD,RSVG-LAD,MAJ DIAGONAL,MAJ OM, RPDA)	
427	387709	SASIDHARAN P.	64	M	22-Jul-2015	CAD LMCA, TVD, GDLV, SR, DM, HTN, DLP	CABG X 3 GRAFTS (LIMA - LAD, RSVG - MAJ OM, DISTAL RCA)	DR. JAYAKUMAR K
428	7986	RAJAN.T.	57	M	23-Jul-2015	S/P OPASD CLOSURE + MV REPAIR SEV MR, SEV AR, SEV TR, POOR LVRV FUNCTION, CHB ON	REDOSTERNOTOMY + DVR (SUPRA-ANNULAR MVR # 27CHVP + SUPRA- ANNULAR AVR #29 CHVP) + BPP AUGMENTATION	DR. VARGHESE T.PANICKER

						PACEMAKER	OF AORTIC AND MITRAL ANNULUS + BPP RECONSTRUCTION OF AORTIC ROOT	
429	379956	KUMARAN V	46	M	24-Jul-2015	RHD, SEV AS, SEV AR, SEV MR, MOD MS, GDLV, SR, DM, NC	DVR (MVR#21CHVP + AVR#27CHVP)	DR. VARGHESE T.PANICKER
430	392818	REGINA V.	28	F	24-Jul-2015	RHD , SEV MS , MOD MR , OS ASD , GDLV , SR , SEV PAH	DC OF ASD + MVR # 25 CHVP	DR. VIVEK V. PILLAI
431	340433	LEELA KUMARI C	49	F	27-Jul-2015	RHD,SEV CALC MS, MOD MR, MOD PAH, GD LV, AF	MVR # 27 CHVP	DR. VARGHESE T.PANICKER
432	392807	THOMAS JOSEPH	67	M	27-Jul-2015	CAD,TVD,CSA,GD LV,DM,HTN,DLP,SR	CABG X 6 GRAFTS (LIMA - LAD , RSVG - D1/D2/OM 1/OM 2/RCA)	DR. JAYAKUMAR K
433	399315	SIVAPRASAD S.	53	M	28-Jul-2015	CAD TVD, LMCA, SR	CABG X 6 GRAFTS (LIMA-LAD, RSVG- D1, D2, D3, MAJOM, RPDA)	DR. JAYAKUMAR K
434	391855	HAMEED V.M.	54	M	29-Jul-2015	RHD SEV MS, MOD MR, FAIR LV, SR, DM, COPD	MVR #25CHVP	DR. BINEESH K. R.
435	392805	CHANDRASHEKHARA PILLAI K.	57	M	29-Jul-2015	CAD, TVD, SEV LVD, DM, HTN, SR	CABG X 4 GRAFTS (LIMA-LAD, RSVG - D1, LATERAL BRANCH OF OM, LPDA) + LINEAR PPLICATION OF ANTERIOR WALL OF LV	DR. JAYAKUMAR K
436	383874	MURALIDHARAN P.	47	M	30-Jul-2015	CAD,TVD,GD LV,SR,DM,HTN	CABG X 4 GRAFTS(LIMA-LAD;RSVG-D1,MAJ OM MEDIAL BR AND RPDA)	DR. JAYAKUMAR K
437	369998	ANISH T	28	M	31-Jul-2015	SEV AR, FAIR LV FUNCTION, S/P RSOV REPAIR, MILD PAH, SR.	REDO STERNOTOMY + AVR # 25 CHVP	DR. VARGHESE T.PANICKER
438	400353	B/O SREEKALA	0	F	03-Aug-2015	OBSTRUCTED INFRACARDIAC TAPVC,SEV PAH,GDLV,SR	PRIMARY SUTURELESS REPAIR	DR. BAIJU S.DHARAN
439	400414	MUHAMMED SHIHAN C P.	0	M	04-Aug-2015	CS TAPVC MOD PAH GDLV SR	PRIMARY SUTURELESS REPAIR OF CS TAPVC, REROUTING OF LSVC TO	DR. BAIJU S.DHARAN

							RA	
440	395490	ADITYAN B.	8	M	05-Aug-2015	ACHD OSASD GD LV MILD PAH SR	ASD CLOSURE	DR. THOMAS MATHEW
441	352911	ALSHAH P K	2	M	10-Aug-2015	DTGA,SPVSD,SEV PS,PFO,L POSED AO,P/BAS,SR,GDLV,SR	RASTELLI PROCEDURE	DR. BAIJU S.DHARAN
442	390395	FAMIYA FATHIMA KADAVATH	1	F	11-Aug-2015	SAVSD WITH INFLOW EXTENSION,MULTIPLE ADDITIONAL VSIDS, SEV PAH, GDLV,SR	VSD CLOSURE, PA & BRANCH PA PLASTY	DR. THOMAS MATHEW
443	400368	B/O TIBY	0	M	12-Aug-2015	ALCAPA,MILD MR,SEV LV DYSFN,SR,CLEFT LIP & PALATE	LCA TRANSLOCATION	DR. BAIJU S.DHARAN
444	368831	AKSHAY KRISHNA K	5	M	13-Aug-2015	OSASD,NO PAH,GDLV,SR	ASD CLOSURE	DR. VIJAY THOMAS CHERIAN
445	323357	ABIGAIL BINU CHERIAN	4	F	14-Aug-2015	DILV, DTGA, P/PAB + PDA INTERRRUPTION(2011), GD VENTRICULAR FUNCTION, SR	REDOSTERNOTOMY, BDG, ATRIAL SEPTECTOMY, MPA INTERRUPTION.	DR. BAIJU S.DHARAN
446	365060	SREEKUTTY PURUSHAN	18	F	17-Aug-2015	PA SAVSD GD CONFLUENT PA ANATOMY P/LMBTS (1999) PDA SR	ICR WITH RV-PA VALVED CONDUIT(19 PERIMOUNT MAGNA + 22 DACRON TUBE GRAFT COMPOSITE CONDUIT)	DR. THOMAS MATHEW
447	397713	B/O PRASANNA VIJAYAKUMAR	0	M	18-Aug-2015	CCHD DTGA SP VSD GDLV SR 1 LCX 2 R	ASO + VSD CLOSURE	DR. BAIJU S.DHARAN
448	400004	BHARATH B	1	M	19-Aug-2015	TOF CONFLUENT PA SPELLS+ SR NC	ICR (SA VSD CLOSURE + INFUNDIBULAR RESECTION) + TRANS ANNULAR PATCH	DR. THOMAS MATHEW
449	398343	THEJAS SUBIN A.	0	M	20-Aug-2015	TOF CONFLUENT PA B/L SVC NC SR SPELLS+	ICR (GP CLOSURE OF VSD + INFUNDIBULAR RESECTION) + RVOT PATCH	DR. THOMAS MATHEW
450	400717	IMAN SYED AFSAL	4	M	25-Aug-2015	SVASD WITH PAPVC OF RUPV TO SVC RA JN, B/L SVC, NO PAH,	WARDEN'S REPAIR	DR. SABARINATH MENON

						SR		
451	386235	MINHA FATHIMA V.P.	4	F	26-Aug-2015	OSASD, HYPERKINETIC PAH,MOD TR, SR NC	TPP CLOSURE OF OSASD + BICUSPIDISATION OF TV	DR. SABARINATH MENON
452	950733 0	JABIR.T.P	24	M	26-Aug-2015	PE,S/P ICR FOR TOF DORV,ADD.MUSCULA R VSD,GD LV,SEV PAH,SR	PE DRAINAGE	DR. SABARINATH MENON
453	386918	LEKSHMI S.	0	F	27-Aug-2015	CCHD DOUBLY COMMITTED VSD, OS ASD, B/L SVC, MOD PAH, SR, NC	VSD CLOSURE (PFO OPEN)	DR. BAIJU S.DHARAN
454	399251	GODWIN BINU	0	M	01-Sep-2015	UNOBSTRUCTED SCTAPVC, MILD PAH,GDLV, PDA	ASO + VSD CLOSURE + OS ASD CLOSURE	DR. BAIJU S.DHARAN
455	399943	DIYA LAKSHMI	0	F	02-Sep-2015	CCHD TOF, DOUBLY COMMITTED VSD, VALVULAR PS, SR, NC	TAPVC REPAIR	DR. SABARINATH MENON
456	321302	MALU S.C.	4	F	02-Sep-2015	CCHD,DTGA,INTACT IVS, ASD,PDA, PRESERVED LV, SR, 1L 2RCX	TRANS RA-PA ICR	DR. SABARINATH MENON
457	401056	B/O MINI	0	F	03-Sep-2015	DESATURATION, S/P BDG AND ATRIAL SEPTECTOMY FOR PA, INTACT IVS.	ASO	DR. BAIJU S.DHARAN
458	401826	SINUSHID S.	0	M	06-Sep-2015	S/P BDG+ AS+PAPVC ROUTING	REDO STERNOTOMY WITH LIGATION OF VENOUS COLLATERALS	DR. BAIJU S.DHARAN
459	401826	SINUSHID S.	0	M	08-Sep-2015		REDO BACKOUT	DR. BAIJU S.DHARAN

INTERESTING CASES

INTERESTING CASES

- BENTALL OPERATION FOR ANNULO AORTIC ECTASIA IN MARFANS SYNDROME
- ASO WITH ACCESSORY MITRAL VALVE TISSUE RESECTION FOR DTGA WITH INTACT IVS , ASD , S/P BAS , PDA ,LVOTO DUE TO ACCESSORY MITRAL TISSUE
- VSR CLOSURE WITH PRE-CLOTTED FELT PATCH+LV ANEURYSMORAPHY + CABG X 1 GRAFT(RSVG-LAD)
- ANOMALOUS LCA TRANSLOCATION
- RESECTION AND EXTENDED E-E ANASTAMOSIS WITH REVERSE SUBCLAVIAN FLAP
- CABG X 3 GRAFTS (LIMA- LAD;RSVG-D1 AND MAJOR OM) WITH EXTENSIVE LAD ENDARTERECTOMY AND VEIN PATCH AUGMENTATION
- RV TO PA HOMOGRAFT CONDUIT REPAIR
- WARDEN'S PROCEDURE
- ONE AND A HALF REPAIR(CONE REPAIR+ BDG)
- RASTELLI PROCEDURE

BENTALL OPERATION FOR ANNULO AORTIC

ECTASIA IN MARFANS SYNDROME

DIAGNOSIS: MARFAN'S SYNDROME, ANNULO AORTIC ECTASIA, SEV AR, DIL LV, MILD LVD, S/P COA STENTING, SEV PAH, OS ASD, SR WITH 1 AVB, AVNRT, OLD CVA (RECOVERED)

PROCEDURE: MODIFIED BENTALL'S PROCEDURE (AVR#25 CHVP AND #26 ALBOGRAFT)

HISTORY: 24 years old shopkeeper from Assam presented with H/o H/o DOE FC II AND Palpitation since 4years, started as FC- II now progressed to FC- III. H/o Atypical Lt sided chest pain occasionally. No h/o syncope / pre-syncope. No H/o ACS/ CCF. No H/o ALI. H/o CVA (Lt Hemiparesis) 12 years back with complete neurologic recovery. No h/o DM / HTN / DLP. H/o CoA stenting done on 26/4/2013 at SCT. Elder brother is also a Marfan's syndrome with h/o aortic surgery 6 years back.

PHYSICAL EXAMINATION:

GE: No pallor, icterus, clubbing, cyanosis, LN, Pedal oedema.

PR: 82/min, Regular. Water hammer pulse+, Peripheral pulses palpable

BP: 150/40 mmHg. JVP: Not raised.

CVS: Hyper dynamic precordium. Apex beat Lt 6 th ICS in anterior axillary line. No Palpable P2. No thrill. S1, S2 normally heard. Grade 3/6 EDM at Aortic area.

Peripheral signs of AR Present: Corrigan's pulse, Hill's sign, De Musset's sign, Quincke's sign, Duroziez's sign, Traube's sign, Lincoln's sign.

RS: AEBE, Clear. Abdomen: No hepatosplenomegaly. CNS: NAD

INVESTIGATIONS:

Blood Investigations: Normal

CXR: CTR 0.68, Bone and Soft tissue shadows normal. LV apex. Dilated Ascending aorta. Left arch. Stent in situ in DTA.

ECG: SR. HR 78/min. 1' AVB, LAE, LV vol overload+, LVH+, QRS Axis + 45 deg.

ECHO: LV 76/51, LA/Ao- 28/65, EF 45%, Dilated LV, Fair LV function. AV- Trileaflet mobile, Annulo aortic ectasia, aortic annulus 32 mm, AR 4+, TR 2+, RVSP 33+RA, Peak gradient across CoA stent 30. No VSD/PDA CT
Angiogram: Annuloaortic ectasia. Normal coronaries. Aorta at the level of annulus 7.8 x6.5 cm. Distal Asc Aorta 3.2 cm and Aortic arch- 3 cm. DTA- 2.6 cm. DTA at diaphragm- 2 cm.

SURGICAL FINDINGS: Cardiomegaly present, Dilated LV, Fair LV function. Aortic valve Trileaflet and thin. Dilated aortic annulus (35 mm). Sev AR. Dilated and aneurysmal sinuses (NCC>>LCC/RCC). Dilated and thinned

ascending Aorta measuring approximately 8 x 7 cm. Distal asc aorta and arch normal.

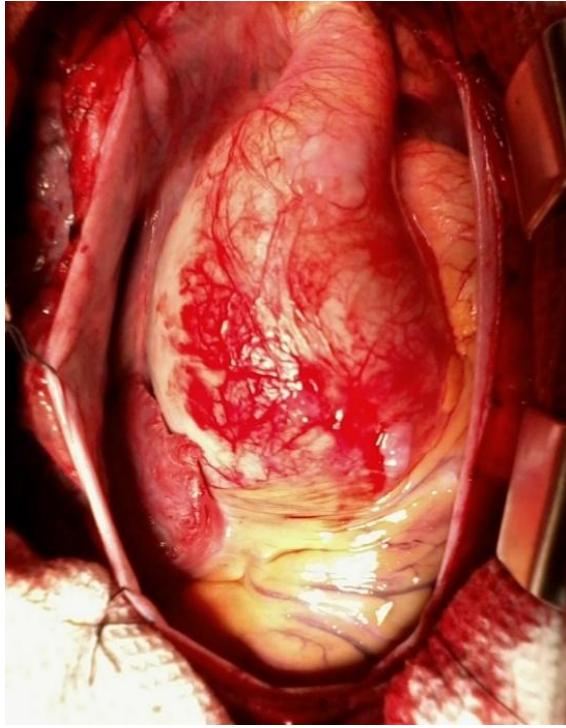
Aorto – RA Cannulation CPB time: 126 mins. ACC time :98 mins.

PROCEDURE: Standard midline sternotomy. Aorto-RA bypass. LV vented through RSPV. Aorta cross clamped. Aorta transacted, Complete diastolic arrest of the heart attained with tepid Ostial blood cardioplegia. Aneurysmal aortic sinuses excised and Coronary buttons harvested. Aortic valve excised and the root replaced using a valve graft conduit prepared using 27 CHVP and 28 mm Albograft. Valve movements checked. Both coronary buttons anastomosed to the conduit. Distal anastomosis of the graft to the Aorta performed using 4-0 prolene and Felt interposition. Aorta de-aired through the graft and Aortic cross clamp released. Heart picked up in SR with good rate. Came off bypass with adrenaline 0.05 mics/kg/min. Hemostasis

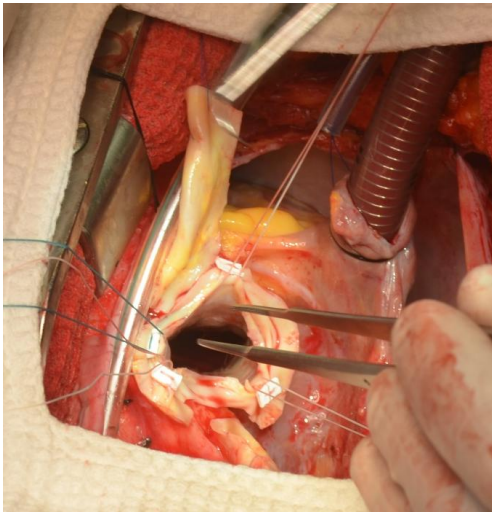
COURSE IN HOSPITAL: Uneventful

Pre discharge ECHO: PV grad-18/9, No AR, Trivial PE, Mild LV dysfunction.

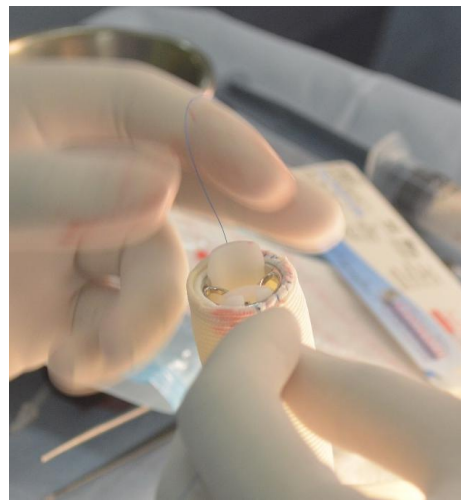
MODIFIED BENTALL'S PROCEDURE



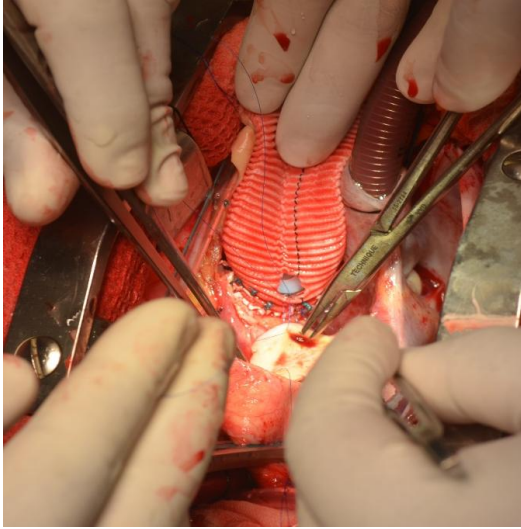
**ANNULO AORTIC ECTASIA – DILATED AORTIC ROOT
WITH NORMAL DISTAL AORTA**



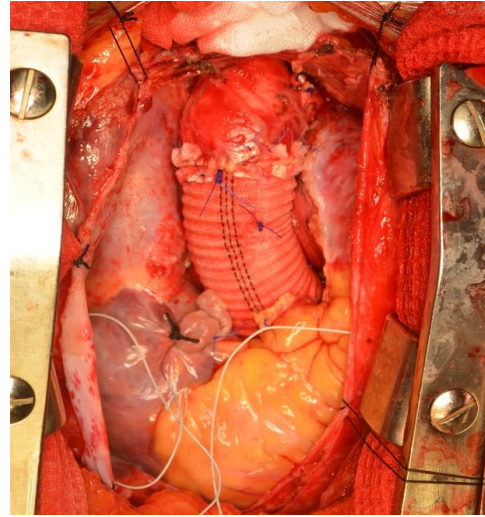
**AORTIC VALVE STITCHES
MODIFIED BENTALL'S PROCEDURE**



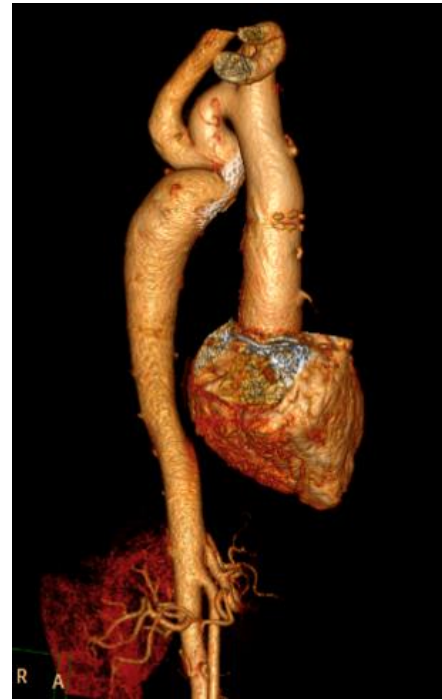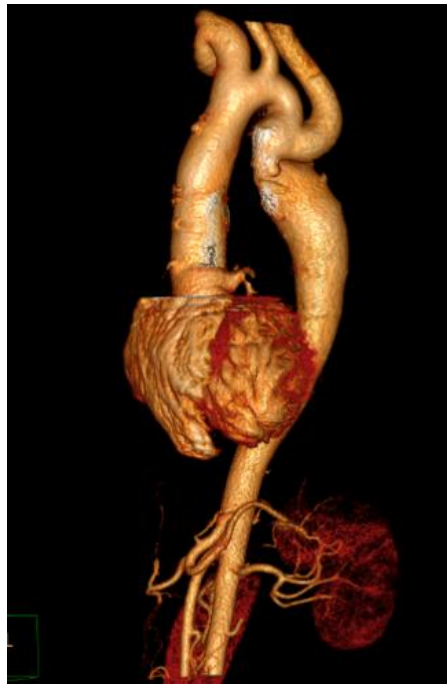VALVE GRAFT CONDUIT



CORONARY BUTTON ANASTAMOSIS



COMPLETED PROCEDURE



**POST OP IMAGES SHOWING NEO ASC AORTA & STENTED COA
SEGMENT**

ASO WITH ACCESSORY MITRAL VALVE TISSUE
RESECTION FOR DTGA WITH INTACT IVS , ASD , S/P
BAS , PDA ,LVOTO DUE TO ACESSORY MITRAL TISSUE

DIAGNOSIS: DTGA , INTACT IVS , ASD , S/P BAS , PDA ,LVOTO DUE TO ACESSORY MITRAL TISSUE, PRESERVED LV, SR

PROCEDURE: ASO WITH ACCESSORY MITRAL VALVE TISSUE RESECTION

HISTORY: 6 day old baby born out of nonconsanguinous marriage at full term by LSCS with birth weight of 3.5 kg, immediately cried after birth. He developed cyanosis on postnatal period and was detected to have cyanotic congenital heart disease on clinical examination. No spells. No significant ante natal history. Admitted for BAS followed by surgical repair.

PHYSICAL EXAMINATION: Baby sleeping well. Afebrile. BP: 78/33 PR: 154/min SPO2: 82% RR: 47/min; cyanosis+. CVS: S1S2+, SM @ LUSB+, S2 single. NS: NVBS+ BAE+, No crepts. Abd : Liver 2cm below RCM

INVESTIGATIONS:

Blood Inv: Within normal limits

ECHO: SS, LC, AV concordance, VA discordance. Normal venous drainage. 2 ASDs,

L->R, No VSD, 3mm PDA EF 66%, Tissue seen 3mm below AV causing

LVOTO; gradient of 75mm of Hg. looks resectable.

CXR: SS, LC, CTR 0.6

SURGICAL FINDINGS: Sternum normal. Mild PE. SS, LC, normal systemic and pulmonary venous drainage, Aorta anterior and to the right, PA posterior and to the left, PA larger than Aorta. Atrioventricular concordance, Ventriculoarterial discordance, ASD of size 2 x 2 cm, Intact ventricular septum, PDA, Accessory additional papillary muscle near apex of ventricle leading to LVOTO.

Coronaries: 1LCX 2R

CPB DATA & MYOCARDIAL PROTECTION: Roller pump and Membrane Oxygenator., Heparin-Protamine chemistry.

Cannulae: Aortic: 8 Fr biomedicus, RA-SVC: 18 BARD, IVC: 14 Fr DLP.

Antegrade tepid blood cardioplegia, followed by direct ostial cardioplegia.

Myocardium protected with topical iced saline. Core cooling upto 26 degrees.

LA vent through the RSPV, Aortic root vent.

CPB Time: 214 min, ACC Time: 133 min.

Urine Output on pump: 20 ml, MUF+CUF 300 ml.

PROCEDURE: Standard midline sternotomy. Thymectomy done. Patch harvesting pericardiotomy, which was given for tanning. Aorta dissected and PA dissected up to hilum, branches looped. Heparinised. Aorta and RA cannulated and went on Aorto atrial bypass after snugging branch PA's. IVC cannulated and connected and CPB instituted. PDA ligated and divided. LA vent inserted. Cooling started. Cardioplegia cannulation done. Aorta crossclamped. Antegrade tepid

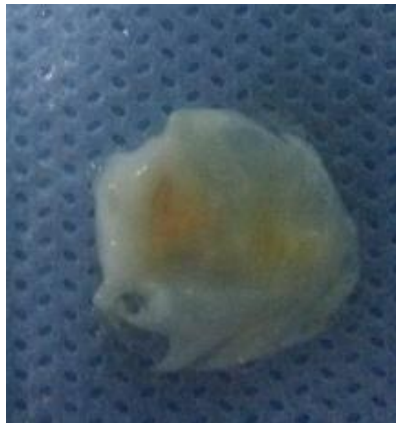
blood cardioplegia delivered and prompt diastolic arrest of the heart achieved. Myocardium protected with iced saline slush. Marker stays taken on the PA, at the planned sites of coronary translocation. Aorta transected. Coronary buttons harvested and adequate length of Coronary arteries mobilised. Neo PA reconstructed with tanned pericardial patch posteriorly and the posterior commissure resuspended. PA transected just below the bifurcation of the PA. Lecompte manoeuvre done. Incisions for coronary buttons made on the neo aorta at the site of marker stitch. Posterior wall of neo aorta anastomosed to the posterior wall of transected distal aorta. accessory mitral tissue causing LVOTO resected from aortic opening. Coronary button anastomosis done after confirming the lie of the coronaries and anterior wall anastomosis completed. Rewarming started. Went on total bypass after pushing in the RA cannula into SVC, and snugging SVC and IVC. RA opened and ASD identified, MV anatomy checked and function confirmed with saline test and closure done with 6-0 prolene. RA closed in single layer. SVC and IVC de-snugged, back on partial bypass. Deairing done and aortic cross clamp removed. Neo pulmonary artery anastomosed to the PA. Two RA, RV pacing wires. Hemostasis confirmed. Heart picked up in sinus bradycardia, for sometime required pacing later own rate picked up to /min. Came off bypass in stages with supports Inj Milrinone 0.75 mcg/kg/min. MUF done for 20 mins. Protamine reversal. Aorta decannulated. Hemostasis achieved. Two Mediastinal drains inserted.

Sternum stented electively. Skin closed with blood bag. Baby was shifted to

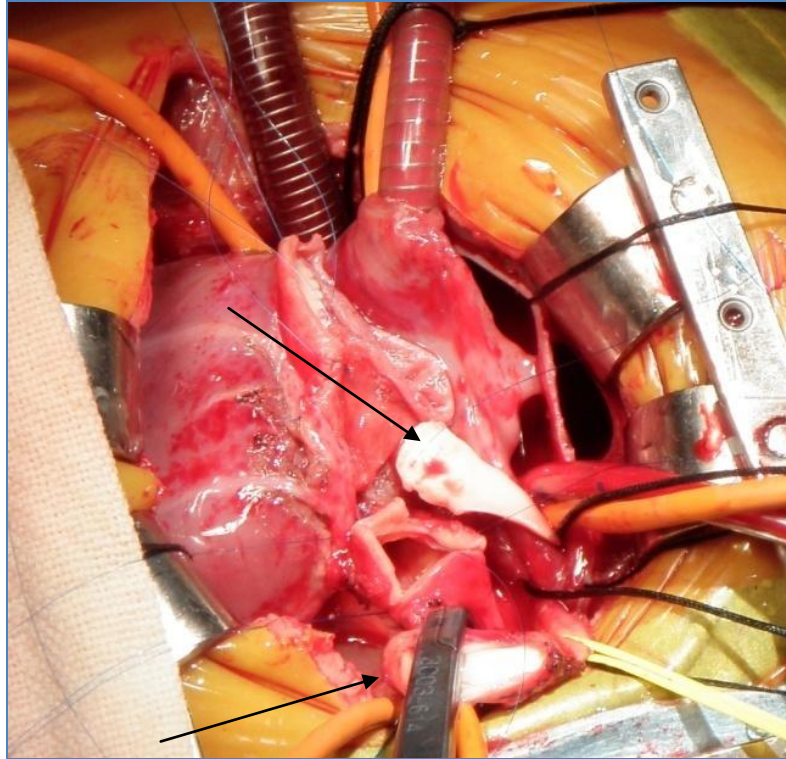
CHICU on supports for elective ventilation.

COURSE IN HOSPITAL: Required prolonged ventilatory and ICU care. Blood Culture showed growth of *Acinetobacter lwoffii*. Started on parenteral antibiotics to which she responded. Patient stable with No signs of sepsis and negative blood cultures at discharge.

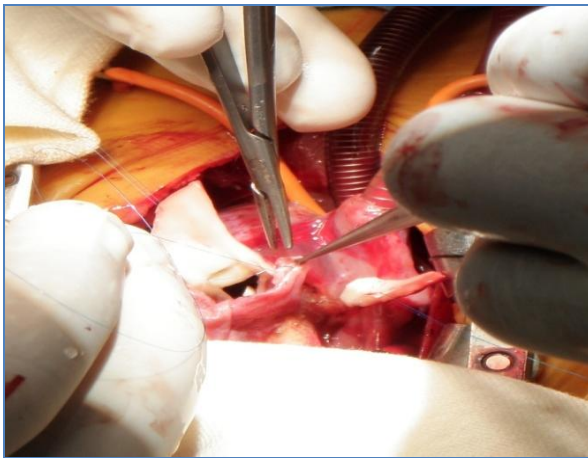
Predischarge ECHO: No PE, good LV/RV function, Laminar Neo Ao/PA flow, No Neo AR.



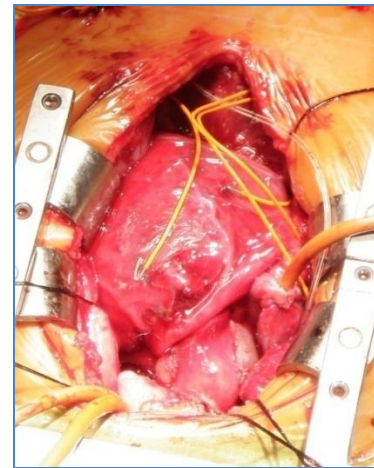
RESECTED ACCESSORY MITRAL TISSUE



HARVESTED CORONARY BUTTONS



**CORONARY BUTTON
ANASTOMOSIS**



COMPLETED ASO

VSR CLOSURE WITH PRE-CLOTTED FELT PATCH+LV

ANNEURYSMORAPHY+CABG X 1 GRAFT(RSVG-LAD)

DIAGNOSIS: CAD,SVD,REC ACS,VSR,MOD LVD,PAH,SR.DM(+),

CONTROLLED CHF

PROCEDURE: VSR CLOSURE WITH PRE-CLOTTED FELT PATCH + LV
ANNEURYSMORAPHY + CABG X 1 GRAFT (RSVG-LAD)

HISTORY: A 63 years old female, known case of DM presented with c/o DOE/FC-II x 3 months. She gives no h/o MI or ACS. h/o orthopnoea +, h/o PND+. No h/o angina / syncope / pre-syncope. No H/o Claudication / CVA / TIA / Seizure / BA. H/o LSCS twice. No significant family history. No h/o drug allergy.She was evaluated at local hospital and found to have signs of recent MI and VSR and referred for further evaluation and management.Now controlled failure.

PHYSICAL EXAMINATION: GC fair. Afebrile.

PR: 94/min, regular, high volume pulse+, Peripheral pulses palpable

BP: 150/60mmHg Rt arm supine. RR: 20 / Min, JVP: Normal.

No cyanosis / icterus / clubbing / oedema / pallor / LNpathy.

CVS-Precordium hyperdynamic. AI at 6th ICS, 1 cm lateral in MCL. S1 S2 (+).

3/6 PSM at apex.

RS: AEBE, clear. P/A: Soft, hepatomegaly,+, CNS- WNL.

INVESTIGATIONS:

Blood Inv: Within normal limits. CXR: CTR- 0.60, Prominent BVM

ECG: SR at 97/min, PR normal

ECHO: LV- 58/46, LA/AO- 40/25, EF- 39%, Septum- 9/10, Septal and ALW RWMA, Global LV hypokinesia, VSD 3 x 3cm L>R. MR- 1-2+, No AR, RVSP- 57 + RA, TV- Normal

CAG: LMCA- Normal. LAD- total obstruction. LCx- Non-dominant and normal.

RCA- Dominant and normal

SURGICAL FINDINGS:

Cardiomegaly (+). moderate pericardial effusion, RA, RV tense, LV Apex aneurysmal, 2 x 2 cm anterior distal septal VSD identified from the LV through LV Ventriculotomy(apical aneurysm). No additional VSD's could be visualised. No ASD. Tricuspid valve appears normal.

RSVG harvested from left leg, good caliber and quality.

RSVG-LAD-1.25 proximal disease, arteriotomy site plaquey, distal runoff good

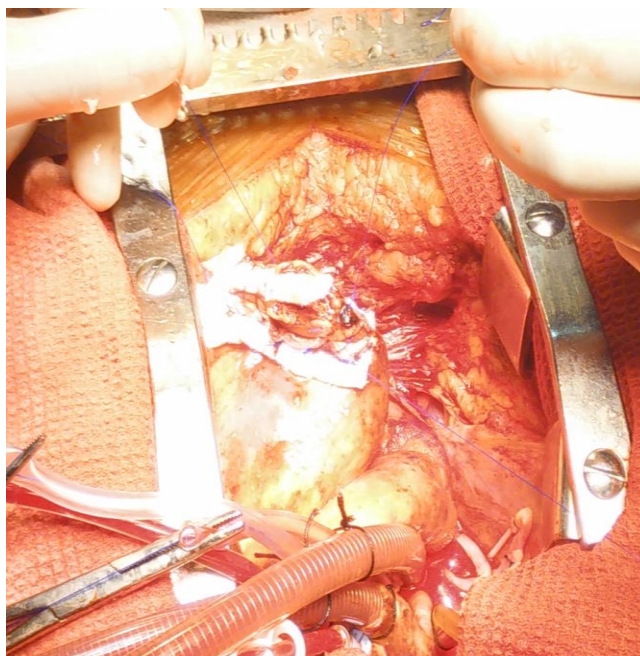
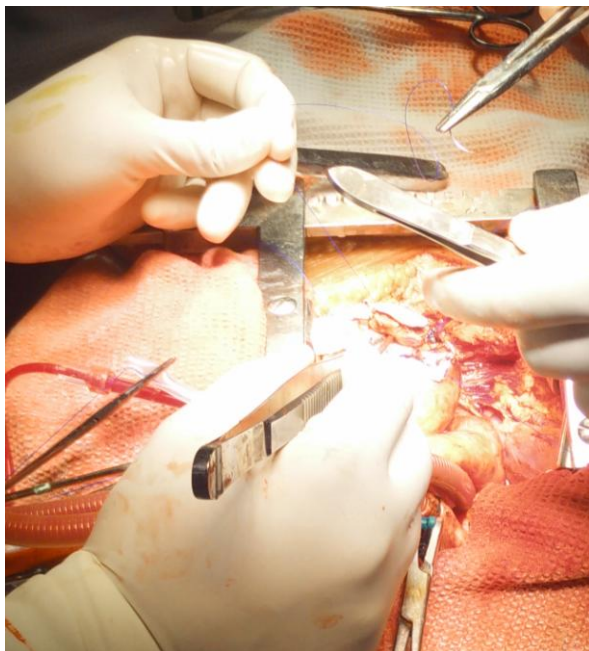
CPB and MYOCARDIAL PROTECTION DATA: Roller pump, membrane oxygenator, crystalloid prime. Heparin - protamine chemistry Aortic root antegrade cold blood cardioplegia, topical ice slush. Aortic cannula - 24 Fr Edwards; SVC - 30 Fr DLP; IVC - 32 Fr DLP. Minimum temp : 27 degree

Urine output on pump : 1300 ml

ACC : 80 min; CPB 500 min

Post-op ECHO : - No residual VSD seen. Fair ventricular fn.

PROCEDURE: Midline sternotomy, pericardium marsupialised, aorto-SVC-IVC cannulation, went on bypass. Heart arrested with antegrade cold blood cardioplegia. Distal anastomosis of RSVG to LAD done with 7-0 prolene sutures. SVC and IVC snugged, went on total bypass. LA opened. VSD visualised. VSD closed with preclotted felt patch, patch fixed to the edges of the defect with 5 interrupted prolene sutures. Checked for additional VSD's. No additional VSD could be made out by direct visualisation. LV apical aneurysmorrhaphy done. Left heart deaired, cross clamp removed. Root vented. Heart picked up in low sinus rhythm. SVC/IVC desnugged. Ventricular pacing wires taken and heart paced. Root vent removed. Proximal anastomosis of the RSVG to aorta done with 6-0 prolene with a side clamp on the aorta. Grafts deaired. Came off CPB. Pt was on supports of adrenaline 0.05 mics/kg/min. Protamine given. Decannulated in stages. Adequate hemostasis achieved. Sternum closed with SS wires (6 nos), skin closed in layers with 2-0 vicryl and 3-0 monocryl sutures. Pt shifted to CSICU for elective ventilation and further management.



LV apical aneurysmorrhaphy after VSR closure

ANOMALOUS LCA TRANSLOCATION

DIAGNOSIS: ACHD, ALCAPA, DILATED CM, SEV LVD, MOD MR, SR

PROCEDURE: LCA TRANSLOCATION + MV ANNULOPLASTY on 25/05/2015.

HISTORY: 4 month old first born male child, born of NCM. No significant antenatal history, full term NVD with birth weight of 3.020 Kg. Diagnosed to have CHD when evaluated for feeding and breathing difficulty on the 7th day of life. Suck-rest-suck cycle present. No h/o Recurrent LRTI/ cyanotic spells/ TIA/ seizures. Not immunised, No history of any other significant illness, Normal development

PHYSICAL EXAMINATION: Patient conscious and alert. No Pallor/ Cyanosis/ Icterus/ Clubbing/ LNE. Skin /hair/ nail normal.

Pulse - 140/min, regular normal volume. CVS- S1S2 +, PSM at apex. Apex at 5th ICS 2 cm lateral to MCL.

Resp. System: Chest clear, No crepitations. P/A: Liver palpable 2cm below right costal margin. CNS: No focal deficit noted.

INVESTIGATIONS:

Blood Investigations: Normal

ECG: SR, HR- 150/ min, QRS axis +30 deg, no clear P waves, Q in I, aVL, V5, V6. ST elevated in V4 to V6.

CXR: CTR 77 %, grossly dilated heart. LV apex

ECHO: LV 39/34, LA/Ao 30/12, AV/ MV normal, septal motion normal, EF 15%, dilated LV, severe LV dysfunction, mild to moderate MR, dilated RCA, LMCA from Pulmonary Artery (with a 3-4 mm intramural course), from Lt facing sinus, Left Arch.

SURGICAL FINDINGS: Situs solitus, levocardia. Normally related great arteries. Normal systemic and pulmonary venous drainage. Atria normal. LV dilated, with poor contractility. Aortic Valve tricuspid. Pulmonary artery not dilated or tense. Pulmonary valve tricuspid. LMCA arising from left facing (posterior) sinus of MPA. RCA arising from Right coronary sinus of Aorta. No intramural course. Dilated collateral vessels on the surface of the heart.

CPB DATA & MYOCARDIAL PROTECTION: Roller pump, membrane oxygenator, blood prime. Heparin-Protamine chemistry.

Aortic cannula - 10 Fr Biomedicus, Venous SVC:14 BARD, IVC-20Fr BARD

Cold antegrade blood cardioplegia initially root and subsequently ostial. Core cooling to 27degrees.

CPB - 252 mts, ACC - 138 mts. Vent: LA vent through RSPV & Aortic root vent.

Urine : 20ml, MUF150

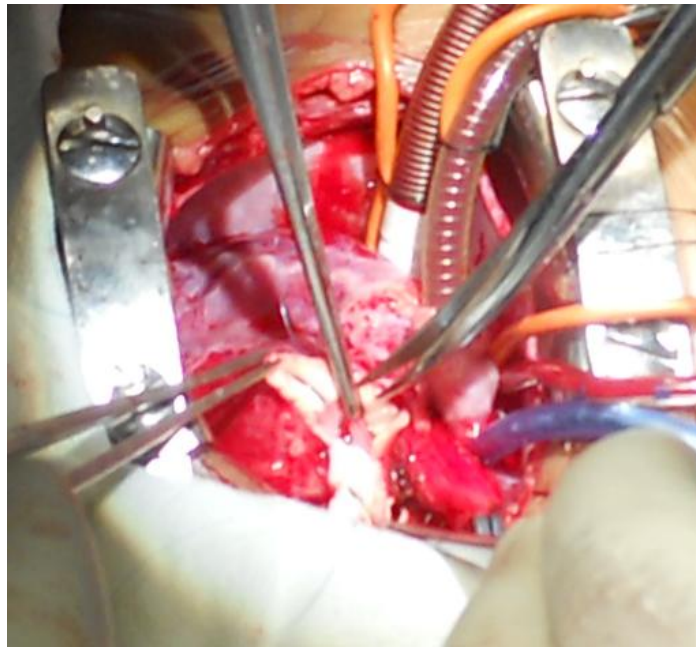
PROCEDURE: Primary median sternotomy. Total thymectomy. Patch harvesting pericardiotomy & pericardial well created. Marking stich over Aorta taken at planned site of LCA translocation. Aorta-PA groove created. MPA & branches dissected (upto hilum) and branch PAs looped. Aorta and RA canulated and went

on bypass. RPA and LPA snugged. PDA transfixated at both ends with 6-0 prolene and divided; followed by clip application at distal end. RSPV vent inserted and cooling started. Aorta and PA separated to root as far as possible. Converted to Aorto bicaval bypass.

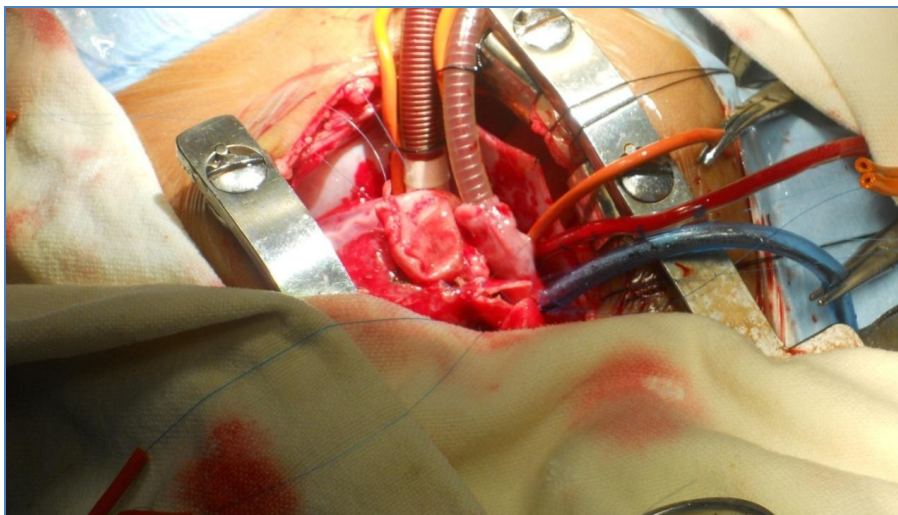
Once temperature reached 27 degrees, Aorta clamped and cardioplegia given into the root of PA and Aorta. Heart arrested promptly in diastole. Went on total bypass. Tropical cold saline and SVC and IVC snugged. PA opened transversely 1 cm above level of pulmonary annulus. LMCA ostium seen in PA and MPA divided completely. Ostial button with LMCA mobilization done along with pulmonary wall additional tissue, A funnel tubing is created to cover additional length required for Ao - LMCA anastomosis. Defect in MPA reconstructed with tanned pericardial patch. Plegia given via Aortic root and LMCA ostium. Aorta opened 1 cm above level of LCC and ostial Button sutured to Aorta with 8/0 prolene. RA opened, Through Atrial septum, Mitral valve was inspected & Mod MR noted with saline test, MV annuloplasty done sized to 10 sized hegar, ASD closed with direct closure & RA closed in single layer. Rewarming started. Caval snigger removed. Dearing done and cross clamp released. Heart slowly picked up in sinus rhythm. Two atrial and two ventricular wires placed. Came off with adequate filling pressures Hemostasis achieved. LA line secured, LA pressures were 20-25mmHg to begin with than gradually managed to keep at 10-15mmHg. 1 Mediastinal & 1 right mediastinopleural drains placed. Sternum kept stented. Incision covered with membrane. Patient shifted to CHICU in a hemodynamically

stable condition for elective ventilation with inotropic supports of 0.05mic/kg/min ADR & NA. Milrinone of 0.5mic/kg/min.

HARVESTING CORONARY BUTTON



ANASTOMOSIS OF LCA BUTTON TO AORTA



RESECTION AND EXTENDED E-E ANASTAMOSIS WITH
REVERSE SUBCLAVIAN FLAP

DIAGNOSIS: ACHD, POST SCA COA WITH DISTAL ARCH HYPOPLASIA, SUPRAMITRAL MEMBRANE, MILD MS, BAV, SMALL VSD, SEV PAH, SR

PROCEDURE: RESECTION AND EXTENDED E-E ANASTAMOSIS WITH REVERSE SUBCLAVIAN FLAP BY LEFT POSTEROLATERAL THORACOTOMY

HISTORY: 10 day old male child. 3rd born male child of NCM born by Emergency LSCS delivery for fetal distress at term with birth weight 2.68 Kg with no significant antenatal history, diagnosed to have CHD at immediate post natal period as baby developed respiratory distress. Diagnosed as Post subclavian coarctation of aorta with severe PAH. H/o suck rest cycles+. Feeding difficulty +. No other significant illnesses. No significant family history. Not on any drugs

PHYSICAL EXAMINATION: Alert. AF Normal No Pallor/Icterus/Clubbing/LNE. Skin/Hair/Nail normal. No deformities.

HR- 150/min Regular, BP Rt U/L 86/59mmHg, Lt U/L 124/98, Rt L/L 78/56, Lt L/L 63/48,

SPO2 -100%

CVS: S1 S2+, Systolic Murmur in LUSB+ RS: B/L Breath sounds+, No crepts,

P/A: Soft, No organomegaly. CNS: No focal Neurological deficits

INVESTIGATIONS:

Blood Investigations: Normal

CXR: Cardiomegaly+, Pulmonary plethora present.

ECG: SR @ 150/min, QRS axis +30

ECHO: LV 14/9, EF 67%, Ao Annulus 7.5, Bicuspid AV, Severe infantile coarctation, Supramitral membrane with mild MS. Small ASD L->R

Sev PAH, Posterior Apical 2.8mm muscular VSD

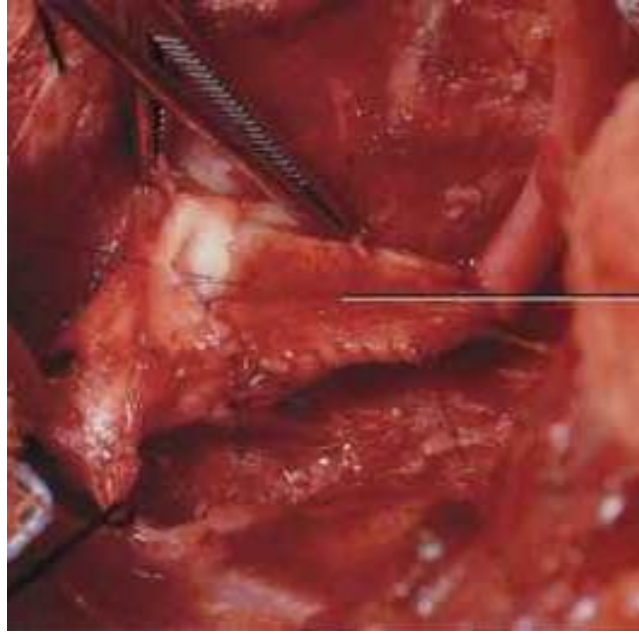
SURGICAL FINDINGS: SS, LC, Left sided Aortic Arch, Distal arch hypoplastic, Arch~ 4 mm, Post SCA CoA with Narrowest portion of the coarcted segment ~ preductal: 1.8 mm, PDA ~ 5 mm. DTA ~ 8 mm. Post Repair Upper Limb Pressures- 80/44 mm Hg. Lower Limb Pressures- 60/42 mm Hg . Mean pressures had a gradient of 10 mm of Hg . Aorta clamping time 26 + 27 minutes with 15 minutes perfusion in between.

PROCEDURE: Left Posterolateral thoracotomy incision. Pleural space entered through 4th LICS. Lt Lung retracted. Posterior pleura incised along the line of Descending Thoracic Aorta, posterior to the Lt Vagus Nerve. Proximal DTA, Arch, PDA, Inominate .A, Left Subclavian Artery, vertebral .A and Left Common Carotid Artery dissected. Entire arch hypoplastic. Left Recurrent Laryngeal Nerves identified and safeguarded. Aorta (proximal and distal to the PDA), PDA, LSCA, LCC dissected out. 3rd and 4th Intercostal arteries and other smaller collaterals ligated and divided at their origin from DTA. PDA ligated and clipped. Stay suture taken on the arch of Aorta, just distal to the origin of LSCA.

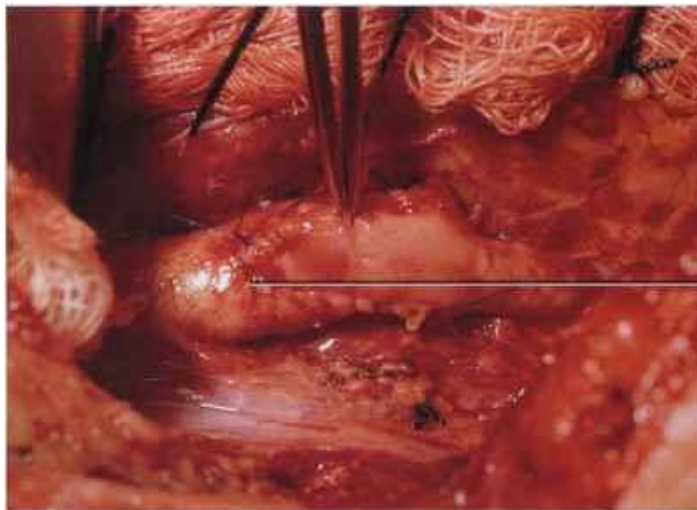
.Aortic arch clamped almost to the base of innominate artery, LSCA clamped separately and Distal Clamp applied in the DTA above the origin of 5th Intercostal Artery. Coarcted segment excised, PDA divided. Incision extended to the under surface of the Arch of Aorta upto the base of Innominate artery. Extended end to end anastomosis done using 6 - 0 Prolene , continuous sutures in single layer. Distal clamp removed before tightening the sutures. Deaired and tightened the suture. Proximal clamp removed in stages. There was a systolic gradient of 45 mm of Hg between upper and lower limb pressures and distal arch looked small. Hence we decided on reverse subclavian flap. After perfusing for 15 minutes Aorta was clamped again and LSCA ligated and proximal part used for reverse subclavian flap. Systolic Gradient came down to 20mm of Hg. Haemostasis achieved. Pleura over DTA closed with 6 - 0 Prolene. Left Pleural drain kept. Thoracotomy incision closed in layers.

Rib sutures with 2 - 0 Vicryl , Muscle in 2 layers with 3 - 0 Monocryl. S/C tissue with 3 - 0 Monocryl, Skin- 4 - 0 Monocryl subcuticular.

Baby shifted to CHICU for elective ventilation and Post operative care on supports of adrenaline 0.05 mics/kg/min.



REVERSE SCA FLAP



REVERSE SCA FLAP

COURSE IN HOSPITAL: Uneventful

**CABG X 3 GRAFTS (LIMA- LAD;RSVG-D1 AND MAJOR
OM) WITH EXTENSIVE LAD ENDARTERECTOMY AND
VEIN PATCH AUGMENTATION**

DIAGNOSIS: CAD LMCA DVD SEV LVD SR

PROCEDURE: CABG X 3 GRAFTS (LIMA- LAD;RSVG-D1 AND MAJOR
OM) WITH LAD ENDARTERECTOMY AND VEIN PATCH
AUGMENTATION

HISTORY: 63 year old with H/O AWTMI on 26/10/2014, TLT with STK-Bhilai.
Now patient is on restricted activity with FC II III AOE/DOE. No h/o
CVA/TIA/bleeding PR/renal stones/BPH. No h/o DM/HTN/BA. Not a
smoker/DM/HTN/f/h/o CAD.

PHYSICAL EXAMINATION: GC fair. Afebrile. PR: 74/min, regular, Low
volume, slow rising pulse. BP: 130/80mmHg. RR: 18 / Min, JVP: Normal. No
cyanosis / icterus / clubbing / oedema / pallor / LN pathy. CVS-Precordium
normal. AI at 5th ICS in MCL. S1 S2 (+).RS: AEBE, clear. P/A: Soft, No
organomegaly, CNS- WNL. Allen's test (-). Carotid bruit (-). PVOD (-).
Varicose vein (-).

INVESTIGATIONS:

Blood Inv: Within normal limits

CXR: CTR- 0.55, Prominent BVM, Ascending aorta mildly prominent.

ECG: SR at 60/min, PR- 160ms, QRS 124 ms, LAD, LVH strain+

ECHO: LV 58/46, EF 35%, LA 31, AO 30. RWMA-AW/AS/AL with thinning +.

No PE /clot, no VSD, MR1+, TR 1+,.

CAG: LMCA- Normal. LAD- Type-III, mid LAD shows diffuse 80%, Distal 99%, term LAD small diagonal diffusely diseased. D1 Diseased, graftable. LCx- Non-dominant, mid LCx 20%, OM1, Normal, OM2 small and total occluded mid part. RCA- Dominant, shows minor irregularities, PLB shows 90% lesion, PDA diffusely diseased.

SURGICAL FINDINGS: Sternum osteoporotic.No Cardiomegaly. No PE. Aorta normal.

LIMA harvested - good flow and calibre. Great saphenous vein harvested from left L.L.of good calibre and quality.

1. LIMA to vein patch augmented LAD -totally occluded vessel. Endarterectomy done.post grafting fair distal flow.
2. RSVG to D1 -1.25 mm, good calibre, Arteriotomy site healthy, post grafting good distal flow
3. RSVG to Maj OM - 1.5mm, good calibre, Arteriotomy site healthy, post grafting good distal flow.

Post Op TEE-No new RWMA.Contractility improved. EF 45%

CPB and MYOCARDIAL PROTECTION DATA:

Membrane oxygenator and Roller pump.

Ao cannula : 24Fr Edwards, Venous cannula: 34/46Fr cannula

CPB time : 77 mins, ACC time: 47 mins.

Tepid blood antegrade aortic root cardioplegia, topical cooling with ice slush, core cooling to 30.0 degrees, aortic root vent.

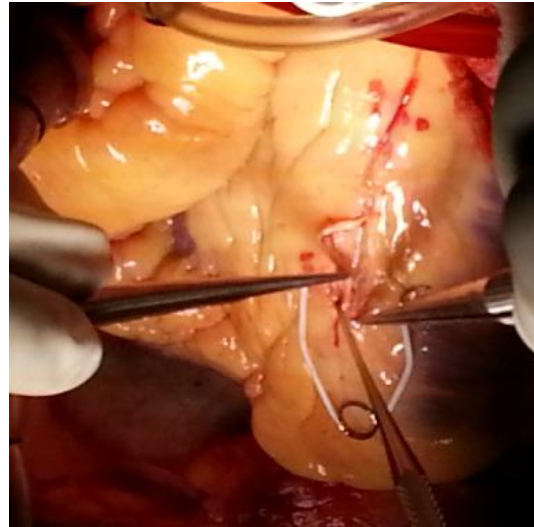
Urine on pump 450 ml

PROCEDURE: Midline Sternotomy, left Lower limb incision for harvesting the great saphenous vein. Pericardium opened and cradled. Heparinised. Aorto & RA cannulation done. CPB started. Cooling started. Aorta cross clamped. Topical cooling with cold saline. Antegrade cold Blood cardioplegia through aortic root. Heart arrested in diastole. Distal venous grafts were anastomosed to D1 & Major OM. LAD was a plaquey vessel with diffuse disease and endarterectomy was done and augmented with a vein patch and LIMA to on-top of the vein patch over LAD using 7-0 prolene. Cross clamp released. Rewarming started. Heart picked up in Sinus rhythm. Side biting clamp applied to Aorta and proximal anastomosis were done. Came off bypass in stages. Stable hemodynamics attained with supports of Adrenaline 0.05 mcg/kg/min and NorAdrenaline 0.05 mcg/kg/min. no NEW RWMA and good contractility was there. Heparin reversal with protamine. Hemostasis attained. Drains placed and wound closed in layers. Patient shifted to ICU with stable hemodynamics on same supports.

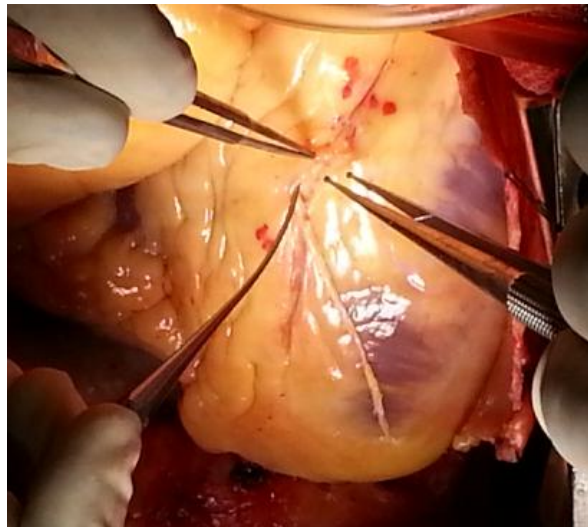
COURSE IN HOSPITAL: Uneventful

Pre discharge ECHO: Good LV/RV/PV function, Trivial PE

LAD ENDARTERECTOMY



ENDARTERECTOMY PLANE



ENDARTERECTOMY SPECIMEN

RV TO PA HOMOGRAFT CONDUIT REPAIR

DIAGNOSIS: CCHD, DOLV, LPA ORIGIN STENOSIS, S/P LMBTS, BLOCKED LMBTS, SR

PROCEDURE: ICR WITH RV TO PA HOMOGRAFT CONDUIT on 18/05/12

HISTORY: 12year old girl, 3rd born to non consanguineously married couple, FTND (Birth Weight 3kg) was diagnosed at birth of having CHD. No h/o spells/ DOE/ CCF/ IE. LMBTS done at 11 months of age. Post BT Shunt, Child was comfortable till 2years back, when parents noticed worsening cyanosis for which evaluated and detected to have poorly functioning BT Shunt. Presently c/o Cyanosis, DOE. No h/o recurrent RTI/ spells/ CCF.

PHYSICAL EXAMINATION: Conscious, Active, Oriented.

No Pallor/Icterus/ LN pathy/Edema, Cyanosis (+), Clubbing (+).

HR: 90/min, SPO2: 72%, RR: 20/min, Wt: 17kg.

CVS – Apex Beat (L) 4th ICS in MCL. S1 S2 heard, Grade 3/6 ESM at Pulmonary area. Well healed (L) Thoractomy Scar +,

RS - B/L air entry equal, Normal vesicular breath sounds

Abdomen - No Hepatomegaly CNS - Normal.

INVESTIGATIONS:

Blood Investigations: Normal

CXR: CTR 63%, Concave Pulmonary bay,

ECG: SR@ 100/min, QRS axis - +110 degree

ECHO: LV - 26/16, LA/Ao- 20/19, RVID- 20, EF - 74%, Situs solitus. Levocardia. Large SA VSD, 50% Aortic Over ride, (L) Arch, no coarctation, poorly functioning LMBTS, No Additional VSD, Aortomitral continuity+, PS gradient 40mmHg, No Coronary crossing RVOT, Pulmonary Annulus - 14mm, MPA - 14mm, LPA- 5mm, RPA - 8mm, DTA- 8.6mm, Infundibular/ Valvar PS

Cath: CCHD, LPA Origin Stenosis, Coronary Origin not Clear- ?LCx separate origin, LAD and RCA common origin with no major vessel crossing RVOT. Poorly functioning BT Shunt, Systemic RV Pressures.

SURGICAL FINDINGS: Situs solitus, levocardia, normally related great arteries. Normal systemic and pulmonary venous drainage. RV hypertrophied and draining to LV through a Subaortic VSD of size 3 x 3 cm. No ASD/ PFO. Tricuspid valve normal. No additional VSD. Overriding of Aorta present (approx. 40 - 50%). Pulmonary Artery arising from LV. Pulmonary Valve: Bicuspid. Pulmonary annulus appears to be of adequate size. MPA and RPA of adequate size. Small LPA, which was not dissected fully. Origin of LPA appears to be patent and that segment near the previous LMBTS appears to be blocked. Blocked LMBTS. Coronaries: LAD arising from RCA and crossing RVOT. Multiple MAPCAs present. Left aortic arch. Increased return from LA throughout the procedure.

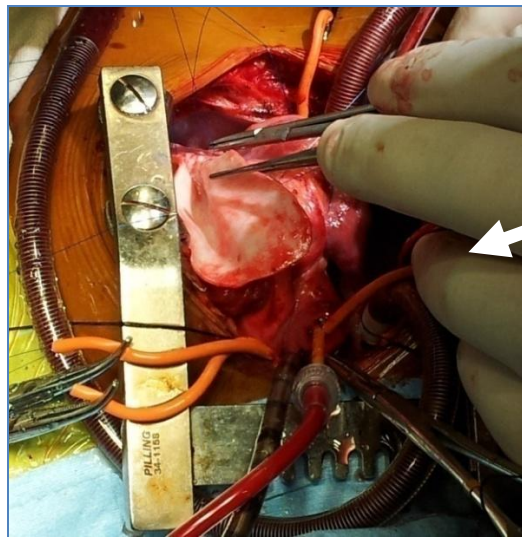
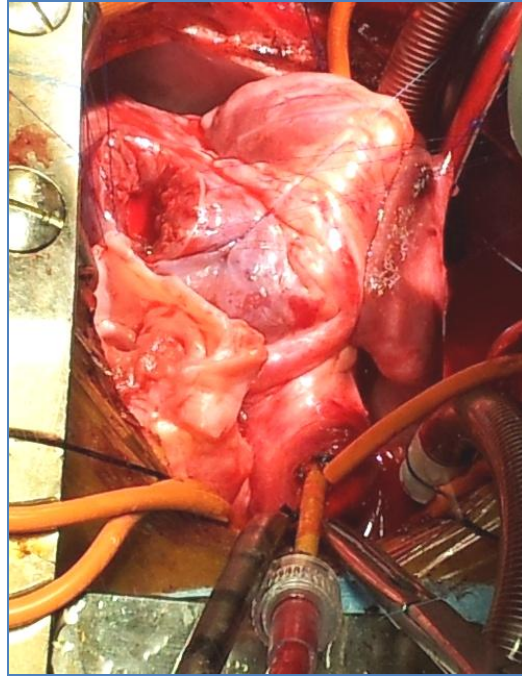
Post Repair pRV/LV = 60/84 mm Hg.

Aortobicaval cannulation.

CPB Time: 212 min ACC Time: 147 min.

PROCEDURE: Standard Midline Sternotomy. Patch harvesting pericardiectomy. Aorta, MPA and LMBTS dissected. PA pressures measured to be 30 mm Hg Mean. Pulmonary Annulus appeared to be of adequate size for weight. Aorto bicaval cannulation. On partial bypass. LV vented through RSPV. Aorta crossclamped. Antegrade tepid blood cardioplegia given and achieved prompt diastolic arrest of the heart. Went on total bypass. RA opened. LA vented through an incision in fossa ovalis. SA VSD closed using PTFE Patch, committing both great vessel openings to LV. MPA transected and the proximal stump closed off in 2 layers. RVOT opened. Distal anastomosis of the homograft conduit was done to the distal cut end of MPA. Proximal anastomosis of conduit to RVOT done with anterior wall reinforcement with bovine pericardium. Fossa ovalis incision closed leaving behind a small PFO. LA vented through RA appendage, through PFO. Heart deaired. Aortic crossclamp removed. RA closed in single layer. Back on partial bypass. Came off CPB. Decannulation in stages. Hemostasis achieved. Wound closed in layers.

HOMOGRAFT BEING ANASTOMOSED TO RVOT INCISION



**BOVINE PERICARDIAL PATCH
AUGMENTATION OF ANTERIOR WALL**

WARDEN'S PROCEDURE

DIAGNOSIS: ACHD, SV ASD, PAPVC OF RUPV, SR

PROCEDURE: WARDEN'S PROCEDURE + PDA LIGATION on 20/06/11

HISTORY: 6 year old boy was evaluated and diagnosed to have an ASD for recurrent LRTI at age of 1. Currently asymptomatic. H/o recurrent LRTI present. No h/o any hospital admissions.

PHYSICAL EXAMINATION: Patient moderately built and nourished.

No pallor, icterus, cyanosis, clubbing, LNE, edema feet.

PR: 96/min, Regular, BP: 100/60 mmHg,

CVS: Apical impulse felt in 5th LICS lateral to MCL, Gr 2/6 ESM at lower sternal border.

RS: Air entry B/L equal, no crepts/ rhonchi.

PA: Soft, no hepatomegaly. CNS: No FND.

INVESTIGATIONS:

Blood Investigations: Normal

CXR: CTR 0.5, RV apex, B/L Prominent PA Branch markings.

ECG: 65/min, SR, QRS +80 degree, RBBB.

ECHO: LV 30/17, LA 22/21, SS/LC, 11 mm SVASD, L -> R shunt, RA/RV dilated, AV/VA concordance, No VSD, no PDA, SVC overriding RUPV-LA junction, TR 2+, RVSP 27 + RAM

SURGICAL FINDINGS: SS, LC. NRG. No LSV. PAPVC of RUPV, with drainage to SVC just above SVC-RA junction. Apical lobe vein draining higher up to SVC as a separate vein. Other PVs draining into LA. Aorta slightly smaller. PA normal sized. PDA of size 7 mm. 1.5 x 1.5 cm SV ASD. Left Aortic Arch.

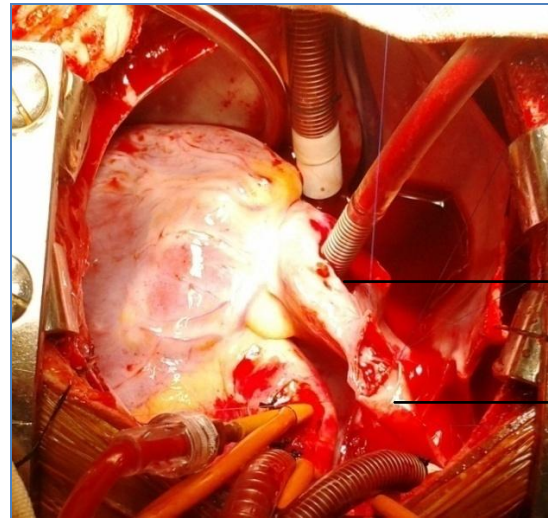
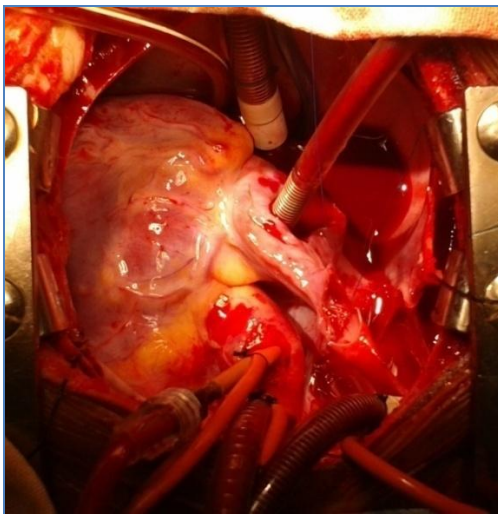
Aortobicaval cannulation

CPB Time: 101 min. ACC Time: 31 min.

PROCEDURE: Standard Midline Sternotomy. Right lobe of thymus removed. Pericardium harvested and given for tanning. Pericardium cradled. SVC and both Brachiocephalic veins dissected. Planned for Warden's procedure because of high insertion of Right Apical lobe vein. Heparinised. Aorta, SVC and IVC cannulated and went on partial bypass. Cardioplegia cannulation done. Went on total bypass using IVC and SVC. Right Internal mammary and Azygos veins ligated and divided. SVC clamped at the junction with Right Apical lobe vein and transected. Cardiac end of SVC oversewn so that all PVs drain into the heart. Aorta crossclamped and tepid blood cardioplegia given through the aortic root. Topical ice cold saline applied. Heart arrested promptly in diastole. RA opened below its junction with SVC. SV ASD closed using tanned pericardial patch. Left heart deaired and aortic cross clamp removed, with root on suction. RA appendage opened at its tip and anastomosed to the proximal end of SVC. Rewarming started. RA closed in single layer. SVC and IVC snuggers released and went on partial bypass. Came off bypass in stages without any inotropic support. Maintaining

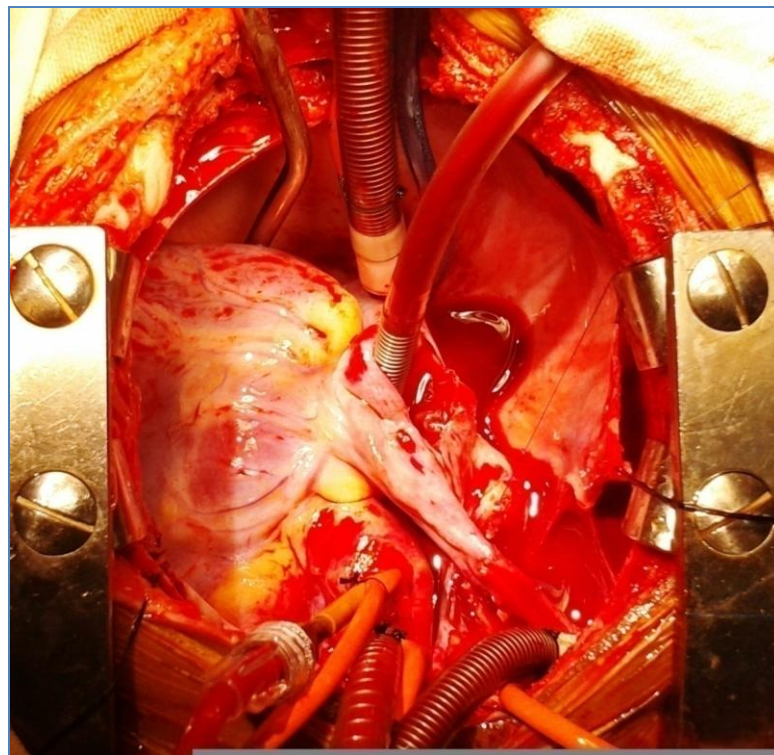
hemodynamics off CPB. Protamine reversal. Hemostasis achieved. Wound closed in layers.

SVC TO RAA ANASTOMOSIS



→ RAA

→ SVC



COMPLETED WARDEN'S PROCEDURE

CONE REPAIR

DIAGNOSIS: EBSTEIN ANOMALY OF TV, SEV TR, NO ASD, SR

PROCEDURE: ONE AND A HALF REPAIR(CONE REPAIR+ BDG)

HISTORY: 44 year old female, K/c/o Ebstein anomaly of tricuspid valve, diagnosed to have CHD at age of 9 years of age.

PHYSICAL EXAMINATION: PR: 75/min. BP: 130/180mmHg. **CVS:** precordium normal. AI – 5th ICS in MCL. S1 S2 (+) **RS:** WNL **CNS:** WNL **PA:** WNL

BLOOD INVESTIGATIONS: WNL

ECHO: SS, LC, LV- 32/28, AVVA concordance (+). Ebstein anomaly of TV, RA/RV dilated, good sized PA , no VSD, Aorta- right and posterior, large mobile ATL, PTL displaced 22mm, PFO Right to Left, No ASD, TR- 4+, MR- 1+, AR- 1+

SURGICAL FINDINGS:

SS,LC,NRGA. Normal coronary pattern.Gross RA dilatation present. RV dilated and fair contractility. Atrialised right ventricle approx 4 cm,Good Confluent PA, CS normal.

Tricuspid valve : Thin large anterior leaflet arising from true annulus and with tethering of free edge and ATL is partially muscularised.No fenestration of the ATL. STL and PTL displaced downwards towards the apex. PTL totally plastered

to the posterior wall of RV. Delaminated septal leaflet small in size and rudimentary. No ASD.

CPB DETAILS:

Heparin protamine chemistry. Myotherm

Aortobicaval cannulation: Aorta : 21 Fr Jostra, SVC:20 Fr DLP; IVC:24 DLP

CPB : 199 min ; ACC :118 min

Core cooling to 29 degree C. Antegrade tepid blood cardioplegia to root

LA vent via LA

Urine - 900 ml

PROCEDURE: Median Sternotomy. Assymetrical patch harvesting Pericardiectomy done. Pericardial patch given for tanning. Pericardium cradled. RPA and SVC dissected and kept. Heparinised. Aortobicaval cannulation done. Went on partial bypass. LV vent through RUPV. Core cooling to 28 deg. Aorta cross clamped. Antegrade Blood CP admistered and heart arrested in diastole. SVC and IVC snugged and went on total bypass.

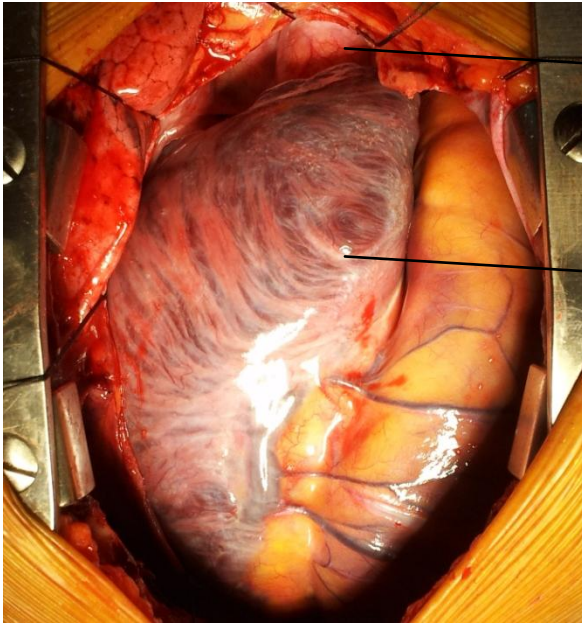
RA opened pallel to AV groove. Findings as above. Anterior leaflet mobilised from the free wall of the RV. ATL dettached from the annulus. Septal leaflet detached from RV. ATL rotated towards the STL . Free margin of STL sutured to mobilised ATL using 6-0 gortex sutures. Carpentier's plication of atrialised RV done using 4-0 prolene. Annulus was reduced to the required size by Devega's posterior annuloplasty. STL and ATL reattached to the annulus using 6-0 gortex

sutures. Tricuspid valve coaptation tested with saline. No TR present. RA closed in single layer with 5-0 prolene.

Rewarming started. Deairing done and cross clamp released. SVC and IVC de-snugged and went on partial bypass. Heart picked up in SR. Came off bypass in stages with adequate filling pressure and dobutamine 5mcg/kg/min. BDG done in view of reduced functional RV for 1 and half repair. Protamine given. Decannulated in stages. Drains placed, Pacing wires taken. Hemostasis attained. Chest closed in layers.

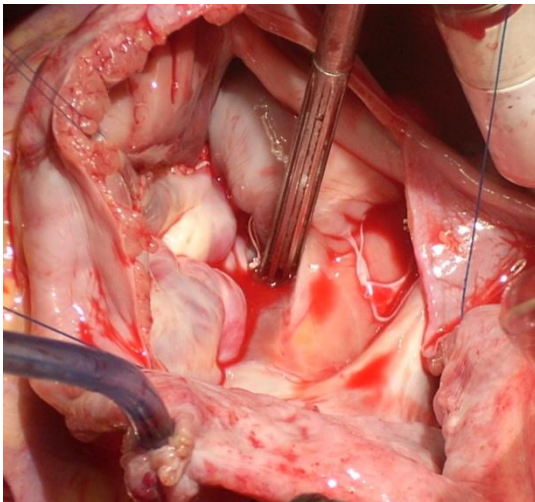
Post OP ECHO: Functioning BDG, No PE/ No Clot, mild RV dysfunction, Good LV function, no PAH. Trivial TR

COURSE IN HOSPITAL: Uneventful

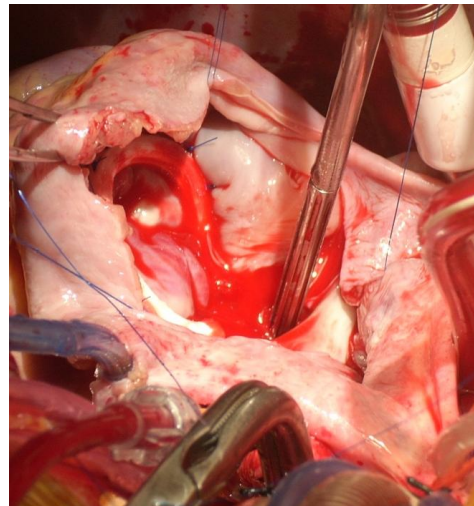


AORTA

ANEURYSMAL RA



COAPTING TV LEAFLETS
AFTER CONE REPAIR



TV ANNULOPLASTY RING

RASTELLI PROCEDURE

DIAGNOSIS: CCHD, DTGA, SP VSD, SEVERE PS, STRADDLING MV, ASD, CONFLUENT PA's, SR, NC

PROCEDURE: RASTELLI PROCEDURE (# 21 PA HOMOGRAFT), PFO OPEN.

HISTORY: A 3 year old male child, 3rd in birth order born to non-consanguineous couple was brought with history of cyanosis since 4 months of age. No h/o cyanotic spell.

PHYSICAL EXAMINATION: Central cyanosis (+). HR: 111bpm. SpO2- 71%.

CVS: Precordium – normal. AI 5th ICS Left lat to MCL. S1 S2- (+) 4/6, ESM in para-sternal area. **RS:** WNL **P/A:** WNL. **CNS:** WNL.

BLOOD INVESTIGATIONS: WNL

ECHO: LV- 27/15, EF- 79%, PW- 7/9, Septum- 7/10, FS- 42, Confluent PAs, RPA- 5.4, LPA- 5.2, SS. LC, OS ASD (B/D), AV concordance, VA discordance, LVOTO gradient 100mmHg (SV level), Sp VSD, No PDA, Left arch.

SURGICAL FINDINGS:

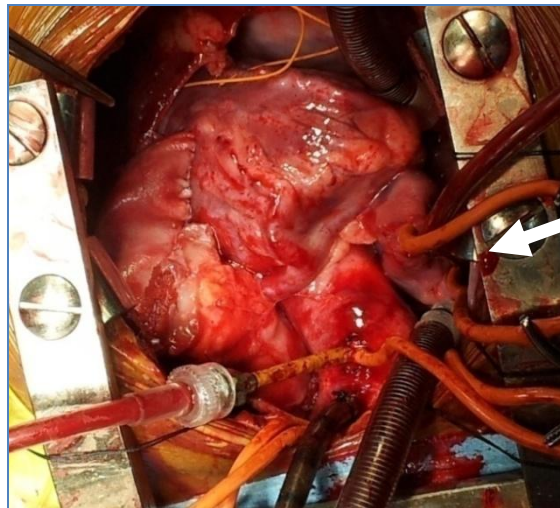
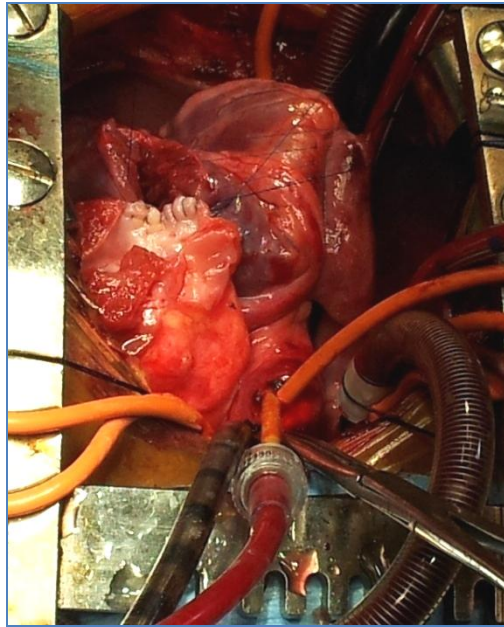
SS, LC, normal PV and systemic venous drainage, AV concordance, VA discordance. Aorta arising from RV and anterior to PA. PA arising from LV. PDA +, MPA and branch PA's are of adequate size, Sub-valvar PS+, coronaries

normal (1LCx, 2R), OS ASD (9mm x 5mm), large subpulmonic VSD. Straddling MV with papillary muscle attached to RV side of septum. TV normal. A large conal branch crossing RVOT.

CPB Details : 245minutes **ACC:** 220 minutes.

PROCEDURE: Median sternotomy. Thymus excised. Pericardial patch harvested and tanned. Branch PAs dissected upto hilum on both sides. Aorto – bicaval CPB instituted. PDA ligated and clipped. Left Heart vent put via RVSP. Core Cooling started. Cardioplegia cannula inserted, Aorta cross clamped. Cardioplegic arrest achieved. RA opened parallel to the AV groove. RVOT opened lateral to conal artery and anatomy assessed, Accessory chordae of MV from IVS excised. Hypertrophied conal septum excised. Goretex patch fashioned. Sub pulmonic VSD rerouted to aorta with goretex patch through RV incision. Intermittent pledgetted sutures used to suture the patch under tricuspid annulus and near aortic annulus. PA divided at confluence, cardiac end sutured in 2 layers. #21 Pulmonary valve conduit sized and fashioned as RV-PA conduit. Posterior layer of anastomosis of conduit to RV done with 5-0 prolene. Anterior layer augmented with BPP. Rewarming started. ASD closed with tanned pericardial patch. PFO left open. RA closed in single layer. De-airing done. Aortic cross clamp removed. Heart picked up in sinus rhythm. 2 atrial and 2 ventricular pacing wires taken and atrial pacing started. Came off CPB with stable hemodynamics. Protamine. Decannulation. Hemostasis achieved. Sternotomy wound closed in layers.

HOMOGRAFT ANASTOMOSIS



COMPLETED ANASTOMOSIS